



Interstitial Lung Disease Associated With the Idiopathic Inflammatory Myopathies

What Progress Has Been Made in the Past 35 Years?

Geoffrey R. Connors, MD; Lisa Christopher-Stine, MD; Chester V. Oddis, MD; and Sonye K. Danoff, MD, PhD, FCCP

Interstitial lung disease is commonly associated with the autoimmune inflammatory myopathies dermatomyositis and polymyositis and accounts for significant morbidity and mortality in these conditions. In the 35 years since the association between inflammatory myopathy and interstitial lung disease was initially described, there has been progress in diagnosing and treating this disorder. Nevertheless, there remains much about pathogenesis and therapeutics to be learned. This review examines the changes in the understanding of this complex condition, highlighting recent advances and areas deserving of further study. *CHEST 2010; 138(6):1464-1474*

Abbreviations: ASA = antisynthetase syndrome; CADM = clinically amyopathic dermatomyositis; CYC = cyclophosphamide; DLCO = diffusing capacity for carbon monoxide; DM = dermatomyositis; HRCT = high-resolution CT; IIM = idiopathic inflammatory myopathy; ILD = interstitial lung disease; MA-ILD = myositis-associated interstitial lung disease; MTX = methotrexate; NSIP = nonspecific interstitial pneumonia; PFT = pulmonary function testing; PM = polymyositis

The idiopathic inflammatory myopathies (IIMs) affect more than 60,000 individuals in the United States and an estimated 770,000 worldwide.¹ Although widely considered a disease confined to muscle, interstitial lung disease (ILD) remains one of the greatest contributors to morbidity and mortality in IIM, resulting in an estimated excess mortality of 40%.² Myositis-associated interstitial lung disease (MA-ILD) may occur in the context of virtually all of the IIM and yet remains poorly understood. Since the first reviews and comprehensive descriptions nearly

35 years ago by Frazier and Miller³ and Schwarz et al,⁴ many case series and a few prospective studies have addressed the pathogenesis of, and therapy for, this condition. Despite these efforts, ILD is independently associated with a poor quality of life for patients with myositis even when the response to the myopathic, arthritic, and dermatologic manifestations is favorable.

This article reviews MA-ILD, focusing on progress made over the past 35 years, as well as highlighting existing gaps in the understanding of this disorder. This review focuses specifically on the lung disease associated with dermatomyositis (DM), polymyositis (PM), and amyopathic dermatomyositis (ADM) and considers pathogenesis and epidemiology, approach to diagnosis, as well as current and investigational treatment modalities. Myositis can also be associated with other connective tissue diseases; bacterial, viral, and parasitic infections; certain drugs; and malignancy; and is found in juvenile forms. Given the less frequent association of ILD with these conditions, they will not be addressed in this review. Through critical review and synthesis of the relevant literature, we aim to clarify what is currently known regarding MA-ILD and bring into focus what remains to be elucidated regarding this multifaceted condition.

Manuscript received January 20, 2010; revision accepted June 1, 2010.

Affiliations: From the Department of Medicine, Division of Pulmonary and Critical Care Medicine (Drs Connors and Danoff), and Division of Rheumatology (Dr Christopher-Stine), Johns Hopkins University School of Medicine, Baltimore, MD; and the Department of Medicine, Division of Rheumatology (Dr Oddis), University of Pittsburgh Medical Center, Pittsburgh, PA.

Funding/Support: This work was supported by funding from the Lisa Sandler Spaeth Fund to S. K. D.

Correspondence to: Sonye K. Danoff, MD, PhD, FCCP; Pulmonary and Critical Care Medicine, 1830 E. Monument St, 5th Floor, Baltimore, MD 21210; e-mail: sdanoff@jhmi.edu

© 2010 American College of Chest Physicians. Reproduction of this article is prohibited without written permission from the American College of Chest Physicians (<http://www.chestpubs.org/site/misc/reprints.xhtml>).

DOI: 10.1378/chest.10-0180

INTERSTITIAL LUNG DISEASE

ILD encompasses a diverse group of pulmonary disorders also known as diffuse parenchymal lung diseases.⁵ These diseases are typically classified together because of unifying clinical, physiologic, pathologic, and roentgenographic manifestations.⁶ Since its description in 1956 by Golden and Bronk⁷ and an initial effort at classification by Liebow and Carrington in 1969,⁸ a precise classification system for ILD has continued to evolve as new clinical, histopathologic, and radiographic information develops. Despite multiple causes for ILD, all culminate in a final common pathway resulting in compromise of the alveolar-capillary interface with subjective dyspnea, decreased exercise tolerance, restrictive physiology, and evidence of reticulation and honeycombing of the lung parenchyma on CT scanning of the thorax. It is estimated that ILD affects 200,000 to 500,000 people in the United States alone and accounts for 100,000 hospitalizations each year.⁶ The annual mortality for all forms of ILD is estimated at 40,000 persons, comparable to that for breast cancer.

IDIOPATHIC INFLAMMATORY MYOPATHIES

The IIMs, initially defined by Bohan and Peter (Table 1) in 1975,^{9,10} encompass a group of disorders in which muscle is targeted in an inflammatory, autoimmune attack that generally leads to muscle weakness. For the purposes of this review, we will not consider the myopathies associated with bacterial, viral, and parasitic diseases; the more uncommon inflammatory myopathies, such as granulomatous myositis or eosinophilic myositis; or inclusion body myositis, as these entities are rarely associated with ILD. The subtypes of IIM relevant to the discussion of ILD include PM, DM, clinically amyopathic DM (CADM), and the antisynthetase syndrome.

THE INTERSECTION OF ILD AND IIM: MA-ILD

It is estimated that among patients diagnosed with PM/DM, 35% to 40% will be afflicted with ILD during the course of their illness, although there is variation in prevalence estimates in the literature and few large-scale cohort studies are available (Table 2).¹¹⁻¹⁹ Little is known about how MA-ILD affects specific populations, including women, minorities, and people of various ages. Overall, ILD is a major contributor to morbidity and mortality, and once pulmonary involvement is recognized in PM or DM the 5-year mortality ranges from 0 to 50% according to several small studies.^{2,20} One longitudinal study of 27 patients

with DM found pulmonary involvement to be the leading cause of death over a 10-year follow-up period.²¹

PATHOGENESIS

There is a great deal yet to be learned regarding the pathogenesis of ILD in the context of myositis. The leading hypothesis is that MA-ILD begins as a cellular inflammatory process that fails to appropriately terminate and progresses to a fibroproliferative condition²² often unresponsive to traditional immunosuppressive therapies. This hypothesis is supported by the longitudinal analysis of several biopsy-proven cases.^{4,23} However, the variable progression of MA-ILD over time lends support to the presence of heterogeneity in its pathogenesis. This variability has led to the examination of a number of other hypotheses regarding the etiology of lung involvement.

Viral Hypothesis of ILD Etiology

One hypothesis is that the inflammatory cascade of MA-ILD, resulting in both the pulmonary and non-pulmonary manifestations, is initiated by an unidentified viral infection, although the associations to date are weak. Many viruses, including coxsackie, influenza, echoviruses, HIV, and human T-cell leukemia virus, have a known tropism to muscle or have been associated with overt myositis.²⁴⁻²⁸ In vitro and animal models also implicate encephalomyocarditis, adenovirus type 2, and the mumps virus as possible etiologic agents.²⁹⁻³¹ Although these viruses are associated with the development of myositis, there is no recognized association with the development of ILD in these patients.

The hepatitis C virus (HCV) has increased seropositivity in patients with DM and PM,³² and PM alone is known to complicate up to 1% of hepatitis C cases.³³ Simultaneous pathologic appearance of hepatitis C and MA-ILD has been reported,^{32,34-36} including the association of Jo-1-positive ILD in a patient with PM with HCV infection.³⁶ Cytomegalovirus has been associated with rapidly progressive ILD in patients receiving immunosuppressive therapy for DM.^{37,38} It is not established whether this represents a de novo infection or reactivation of latent cytomegalovirus contributing to a more fulminant manifestation of already-present ILD.

Finally, parvovirus B19 is known to be associated with a number of autoimmune conditions^{39,40} and has been shown to be causally related to the microvascular injury seen in patients with ILD.⁴¹ To date no study has assessed a sufficiently large population of patients with MA-ILD to confirm this association.

Table 1—Diagnostic Criteria for Polymyositis and Dermatomyositis^{9,10}

1. Symmetric proximal muscle weakness determine by physical examination.
2. Elevation of serum skeletal muscle enzymes (particularly creatine kinase and aldolase), serum glutamate oxaloacetate, pyruvate transaminases, and lactate dehydrogenase.
3. The electromyographic triad of short, small, polyphasic motor unit potentials; fibrillations, positive sharp waves, and insertional irritability; and bizarre, high-frequency repetitive discharges.
4. Muscle biopsy specimen abnormalities of degeneration, regeneration, necrosis, phagocytosis, and interstitial mononuclear infiltrate.
5. Typical skin rash of dermatomyositis, including a heliotrope rash, Gottron sign, and Gottron papules.

Polymyositis is defined through these criteria as definite (all of criteria 1-4), probable (any three of criteria 1-4), or possible (any two of criteria 1-4). Dermatomyositis is defined as definite (5 plus any three of criteria 1-4), probable (5 plus any two of criteria 1-4), or possible (5 plus any one of criteria 1-4).

Cellular and Immunologic Hypotheses of ILD Etiology

A number of studies have focused on components of the cellular immune system in the induction of MA-ILD. In muscle biopsy specimens, CD8⁺ T cells are more closely associated with PM,⁴² whereas B cells and CD4⁺ T cells are more commonly seen with DM and ILD.⁴³ A study evaluating BAL fluid from patients with MA-ILD demonstrated increased T-cell clones compared with healthy controls, suggesting a potential role for T cells in the development of MA-ILD.⁴⁴ Studies examining lung biopsy specimens demonstrate that, in contrast to normal lung tissue in which the number of lymphocytes is low, biopsies from patients with PM/DM have markedly elevated lymphocyte numbers.⁴⁵⁻⁴⁷ These cells, specifically the CD8⁺ T cells, although diffusely distributed in both affected and normal tissue, were noted to be activated.⁴⁸ Elevated levels of these activated cells have also been demonstrated in 22 patients with MA-ILD, with a

difference noted in CD8⁺ levels between steroid-responsive and steroid-unresponsive patients.⁴⁹

Immunogenetics almost certainly plays a role in the development of MA-ILD with known HLA haplotype specificity in the development of both PM and DM as well as associated ILD.^{50,51} Recently, specific HLA-DRB1 and tumor necrosis factor- α subtypes have been reported in patients with MA-ILD.⁵² Furthermore, the HLA-DRB1*03-DQA1*05-DQB1*02 haplotype is associated with (52.3% disease vs 16.5% controls, OR = 5.5) expression of the ILD phenotype in both DM and PM when associated with a positive antisynthetase antibody.⁵³

Humoral Immunity and the Causal Antibody Hypothesis

The identification of autoantibodies, whether specific to myositis or associated with other connective tissue diseases, has led to consideration of a humoral immune etiology: the antisynthetase syndrome (Table 3). The autoantibodies in MA-ILD, which target any one of several aminoacyl-transfer RNA synthetases, are collectively termed antisynthetase antibodies (ASA). Anti-Jo-1, directed against histidyl-tRNA synthetase, is the most common ASA^{54,55} (Table 4)⁵⁶ and was initially reported in 1976 in a patient with PM and ILD.⁵⁷ The complete syndrome was defined in 1990 based on the retrospective analysis of 29 patients with myositis and ILD.⁵⁸

ILD is often the dominant symptom in patients with antisynthetase syndrome and, if present, drives the prognosis and response to therapy. Up to 40% of all patients with myositis, regardless of their ILD status, will be positive for one of the ASAs.⁵⁹ Larger published case series suggest that > 75% of patients with ASAs will develop ILD.^{14,60} A recent cohort study of 90 patients known to be Jo-1-positive demonstrated that 86% of subjects had CT scan evidence of ILD.⁶¹ Patients with DM positive for an ASA are more likely to have ILD than patients with antibody-negative

Table 2—Prevalence of Interstitial Lung Disease in Polymyositis/Dermatomyositis/Clinically Amyopathic Dermatomyositis, 2002-2009

Study/Year	Mean Age, y	Sex Distribution	Ratio of Classifications of DM/PM/CADM	Patients with ILD, No. (%) (PM/DM/CADM)
Tani et al ¹¹ /2007, N = 23	54	6 male, 17 female	9/14/0	17 (74) (5/12/0)
Ye et al ¹² /2007, N = 145	47	47 male, 98 female	61/56/28	70 (48.3) (28/21/21)
Fathi et al ¹³ /2004, N = 17	58	6 male, 11 female	9/8/0	11 (64.7) (7/4/0)
Kang et al ¹⁴ /2005, N = 72	44	14 male, 58 female	22/44/6	29 (40.3) (6/18/5)
Chen et al ¹⁵ /2007, N = 51	44	19 male, 32 female	11/28/12	23 (41.4) (3/16/4)
Won Huh et al ¹⁶ /2007, N = 99	48	43 male, 56 female	...	33 (33.3)
Chen et al ¹⁷ /2009, N = 141	51	50 male, 91 female	69/71/1	30 (21.3) (11/19)
Marie et al ¹⁸ /2002, N = 156	52	58 male, 98 female	90/66/0	36 (23.1)
Selva-O'Callaghan et al ¹⁹ /2005, N = 60	47	19 male, 41 female	17/43/0	22 (36.7)
Totals: N = 764	49	262 male, 502 female	288/330/47	326 (37.4) (60/90/30)

CADM = clinically amyopathic dermatomyositis; DM = dermatomyositis; ILD = interstitial lung disease; PM = polymyositis.

Table 3—Proposed Criteria for the Antisynthetase Syndrome

Patient must have:
Positive serologic testing for an anti-tRNA synthetase autoantibody
Plus one or more of the following conditions:
Evidence of myositis by Bohan and Peter criteria
Evidence of ILD by ATS criteria
Evidence of arthritis by clinical examination, radiographic findings, or patient self-report
Unexplained, persistent fever
Raynaud phenomenon
Mechanic's hands

ATS = American Thoracic Society. See Table 2 for expansion of other abbreviation.

DM (94% vs 23%) and are more likely to require prolonged, higher doses of immunosuppressive agents.⁶² A number of smaller studies have confirmed these associations.^{15,19,59} Also notable is the fact that patients with ASA may present as an undifferentiated connective tissue disease (symptoms including arthralgias, myositis, or dermatologic manifestation without a definable pattern).⁶³

Whether antisynthetase antibodies are causative of MA-ILD or simply a marker of disease remains to be elucidated. Animal studies in which mice were injected with murine Jo-1 antibodies demonstrate an increase in targeted B and T cells as well as a phenotype consistent with diffuse lung and muscle inflammation.⁶⁴ Evidence that disease activity in humans directly correlates with antisynthetase antibody titer levels provides further compelling but indirect evidence of their pathogenic nature.^{65,66} There is also a growing body of literature suggesting the ability of the antisynthetase autoantibodies and their cleaved fragments, once released into the extracellular milieu, to serve as chemokines and cytokines directly responsible for the migration of mononuclear cells and immature dendritic cells and the resultant proinflammatory cascade.⁶⁷⁻⁷⁰ Other work to date, indicating the near-complete absence of these antibodies in the general population combined with early data suggesting unique phenotypic, cellular, and immunologic variation associated with the different antibodies,^{71,72} makes their role as a causative agent of disease possible.

Table 4—Known Antisynthetase Antibodies⁵⁶

Antibody	Antigen (tRNA Synthetase)	Prevalence in IIM, %
Jo-1	Histidyl	25-30
PL-7	Threonyl	2-5
PL-12	Alanyl	2-5
EJ	Glycyl	1
OJ	Isoleucyl	1
KS	Asparaginyl	1
Zo	Phenylalanyl	1
Tyr	Tyrosyl	1

IIM = idiopathic inflammatory myopathy.

The majority of patients with MA-ILD will have symptoms common to all interstitial lung diseases, including cough, dyspnea on exertion, decreased exercise tolerance, and fatigue. Clubbing of the digits may be seen, although it is often not apparent early in the disease. Importantly, this is a syndrome with extreme variability in its main features: patients may present with myositis or dermatologic manifestations or lung disease in any combination simultaneously or sequentially. Although the myopathic manifestations of the IIMs often precede lung involvement, this is not always the case. In one series, 18% of patients ultimately diagnosed with MA-ILD had no muscle-related symptoms at the time of radiographic or physiologic confirmation of lung involvement.¹³ The same study demonstrated that patients with myositis and no evidence of lung involvement had a similar frequency of pulmonary complaints, reinforcing that dyspnea and/or hypoxia in this population can be caused both by intrinsic lung disease and by respiratory muscle weakness. Treatment effects are equally variable. In our clinical experience, response to steroids or other medications may be limited to the myositis, the skin disease, or the pulmonary disease, and any of these features may become treatment unresponsive over time, independent of the others. This suggests that a high index of suspicion for ILD is imperative and a standardized diagnostic algorithm should be considered in this population. A number of skin and joint manifestations may also herald the antisynthetase syndrome. These include nonerosive arthritis, mechanic's hands, and Raynaud phenomenon (Fig 1).

DIAGNOSIS

Based on the existing literature and our large single-center experience, we present a diagnostic algorithm for ILD. This algorithm can be considered for all patients with PM, DM, and ADM upon presentation (Fig 2).

Pulmonary Function Testing

Pulmonary function testing (PFT) is a readily reproducible, validated, and minimally invasive procedure^{73,74} that can both uncover occult MA-ILD and assess the response to therapy over time. Patients typically demonstrate a restrictive pattern of disease (FVC or total lung capacity < 80% of the predicted value for age and height) with a decrease in the diffusing capacity for carbon monoxide (DLCO). Notably, an FVC < 60% predicted at the time of diagnosis has been associated with a worse overall survival.¹⁴ PFTs are useful for deciding whether lung disease is worsening despite

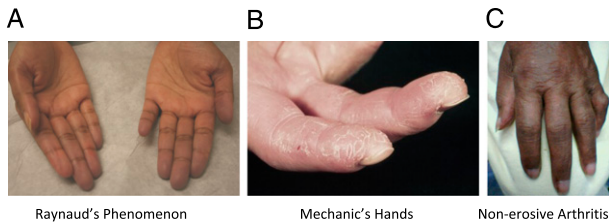


FIGURE 1. A, Raynaud phenomenon. B, Mechanic's hands. C, Nonerosive arthritis.

improving muscle and skin disease as well as determining the cause of common, nonspecific complaints, such as fatigue, which can have their basis in either lung or muscular dysfunction.

Complicating the use and interpretation of PFTs in this population is the potential coexistence of respiratory muscle weakness and ILD. As the disease manifesta-

tions can be variable both between individuals and in an individual over time, it is critical to interpret lung volumes with caution. A diagnosis of ILD in this population cannot be made in the absence of a confirmatory CT scan because PFTs with a restrictive physiology and low DLCO could be the result of respiratory muscle weakness alone. Similarly, progressive ILD can be obscured by a pseudostabilization of the PFTs as diaphragmatic strength improves. The use of the DLCO in these cases can be helpful as a relatively preserved DLCO in the setting of restrictive physiology favors respiratory muscle weakness. A reduced DLCO in this setting, however, is not as helpful as it could result from either ILD or atelectasis in the lung bases, which can accompany respiratory muscle weakness.

High-Resolution CT Scanning

High-resolution CT (HRCT) scanning of the thorax provides a sensitive marker of ILD with some potential to predict response to early therapy.^{75,76} Characteristic HRCT findings include nodules, micronodules, linear opacities, irregularity of interfaces, ground glass opacities, fibrosis with or without honeycombing, consolidation, traction bronchiectasis, and bronchiolectasis.^{13,77,78} Early studies in MA-ILD suggested a better response to therapy in patients with ground glass as the predominant pattern on CT scan.⁷⁹ In contrast, subsequent studies have suggested that patients demonstrating more ground glass opacities and reticulation were more likely to have a poor prognosis than those with a predominantly fibrotic pattern.^{16,76} One study demonstrated a 72% vs 21.2% 3-year mortality based on the pattern of disease with ground glass/reticulation being worse.¹⁶ Further research is needed to validate CT scanning as a prognostic tool.

Fiberoptic Bronchoscopy

Bronchoscopy with BAL can be helpful to rule out occult infections, which can resemble interstitial lung disease. This is especially relevant for patients on immunosuppressive drugs for a prolonged period of time because such patients are susceptible to atypical infections, including *Mycobacterium avium intracellulare*, *Pneumocystis pneumonia*, *Nocardia* lung disease, atypical bacterial pathogens, and, more rarely, cytomegalovirus and fungal infections.

The role of transbronchial biopsy in diagnosing the histologic type of ILD is limited. One recent study from Japan has shown a prognostic benefit to transbronchial biopsy in previously unclassified MA-ILD.⁸⁰ When biopsy specimens were grouped according to the type of intraluminal fibrosis observed (bud or poly-

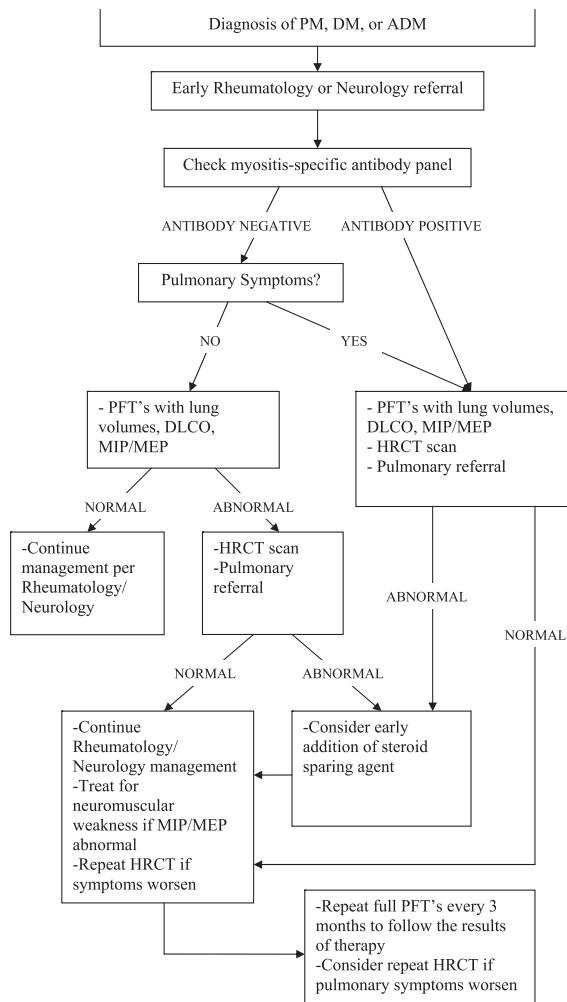


FIGURE 2. Myositis-associated interstitial lung disease diagnostic flow chart. ADM = amyopathic dermatomyositis; DLCO = diffusing capacity for carbon monoxide; DM = dermatomyositis; HRCT = high-resolution CT; MEP = maximal expiratory pressure; MIP = maximal inspiratory pressure; PFT = pulmonary function test; PM = polymyositis.

type vs mural incorporation type), the patients with bud-type fibrosis had a 100% response rate to steroids, whereas the patients with mural incorporation-type fibrosis only responded 21% of the time and had a 5-year mortality of 29%.⁸⁰ At present, surgical lung biopsy remains the method of choice for diagnosis of ILD subclasses in patients with myositis.

Surgical Biopsy

The role of surgical biopsy remains controversial. Regional histopathologic variability can make representative tissue sampling challenging. This has led to differing opinions in the literature regarding whether biopsy findings are sufficient to guide treatment or aid in prognosis. Numerous small studies have reported MA-ILD histology, and the results are summarized in Table 5.^{81,82}

The majority (56.3%) of reported patients have nonspecific interstitial pneumonia (NSIP) as their biopsy diagnosis, with usual interstitial pneumonia (17.5%), cryptogenic organizing pneumonia (14.6%), diffuse alveolar damage (5.8%), lymphocytic interstitial pneumonia (3.8%), and unknown histology (1.9%) following in decreasing frequency. Although one series identified a relationship between biopsy subtype and disease prognosis,⁴⁷ 5-year mortality appears to have little relationship to biopsy subtype in three other studies^{2,81,82} and offers unclear prognostic value above CT scanning and pulmonary function testing alone. At this time, the evidence suggests that open lung or video-assisted thoracoscopic surgery biopsy should be used only to clarify the diagnosis of ILD if there is clinical uncertainty. Given the paucity of literature, the role of surgical lung biopsy in prognosis and therapeutic decision making is an area deserving of further research.

SERUM BIOMARKERS

The serum muscle enzyme creatine kinase has been examined as a biomarker of IIM disease activity, but its role in MA-ILD has not been studied to date.

Other general markers of inflammation, such as the erythrocyte sedimentation rate⁸³ and lactate dehydrogenase,⁸³ have been shown to be elevated in MA-ILD in a single case study. More promising is the mucin-like glycoprotein KL-6, whose elevation in MA-ILD has been demonstrated in several small, prospective studies in Europe and Japan.⁸⁴⁻⁸⁶ Other serum biomarkers have also been described in a limited fashion, including B-cell activating factor,⁸⁷ surfactant protein D,⁸⁶ and the tandem of cancer-associated serum antigen and CA 15-3.^{88,89} The level of current evidence favors more lung-specific measures, such as PFTs and HRCT scanning, in following the pulmonary disease course.

CURRENT THERAPEUTIC APPROACHES

Despite the common use of steroids and various steroid-sparing agents, no prospectively tested therapeutic regimen for MA-ILD exists at this time. Since the recognition of MA-ILD, corticosteroids, either in oral or IV form, have been regarded as the mainstay of therapy. A number of immune modulating agents have been tested in small studies. The options for therapy are presented below, but it should be noted that the majority of the studies were neither placebo-controlled nor prospective.

In addition to more commonly accepted medications, a number of other experimental therapeutic agents and approaches have been tried in an effort to slow the progression of MA-ILD. Among these are immunosuppressive and biologic agents targeted at disrupting T- and B-cell function directly. Less conventional and potential future therapeutic interventions are addressed in Table 6.⁹⁰⁻¹⁰⁴

Corticosteroids

Empirical treatment of MA-ILD with oral corticosteroids dates to the initial reports of this condition.^{3,4} Although the de facto standard of care (historically and currently) for MA-ILD, corticosteroids have little prospective evidence supporting their use. In

Table 5—Lung Biopsy Results of Patients With Myositis-Associated Interstitial Lung Disease

Study/Year	NSIP ^a	UIP	COP	DAD	LIP	Unclassified
Fujisawa et al ⁹⁰ /2005, N = 10	7	3	0	0	0	0
Cottin et al ² /2003, N = 17	11	2	2	0	1	1
Tansey et al ⁸¹ /2004, N = 13	7	1	5	0	0	0
Shi et al ⁷⁷ /2008, N = 26	14	1	4	5	2	0
Fathi et al ¹³ /2004, N = 11	4	5	2	0	0	0
Won Huh et al ¹⁶ /2007, N = 9	4	4	0	1	0	0
Totals: N = 86	47	16	13	6	3	1

Where results were listed as minor pattern vs major pattern, only major patterns are reported. COP = cryptogenic organizing pneumonia; DAD = diffuse alveolar damage; LIP = lymphocytic interstitial pneumonia; NSIP = nonspecific interstitial pneumonia; UIP = usual interstitial pneumonia.

^aIn studies where results were reported as cellular vs fibrotic NSIP, results were combined into the NSIP category.

these articles and other smaller case series,¹⁰⁵ roughly 50% of patients with PM/DM initially responded to corticosteroid therapy alone. Existing literature derived from small case series of patients analyzed retrospectively for relatively short periods of time without a standard dosing schedule or consistent definition of response show that the effect of corticosteroids in MA-ILD was variable.^{47,106-108} Later studies have confirmed these mixed results.¹⁰⁹ Corticosteroids remain the standard of care, making future placebo-controlled prospective studies difficult. This lack of evidence should be recognized when treating patients in the clinical setting.

Azathioprine

Through its prevention of lymphocyte clonal expansion and the resultant effects on both cellular and humoral immunity, azathioprine has proved useful in treating a number of autoimmune conditions. In our clinical experience and according to the literature, azathioprine is the most common clinically used corticosteroid-sparing agent in the treatment of MA-ILD.¹¹⁰ Only one case report of azathioprine as a successful adjunctive maintenance therapy for the control of MA-ILD could be found.¹¹¹ No prospective trials or large case series exist.

Methotrexate

Methotrexate (MTX) is an inhibitor of folic acid metabolism as well as purine metabolism and T-cell activation.⁹⁶ Its successful use in treating the arthritis and myositis of PM/DM as an adjunctive agent when steroids have failed^{112,113} is well established. No trials of MTX specifically for MA-ILD exist. Despite the absence of pulmonary-specific evidence and due to its relatively low side-effect profile, MTX has become accepted in the treatment of MA-ILD. Particular care must be taken in treating MA-ILD with MTX given the agent's known association with idiosyncratic drug-related hypersensitivity pneumonitis.¹¹⁴ Using

literature from rheumatoid arthritis cohorts, it can be estimated to affect approximately 0.5% of those who take the drug,¹¹⁵ with another review further classifying the risk as one event per 35.4 patient-years of therapy.¹¹⁶ In the rheumatoid arthritis population, it has been suggested that pneumonitis is more common in patients who are diabetic, have hypoalbuminemia, or are >60 years of age, or, notably, in those in whom preexisting lung disease was noted.¹¹⁷ When this occurs, often early in the course of therapy,¹¹⁶ it can be difficult to distinguish symptoms as being related to the drug (using the major and minor criteria developed by Searles and McKendry)¹¹⁸ or a manifestation of the MA-ILD itself without a lung biopsy to obtain histopathology. Both the drug toxicity and a worsening of the ILD can present with interstitial infiltrates, increased dyspnea or cough, and a decline in pulmonary function, including a drop in the DLCO. Given this diagnostic dilemma, stopping the drug and switching immunomodulatory agents is prudent should pulmonary symptoms, PFT results, or CT scan findings worsen after starting this agent.

Cyclophosphamide

Cyclophosphamide (CYC), commonly used in rapidly progressive MA-ILD, is believed to exert its immunosuppressive actions through a variety of effects on T cells resulting in abolished immunologic memory.¹¹⁹ Because of its side-effect profile as an alkylating agent, its use is commonly restricted to refractory, treatment-resistant MA-ILD. It can be administered orally or IV (monthly IV pulse), most commonly with corticosteroids. Several case studies demonstrate its potential efficacy in treating MA-ILD.¹²⁰⁻¹²³ Only one study showed improvement as an adjunct to corticosteroids when CYC was administered orally.¹¹¹ One larger case series of CYC in pulse-dose fashion (300-800 mg/m² approximately every 5 days for 4 weeks) in combination with corticosteroids in 17 refractory patients¹²⁴ noted significant

Table 6—Less Conventional/Potential Future Therapeutic Approaches

Agent	Class	Level of Evidence/Demonstration of Benefit	Potential Concerns
Cyclosporin A (CsA)	Calcineurin inhibitor	Several case reports, ⁹⁰⁻⁹³ one retrospective trial, ⁸⁰ one prospective trial ⁹⁴	Nephrotoxicity, hepatotoxicity, infection
Tacrolimus (FK-506)	Calcineurin inhibitor	One case report, ⁹⁵ several retrospective reviews ^{94,96-98}	Nephrotoxicity, weakness, infection, induction of neoplasm
Mycophenolate mofetil (MMF)	Inhibitor of purine synthesis	Two small retrospective reviews ^{99,100}	Bone marrow suppression, infection
Leflunomide	DMARD	Single case report ¹⁰¹	Hepatotoxicity, bone marrow suppression
IV immunoglobulin (IVIg)	Pooled IgG immunoglobulins	Single case report, ¹⁰² single retrospective trial ¹⁰³	Aseptic meningitis, nephrotoxicity, anaphylaxis
Autologous stem cell transplantation	N/A	Single case report ¹⁰⁴	Extremely invasive, high risk of infection

DMARD = disease-modifying antirheumatic drug; N/A = not applicable.

improvement in dyspnea, vital capacity, and HRCT scan findings (although two Jo-1-positive patients had ILD flares). Another prospective, randomized trial of CYC demonstrated efficacy over corticosteroids alone when used in combination with prednisolone and cyclosporine A.¹²⁵ In this trial, 10 patients with DM and acute/subacute interstitial pneumonitis were initially treated with the combination therapy. When compared with historical controls treated with corticosteroids alone, the study group had a lower, although significant, mortality (50% vs 75%) over 3 months.

CONCLUSION

Since the original reviews describing myositis-associated interstitial lung disease in the mid-1970s, much has changed in the way we view and approach this condition. As case series and cohort studies grow in number, multiple disciplines are contributing to advances in the science of this disease. With this growing body of literature, we are poised to make larger advances in the coming years. Although its effect on morbidity and mortality of those affected, as well as its cost to the health system, have become clearer, much remains to be done in terms of understanding the cause of MA-ILD. The discoveries of antisynthetase autoantibodies and HLA subtype associations provide encouragement that a more accurate classification and predictive system may be on the horizon.

To date, as has been the case for > 35 years, the mainstay of treatment of MA-ILD is corticosteroids. New therapies, including the use of targeted immune modulators as well as the more experimental methods described in this review, require further prospective, large-scale study, specifically in patients with myositis demonstrating ILD, but offer a promise of less toxic, more tailored therapy.

In order to address this relatively rare condition, multicenter, multinational, collaborative efforts spanning the numerous disciplines involved in the treatment of patients with MA-ILD are required. The development of large, open-access patient databases will facilitate understanding of this disease and help drive progress in the accurate diagnosis and treatment of MA-ILD.

ACKNOWLEDGMENTS

Financial/nonfinancial disclosures: The authors have reported to *CHEST* that no potential conflicts of interest exist with any companies/organizations whose products or services may be discussed in this article.

REFERENCES

- Ahlström G, Gunnarsson LG, Leissner P, Sjødén PO. Epidemiology of neuromuscular diseases, including the postpolio sequelae, in a Swedish county. *Neuroepidemiology*. 1993;12(5):262-269.
- Cottin V, Thivolet-Béjui F, Reynaud-Gaubert M, et al; Groupe d'Etudes et de Recherche sur les Maladies "Orphelines" Pulmonaires. Interstitial lung disease in amyopathic dermatomyositis, dermatomyositis and polymyositis. *Eur Respir J*. 2003;22(2):245-250.
- Frazier AR, Miller RD. Interstitial pneumonitis in association with polymyositis and dermatomyositis. *Chest*. 1974;65(4):403-407.
- Schwarz MI, Matthay RA, Sahn SA, Stanford RE, Marmorstein BL, Scheinhorn DJ. Interstitial lung disease in polymyositis and dermatomyositis: analysis of six cases and review of the literature. *Medicine (Baltimore)*. 1976;55(1):89-104.
- American Thoracic Society; European Respiratory Society. American Thoracic Society/European Respiratory Society International Multidisciplinary Consensus Classification of the Idiopathic Interstitial Pneumonias. This joint statement of the American Thoracic Society (ATS), and the European Respiratory Society (ERS) was adopted by the ATS board of directors, June 2001 and by the ERS Executive Committee, June 2001. *Am J Respir Crit Care Med*. 2002;165(2):277-304.
- Coultas DB, Zumwalt RE, Black WC, Sobonya RE. The epidemiology of interstitial lung diseases. *Am J Respir Crit Care Med*. 1994;150(4):967-972.
- Golden A, Bronk TT. Diffuse interstitial fibrosis of lungs; a form of diffuse interstitial angiosis and reticulosis of the lungs. *AMA Arch Intern Med*. 1953;92(5):106-114.
- Liebow AA, Carrington CB. *The Interstitial Pneumonias*. 1st ed. New York, NY: Grune and Stratton; 1969.
- Bohan A, Peter JB. Polymyositis and dermatomyositis (second of two parts). *N Engl J Med*. 1975;292(8):403-407.
- Bohan A, Peter JB. Polymyositis and dermatomyositis (first of two parts). *N Engl J Med*. 1975;292(7):344-347.
- Tani K, Tomioka R, Sato K, et al. Comparison of clinical course of polymyositis and dermatomyositis: a follow-up study in Tokushima University Hospital. *J Med Invest*. 2007; 54(3-4):295-302.
- Ye S, Chen XX, Lu XY, et al. Adult clinically amyopathic dermatomyositis with rapid progressive interstitial lung disease: a retrospective cohort study. *Clin Rheumatol*. 2007; 26(10):1647-1654.
- Fathi M, Dastmalchi M, Rasmussen E, Lundberg IE, Tornling G. Interstitial lung disease, a common manifestation of newly diagnosed polymyositis and dermatomyositis. *Ann Rheum Dis*. 2004;63(3):297-301.
- Kang EH, Lee EB, Shin KC, et al. Interstitial lung disease in patients with polymyositis, dermatomyositis and amyopathic dermatomyositis. *Rheumatology (Oxford)*. 2005; 44(10):1282-1286.
- Chen YJ, Wu CY, Shen JL. Predicting factors of interstitial lung disease in dermatomyositis and polymyositis. *Acta Derm Venereol*. 2007;87(1):33-38.
- Won Huh J, Soon Kim D, Keun Lee C, et al. Two distinct clinical types of interstitial lung disease associated with polymyositis-dermatomyositis. *Respir Med*. 2007;101(8): 1761-1769.
- Chen IJ, Jan Wu YJ, Lin CW, et al. Interstitial lung disease in polymyositis and dermatomyositis. *Clin Rheumatol*. 2009;28(6):639-646.
- Marie I, Hachulla E, Chérin P, et al. Interstitial lung disease in polymyositis and dermatomyositis. *Arthritis Rheum*. 2002;47(6):614-622.
- Selva-O'Callaghan A, Labrador-Horrillo M, Muñoz-Gall X, et al. Polymyositis/dermatomyositis-associated lung disease: analysis of a series of 81 patients. *Lupus*. 2005;14(7):534-542.
- Nicholson AG, Colby TV, du Bois RM, Hansell DM, Wells AU. The prognostic significance of the histologic pattern of

- interstitial pneumonia in patients presenting with the clinical entity of cryptogenic fibrosing alveolitis. *Am J Respir Crit Care Med.* 2000;162(6):2213-2217.
21. Porkodi R, Shanmuganandan K, Parthiban M, Madhavan R, Rajendran P. Clinical spectrum of inflammatory myositis in South India—a ten year study. *J Assoc Physicians India.* 2002;50:1255-1258.
 22. Brown KK. Rheumatoid lung disease. *Proc Am Thorac Soc.* 2007;4(5):443-448.
 23. Sakamoto N, Mukae H, Fujii T, et al. Nonspecific interstitial pneumonia with poor prognosis associated with amyopathic dermatomyositis. *Intern Med.* 2004;43(9):838-842.
 24. Christensen ML, Pachman LM, Schneiderman R, Patel DC, Friedman JM. Prevalence of Coxsackie B virus antibodies in patients with juvenile dermatomyositis. *Arthritis Rheum.* 1986;29(11):1365-1370.
 25. Dalakas MC, Pezeshkpour GH, Gravell M, Sever JL. Polymyositis associated with AIDS retrovirus. *JAMA.* 1986;256(17):2381-2383.
 26. Morgan OS, Rodgers-Johnson P, Mora C, Char G. HTLV-1 and polymyositis in Jamaica. *Lancet.* 1989;2(8673):1184-1187.
 27. Travers RL, Hughes GR, Cambridge G, Sewell JR. Coxsackie B neutralisation titres in polymyositis/dermatomyositis. *Lancet.* 1977;1(8024):1268.
 28. Pearson CM. Editorial: Myopathy with viral-like structures. *N Engl J Med.* 1975;292(12):641.
 29. Mikol J, Felten-Papaiconomou A, Ferchal F, et al. Inclusion-body myositis: clinicopathological studies and isolation of an adenovirus type 2 from muscle biopsy specimen. *Ann Neurol.* 1982;11(6):576-581.
 30. Nishino H, Engel AG, Rima BK. Inclusion body myositis: the mumps virus hypothesis. *Ann Neurol.* 1989;25(3):260-264.
 31. Rosenberg N. Experimental models of inflammatory myopathies. *Baillieres Clin Neurol.* 1993;2(3):693-715.
 32. Nishikai M, Miyairi M, Kosaka S. Dermatomyositis following infection with hepatitis C virus. *J Rheumatol.* 1994;21(8):1584-1585.
 33. Buskila D, Shnaider A, Neumann L, et al. Musculoskeletal manifestations and autoantibody profile in 90 hepatitis C virus infected Israeli patients. *Semin Arthritis Rheum.* 1998;28(2):107-113.
 34. Agha B, Rasheed M, Kenyon L, Jimenez SA. Hepatitis C virus infection, inflammatory myopathy, and pulmonary fibrosis: are they related? *J Clin Rheumatol.* 2002;8(1):44-49.
 35. Ueno Y, Kondo K, Kidokoro N, Kobashi R, Kanaji K, Matsumura T. Hepatitis C infection and polymyositis. *Lancet.* 1995;346(8970):319-320.
 36. Weidensaul D, Imam T, Holyst MM, King PD, McMurray RW. Polymyositis, pulmonary fibrosis, and hepatitis C. *Arthritis Rheum.* 1995;38(3):437-439.
 37. Boumpas DT, Chrousos GP, Wilder RL, Cupps TR, Balow JE. Glucocorticoid therapy for immune-mediated diseases: basic and clinical correlates. *Ann Intern Med.* 1993;119(12):1198-1208.
 38. Kaşifoğlu T, Korkmaz C, Ozkan R. Cytomegalovirus-induced interstitial pneumonitis in a patient with dermatomyositis. *Clin Rheumatol.* 2006;25(5):731-733.
 39. Magro CM, Crowson AN, Dawood M, Nuovo GJ. Parvoviral infection of endothelial cells and its possible role in vasculitis and autoimmune diseases. *J Rheumatol.* 2002;29(6):1227-1235.
 40. Magro CM, Wusirika R, Frambach GE, Nuovo GJ, Ferri C, Ross P Jr. Autoimmune-like pulmonary disease in association with parvovirus B19: a clinical, morphologic, and molecular study of 12 cases. *Appl Immunohistochem Mol Morphol.* 2006;14(2):208-216.
 41. Magro CM, Allen J, Pope-Harman A, et al. The role of microvascular injury in the evolution of idiopathic pulmonary fibrosis. *Am J Clin Pathol.* 2003;119(4):556-567.
 42. Cherin P, Herson S, Crevon MC, et al. Mechanisms of lysis by activated cytotoxic cells expressing perforin and granzyme-B genes and the protein TIA-1 in muscle biopsies of myositis. *J Rheumatol.* 1996;23(7):1135-1142.
 43. Benveniste O, Chérin P, Maisonobe T, et al. Severe perturbations of the blood T cell repertoire in polymyositis, but not dermatomyositis patients. *J Immunol.* 2001;167(6):3521-3529.
 44. Chino Y, Murata H, Goto D, et al. T cell receptor BV gene repertoire of lymphocytes in bronchoalveolar lavage fluid of polymyositis/dermatomyositis patients with interstitial pneumonitis. *Int J Mol Med.* 2006;17(1):101-109.
 45. Berman JS, Beer DJ, Theodore AC, Kornfeld H, Bernardo J, Center DM. Lymphocyte recruitment to the lung. *Am Rev Respir Dis.* 1990;142(1):238-257.
 46. Salmeron G, Greenberg SD, Lidsky MD. Polymyositis and diffuse interstitial lung disease. A review of the pulmonary histopathologic findings. *Arch Intern Med.* 1981;141(8):1005-1010.
 47. Tazelaar HD, Viggiano RW, Pickersgill J, Colby TV. Interstitial lung disease in polymyositis and dermatomyositis. Clinical features and prognosis as correlated with histologic findings. *Am Rev Respir Dis.* 1990;141(3):727-733.
 48. Yamadori I, Fujita J, Kajitani H, et al. Lymphocyte subsets in lung tissues of interstitial pneumonia associated with untreated polymyositis/dermatomyositis. *Rheumatol Int.* 2001;21(3):89-93.
 49. Kurasawa K, Nawata Y, Takabayashi K, et al. Activation of pulmonary T cells in corticosteroid-resistant and -sensitive interstitial pneumonitis in dermatomyositis/polymyositis. *Clin Exp Immunol.* 2002;129(3):541-548.
 50. Arnett FC, Hirsch TJ, Bias WB, Nishikai M, Reichlin M. The Jo-1 antibody system in myositis: relationships to clinical features and HLA. *J Rheumatol.* 1981;8(6):925-930.
 51. Love LA, Leff RL, Fraser DD, et al. A new approach to the classification of idiopathic inflammatory myopathy: myositis-specific autoantibodies define useful homogeneous patient groups. *Medicine (Baltimore).* 1991;70(6):360-374.
 52. Furuya T, Hakoda M, Tsuchiya N, et al. Immunogenetic features in 120 Japanese patients with idiopathic inflammatory myopathy. *J Rheumatol.* 2004;31(9):1768-1774.
 53. Chinoy H, Salway F, Fertig N, et al; UK Adult Onset Myositis Immunogenetic Collaboration (AOMIC). In adult onset myositis, the presence of interstitial lung disease and myositis specific/associated antibodies are governed by HLA class II haplotype, rather than by myositis subtype. *Arthritis Res Ther.* 2006;8(1):R13.
 54. Vázquez-Abad D, Rothfield NF. Sensitivity and specificity of anti-Jo-1 antibodies in autoimmune diseases with myositis. *Arthritis Rheum.* 1996;39(2):292-296.
 55. Yoshida S, Akizuki M, Mimori T, Yamagata H, Inada S, Homma M. The precipitating antibody to an acidic nuclear protein antigen, the Jo-1, in connective tissue diseases. A marker for a subset of polymyositis with interstitial pulmonary fibrosis. *Arthritis Rheum.* 1983;26(5):604-611.
 56. Imbert-Masseau A, Hamidou M, Agard C, Grolleau JY, Chérin P. Antisynthetase syndrome. *Joint Bone Spine.* 2003;70(3):161-168.
 57. Wasicek CA, Reichlin M, Montes M, Raghu G. Polymyositis and interstitial lung disease in a patient with anti-Jo1 prototype. *Am J Med.* 1984;76(3):538-544.
 58. Marguerie C, Bunn CC, Beynon HL, et al. Polymyositis, pulmonary fibrosis and autoantibodies to aminoacyl-tRNA synthetase enzymes. *Q J Med.* 1990;77(282):1019-1038.

59. Ghirardello A, Zampieri S, Tarricone E, et al. Clinical implications of autoantibody screening in patients with autoimmune myositis. *Autoimmunity*. 2006;39(3):217-221.
60. Grau JM, Miró O, Pedrol E, et al. Interstitial lung disease related to dermatomyositis. Comparative study with patients without lung involvement. *J Rheumatol*. 1996;23(11):1921-1926.
61. Richards TJ, Eggebeen A, Gibson K, et al. Characterization and peripheral blood biomarker assessment of anti-Jo-1 antibody-positive interstitial lung disease. *Arthritis Rheum*. 2009;60(7):2183-2192.
62. Matsushita T, Hasegawa M, Fujimoto M, et al. Clinical evaluation of anti-aminoacyl tRNA synthetase antibodies in Japanese patients with dermatomyositis. *J Rheumatol*. 2007;34(5):1012-1018.
63. Lega JC, Cottin V, Fabien N, Thivolet-Béjui F, Cordier JF. Interstitial lung disease associated with anti-PM/Scl or anti-aminoacyl-tRNA synthetase autoantibodies: a similar condition? *J Rheumatol*. 2010;37(5):1000-1009.
64. Katsumata Y, Ridgway WM, Oriss T, et al. Species-specific immune responses generated by histidyl-tRNA synthetase immunization are associated with muscle and lung inflammation. *J Autoimmun*. 2007;29(2-3):174-186.
65. Miller FW, Waite KA, Biswas T, Plotz PH. The role of an autoantigen, histidyl-tRNA synthetase, in the induction and maintenance of autoimmunity. *Proc Natl Acad Sci U S A*. 1990;87(24):9933-9937.
66. Stone KB, Oddis CV, Fertig N, et al. Anti-Jo-1 antibody levels correlate with disease activity in idiopathic inflammatory myopathy. *Arthritis Rheum*. 2007;56(9):3125-3131.
67. Howard OM, Dong HF, Yang D, et al. Histidyl-tRNA synthetase and asparaginyl-tRNA synthetase, autoantigens in myositis, activate chemokine receptors on T lymphocytes and immature dendritic cells. *J Exp Med*. 2002;196(6):781-791.
68. Levine SM, Rosen A, Casciola-Rosen LA. Anti-aminoacyl tRNA synthetase immune responses: insights into the pathogenesis of the idiopathic inflammatory myopathies. *Curr Opin Rheumatol*. 2003;15(6):708-713.
69. Wakasugi K, Schimmel P. Highly differentiated motifs responsible for two cytokine activities of a split human tRNA synthetase. *J Biol Chem*. 1999;274(33):23155-23159.
70. Wakasugi K, Schimmel P. Two distinct cytokines released from a human aminoacyl-tRNA synthetase. *Science*. 1999;284(5411):147-151.
71. Ascherman DP. The role of Jo-1 in the immunopathogenesis of polymyositis: current hypotheses. *Curr Rheumatol Rep*. 2003;5(6):425-430.
72. Targoff IN. Autoantibodies and their significance in myositis. *Curr Rheumatol Rep*. 2008;10(4):333-340.
73. Miller MR, Crapo R, Hankinson J, et al; ATS/ERS Task Force. General considerations for lung function testing. *Eur Respir J*. 2005;26(1):153-161.
74. Miller MR, Hankinson J, Brusasco V, et al; ATS/ERS Task Force. Standardisation of spirometry. *Eur Respir J*. 2005;26(2):319-338.
75. Bonnefoy O, Ferretti G, Calaque O, et al. Serial chest CT findings in interstitial lung disease associated with polymyositis-dermatomyositis. *Eur J Radiol*. 2004;49(3):235-244.
76. Hayashi S, Tanaka M, Kobayashi H, et al. High-resolution computed tomography characterization of interstitial lung diseases in polymyositis/dermatomyositis. *J Rheumatol*. 2008;35(2):260-269.
77. Shi JH, Xu WB, Liu HR, et al. Clinico-pathological manifestations in interstitial lung diseases associated with polymyositis-dermatomyositis [in Chinese]. *Zhonghua Jie He He Hu Xi Za Zhi*. 2008;31(4):250-254.
78. Ikezoe J, Johkoh T, Kohno N, Takeuchi N, Ichikado K, Nakamura H. High-resolution CT findings of lung disease in patients with polymyositis and dermatomyositis. *J Thorac Imaging*. 1996;11(4):250-259.
79. Mino M, Noma S, Taguchi Y, Tomii K, Kohri Y, Oida K. Pulmonary involvement in polymyositis and dermatomyositis: sequential evaluation with CT. *AJR Am J Roentgenol*. 1997;169(1):83-87.
80. Mochimaru H, Kawamoto M, Enomoto T, et al. Transbronchial biopsy is clinically useful in classifying patients with interstitial pneumonia associated with polymyositis and dermatomyositis. *Respirology*. 2008;13(6):863-870.
81. Fujisawa T, Suda T, Nakamura Y, et al. Differences in clinical features and prognosis of interstitial lung diseases between polymyositis and dermatomyositis. *J Rheumatol*. 2005;32(1):58-64.
82. Tansey D, Wells AU, Colby TV, et al. Variations in histological patterns of interstitial pneumonia between connective tissue disorders and their relationship to prognosis. *Histopathology*. 2004;44(6):585-596.
83. Wang PZ, Guan JL, Han XH. The predictive factors and unfavourable prognostic factors of interstitial lung disease in patients with polymyositis/dermatomyositis [in Chinese]. *Zhonghua Jie He He Hu Xi Za Zhi*. 2008;31(6):417-420.
84. Bandoh S, Fujita J, Ohtsuki Y, et al. Sequential changes of KL-6 in sera of patients with interstitial pneumonia associated with polymyositis/dermatomyositis. *Ann Rheum Dis*. 2000;59(4):257-262.
85. Kubo M, Ihn H, Yamane K, et al. Serum KL-6 in adult patients with polymyositis and dermatomyositis. *Rheumatology (Oxford)*. 2000;39(6):632-636.
86. Kumánovics G, Minier T, Radics J, Pálkás L, Berki T, Cziráj L. Comprehensive investigation of novel serum markers of pulmonary fibrosis associated with systemic sclerosis and dermatomyositis. *Clin Exp Rheumatol*. 2008;26(3):414-420.
87. Krystufkova O, Vallerskog T, Helmers SB, et al. Increased serum levels of B-cell activating factor (BAFF) in subsets of patients with idiopathic inflammatory myopathies. *Ann Rheum Dis*. 2009;68(6):836-843.
88. Wong RC, Brown S, Clarke BE, Klingberg S, Zimmerman PV. Transient elevation of the tumor markers CA 15-3 and CASA as markers of interstitial lung disease rather than underlying malignancy in dermatomyositis sine myositis. *J Clin Rheumatol*. 2002;8(4):204-207.
89. Okada M, Suzuki K, Nakanishi T, Nakashima M. Serum levels of KL-6 are positively correlated with those of CA15-3 in patients with interstitial pneumonia associated with collagen diseases. *Respirology*. 2006;11(4):509-510.
90. Jankowska M, Butto B, Debska-Slizie A, Rutkowski B. Beneficial effect of treatment with cyclosporin A in a case of refractory antisynthetase syndrome. *Rheumatol Int*. 2007;27(8):775-780.
91. Sakamoto S, Homma S, Kawabat M, Kono T, Motoi N, Yoshimur K. A case of corticosteroid-resistant nonspecific interstitial pneumonia associated with dermatomyositis successfully treated with cyclosporin A [in Japanese]. *Nihon Kokyuki Gakkai Zasshi*. 2005;43(3):171-178.
92. Shimojima Y, Ishii W, Kato T, et al. Intractable skin necrosis and interstitial pneumonia in amyopathic dermatomyositis, successfully treated with cyclosporin A. *Intern Med*. 2003;42(12):1253-1258.
93. Ando S, Kobayashi S, Yamanaka K, Takasaki Y, Hashimoto H. Successful combination therapy of cyclosporine and steroids in two cases with interstitial pneumonitis associated with polymyositis [in Japanese]. *Ryumachi*. 1995;35(1):95-99.

94. Takada K, Nagasaka K, Miyasaka N. Polymyositis/dermatomyositis and interstitial lung disease: a new therapeutic approach with T-cell-specific immunosuppressants. *Autoimmunity*. 2005;38(5):383-392.
95. Guglielmi S, Merz TM, Gugger M, Suter C, Nicod LP. Acute respiratory distress syndrome secondary to antisynthetase syndrome is reversible with tacrolimus. *Eur Respir J*. 2008;31(1):213-217.
96. Johnston A, Gudjonsson JE, Sigmundsdottir H, Ludviksson BR, Valdimarsson H. The anti-inflammatory action of methotrexate is not mediated by lymphocyte apoptosis, but by the suppression of activation and adhesion molecules. *Clin Immunol*. 2005;114(2):154-163.
97. Oddis CV, Sciruba FC, Elmagd KA, Starzl TE. Tacrolimus in refractory polymyositis with interstitial lung disease. *Lancet*. 1999;353(9166):1762-1763.
98. Wilkes MR, Sereika SM, Fertig N, Lucas MR, Oddis CV. Treatment of antisynthetase-associated interstitial lung disease with tacrolimus. *Arthritis Rheum*. 2005;52(8):2439-2446.
99. Swigris JJ, Olson AL, Fischer A, et al. Mycophenolate mofetil is safe, well tolerated, and preserves lung function in patients with connective tissue disease-related interstitial lung disease. *Chest*. 2006;130(1):30-36.
100. Saketkoo LA, Espinoza LR. Experience of mycophenolate mofetil in 10 patients with autoimmune-related interstitial lung disease demonstrates promising effects. *Am J Med Sci*. 2009;337(5):329-335.
101. Lange U, Piegsa M, Müller-Ladner U, Strunk J. Anti-Jo-1 antibody positive polymyositis—successful therapy with leflunomide. *Autoimmunity*. 2006;39(3):261-264.
102. Murota H, Muroi E, Yamaoka T, Hamasaki Y, Katayama I. Successful treatment with regimen of intravenous gamma globulin and cyclophosphamide for dermatomyositis accompanied by interstitial pneumonia, opportunistic infection and steroid psychosis. *Allergol Int*. 2006;55(2):199-202.
103. Suzuki Y, Hayakawa H, Miwa S, et al. Intravenous immunoglobulin therapy for refractory interstitial lung disease associated with polymyositis/dermatomyositis. *Lung*. 2009;187(3):201-206.
104. Oryoji K, Himeji D, Nagafuji K, et al. Successful treatment of rapidly progressive interstitial pneumonia with autologous peripheral blood stem cell transplantation in a patient with dermatomyositis. *Clin Rheumatol*. 2005;24(6):637-640.
105. Songcharoen S, Raju SF, Pennebaker JB. Interstitial lung disease in polymyositis and dermatomyositis. *J Rheumatol*. 1980;7(3):353-360.
106. Takizawa H, Shiga J, Moroi Y, Miyachi S, Nishiwaki M, Miyamoto T. Interstitial lung disease in dermatomyositis: clinicopathological study. *J Rheumatol*. 1987;14(1):102-107.
107. Arsuru EL, Greenberg AS. Adverse impact of interstitial pulmonary fibrosis on prognosis in polymyositis and dermatomyositis. *Semin Arthritis Rheum*. 1988;18(1):29-37.
108. Saeki T, Suzuki E, Watanabe T, et al. Prognosis of interstitial pneumonitis (IP) in polymyositis (PM)/dermatomyositis (DM) [in Japanese]. *Ryumachi*. 1994;34(1):16-21.
109. Oddis CV. Current approach to the treatment of polymyositis and dermatomyositis. *Curr Opin Rheumatol*. 2000;12(6):492-497.
110. Douglas WW, Tazelaar HD, Hartman TE, et al. Polymyositis-dermatomyositis-associated interstitial lung disease. *Am J Respir Crit Care Med*. 2001;164(7):1182-1185.
111. Mok CC, To CH, Szeto ML. Successful treatment of dermatomyositis-related rapidly progressive interstitial pneumonitis with sequential oral cyclophosphamide and azathioprine. *Scand J Rheumatol*. 2003;32(3):181-183.
112. Malaviya AN, Many A, Schwartz RS. Treatment of dermatomyositis with methotrexate. *Lancet*. 1968;2(7566):485-488.
113. Sokoloff MC, Goldberg LS, Pearson CM. Treatment of corticosteroid-resistant polymyositis with methotrexate. *Lancet*. 1971;1(7688):14-16.
114. Lateef O, Shakoor N, Balk RA. Methotrexate pulmonary toxicity. *Expert Opin Drug Saf*. 2005;4(4):723-730.
115. Hoekstra M, van Ede AE, Haagsma CJ, et al. Factors associated with toxicity, final dose, and efficacy of methotrexate in patients with rheumatoid arthritis. *Ann Rheum Dis*. 2003;62(5):423-426.
116. Carroll GJ, Thomas R, Phatouros CC, et al. Incidence, prevalence and possible risk factors for pneumonitis in patients with rheumatoid arthritis receiving methotrexate. *J Rheumatol*. 1994;21(1):51-54.
117. Alarcón GS, Kremer JM, Macaluso M, et al; Methotrexate-Lung Study Group. Risk factors for methotrexate-induced lung injury in patients with rheumatoid arthritis. A multicenter, case-control study. *Ann Intern Med*. 1997;127(5):356-364.
118. Searles G, McKendry RJ. Methotrexate pneumonitis in rheumatoid arthritis: potential risk factors. Four case reports and a review of the literature. *J Rheumatol*. 1987;14(6):1164-1171.
119. Turk JL, Parker D, Cameron AE. The effect of cyclophosphamide on immunological control mechanisms. *Int J Tissue React*. 1984;6(3):205-211.
120. Kotani T, Makino S, Kawasaki Y, et al. A case of interstitial pneumonia associated with dermatomyositis effectively treated with cyclosporin-A and cyclophosphamide pulse [in Japanese]. *Nihon Rinsho Meneki Gakkai Kaishi*. 2005;28(3):148-153.
121. Shinohara T, Hidaka T, Matsuki Y, et al. Rapidly progressive interstitial lung disease associated with dermatomyositis responding to intravenous cyclophosphamide pulse therapy. *Intern Med*. 1997;36(7):519-523.
122. Tanaka F, Origuchi T, Migita K, et al. Successful combined therapy of cyclophosphamide and cyclosporine for acute exacerbated interstitial pneumonia associated with dermatomyositis. *Intern Med*. 2000;39(5):428-430.
123. Yoshida T, Koga H, Saitoh F, et al. Pulse intravenous cyclophosphamide treatment for steroid-resistant interstitial pneumonitis associated with polymyositis. *Intern Med*. 1999;38(9):733-738.
124. Yamasaki Y, Yamada H, Yamasaki M, et al. Intravenous cyclophosphamide therapy for progressive interstitial pneumonia in patients with polymyositis/dermatomyositis. *Rheumatology (Oxford)*. 2007;46(1):124-130.
125. Kameda H, Nagasawa H, Ogawa H, et al. Combination therapy with corticosteroids, cyclosporin A, and intravenous pulse cyclophosphamide for acute/subacute interstitial pneumonia in patients with dermatomyositis. *J Rheumatol*. 2005;32(9):1719-1726.