Ann Dermatol Vol. 22, No. 1, 2010 DOI: 10.5021/ad.2010.22.1.69

CASE REPORT

Eccrine Hidrocystoma in a Child: An Atypical Presentation

Jae-Hui Nam, M.D., Ga-Young Lee, M.D., Won-Serk Kim, M.D., Kea Jeung Kim, M.D.[1]

Department of Dermatology, Sungkyunkwan University School of Medicine, Kangbuk Samsung Hospital, Seoul,
[1]Masan Samsung Hospital, Masan, Korea

Eccrine hidrocystomas are small benign cystic lesions that normally affect only adult females. Eccrine hidrocystoma is characterized by tense vesicles that are predominately located on the face and particularly on the periorbital areas. Histologically, eccrine hidrocystoma consists of one or more partially collapsed unilocular cysts in the dermis, and these cysts are often situated adjacent to normal eccrine ducts. An 8-year-old boy presented with multiple skin-colored to bluish tiny papules on his nose. Histopathologically, the dilated partial cystic structures in the middermis were lined by one or two layers of flattened or cuboidal epithelial cells. We report here on an atypical presentation of multiple eccrine hidrocystomas that were localized on the nose of a child. **(Ann Dermatol 22(1) 69～72, 2010)**

-Keywords-
Child, Eccrine hidrocystoma, Nose

INTRODUCTION

Robinson[1] was the first to describe eccrine hidrocystoma (EH) in 1893. EHs characteristically appear as skin-colored to bluish vesiculopapular lesions, and most commonly on the periorbital area, and these lesions predominantly occur in middle-aged and elderly women[2,3]. EH is a benign small cystic lesion that usually enlarges during the summer and may disappear spontaneously in cooler weather[2]. To the best of our knowledge, EH in children has not previously been described in the medical literature and grouped EHs localized on the tip of the nose is a very rare and atypical presentation.

Received September 22, 2008, Revised June 26, 2009, Accepted for publication July 6, 2009

Reprint request to: Ga-Young Lee, M.D., Department of Dermatology, Kangbuk Samsung Hospital, Sungkyunkwan University School of Medicine, 108, Pyung-dong, Jongno-gu, Seoul 100-634, Korea. Tel: 82-2-2001-2233, Fax: 82-2-2001-2236, E-mail: gylee0716@hanmail.net

CASE REPORT

An 8-year-old boy presented with a 3-year history of multiple flesh-colored to bluish domed papules on the tip of the nose (Fig. 1). CO_2 laser treatment had been performed at a local clinic during the prior year, but the lesions had not completely resolved. Both his past medical and family histories were not remarkable. The papules became more prominent in hot environments.

The histopathology showed a dilated, partially cystic structure in the middermis (Fig. 2A). The cystic cavity was lined by one or two layers of cuboidal or flattened epithelial cells (Fig. 2B). No decapitation secretion was visualized. The immunohistochemical studies showed positivity for CEA, but negativity for S-100 and PAS (Fig. 3). The diagnosis of EH was established based on these

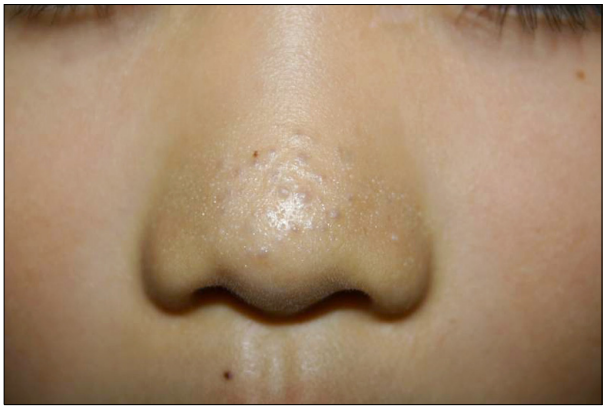

Fig. 1. The grouped skin-colored to bluish, dome-shaped papules on the nose.

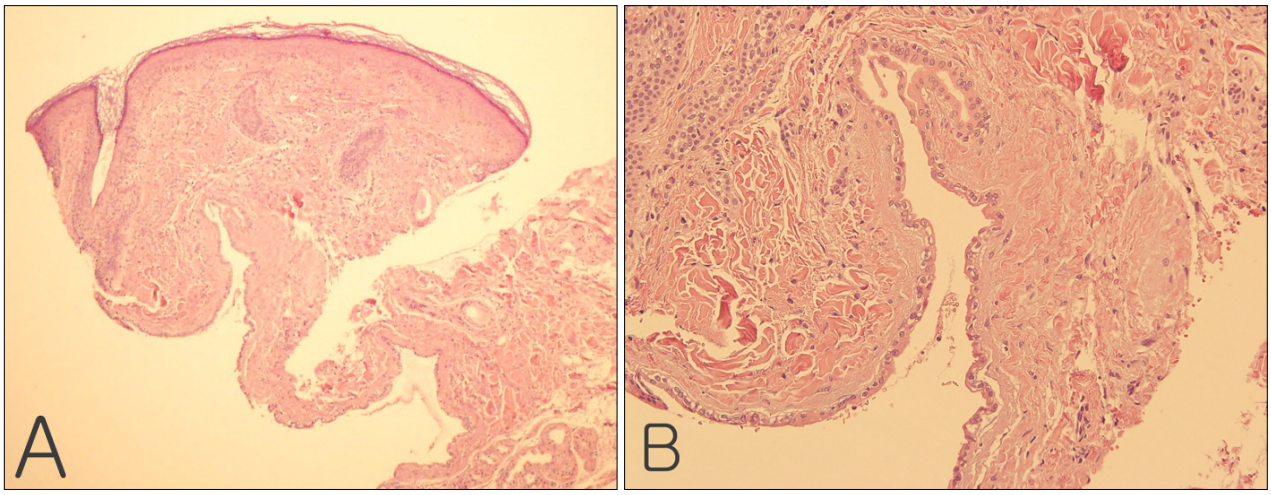

Fig. 2. (A) A dilated partial cystic structure in the middle dermis is shown (H&E, ×40), and (B) the cystic wall is lined by one or two layers of cuboidal or flattened epithelial cells without decapitation (H&E, ×200).

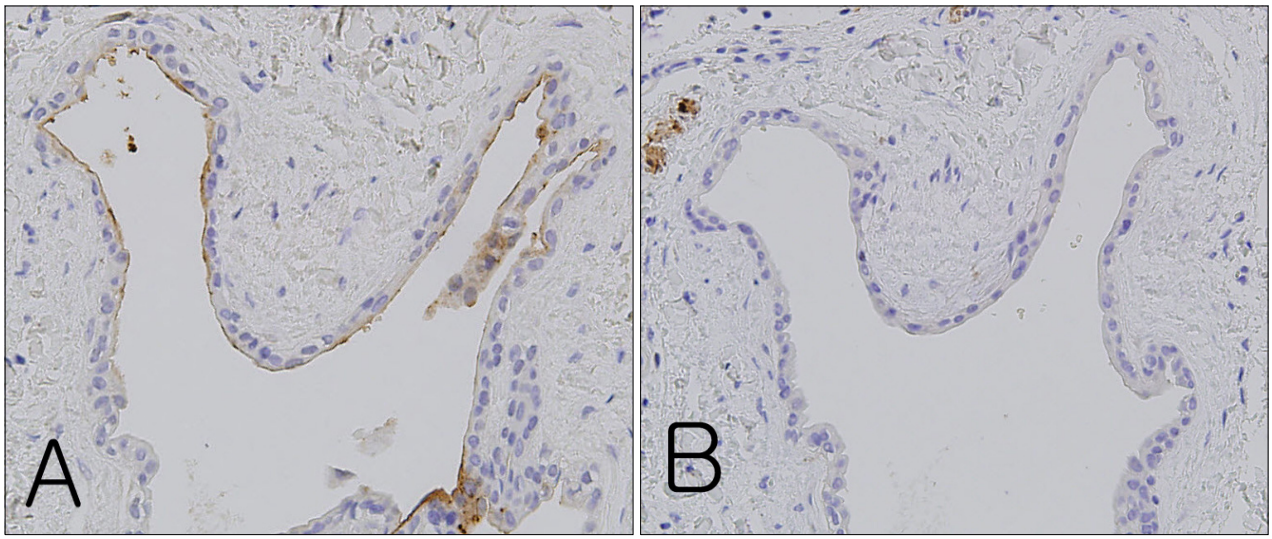

Fig. 3. (A) The epithelial cells showed positivity for CEA (CEA, ×200). (B) However, they did not stain for S-100 (S-100, ×200).

findings.

Therapy with topical 1% atropine sulfate two times daily was instituted. The skin lesions showed great improvement after a month of treatment. No recurrence has been noted during the 1 year follow-up period.

DISCUSSION

EH usually presents as a small, translucent, cystic nodule that is 1 to 3 mm in diameter and the nodule often has a bluish hue[3]. They are predominantly found on adult females, they occur as single or multiple lesions and they are mostly located on the periorbital and malar regions[2]. EH is prevalent in adults between the ages of 20 and 70 years[2,4]. There have been no reported cases of EH in childhood in the medical literature.

EH is currently classified into two types according to the number of lesions. The first type was described by Robinson[1] and this is known as the Robinson type. Most of his patients were women who worked in hot and humid environments. Their lesions were characterized as having multiple small papules[1]. Smith and Chernosky[5] subsequently described a group of patients whose lesions were primarily solitary. The individual lesions of the multiple type are similar to the solitary lesions of the Smith type, except they are smaller[6]. Tokura et al.[7] suggested solitary EH is derived from the secretory coil, and the multiple ones are derived from the duct. The

Robinson-type multiple EHs are much more common in Korea and the Smith-type solitary EHs are relatively rare[4].

The etiology of multiple EH remains unknown. A suggested cause for EH involves occlusion of the intradermal portion of the eccrine duct[8]. However, Murayama et al.[9] suggest that EH is a hamartoma-like disorder that becomes more pronounced as a result of retaining sweat. We thought that the latter hypothesis might explain the atypical, early presentation of our case.

EH must be differentiated from apocrine hidrocystomas. Apocrine hidrocystoma is usually larger and it does not become more prominent in hot environments or after exercise[10]. Apocrine hidrocystomas affect the same age groups as do EHs, and they rarely occur during childhood or adolescence[2]. Histopathologically, eccrine hidrocystoma, which is lined by ductal cells, differs from apocrine hidrocystoma by the absence of decapitation secretions, papillary projection into the lumen, PAS-positive granules and myoepithelial cells. EH is usually unilocular, whereas apocrine hidrocystomas are multilocular[2]. Histochemically, solitary EH stains positive for S-100 protein, whereas the Robinson type EH and apocrine hidrocystomas do not[2]. However, it may be difficult to differentiate EH from apocrine hidrocystomas even with conducting immunohistochemical study[2,11].

There is an interesting previously reported case of steatocystoma multiplex localized on the nose of a child[12]. But the differentiation with EH was not difficult because steatocystoma usually has a yellowish color and it is histopathologically characterized by a folded cyst wall that consists of squamous epithelium, flattened sebaceous lobules within or close to the wall and a positive reaction of the lining cells for PAS. Clinically, other cystic lesions such as epidermal inclusion cyst, comedone and mucous cyst could be considered in the differential diagnosis, but all these lesions differ from EH histopathologically[13-15].

Although a solitary EH can be easily treated with surgical excision, eliminating multiple hidrocystomas is difficult because of their number and cosmetic location. The therapeutic options can be divided into medical and surgical modalities. Multiple lesions have been treated with topical scopolamine, topical atropine and botulinum toxin type A[16,17]. Simple needle puncture has not been shown to produce lasting effects[18]. Using a 585-nm pulsed dye laser has resulted in good outcomes when treating multiple EHs[19]. Most importantly, avoiding hot temperatures or humid conditions will help prevent worsening of symptoms in patients. We chose topical atropine as a treatment method because of the patient's young age, and the number of skin lesions, and the site of presentation was cosmetically and functionally important.

The age at presentation and the clinical features of our case do not mimic the classic presentation of EH, be it the Robinson-type or the Smith-type. Due to the histologic findings, the lesion's aggravation during hot weather and the good response to atropine sulfate, we were able to make the diagnosis of EHs with an atypical presentation.

REFERENCES

1. Robinson AR. Hidrocystoma. J Cutan Genitourin Dis 1893; 11:293-303.
2. Alfadley A, Al Aboud K, Tulba A, Mourad MM. Multiple eccrine hidrocystomas of the face. Int J Dermatol 2001; 40:125-129.
3. Klein W, Chan E, Seykora J. Tumors of the epidermal appendages. In: Elder DE, Elenitsas R, Johnson BL Jr, Murphy GF, editors. Lever's histopathology of the skin. 9th ed. Philadelphia: Lippincott Williams & Wilkins, 2005:867-926.
4. Cho YK, Kim MY, Park HJ, Park CJ, Lee JY, Kim HO, et al. Clinicopathologic study of 15 cases of eccrine hidrocystoma. Korean J Dermatol 2004;42:704-709.
5. Smith JD, Chernosky ME. Hidrocystomas. Arch Dermatol 1973;108:676-679.
6. Kim YD, Lee EJ, Song MH, Suhr KB, Lee JH, Park JK. Multiple eccrine hidrocystomas associated with Graves' disease. Int J Dermatol 2002;41:295-297.
7. Tokura Y, Takigawa M, Inoue K, Matsumoto K, Yamada M. S-100 protein-positive cells in hidrocystomas. J Cutan Pathol 1986;13:102-110.
8. Matsushita S, Higashi Y, Uchimiya H, Ohtani K, Kanekura T. Case of giant eccrine hidrocystoma of the scalp. J Dermatol 2007;34:586-587.
9. Murayama N, Tsuboi R, Unno K, Ogawa H. Multiple eccrine hidrocystomas. Br J Dermatol 1994;131:585-586.
10. Choi JE, Ko NY, Son SW. Lack of effect of the pulsed-dye laser in the treatment of multiple eccrine hidrocystomas: a report of two cases. Dermatol Surg 2007;33:1513-1515.
11. de Viragh PA, Szeimies RM, Eckert F. Apocrine cystadenoma, apocrine hidrocystoma, and eccrine hidrocystoma: three distinct tumors defined by expression of keratins and human milk fat globulin 1. J Cutan Pathol 1997;24:249-255.
12. Park YM, Cho SH, Kang H. Congenital linear steatocystoma multiplex of the nose. Pediatr Dermatol 2000;17:136-138.
13. Heenan PJ. Tumors of fibrous tissue involving the skin. In: Elder DE, Elenitsas R, Johnson BL Jr, Murphy GF, editors. Lever's histopathology of the skin. 9th ed. Philadelphia: Lippincott Williams & Wilkins, 2005:979-1013.
14. Ioffreda MD. Inflammatory diseases of hair follicles, sweat glands, and cartilage. In: Elder DE, Elenitsas R, Johnson BL Jr, Murphy GF, editors. Lever's histopathology of the skin. 9th ed. Philadelphia: Lippincott Williams & Wilkins, 2005: 469-512.
15. Kirkham N. Tumors and cysts of the epidermis. In: Elder DE, Elenitsas R, Johnson BL Jr, Murphy GF, editors. Lever's histopathology of the skin. 9th ed. Philadelphia: Lippincott Williams & Wilkins, 2005:805-866.

16. Masri-Fridling GD, Elgart ML. Eccrine hidrocystomas. J Am Acad Dermatol 1992;26:780-782.
17. Blugerman G, Schavelzon D, D'Angelo S. Multiple eccrine hidrocystomas: a new therapeutic option with botulinum toxin. Dermatol Surg 2003;29:557-559.
18. Armstrong DK, Walsh MY, Corbett JR. Multiple facial eccrine hidrocystomas: effective topical therapy with atropine. Br J Dermatol 1998;139:558-559.
19. Tanzi E, Alster TS. Pulsed dye laser treatment of multiple eccrine hidrocystomas: a novel approach. Dermatol Surg 2001;27:898-900.