

Case Report

Aspergilloma formation in cavitary sarcoidosis*, **

Formação de uma aspergilloma em sarcoidose com cavitação

Chandramani Panjabi, Sandeep Sahay, Ashok Shah

Abstract

Pulmonary cavitation is rather uncommon in patients with sarcoidosis, and aspergilloma is even more uncommon in such cases. Here, we present the case of a 63-year-old female patient with cavitary lung disease who had been under treatment for TB for 9 months. A diagnosis of pulmonary sarcoidosis was established based on the fiberoptic bronchoscopy finding of noncaseating granuloma. Treatment with corticosteroids led to a dramatic improvement in symptoms. While under treatment for sarcoidosis, the patient developed an aspergilloma. She presented immediate skin test reactivity to *Aspergillus fumigatus*, as well as positivity for *A. fumigatus* serum precipitins. This is the first reported case of aspergilloma formation in a patient with cavitary sarcoidosis in India.

Keywords: Sarcoidosis, pulmonary; Aspergillosis; Medical records.

Resumo

A cavitação pulmonar é rara em pacientes com sarcoidose, e o aspergiloma é ainda mais raro nestes casos. Apresentamos o caso de uma paciente de 63 anos com doença pulmonar cavitária em tratamento para a TB por 9 meses. Estabeleceu-se o diagnóstico de sarcoidose pulmonar com base nos achados de granuloma não-caseoso na fibrobroncoscopia. Houve grande melhora dos sintomas com o tratamento com corticosteroides. A paciente desenvolveu um aspergiloma durante o tratamento para a sarcoidose. Houve reação imediata ao teste cutâneo para *Aspergillus fumigatus*, assim como resultado positivo para precipitinas de *A. fumigatus* no soro. Este é o primeiro caso relatado de formação de aspergiloma em um paciente com sarcoidose com cavitação na Índia.

Descritores: Sarcoidose pulmonar; Aspergilose; Registros médicos.

Introduction

Sarcoidosis, often mistaken for TB in India, is just beginning to emerge from obscurity.^(1,2) Over the last half-century, approximately 1,100 cases have been reported.⁽³⁻⁵⁾ The collective data suggest that the presentation of sarcoidosis in Indians is akin to that of the chronic fibrosing relapsing form of the disease seen in African-Americans. However, in Indians, the disease occurs far less frequently, is less severe and is still regarded as uncommon.⁽²⁾

The fibrotic lung disease observed in Indian patients with sarcoidosis is similar to that found in pulmonary TB. However, pulmonary cavitation is uncommon in patients with sarcoidosis and has not been reported in any studies conducted in India.⁽³⁻⁵⁾ Here, we report the case of a patient with cavitary pulmonary sarcoidosis who had

previously been treated for TB and who, while under treatment for sarcoidosis, developed an aspergilloma. To our knowledge, this is the first reported case of aspergilloma formation in a patient with cavitary sarcoidosis in India.

Case report

A 63-year-old female patient with diabetes and hypertension was referred to the Vallabhbhai Patel Chest Institute at the University of Delhi, in the city of Delhi, India, for evaluation of progressive pulmonary disease. Her clinical course over the preceding 18 months had been characterized by paroxysmal attacks of dry cough, gradually increasing breathlessness and intermittent low-grade fever. This had been accompanied

* Study carried out in the Department of Respiratory Medicine, Vallabhbhai Patel Chest Institute, University of Delhi, Delhi, India. Correspondence to: Ashok Shah, Department of Respiratory Medicine, Vallabhbhai Patel Chest Institute, University of Delhi, P.O. Box: 2101, Delhi, India, 110007.

Fax 91 11 27667420. E-mail: ashokshah99@yahoo.com

Financial support: None.

Submitted: 5 August 2008. Accepted, after review: 1 September 2008.

**A versão completa em português deste artigo está disponível em www.jornaldepneumologia.com.br

by malaise, anorexia and weight loss. Although sputum smears had consistently tested negative for acid-fast bacilli, the symptom profile and radiological findings had prompted her treating physician to initiate antituberculosis therapy, which was then continued for 9 months but provided no symptom relief.

Physical examination revealed no acute distress. There was no clubbing or cyanosis. Diaphragmatic excursions were normal. On auscultation of the chest, bilateral basal end-inspiratory crackles were audible. In the evaluation of other systems, including that related to an ophthalmologic referral, no abnormalities were detected.

On reviewing a chest X-ray taken 9 months prior to referral, when antituberculosis therapy had been initiated, we observed diffuse, patchy opacities in both lungs, together with bilateral hilar adenopathy (Figure 1). An acinar pattern with areas of confluence was apparent in the right middle and lower fields. A CT scan of the chest, also obtained 9 months prior to referral, showed a well-defined cavitary lesion, not visible on the chest X-ray, in the anterior segment of the right upper lobe (Figure 2). In addition, we observed ground-glass opacities, accompanied by perihilar areas of consolidation and bronchovascular bundles with a beaded appearance. Bilateral hilar lymphadenopathy and asymmetric mediastinal lymphadenopathy, without caseation or rim enhancement, were also present. The cavitation seen on the CT scan probably prompted the initiation of the antituberculosis therapy. The laboratory evaluation at that time showed hemoglobin of 13.3 g/dL, with a total leukocyte count of 6,700 cells/mm³ and a normal differential leukocyte count. Although routine urine testing revealed traces of glucose, blood glucose values were within the normal range, since the patient was under treatment with oral hypoglycemic agents. The results of liver and kidney function tests, as well as the lipid profile and electrocardiographic findings, were also within normal limits. Sputum smear microscopy and culture for *Mycobacterium tuberculosis* and other aerobic organisms continued to yield negative results. Tuberculin testing with a 5-TU dose of PPD resulted in no induration.

A chest X-ray taken after referral showed persistent mediastinal lymphadenopathy with pronounced parenchymal shadows. On

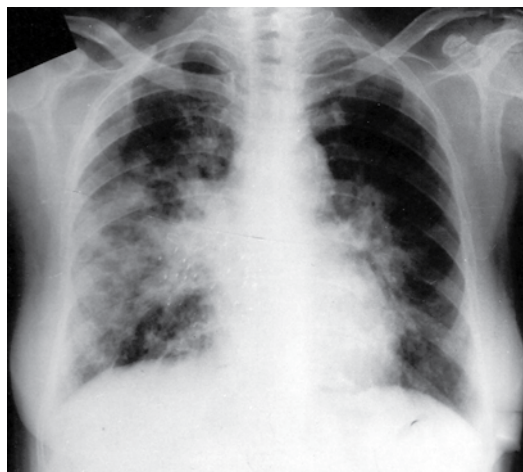


Figure 1 - Anteroposterior chest X-ray, taken 9 months prior to referral, showing diffuse, patchy opacities in both lungs, together with bilateral hilar enlargement. An acinar pattern with areas of confluence can be seen in the right middle and lower fields.

pulmonary function testing, the FVC was 1.45 L (63% of predicted), FEV₁ was 1.05 L (56% of predicted), and the FEV₁/FVC ratio was 0.72. The total lung capacity was 2.67 L (66% of predicted), and DLCO was 12.53 mL • min⁻¹ • mmHg⁻¹ (68% of predicted), although diffusion per unit of alveolar volume was normal. This was indicative of moderately severe restrictive ventilatory defect, with reductions in total lung capacity and DLCO. Fiberoptic bronchoscopy revealed multiple

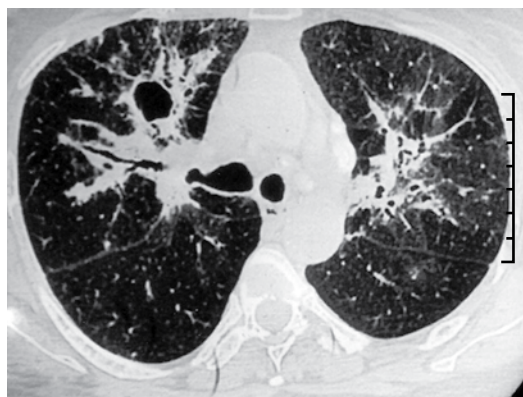


Figure 2 - CT scan of the chest, obtained 9 months prior to referral, showing a well-defined cavitary lesion in the anterior segment of the right upper lobe. Bronchovascular bundles with a beaded appearance can also be seen.

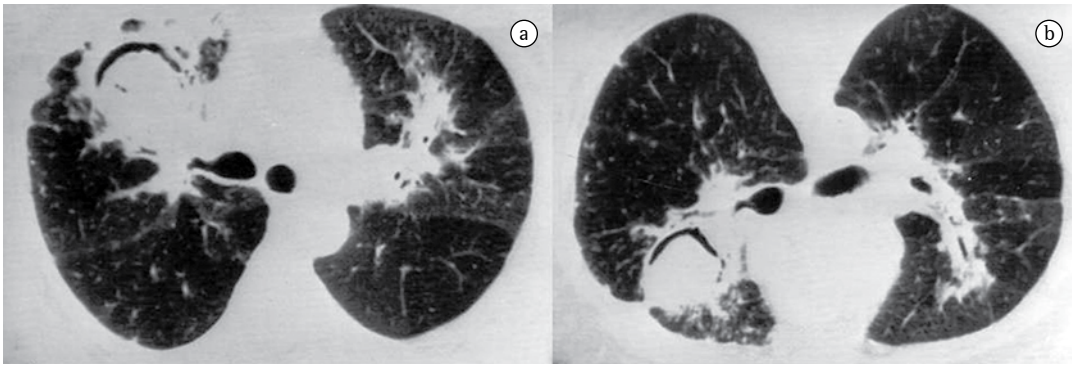


Figure 3 – CT scans of the chest obtained after referral: (a) well-defined cavitary lesion in the anterior segment of the right upper lobe; and (b) positional change of the mass within the cavity in the prone position.

granulomatous lesions throughout the bronchial mucosa of the bronchial tree. Multiple endobronchial biopsies, taken from the granulomatous lesions, revealed noncaseating granuloma consisting of epithelioid cells and multinucleated giant cells. Serum angiotensin-converting enzyme, calcium, rheumatoid factor, and 24-h urinary calcium were within normal limits; antinuclear antibody was not detected.

A diagnosis of pulmonary sarcoidosis was made, and the antituberculosis therapy was stopped forthwith. The patient was started on oral prednisolone at 30 mg/day. After 2 weeks, the dose was reduced to 30 mg on alternate days and then gradually tapered over 6 months at a rate of 5 mg/month. There was remarkable clinical improvement. However, during the eighth month of therapy, the patient presented with hemoptysis. A chest X-ray showed a cavitary lesion containing a mass, together with an air crescent sign. The lateral decubitus view demonstrated positional change, suggesting an aspergilloma. A new CT scan of the chest confirmed the presence of an intracavitary mass in the right upper lobe (Figure 3a), and positional change was also observed on prone position (Figure 3b). However, the mediastinal nodes had regressed significantly. Intradermal testing with *Aspergillus* antigens demonstrated immediate reactivity to *Aspergillus fumigatus*. Serum precipitins to *A. fumigatus* were also detected. Hemoptysis subsided with symptomatic treatment. At this writing, the patient was asymptomatic, although still under treatment.

Discussion

Cavitation is not commonly encountered in sarcoidosis.^(6,7) In a review of ten studies involving a total of 1,254 patients, it was found that cavitary lesions were reported in only 3 (1.3%) of the 235 patients for whom such information was available.⁽⁸⁾ However, in another study involving 200 patients, cavities, defined as “abnormal air spaces with thick walls”, were reported in 12.8% of “black” patients and 10.8% of “white” patients.⁽⁹⁾ However, in two large studies involving patients with pulmonary sarcoidosis in India,^(3,5) the discussion of the radiological aspects of the disease included no mention of cavitation. Cavitary lesions, if present, are generally seen in the irreversible, fibrotic stage of the disease. In rare cases, true primary pulmonary sarcoid cavitation can develop in the absence of fibrocystic disease, and characteristic noncaseating granulomas can be seen in the walls of the cavities.⁽¹⁰⁾

The combination of aspergilloma and sarcoidosis was first described by Fougner & Gjone in 1958.⁽¹¹⁾ Aspergillomas complicating sarcoidosis have since been shown to occur in 0.7-5.0% of patients with sarcoidosis.^(7,9,12,13) In the previously cited study involving 200 patients with pulmonary sarcoidosis,⁽⁹⁾ cavities were present in 25 (12.5%) of the patients, and aspergillomas were found in 10 of those patients. To our knowledge, aspergilloma formation in a patient with cavitary sarcoidosis has never before been reported in India.

In a prospective study of 100 patients with sarcoidosis,⁽¹⁴⁾ aspergillomas were seen in 10,

all of whom presented serum precipitins to *A. fumigatus*. In 6 of those 10 patients, precipitin bands were absent when sarcoidosis was diagnosed but were detected during follow-up. However, aspergilloma formation has been reported in up to 7% patients without serum precipitins to *A. fumigatus*.⁽¹⁵⁾ Testing for serum precipitins to *A. fumigatus* might be useful in screening to determine which patients are at risk for developing an aspergilloma.

In the only review in which TB patients and sarcoidosis patients (14 cases each) were compared in terms of aspergilloma formation,⁽¹⁶⁾ the authors found that the clinical presentation was similar in the two groups. However, the radiographic profile was strikingly different: localized disease was seen in 12 of the 14 patients with TB; and diffuse disease was seen in 13 of the 14 with sarcoidosis. This difference led to distinct management strategies. Among the patients with persistent hemoptysis, only those with TB underwent surgical resection of the aspergilloma. The authors speculated that the decision not to perform surgery in the patients with sarcoidosis might have been influenced by a number of factors, including diffuse lung involvement, pleural fibrosis and poor general condition of the patient.

In areas of high TB prevalence, the presence of an aspergilloma in a patient with cavitary disease is often associated with inactive pulmonary TB. The case presented here serves to alert physicians to the fact that aspergillomas can also occur in patients with cavitary sarcoidosis.

References

1. Pant K, Chawla R, Shah A, Gaur SN, Bhagat R, Bhatia A, et al. Fibrebronchoscopy in pulmonary sarcoidosis--an

- Indian experience. Indian J Chest Dis Allied Sci. 1990;32(4):199-203.
2. Shah A. Is sarcoidosis still uncommon in India? Indian J Chest Dis Allied Sci. 2003;45(2):93-5.
3. Gupta SK, Gupta S. Sarcoidosis in India: a review of 125 biopsy-proven cases from eastern India. Sarcoidosis. 1990;7(1):43-9.
4. Shah A, Bhagat R, Agarwal AK. Sarcoidosis: A review of 73 Indian patients. Chest (India) 2001;2(Suppl):S52.
5. Sharma SK, Mohan A. Sarcoidosis: global scenario & Indian perspective. Indian J Med Res. 2002;116:221-47.
6. Deepak D, Shah A. Thoracic sarcoidosis: The spectrum of roentgenologic appearances. Indian J Radiol Imag. 2001;11(4):191-8.
7. Hours S, Nunes H, Kambouchner M, Uzunhan Y, Brauner MW, Valeyre D, et al. Pulmonary cavitary sarcoidosis: clinico-radiologic characteristics and natural history of a rare form of sarcoidosis. Medicine (Baltimore). 2008;87(3):142-51.
8. Mayock RL, Bertrand P, Morrison CE, Scott JH. Manifestations of sarcoidosis. Analysis of 145 patients, with a review of nine series selected from the literature. Am J Med. 1963;35:67-89.
9. Freundlich IM, Libshitz HI, Glassman LM, Israel HL. Sarcoidosis. Typical and atypical thoracic manifestations and complications. Clin Radiol. 1970;21(4):376-83.
10. Rockoff SD, Rohatgi PK. Unusual manifestations of thoracic sarcoidosis. AJR Am J Roentgenol. 1985;144(3):513-28.
11. Fougner K, Gjone E. Pulmonary aspergilloma in a case of Boeck's sarcoidosis [Article in Norwegian]. Nord Med. 1958;59(8):303-5.
12. Kirks DR, McCormick VD, Greenspan RH. Pulmonary sarcoidosis. Roentgenologic analysis of 150 patients. Am J Roentgenol Radium Ther Nucl Med. 1973;117(4):777-86.
13. Kaplan J, Johns CJ. Mycetomas in pulmonary sarcoidosis: non-surgical management. Johns Hopkins Med J. 1979;145(4):157-61.
14. Wollschlager C, Khan F. Aspergillomas complicating sarcoidosis. A prospective study in 100 patients. Chest. 1984;86(4):585-8.
15. Coleman RM, Kaufman L. Use of the immunodiffusion test in the serodiagnosis of aspergillosis. Appl Microbiol. 1972;23(2):301-8.
16. Tomlinson JR, Sahn SA. Aspergilloma in sarcoid and tuberculosis. Chest. 1987;92(3):505-8.

About the authors

Chandramani Panjabi

Senior Resident. Department of Respiratory Medicine, Vallabhbhai Patel Chest Institute, University of Delhi, Delhi, India.

Sandeep Sahay

Junior Resident. Department of Respiratory Medicine, Vallabhbhai Patel Chest Institute, University of Delhi, Delhi, India.

Ashok Shah

Professor of Respiratory Medicine. Vallabhbhai Patel Chest Institute, University of Delhi, Delhi, India.