

A High Association with Cone Dystrophy in Fundus Albipunctatus Caused by Mutations of the *RDH5* Gene

Makoto Nakamura, Yoshihiro Hotta, Atsubiro Tanikawa,
Hiroko Terasaki, and Yozo Miyake

PURPOSE. To analyze the *RDH5* gene in patients with fundus albipunctatus with and without cone dystrophy and to determine whether the disease is stationary or progressive and whether the cone dystrophy is a part of fundus albipunctatus or a separate disease.

METHODS. Fourteen patients from 12 separate Japanese families with fundus albipunctatus were examined. Six of the patients from 6 families also had a cone dystrophy. Genomic DNA was extracted from leukocytes of the peripheral blood, and exons 2, 3, 4, and 5 of the *RDH5* gene were amplified by polymerase chain reaction and were directly sequenced. A complete ophthalmic examination was performed including best-corrected visual acuity, slit-lamp examination, indirect ophthalmoscopy, fundus photography, and electroretinography.

RESULTS. In all the patients, either a homozygous mutation or compound heterozygous mutations in the *RDH5* gene were identified. The identified mutations were nucleotide position (nt) 103 G to A (Gly35Ser), nt 319 G to C (Gly107Arg), nt 394 G to A (Val132Met), nt 719 G insertion (frame shift), nt 839 G to A (Arg280His), nt 841 T to C (Tyr281His), and nt 928 C to GAAG (Leu310 to GluVal). All these mutations except the Arg280His were new. The nt 928 C to GAAG mutation was detected in patients with and without cone dystrophy. Cone dystrophy was most frequently seen in patients over 40 years old.

CONCLUSIONS. Fundus albipunctatus either with or without cone dystrophy is caused by mutations of the *RDH5* gene. Cone dystrophy is frequently observed in elderly patients with fundus albipunctatus. The conclusion was reached that the mutations of the *RDH5* gene caused a progressive cone dystrophy as well as night blindness. (*Invest Ophthalmol Vis Sci.* 2000;41:3925-3932)

Fundus albipunctatus is a type of congenital stationary night blindness with an autosomal recessive inheritance pattern.¹ The fundus of these patients has a characteristic appearance: a large number of discrete, small round or elliptical yellow-white lesions at the level of the retinal pigment epithelium (RPE).¹⁻³ Usually the lesions are observed at a maximum density in the midperiphery and not in the center of the macula.^{1,4} The number and the shape of the lesions change with age.³ Patients with fundus albipunctatus complain of night blindness from early childhood, and the clinical course has been considered to be stationary with normal visual acuity, visual field, and color perception.⁴ In addition, electrophysiological examination revealed normal scotopic and photopic electroretinographic (ERG) responses, although a long dark-adaptation period is necessary to obtain the maximum scotopic responses.^{1,4}

Similar yellow-white lesions are observed in patients with retinitis punctata albescens, a kind of retinitis pigmentosa (RP).⁵ In such cases, there is a progressive decline of visual functions with decreasing visual acuity and the development of visual field defects. Both scotopic and photopic ERG responses are reduced and do not recover even after a long period of dark adaptation. The final clinical feature of this disease is the appearance of typical RP lesions, with disappearance of the white punctata. A mutation was found in the human *peripherin/RDS* gene in a family of this disease,⁶ and recent study revealed recessive mutations in the *RLBP1* gene encoding cellular retinaldehyde-binding protein (CRALBP) causes a type of this disease.^{7,8}

It was recently reported that mutations of the 11-*cis* retinol dehydrogenase (*RDH5*) gene, which is expressed predominantly in RPE, cause fundus albipunctatus.⁹ These authors reported that a homozygous missense mutation, Gly238Trp (GGG to TGG), and compound heterozygous missense mutations, Gly238Trp (GGG to TGG) and Ser73Phe (TCC to TTC) of the *RDH5* gene, were detected in a 49-year-old patient and a 16-year-old patient, respectively. However, no mutation in this gene was found in 29 cases of retinitis punctata albescens, 71 cases of autosomal recessive RP, 73 cases of autosomal dominant RP, and 94 normal controls.⁷ Gonzalez-Fernandez et al.¹⁰ examined the *RDH5* gene of 2 patients with fundus albipunctatus and found a homozygous missense mutation, Gly238Trp (GGG to TGG) in a 26-year-old patient and compound heterozygous missense mutations, Arg280His (CGC to CAC) and Ala294Pro (GCC to CCC) in a 28-year-old patient.

From the Department of Ophthalmology, Nagoya University School of Medicine, Nagoya, Japan.

Supported by Grants for Research Committee on Chorioretinal Degenerations from The Ministry of Health and Welfare of Japan and Grants-in-Aid for Scientific Research from the Ministry of Education, Science, Sports and Culture, Japan: Grant B11470363 (YM), Grant C05807166 (YH), and Grant C12671703 (MN).

Submitted for publication April 17, 2000; revised June 26, 2000; accepted July 19, 2000.

Commercial relationships policy: N.

Corresponding author: Makoto Nakamura, Department of Ophthalmology, Nagoya University School of Medicine, 65 Tsuruma-cho, Showa-ku, Nagoya 466-8560, Japan. makonaka@med.nagoya-u.ac.jp

Approximately 10 years ago, we reported five cases of fundus albipunctatus associated with cone dystrophy whose full-field photopic ERGs were severely reduced.¹¹ At that time, we stated that we could not determine with the available data whether these cases represented an advanced stage of fundus albipunctatus or a distinct disease entity. We also could not state whether these cases represented a chance combination of fundus albipunctatus and cone dystrophy in the same patient.¹¹ After that, we reported that between 1979 and 1993, 27 patients with fundus albipunctatus visited our clinic; 7 (26%) of them were affected by Bull's eye or similar lesions.¹² The subjects without macular lesions ranged in age from 5 to 51 years (mean, 18 years), whereas the 7 with macular lesion ranged in age from 36 to 54 years (mean, 44 years), and we suggested the possible occurrence of macular lesions during the natural course of fundus albipunctatus.¹² However, we could not confirm genetically at that time. To settle this uncertainty, we have reexamined 3 of these patients as well as 3 additional male patients from 6 separate Japanese families with fundus albipunctatus and cone dystrophy as well as 8 patients from 6 separate Japanese families with fundus albipunctatus in whom cone dystrophy was not seen. We shall show that a homozygous mutation or compound heterozygous mutations in the *RDH5* gene were detected in all the patients. Because there was a progressive decline of the visual functions in some aged patients, we conclude that these mutations of the *RDH5* gene lead to a progressive cone dystrophy as well as the congenital night blindness.

METHODS

This study involving human subjects followed the tenets of the Declaration of Helsinki. Fourteen patients with fundus albipunctatus from 12 Japanese families were analyzed. They lived geographically separately in the Chubu Area, the middle of Japan, and to the best of our knowledge, the families were not related. All individuals examined have been followed in the Departments of Ophthalmology, Nagoya University, Japan. A full ocular history was taken with special attention to any progressive changes in the symptoms and characteristics of the disease. The ophthalmic examination included best-corrected visual acuity, refraction, slit-lamp examination, indirect ophthalmoscopy, fundus photography, and ERGs.

Informed consent was obtained from the subjects after an explanation of this study. Genomic DNA was extracted from leukocytes of peripheral blood from each patient. Exons 2, 3, 4, and 5 of the *RDH5* gene were amplified by polymerase chain reaction (PCR) using the DNA Thermal Cycler 9700 (Perkin Elmer Applied Biosystems, Foster City, CA). Primers were purchased from Life Technologies Oriental, Inc. (Tokyo, Japan) following the sequences published previously by Yamamoto et al.⁹ Genomic DNA (200 ng) was PCR amplified in 50 μ l reactions containing Amplitaq Gold *Taq* DNA polymerase (Perkin Elmer Applied Biosystems). The PCR conditions were as follows: 5 minutes at 94°C, 35 cycles at 94°C for 30 seconds, followed by 30 seconds at 50° to 60°C (exon 2a, 3b, 5a, 50°C; exon 3a, 4, 5b, 54°C; exon 2b, 2c, 60°C), and 45 seconds at 72°C with a final extension step at 72°C for 7 minutes. The PCR products were purified using High Pure PCR Purification Kit (Boehringer Mannheim GmbH, Mannheim, Germany) and then directly sequenced using a DNA sequencing kit (Dye Termina-

tor Cycle Sequencing Ready Reaction Kit; Perkin Elmer Applied Biosystems, Foster City, CA), and an automated DNA sequencer (Model 373; Applied Biosystems, Foster City, CA). Primers for the sequence reaction were the same as those for the PCR reaction. All samples were sequenced on both sense and antisense strands. To search for polymorphisms, the exons of the *RDH5* gene from 90 alleles (24 men and 21 women) from unrelated normal Japanese individuals were directly sequenced. In addition, all exons of *RDH5* gene from 10 patients with cone dystrophy who did not have fundus albipunctatus were also examined.

Conventional ERGs were elicited with Ganzfeld stimuli after 30 minutes of dark adaptation. The rod (scotopic) ERGs were recorded with a blue light at an intensity of 5.2×10^{-3} cd/m² per sec. The mixed rod:cone single flash ERGs were recorded with a white stimulus at an intensity of 44.2 cd/m² per sec. The cone ERG and the 30-Hz flicker ERG were elicited with a white stimulus at an intensity of 4 and 0.9 cd/m² per sec, respectively.

RESULTS

In all the patients, either a homozygous mutation or compound heterozygous mutations were detected in the *RDH5* gene (Table 1). In 4 of the 6 patients with both fundus albipunctatus and cone dystrophy (cases 1 through 6), a novel homozygous base change mutation, nt 928 C to GAAG, was found (case 1 to 4; Fig. 1H). Compound heterozygous mutations of nt 928 C to GAAG (Fig. 1D) and nt 319 G to C (Gly107Arg; Fig. 1C) were found in case 5, and compound heterozygous mutations of nt 719 G insertion (frame shift; Fig. 1E) and nt 841 T to C (Tyr281His; Fig. 1G) were found in case 6. In the patients without cone dystrophy (cases 7 through 14), mutations of nt 839 G to A (Arg280His; Fig. 1F), nt 103 G to A (Gly35Ser; Figs. 1A, 1B), nt 394 G to A (Val132Met; Fig. 1D), and 928 C to GAAG (Figs. 1H, 1I) were found. These mutations were confirmed using both sense and antisense primers. All these mutations except the Arg280His in case 14 were novel. The sequences of the carriers showed a heterozygous pattern including both the wild-type and mutant alleles. For example, a son of case 2, a daughter of case 5, the parents of case 7, and the mother of cases 8 and 9 showed heterozygous nt 928 C to GAAG base change, and the mother of case 11 and the mother of cases 12 and 13 showed heterozygous nt 103 G to A (Gly35Ser) missense change. No base substitution was recognized in all 90 alleles from the normal individuals as well as in the 10 patients with cone dystrophy who did not have fundus albipunctatus.

The scotopic ERGs were significantly reduced after a short period of dark adaptation (30 minutes) in all the patients. They were also recorded after 2 to 3 hours of dark adaptation in some of the patients, showing improvements slightly or to normal levels. In the fundus albipunctatus patients with cone dystrophy, the photopic ERGs were also significantly reduced. In some young patients without cone dystrophy, the photopic ERGs were also reduced (see Fig. 3).

A major mutation, nt 928 C to GAAG base change, was identified in both elderly patients with cone dystrophy and in young patients who did not show the cone dystrophy. Among the seven patients over 40 years of age, six had a cone dystrophy with reduced photopic ERGs. In the other, a 53-year-old

TABLE 1. Clinical and Genetic Findings of Patients with Fundus Albipunctatus

Case	Age (y)	Sex	Visual Acuity		Bull's Eye	Mutation	VF
			OD	OS			
1	63	M	0.1	0.6	+	928 C to GAAG (Leu310 to GluVal)*	I4e paracentral scotoma and constriction to V4e (OD)
2	59	M	0.05	0.05	+	928 C to GAAG (Leu310 to GluVal)*	Big V4e central scotoma (OU)
3	58	M	1.2	1.2	+	928 C to GAAG (Leu310 to GluVal)*	I4e paracentral scotoma (OS)
4	48	M	0.03	0.03	+	928 C to GAAG (Leu310 to GluVal)*	10° V4e central scotoma (OU)
5	65	M	0.07	0.2	+	928 C to GAAG (Leu310 to GluVal)† 319 G to C (Gly107Arg)†	Central scotoma & constriction (OU)
6	74	M	0.02	0.06	+	719 G ins (frame shift)† 841 T to C (Tyr281His)†	10° III4e central scotoma (OU)
7	12	M	1.0	1.0	-	928 C to GAAG (Leu310 to GluVal)*	Full to V4e and I4e
8‡	18	F	1.0	1.0	-	928 C to GAAG (Leu310 to GluVal)*	Full to V4e and I4e
9‡	15	M	1.5	1.5	-	928 C to GAAG (Leu310 to GluVal)*	Full to V4e and I4e
10	18	F	1.0	1.0	-	928 C to GAAG (Leu310 to GluVal)† 839 G to A (Arg280His)†	Full to V4e and I4e
11	20	F	1.2	1.2	-	928 C to GAAG (Leu310 to GluVal)† 103 G to A (Gly35Ser)†	Full to V4e and I4e
12‡	22	M	1.0	1.0	-	103 G to A (Gly35Ser)*	Full to V4e and I4e
13‡	19	M	1.2	1.2	-	103 G to A (Gly35Ser)*	Full to V4e and I4e
14	53	F	1.2	1.2	-	394 G to A (Val132Met)† 839 G to A (Arg280His)†	Full to V4e and I4e

* Homozygous.
 † Compound heterozygous.
 ‡ Cases 8 and 9, Cases 12 and 13 are brothers, respectively.

patient who had compound heterozygous missense mutations, 394 G to A (Val132Met) and 839 G to A (Arg280His) (case 14), cone dystrophy was not observed; however, the photopic

ERGs were mildly reduced. Cone dystrophy was never seen in young patients with fundus albipunctatus associated with the *RDH5* mutation.

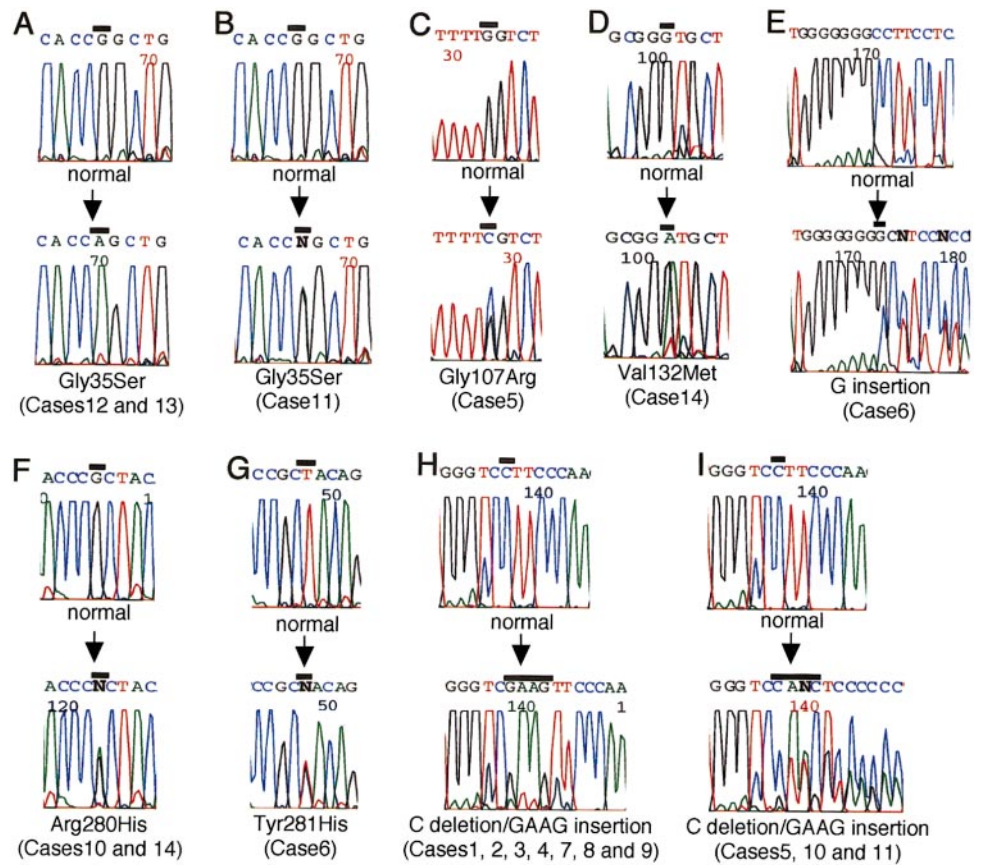


FIGURE 1. Nucleotide sequences of the *RDH5* gene using sense primers in the patients. Bars, the positions of the mutations. (A) Homozygous missense mutation of nt 103 G to A (Gly35Ser), case 12; (B) heterozygous mutation of nt 103 G to A (Gly35Ser), case 11; (C) heterozygous missense mutation of nt 319 G to C (Gly107Arg), case 5; (D) heterozygous missense mutation of nt 394 G to A (Val132Met), case 14; (E) heterozygous mutation of nt 719 G insertion (frame shift), case 6; (F) heterozygous missense mutation of nt 839 G to A (Arg280His), case 14; (G) heterozygous missense mutation of nt 841 T to C (Tyr281His), case 6; (H) homozygous base change mutation of nt 928 C to GAAG, case 1; (I) heterozygous base change mutation of nt 928 C to GAAG, case 5.

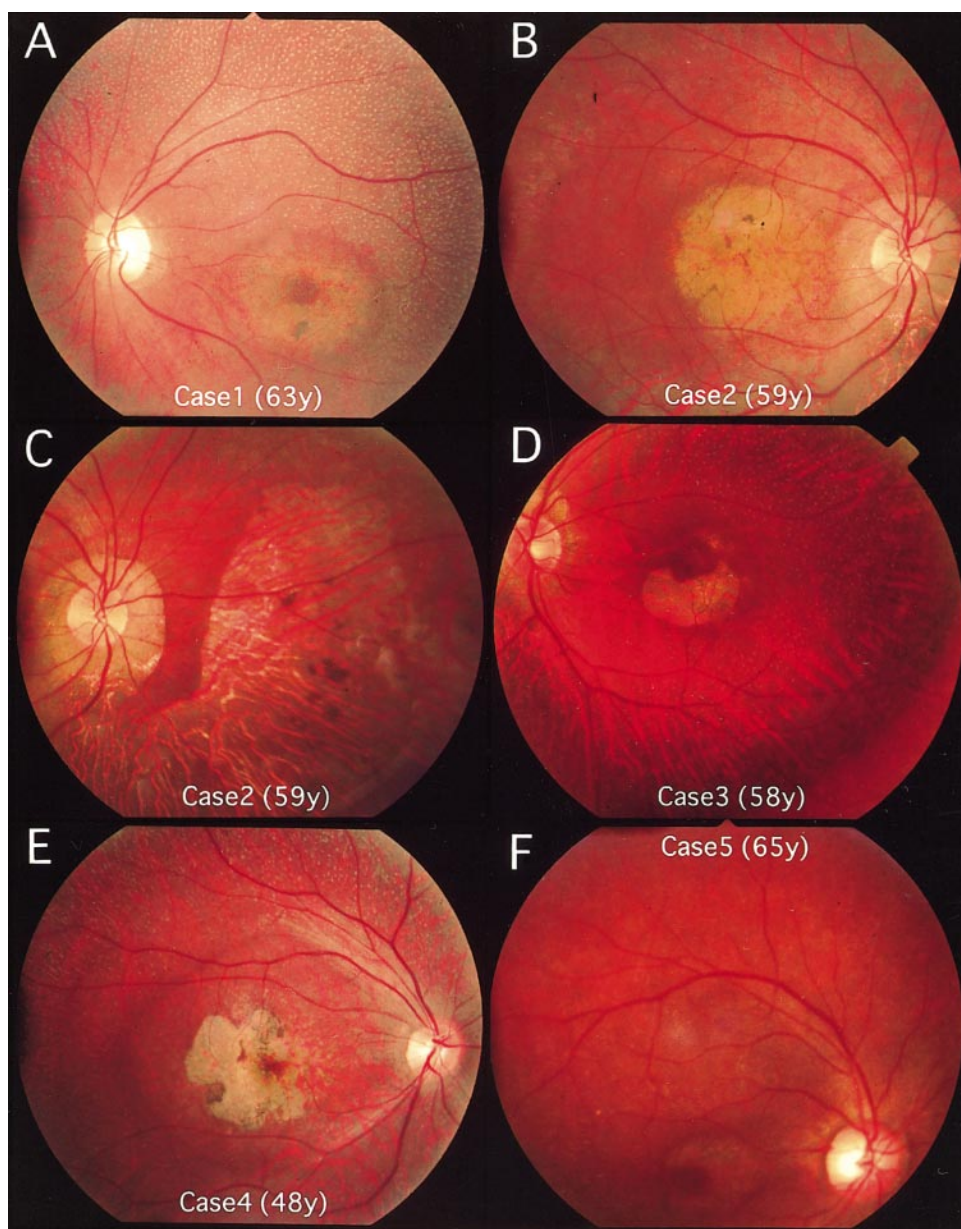


FIGURE 2. Fundus photographs of patients with mutations of *RDH5* gene. (A) Left eye, case 1: *white punctation* and *Bull's eye*; (B) right eye, case 2: distinct macular dystrophy and inconspicuous *white dots*; (C) right eye, case 2: local chorioretinopathy is seen in the nasal and inferior fundus; (D) left eye, case 3: *white punctation* and *Bull's eye*; (E) right eye, case 4: macular dystrophy and *white dots*; (F) right eye, case 5: *Bull's eye* and inconspicuous *white dots*; (G) right eye, case 5: chorioretinal atrophy was seen in the periphery; (H) left eye, case 6: tiny *white punctation* and typical *Bull's eye*; (I) right eye, case 7: numerous dull *white-yellow punctations* are clearly seen in the midperiphery; (J) left eye, case 9: numerous *white dots*; (K) right eye, case 11: distinct *white dots*; (L) left eye, case 14: many *small white dots*. The case number and the age (years) are indicated in each photograph.

CASE REPORTS

We shall describe several patients with both fundus albipunctatus and cone dystrophy. Because we have followed some of these patients for a long time, their findings are crucial to the understanding of the association of fundus albipunctatus and cone dystrophy.

Case 1 is a 63-year-old man who was described in detail 10 years earlier (1992; case 1 in Ref. 11). In 1999, the bull's eye maculopathy had enlarged in both fundus (Fig. 2A, compare with Fig. 1A of Ref. 11), and the visual acuity of the right eye was reduced from 0.6 to 0.1. The central scotomas were enlarged in both eyes as determined by Goldmann perimetry.

Case 2 is a 59-year-old man who was also described previously (1992; case 1 in Ref. 11). In 1999, the patient complained of a significant deterioration of his visual functions. The bull's eye appearance of the both fundus had enlarged (Fig. 2B, compare with Fig. 3A of Ref. 11), and his visual acuity

was reduced from 1.2 OD and 1.0 OS to 0.05 OU. The focal, symmetrical chorioretinal atrophy in the nasal and inferior fundus had enlarged (Fig. 2C). The white punctate lesions were reduced significantly in number and size in both eyes (Figs. 2B, 2C).

Case 3 is a 58-year-old man who was also described previously (1992; case 1 in Ref. 11). In 1981, when the patient was 40 years old, the fundus demonstrated a typical fundus albipunctatus, and his visual acuity was 1.2 in both eyes. Eight years later, in 1989, we recognized the macular changes as an early stage of bull's eye maculopathy. Localized chorioretinal atrophy was recognized in the both eyes. In 1999, the bull's eye maculopathy was more prominent in both eyes (Fig. 2D, compare with Fig. 4 of Ref. 11). However, the visual acuity of both eyes remained at 1.2.

Case 4 is a 48-year-old man with night blindness who noticed a progressive decrease in his vision and a reduction in

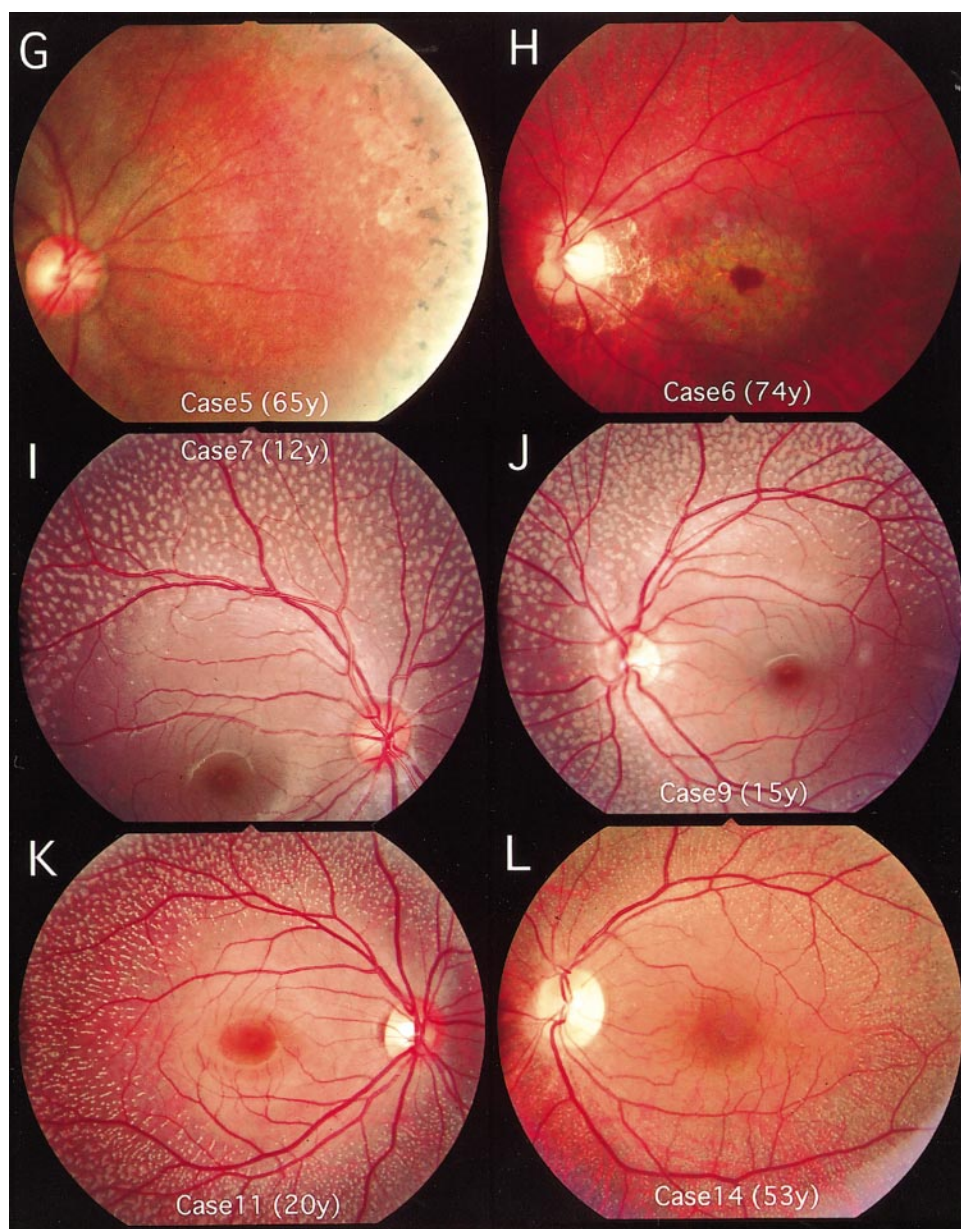


FIGURE 2. (Continued)

the size of his visual field over the previous 10 years. His corrected visual acuity was 0.03 in each eye. There was no abnormality in the anterior segment and the media. Numerous yellow-white dots were observed in the fundi, and the both maculas demonstrated a bull's eye lesion (Fig. 2E). His parents were not consanguineous, and his pedigree contained no other member with night blindness or low visual acuity. A central scotoma was detected in both eyes by Goldmann perimetry.

Full-field ERGs after 30 minutes of dark adaptation showed no rod response, a reduced cone b-wave with delayed implicit times, and a moderately reduced 30-Hz flicker response. Single bright-flash ERGs showed a severely reduced b-wave and moderately decreased a-wave. After 3 hours of dark adaptation, a rod b-wave was recorded (amplitude, 236 μ V), with a normal implicit time. Single bright-flash ERG showed an increase in the amplitude of the a- and b-waves (Fig. 3).

Case 5 is a 65-year-old man with night blindness who reported a progressive decrease in his vision. In 1989 his corrected visual acuity was 0.6 OD and 0.7 OS. His pedigree contained no other members with night blindness or low visual acuity, and no consanguinity was reported in his family.

His fundus demonstrated multiple yellow-white dots mainly in the midperiphery and degenerative changes in the periphery (Fig. 2G). The macula of the right eye showed a bull's eye maculopathy (Fig. 2F), but only atrophic changes were observed in the left macula. There was no vessel attenuation. Color vision tests revealed a severe blue-yellow defect.

Full-field ERG recordings demonstrated that rod, cone, and 30-Hz flicker responses were not present after 30 minutes of dark adaptation. Single bright-flash ERGs showed severely reduced a- and b-waves. After 2 hours of dark adaptation, only

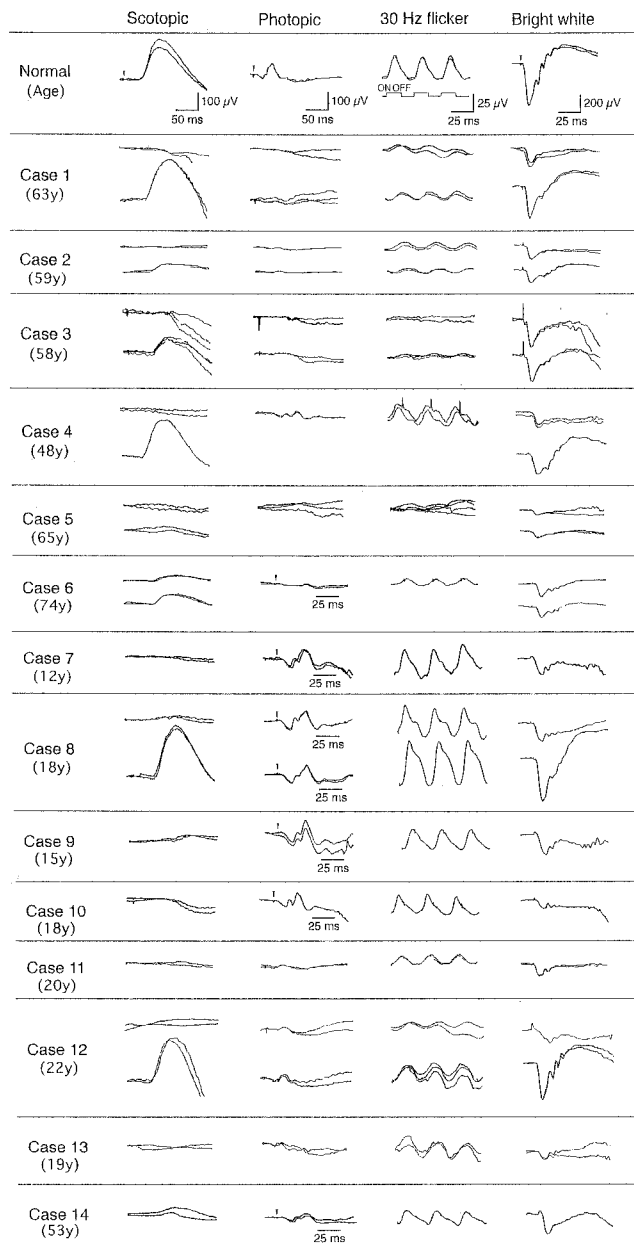


FIGURE 3. Full-field ERGs of a normal subject and cases 1 to 14. *Top tracing:* responses recorded after 20 (cases 7, 9, 10, 11, and 14) or 30 minutes (normal subject and cases 1 to 6, 8, 12, and 13) of dark adaptation; *bottom tracings:* responses recorded after prolonged dark adaptation (90 minutes for case 2; 2 hours for cases 4, 5, and 6; and 3 hours for cases 1, 3, 8, and 12). *Arrows,* stimulus onset. The age (years) of each patient is noted under the case number in the *left column.*

a very small rod b-wave of 19 μV was recorded, and single bright-flash ERGs showed a slightly larger a- and b-waves.

In 1999, when he was 65-year-old, his corrected visual acuity was reduced to 0.07 OD and 0.2 OS. The bull's eye in the right eye had enlarged, and a definite bull's eye was observed in the left eye. It was difficult to recognize the white punctate lesions in the fundus.

Case 6 is a 74-year-old man with night blindness who had noticed a gradual reduction of vision and a central scotoma over the previous 2 years. In 1995, his corrected visual acuity

was 0.3 in both eyes. His healthy parents were first cousins. His younger sister had severely reduced vision. Tiny white, dot-like lesions were seen over the fundi, and bull's eye maculopathy was observed in both maculas (Fig. 2H). Slight cataracts were seen in the both eyes. The peripheral visual fields were normal but the central sensitivity was decreased in both eyes.

Full-field ERGs recorded from the left eye after 30 minutes of dark adaptation showed that both rod and cone b-waves were significantly reduced. The 30-Hz flicker responses were also reduced. A single bright-flash ERG showed moderately decreased a- and b-waves. After 3 hours of dark-adaptation the rod b-wave improved to an amplitude of 73 μV , whereas the single, bright-flash ERG recorded approximately the same amplitude a- and b-waves (Fig. 3). He underwent cataract operations in the both eyes in 1996. In 1999 his visual acuity was reduced to 0.02 OD and 0.06 OS.

DISCUSSION

In the early 1920s, fundus albipunctatus was believed to be a stationary disease with night blindness. It was believed that other than the night blindness, the visual acuity, visual field, color vision, and other visual functions were normal.^{2,4,13-15}

Since then, some reports described cases of fundus albipunctatus with macular degeneration or cone dystrophy, and the question was raised whether this association of fundus albipunctatus and cone dystrophy was a chance association or whether the cone dystrophy was a later stage of fundus albipunctatus. It was noted that long-term follow-up had not been published on this group of patients to validate that the disease was truly stationary over the life of the patient.¹ In addition, genetic analysis was not available to determine whether the fundus albipunctatus and cone dystrophy arose from one or two mutations.

In this study, mutations of the *RDH5* gene were detected in all patients with fundus albipunctatus either with or without cone dystrophy. The cone dystrophy with significantly reduced photopic ERG responses was found in all but one elderly patient with fundus albipunctatus, and even in the elderly patient without cone dystrophy, her photopic ERGs were reduced. This suggests that the association of fundus albipunctatus with cone dystrophy was not due to a chance association of a mutation in two genes.

A major mutation of *RDH5* gene, nt 928 C to GAAG, was identified in patients either with or without cone dystrophy. These results led us to suppose that the cone dysfunction was frequently observed in elderly patients with fundus albipunctatus, in whom cone dystrophy with bull's eye accompanied the fundus albipunctatus, resulting in severe loss of visual function. Because the nt 928 C to GAAG mutation in the *RDH5* gene was found in 10 cases out of 13, this mutation may occur at a relatively high frequency in Japanese patients with fundus albipunctatus. Also, because this kind of base change mutation is rare, we suggest that our patients with this mutation probably originated from a common ancestor who lived many years ago in Japan. In the fundus albipunctatus patients over 40 years of age with the homozygous or heterozygous mutation, a cone dystrophy with bull's eye maculopathy and significantly reduced photopic b responses were found to accompany the fundus albipunctatus. In contrast, patients less than 20 years old with this mutation did not have cone dystrophy. Because it

is possible that they will show the cone dystrophy in the future, it is important to follow these cases for a long time. There were phenotypic differences between cases 1 to 5 with the same homozygous nt 928 mutation and cone dystrophy. For example, visual acuity of case 4 began to be reduced in his thirties and was 0.03 when he was 41 years old. Case 3 started to show macular abnormality after 50 years of age, and his visual acuity was maintained at 1.2 when he was 58 years old. The local chorioretinal atrophies outside the maculas appeared in cases 2, 3, and 5 but not in cases 1 and 4. These phenotypic differences including the clinical course and extent of the disease may be due to acquired factors such as the living environment and customs. In addition, other genetic factors may also play a role. In any case, our results have demonstrated that both the homozygous and heterozygous 928 C to GAAG mutation leads to the cone dystrophy with its manifestation at an older age.

The brothers, cases 12 and 13 with the homozygous Gly35Ser mutation, showed typical fundus albipunctatus without cone dystrophy. However, their cones were probably altered because the photopic ERGs were significantly reduced. One patient (case 11) with compound heterozygous mutations of nt 928 C to GAAG and Gly35Ser showed significantly reduced photopic ERG response, in spite of being only 20 years old. This suggests that the cone function of some patients with fundus albipunctatus can be altered from a young age. It is not known whether all the young patients with fundus albipunctatus will develop cone dystrophy. It is important to follow these patients, and more data are needed to determine the relationship between genotype and phenotype of fundus albipunctatus and its association with cone dystrophy.

We have noted that the size and the number of the white punctata decreased with age, and the white dots become inconspicuous in older patients. For example, in patients with homozygous nt 928 C to GAAG mutation, numerous distinct white dots were observed in the younger patients (cases 7-9; Figs. 2I, J), but they were not conspicuous in the older patients (cases 1-4; Figs. 2A through 2D). The white punctata were clearly observed in all the young patients, including those with other mutations (case 7-13; Figs. 2I through 2K), but it was more inconspicuous in an older patient, even without cone dystrophy (case 14; Fig. 2L). It may be possible that the white lesions will become inconspicuous or disappear at the end stage of fundus albipunctatus when only retinal degeneration is clearly observed. In such an end stage, both scotopic and photopic ERGs may be severely reduced and do not recover even after a long dark-adaptation time, as in case 5. In such cases, it will be difficult to diagnose the difference between fundus albipunctatus and retinitis punctata albescens, and probably only genetic examination can make the diagnosis.

Recently, additional genes causing cone dystrophies have been identified. Mutations of the cone-rod homeobox (*CRX*) gene, which is important for photoreceptor development, causes autosomal dominant cone-rod dystrophy.^{16,17} In *Crx*^{-/-} mice, the outer segments of photoreceptor do not develop.¹⁸ In adult mice, *CRX* is specifically expressed in photoreceptor cells and pinealocytes of pineal gland and activate the expressions of photoreceptor-specific genes, including rhodopsin, arrestin, and IRBP. Mutations of retinal guanylate cyclase (*RetGC-1*), which is a retina-specific, Ca²⁺-regulated membrane guanylate cyclase and is pivotal for vertebrae phototransduction, also causes autosomal dominant

cone-rod dystrophy.¹⁹ A specific mutation (Y99C) has been found in the gene for guanylate cyclase activator 1A (*GUCAIA*) that encodes a guanylate cyclase-activating protein (GCAP1), which is a calcium-binding protein expressed predominantly in the outer segments of photoreceptors. GCAP1 plays an important role in the recovery phase of phototransduction by activating RetGC-1, and mutation of this protein leads to autosomal dominant cone dystrophy.²⁰⁻²² In addition, Val20Glu, Asn244His and Tyr184Ser mutations of the *peripherin/RDS* gene were found in some patients with autosomal dominant cone-rod dystrophy.^{23,24} Mutation in the splice site of retina-specific ATP-binding cassette transporter (*ABCR*) gene, which causes Stargardt disease, was found in a family of autosomal recessive cone dystrophy.²⁵

Our cases are the first showing that mutations of the *RDH5* gene causes cone dystrophy, and to our best of knowledge, this is the sixth gene that causes cone dystrophy. This is also the first report of a gene expressed in the RPE causing cone dystrophy, because all other known genes causing cone dystrophy are expressed in photoreceptor cells. Although the exact mechanism whereby mutations lead to cone dystrophy is unknown, the *RDH5* gene appears important for maintenance of normal cone function.

Acknowledgments

The authors thank Thaddeus P. Dryja, MD and Hiroyuki Yamamoto, MD for their helpful information about the primers for mutation analysis of *RDH5* gene.

References

1. Heckenlively J. Congenital stationary night blindness. In: Traboulsi EI, ed. *Genetic Diseases of the Eye*. New York: Oxford University Press; 1998:389-396.
2. Krill AE. *Hereditary Retinal and Choroidal Diseases*. Volume 2. Hagerstown: Harper and Row; 1977:739-824.
3. Marmor MF. Long-term follow-up of the physiologic abnormalities and fundus changes in fundus albipunctatus. *Ophthalmology*. 1990;97:380-384.
4. Gass JDM. *Stereoscopic Atlas of Macular Disease. Diagnosis and Treatment*. 4th ed. St. Louis: Mosby; 1997:350-351.
5. Lauber H. Die sogenannte Retinitis punctata albescens. *Klin Monatsbl Augenheilkd*. 1910;48:133-148.
6. Kajiwara K, Sandberg MA, Berson EL, Dryja TP. A null mutation in the human *peripherin/RDS* gene in a family with autosomal dominant retinitis punctata albescens. *Nat Genet*. 1993;3:208-212.
7. Burstedt MSI, Sandgren O, Holmgren G, Forsman-Semb K. Bothnia dystrophy caused by mutations in the cellular retinaldehyde-binding protein gene (*RLBP1*) on chromosome 15q26. *Invest Ophthalmol Vis Sci*. 1999;40:995-1000.
8. Morimura H, Berson EL, Dryja TP. Recessive mutations in the *RLBP1* gene encoding cellular retinaldehyde-binding protein in a form of retinitis punctata albescens. *Invest Ophthalmol Vis Sci*. 1999;40:1000-1004.
9. Yamamoto H, Simon A, Eriksson U, Harris E, Berson EL, Dryja TP. Mutations in the gene encoding 11-*cis* retinol dehydrogenase cause delayed dark adaptation and fundus albipunctatus. *Nat Genet*. 1999;22:188-191.
10. Gonzalez-Fernandez F, Kurz D, Bao Y, Newman S, Conway BP, Young JE, Han DP, Khani SC. 11-*cis* Retinol dehydrogenase mutations as a major cause of the congenital night-blindness disorder known as fundus albipunctatus. *Mol Vision*. 1999;5:41.
11. Miyake Y, Shiroyama N, Sugita S, Horiguchi M, Yagasaki K. Fundus albipunctatus associated with cone dystrophy. *Br J Ophthalmol*. 1992;76:375-379.

12. Tomida N, Miyake Y, Horiguchi M, Shiroyama N. Fundus albipunctatus associated with macular atrophy. Comparison with typical fundus albipunctatus in terms of age. *Folia Ophthalmol Jpn*. 1994; 45:623-626.
13. Scouras J, Chevaleraud J, Papastratigakis B. Macular involvement in retinitis albescens. *J Fr Ophthalmol*. 1979;2:613-617.
14. Sato S, Iijima H. A case of fundus albipunctatus associated with cone dysfunction. *Rinsbo Ganka*. 1987;41:1307-1310.
15. Welber RG. Retinitis pigmentosa and allied disorders. In: Ryan SJ, Ogden TE, eds. *Retina*. St Louis: Mosby; 1989;1:346-348.
16. Freund CL, Gregory-Evans CY, Furukawa T, et al. Cone-rod dystrophy due to mutations in a novel photoreceptor-specific homeobox gene (*CRX*) essential for maintenance of the photoreceptor. *Cell*. 1997;91:543-553.
17. Swain PK, Chen S, Wang QL, et al. Mutations in the cone-rod homeobox gene are associated with the cone-rod dystrophy photoreceptor degeneration. *Neuron*. 1997;19:1329-1336.
18. Furukawa T, Morrow EM, Li T, Davis FC, Cepko CL. Retinopathy and attenuated circadian entrainment in *Crx*-deficient mice. *Nat Genet*. 1999;23:466-470.
19. Kelsell RE, Gregory-Evans K, Payne AM, et al. Mutations in the retinal guanylate cyclase (*RETGC-1*) gene in dominant cone-rod dystrophy. *Hum Mol Genet*. 1998;7:1179-1184.
20. Payne AM, Downes SM, Bessant DA, et al. A mutation in guanylate cyclase activator 1A (*GUCA1A*) in an autosomal dominant cone dystrophy pedigree mapping to a new locus on chromosome 6q21.1. *Hum Mol Genet*. 1998;7:273-277.
21. Dizhoor AM, Boikov SG, Olshevskaya EV. Constitutive activation of photoreceptor guanylate cyclase by Y99C mutant of GCAP-1. Possible role in causing human autosomal dominant cone degeneration. *J Biol Chem*. 1998;273:17311-17314.
22. Sokal I, Li N, Surgucheva I, et al. GCAP-1 (Y99C) mutant is constitutively active in autosomal dominant cone dystrophy. *Mol Cell*. 1998;2:129-133.
23. Nakazawa M, Naoi N, Wada Y, et al. Autosomal dominant cone-rod dystrophy associated with a Val200Glu mutation of the *peripherin/RDS* gene. *Retina*. 1996;16:405-410.
24. Nakazawa M, Kikawa E, Chida Y, Wada Y, Shiono T, Tamai M. Autosomal dominant cone-rod dystrophy associated with mutations in codon 244 (Asn244His) and codon 184 (Tyr184Ser) of the *peripherin/RDS* gene. *Arch Ophthalmol*. 1996;114:72-78.
25. Cremers FP, van de Pol DJ, van Driel M, et al. Autosomal recessive retinitis pigmentosa and cone-rod dystrophy caused by splice site mutations in the Stargardt's disease gene *ABCR*. *Hum Mol Genet*. 1998;7:355-362.