THE BEHAVIOR OF CHICKEN SARCOMA IMPLANTED IN THE DEVELOPING EMBRYO.*

By JAMES B. MURPHY, M.D., and PEYTON ROUS, M.D.

(*From the Laboratories of The Rockefeller Institute for Medical Research, New York.*)

Plates 17–22.

Current theories of tumor origin have done much to stimulate the experimental comparison of neoplastic with embryonic tissue. The discussions upon "cell rests," "cell avidity," and the mutual relationships of tissues as determining the incidence of tumors (Thiersch), have led to a vast amount of work in this field. But the methods used have, of necessity, been indirect. In the present paper we wish to offer some observations on the direct transmission of tumors to the developing embryo.[1]

The common transmissible tumors have occurred in mammals, and it is most difficult to inoculate the growth into the mammalian embryo *in utero* without interrupting the course of pregnancy. Nevertheless it can be done, as one of us (Rous) has found. With a fine, hollow needle, injections of tumor pulp were made through the uterine wall into rat embryos; and some of these went on to term. In one instance, the tumor graft was found in an animal killed just after birth, but in the few days previous to the end of pregnancy, it had only established itself and had not grown. Embryos inoculated early in gestation did not survive.

The problem is much simpler when use is made of developing hen's eggs and the avian sarcoma propagated in this laboratory.[2] Under suitable precautions, the injection into the chick or its membranes need do no more than transiently retard development. We have employed the method developed by Peebles[3] for studies in

* Received for publication, December 12, 1911.

[1] Peyton Rous and James B. Murphy, *Jour. Am. Med. Assn.*, 1911, lvi, 741.

[2] Peyton Rous, *Jour. Exper. Med.*, 1910, xii, 696; 1911, xiii, 397.

[3] F. Peebles, *Arch. f. Entwcklngsmechn. d. Organ.*, 1898, vii, 405.

experimental embryology. A small rectangular piece is cut from the shell with a sharp instrument, care being taken not to break the underlying membranes; with fine, sterile forceps, the shell membrane is torn and pulled back, exposing the chick and its membranes, and through a hollow needle the tumor material is placed in the desired location. The bit of shell is then put back and sealed into position with paraffin, or with narrow strips of moist shell membrane from a fresh egg. For the purpose of inoculation, the tumor is reduced to a pulp, either by grinding or by forcing it through a sieve; and a very minute portion is injected into each egg. To regulate the amount actually implanted in the tissue is very difficult, as that which it is intended to place in an extra-embryonic membrane largely escapes to either side, and that implanted in the embryo itself often follows the needle to the surface. The eggs of pure blooded, barred, Plymouth Rock chickens have been mainly used, both for purposes of comparison, and because adult fowls of this variety are especially susceptible as hosts for the sarcoma.

The results include observations upon 147 hen's eggs, 16 duck, and 9 pigeon eggs, which continued to develop after inoculation.

GENERAL DESCRIPTION OF THE FINDINGS.

In 108 of the 147 hen's eggs, the inoculation gave rise to one or more tumors. The findings varied with the stage at which the embryo was inoculated, and were further complicated by its development. For a preliminary general description use will be made of the growths in eggs inoculated on the seventh or eighth day of incubation, and opened a week or ten days later. The best success was obtained under these conditions.

Tumors in the Outer Allantoid Membrane.—The majority of the growths occurred in the outer allantoid membrane (fused chorion and allantois), and for evident reasons. This membrane was necessarily pierced in reaching other structures, and its inoculation could hardly be avoided in withdrawing the needle. Often the material expelled elsewhere from the needle clung, and was dislodged only on the inner surface of the allantoid membrane.

When the egg successfully inoculated is opened on the fifteenth

or sixteenth day of incubation, a disc-shaped, gray opacity is seen at the point where the allantoid membrane was wounded by the needle. It is sharply defined, but not raised, and suggests scar tissue only. Its center may be perforated where healing has been incomplete. When the membrane is cut and turned back, a remarkable picture presents itself. From the inner surface, a discrete growth projects, glistening, smooth, and grayish pink, firm, opaque, more or less globular in shape, and sessile on the membrane (figures 1, 2, and 7). Should the membrane have failed to heal together, the growth takes the form of a sharply raised ring about the hiatus. Numerous dilated vessels course to and over the tumor. The contrast between the filmy membrane and the bulky mass which it supports is very striking.

The main growth is always situated at the point injured by the needle; but one or several, small but similar nodules are sometimes present near by, along the vessels. They also are discrete and project sharply. As early as four days after the inoculation, the implanted tissue may be vascularized and established; while after ten days a mass 1.9 centimeters in diameter may have developed. In consistence, it is softer than a nodule of the same size in the adult fowl. Necrosis is uncommon; hemorrhage into the tumor substance, less so (figure 2).

Tumors in the Other Membranes.—When at the seventh day of incubation, the injection needle is thrust toward the egg's center, it may either (*a*) penetrate the fused inner allantoid and amniotic membranes, with the amniotic sac and embryo, or (*b*) pass through the inner allantoid membrane into the extra-embryonic body cavity and yolk-sac (figure 3). When the inoculation has taken place according to the first possibility, a small tumor is usually found at the point where the needle has pierced the fused amnion and allantoid membrane. In general appearance, the growth resembles those already described, but it is usually much smaller, lies in the plane of the membrane and projects sharply on either surface. Its vascularization is less profuse than in the outer allantoid membrane, which probably in part explains its small size.

When the inoculation has occurred according to the second possibility, namely, through the inner allantoid membrane into the extra-

embryonic body cavity and yolk-sac, a most interesting variation is encountered. The tumors heretofore discussed have been localized at the point wounded by the injection needle; but when the material has been introduced into the extra-embryonic body cavity, many scattered growths appear on the surface of the inner allantoid membrane, the amnion, and the yolk-sac, which together enclose it. Their lining surfaces, in distinction from those of the membranes heretofore dealt with, consist of mesoderm (figure 3). The growths that form upon this mesodermal layer are discrete, pearly, globular or disc-shaped, and of various sizes, though usually small; and they lie, not within the substance of the membrane, but upon its surface to which their attachment may be slight (figure 4). In the yolk-sac, there frequently occurs at the point punctured by the needle, a large tumor, discrete as in the other membranes, grayish pink, and translucent. It is raised only slightly on the outer surface of the sac, but may develop considerably towards its interior, forming a conical mass projecting inwards.

Tumors in the Embryo.—Thus far no attempt has been made to implant the sarcoma in special regions of the embryo. The latter swings about under pressure with the needle, rendering this difficult. By indiscriminate implantation, growths have been obtained in the chest wall, heart, liver, peritoneal surface of the gizzard, soft tissue of the thigh and that of various other parts (figures 5 and 6). All appeared in the track of the needle. The sarcomatous nodules were similar in consistency to those in the membrane, often absolutely discrete, and always singularly non-invasive, when compared with those in the adult. Some reached a considerable size, relative to the bulk of the embryo. In several cases, we have thought that death of the embryo was to be accounted for by the presence of large tumors in the membranes. Maceration quickly ruins the material for histological purposes.

HISTOLOGICAL FINDINGS.

Histologically, the tumors differ little from those in the adult fowl. In general structure, they are quite unlike the scar tissue produced in the embryonic tissues by a trauma, or the proliferative reaction that follows the injection of infusorial earth, although

the sarcoma cells have a resemblance to certain individual elements present in both these cases. With infusorial earth, it is possible to obtain pseudo-tumors in the outer allantoid membrane, consisting of many folds of the latter with an edematous, cellular mesoderm, covered by somewhat thickened ecto- and endoderm. All gradations are seen, here and in scar tissue, between the ordinary, stellate, mesodermal cells and spindle-shaped elements irregularly grouped. There are, in addition, polymorphonuclear and large mononuclear cells attesting the inflammatory nature of the growth. In the tumor, on the other hand, the cells are all of one type—spindle cells in bundles—while the general aspect of the neoplasm is entirely homogeneous. Within it there is absolutely no focal arrangement, and about it no cellular reaction (figure 8).

In the embryo, the structure of the sarcoma is much looser than in the adult, and the spindles may be so attenuated as to suggest that the growth is a myoma (figure 9), a possibility ruled out by the use of special stains. Intercellular fibrils are demonstrable, but are few in number. The many blood-vessels are thin walled, often consisting of only a layer of endoderm, and, apart from them, the growth possesses practically no supporting tissues. Well defined lymph-channels are not seen. The rarity of necrosis is doubtless due to the loose structure and the excellent vascularization, both of which, on the other hand, favor hemorrhage (figure 2). In general, the sarcomatous cells are larger than the normal connective-tissue elements, and their cytoplasm stains more deeply with methylene blue. The nucleus is large, oval or elongated, vesicular, with a fine net-work of chromatin and a well defined, deeply staining nucleolus. Proliferation takes place mostly by amitosis. As many as 69 per cent. of the cells, by count, have been found in process of division at one time (table I).

The growth of tumors situated in the membranes is almost wholly expansive in character. Invasion of the neighboring structures is seldom well marked. The soft, normal tissues are pressed to one side, and the mass retains microscopically the well defined border seen in the gross. So too in the embryo, except when the growth lies in structures (heart and liver) which may be supposed to adjust themselves less easily to it, and which are in consequence

infiltrated, as well as thrust to one side. The important influence of mechanical factors on the relations of the growth is well illustrated by the findings in the outer allantoid membrane. Taking the course of least resistance, the neoplasm enlarges in the direction of the allantoid cavity and finally comes to lie almost wholly without the membrane that supports it, although still covered by endoderm and to be considered as having place in the mesoderm.

RELATION OF THE SARCOMA TO THE MESODERM.

It has been shown that in adult fowls the cells of the chicken sarcoma survive transplantation, and, proliferating, give rise to the new nodule. The process has not been followed systematically in the embryo, although it is very evident there, being perhaps best seen in the survival of sarcomatous fragments which have lodged on the exposed mesoderm lining the extra-embryonic body cavity (figure 10). These surface implantations in time become vascularized and eventually develop into neoplastic masses of considerable size.

In the adult fowl, it is not always necessary for the development of tumor fragments that they be brought directly in contact with connective tissue. Bits injected into the peritoneal cavity may establish themselves despite its endothelial lining, proliferating sometimes in a way that suggests cell cultures in a fluid medium, and at length obtaining from the underlying tissues a vascularization. Not so in the extra-embryonic membranes of the chick, according to our experience. Here a layer of ectoderm or endoderm but one cell thick constitutes an absolute protection against surface implantations. Only where a mesodermal layer is exposed, as on the inner side of the inner allantoid membrane, do such implantations occur. This dependence of the tumor cells on a direct association with mesodermal tissue, if they are to become established in the embryo, is responsible for the difference in localization of the tumors in the different membranes—for the occurrence in one of a single nodule at the puncture point, and in another of many surface growths. Recognizing this dependence and knowing the state of development of the egg, and the structures pierced by the injection needle, we can predict with some accuracy, despite the changing conditions, the localization of growths in the membranes.

GROWTH OF SARCOMA CELLS IN THE YOLK.

The presence of a free "rice-body," consisting of tumor cells, in the extra-embryonic body cavity of an inoculated chick, has led to some experiments after the method of Burrows[4] on the *in vitro* growth of sarcoma cells in the fluids of the egg. The "rice-body" in question was rounded, gray, translucent, firm, five millimeters in diameter, was unprovided with blood-vessels or with an epithelial or endothelial covering, and was made up entirely of neoplastic cells of highly attenuated form (figure 11). To judge from the uniform failure of our attempts to grow sarcoma cells *in vitro* in the fluid of the extra-embryonic body cavity, the "rice-body" must at one time have been attached to the membrane and have derived its nourishment therefrom. The cells will not grow in egg albumen taken at various periods in the chick's development. In the yolk, on the other hand, they sometimes proliferate *in vitro,* a fact not very significant, considering the relatively simple fluids in which the proliferation of normal cells can take place.[5]

EFFECT OF THE EMBRYO'S PERIOD OF DEVELOPMENT.

Most of the embryos inoculated at very early stages succumbed to the trauma, and of those which survived, few showed the growth. This is perhaps traceable to a change in the method of inoculation, made necessary by the conditions. Injections into the blastoderm could hardly be practised; so, instead, a minute bit of tumor was placed on the tip of a fine needle and this was thrust into the desired location. Twenty-three eggs in all, which had been incubated for twenty-four to forty-eight hours, continued to develop after an inoculation of this sort into the outer zone of the blastoderm. In five, the tumor developed as a discrete, pearly nodule imbedded in the membrane, usually minute and always very small as compared with growths obtained after the same time in the membranes of older chicks. It was always found close to the margin of the area vasculosa, a fact that indicates that the proliferation of the blastoderm to form the membrane took place to a much greater degree in

[4] M. T. Burrows, *Jour. Am. Med. Assn.*, 1910, lv, 2057.

[5] M. R. Lewis and W. H. Lewis, *Bull. Johns Hopkins Hosp.*, 1911, xxii, 126.

the inner zone than in the tissue marginal to the inoculated spot. With embryos inoculated at somewhat later periods, similar results were obtained.

When incubation was far advanced at the time of inoculation, and the chick was allowed to hatch, the tumors that had developed in the outer membranes were cast off with them. Growths in the yolk sac were drawn with it into the body and continued to develop. In one instance, a chick lived for three weeks after hatching. On autopsy, multiple sarcomatous nodules were discovered in the lungs and liver. They were best developed in the latter organ, and were presumably secondary to a tumor in the yolk-sac, now absorbed.

METASTASES.

Regional metastases in the outer allantoid membrane are fairly common. They take the form of small nodules near the primary growth, along the large vessels supplying the latter, and are presumably distributed by the lymphatics. Remote metastases from growths in the membranes have not been found, a fact which can scarcely be explained by the short period of observation, since this period suffices for the development of regional metastases. It is much better accounted for by the structure of the membranes. The lack of invasive extension in them has already been commented upon. Growth into the blood-vessels of a membrane is of rare occurrence, and even when present need not involve, in a region so protected against trauma, the casting off of cells into the blood-current.

In the embryo itself there has been no case in which the situation of the tumors could not be explained by direct inoculation with the injection needle; but our data are hardly sufficient to permit any conclusion as regards the frequency of secondary growths. In the chick that has hatched, a distribution of the sarcoma may take place by the blood-stream, as in the case of adult fowls.

TRANSPLANTATION FROM EMBRYO TO EMBRYO.

The transplantation of the sarcoma from embryo to embryo is not difficult, but in practice is limited by the small amount of ma-

terial available for the inoculation and the high incidental mortality. By using the outer allantoid membrane as the injection site, and employing the growths found there after seven days, we have successfully transplanted the sarcoma to three successive sets of eggs, only to lose it on the fourth by death of all the embryos. The same cause terminated more quickly two other series. During the continued propagation, no change was noted in the tumor's behavior. Inoculation from the embryo into the adult yields the characteristic sarcoma.

TUMORS PRODUCED BY A BERKEFELD FILTRATE.

The chicken sarcoma has been repeatedly engendered in adults by means of the Berkefeld filtrate of an extract of the fresh tumor in Ringer's solution;[6] and so, too, in the embryo. One of us is now engaged in a study of the histological processes involved. In the egg, the growths are first evident three or four days after the injection, as minute, whitish dots, having the same location in the various structures as those produced by the living cells. For example, in the outer allantoid membrane and others with a protected mesoderm, a single growth appears at the point punctured by the injection needle; but on the exposed mesodermal lining of the extra-embryonic body cavity, widely scattered growths develop. But even on the exposed mesoderm, the neoplastic change is punctate and the nodules remain discrete, from which it may perhaps be inferred that the agent giving rise to them is not in solution but is a formed body.

The sarcoma has also been produced in the embryo by injecting a suspension of the dried and powdered neoplastic tissue. The results do not differ essentially from those obtained with a filtrate.

TUMORS IN THE PIGEON AND DUCK EMBRYOS.

The sarcoma will not grow in pigeons or ducks, while in chickens of another variety than that in which it originally occurred, it grows relatively slowly and is subject to retrogression. But in the embryos of these alien fowls, the results are quite different. In four of nine pigeon eggs inoculated and developing, and in six of sixteen duck eggs, tumors were obtained. The inoculations were made into the

[6] Rous, *loc. cit.*

membranes alone, and the growths developing there (figure 12) resembled those arising in similar situations in Plymouth Rock embryos. When portions were transplanted to adult pigeons and ducks, respectively, no tumor resulted. In the eggs of an alien variety of chicken (Brahma), the growths were also similar to those in Plymouth Rocks.

These observations may be thought to lose in importance because of the short period (seven to ten days) during which the development of the tumor was noted, since in alien, adult fowls a brisk, temporary growth of the implanted tissue is often seen. But in alien adults, even in so short a time, an immense accumulation of lymphocytes takes place about the graft which itself shows well marked degenerative changes. In the embryo, neither phenomenon is present. The growing tissue appears "healthy," and about it small round cells do not collect, despite the fact that many such cells are present in the circulating blood.

RESISTANCE OF THE EMBRYO.

The question arises as to whether some individual chick embryos, like some adult hosts, possess a natural resistance to the tumor. Among 147 chick embryos that continued to develop after inoculation, 39 failed to show any tumor; and we at first supposed this finding to indicate a natural resistance, and referred to it as such in our preliminary note.[7] But an extensive search has failed to disclose, in any instance, those histological signs about and within the growing tumor which, in the adult, are associated with resistance of the host. Because of this total lack of evidence of partial resistance, we now believe that the non-appearance of the sarcoma in inoculated chick embryos is due entirely to chance causes. An analysis of the cases supports this idea. In seventeen of the thirty-nine, the inoculation was done at a very early period, according to the uncertain method already described; while in nine others, a Berkefeld filtrate alone was inoculated; and in five, dried material; leaving but eight that gave negative results after implantation with fresh tumor material, as compared with 108 positive results from inoculations of all sorts. Once the tumor has established itself, no

[7] Peyton Rous and James B. Murphy, *Jour. Am. Med. Assn., loc. cit.*

effectual resistance is opposed to its growth by the chicken embryo, or even by the pigeon or duck embryo.

RELATIVE RAPIDITY OF GROWTH IN THE EMBRYO.

Bashford[8] first showed that young animals are more susceptible than adults as hosts for transmissible tumors; and Buschke[9] has since reported that this susceptibility extends even to the newly born. One of us has made independently many comparative observations on adult mice and mice one or two days old, which confirm Buschke's statement.

A number of complicating circumstances enter into the comparison of results in embryo and adult hosts, as can be well illustrated from the present work. The growth that follows inoculation of a minute bit of sarcomatous tissue into a twenty-four or forty-eight hour chick embryo is found, seven days afterwards, to be very small. But so too, for that matter, is the host nourishing it. The graft implanted in a membrane of an older chick grows vigorously. But here there is a notable absence of the mechanical restraints met with in adult hosts. Very much more tumor tissue, relatively speaking, is injected into embryo hosts than into adults, while, on the other hand, the actual amount is considerably less. These factors and many others complicate the comparison.

The findings in embryos injected at the tenth day are perhaps best compared with those in adults. Here, whether in the membranes or in the embryo's body, the growth of the tumor is excellent. The actual size of the masses formed is not behind that observed within the same period in adults, a fact that gains in significance when the small size of the host and the small amount of implanted tissue are recalled. Several counts have shown that in the tumors of the embryo more cells, on the average, are in process of division at one time than in those of adults (table I), while, as already stated, there is about the tumor a total absence of those histological signs of resistance so frequent even in susceptible adults. Altogether, chicks inoculated at the tenth day of incubation seem more favorable to the tumor growth than adult fowls.

[8] E. F. Bashford, J. A. Murray, M. Haaland, and W. H. Bowen, *Scientific Reports of the Imperial Cancer Research Fund*, 1908, No. 3, 265.

[9] A. Buschke, *Berl. klin. Wchnschr.*, 1911, xlviii, 215.

TABLE I.

Relative Number of Dividing Tumor Cells in Adult and Embryo Hosts.

	Adult.			Embryo.			
	Mitotic, per cent.	Amitotic, per cent.	Total number dividing, per cent.	Total number dividing, per cent.	Mitotic. per cent.	Amitotic per cent.	
Primary (from filtrate)	2	18	20	52	3	49	Liver.
Primary	4	42	46	70	1	69	Chest wall.
Primary (from dried material)	2	28	30	64	4	60	Membrane.
Primary	3	20	23	67	3	64	Membrane.
Metastasis (ovary)	1	26	27	57	1	56	Membrane.
Metastasis (liver)	3	44	47				
Metastasis (lung)	2	24	26	40	13	17	Membrane (pigeon).

Counts of one hundred cells at all stages of division.

We see no reason why this conclusion cannot be extended to embryos at earlier periods of development. The less striking results in these must certainly be laid in large part to the method of inoculation, and to the relative unfitness of the host to nourish the implanted tissue, owing to its small size and simple structure.

SUMMARY.

The direct inoculation of a sarcoma of the fowl into the developing chick embryo or its membranes has yielded growths in many cases. The best results have been obtained with grafts of the living tumor tissue, but, as in the adult, growths can be engendered with dried tissue or with the Berkefeld filtrate of a tumor extract. When living tumor tissue is used, an actual transplantation occurs.

The neoplasms developing are spindle-celled sarcomata, remarkably uniform in structure, and similar to those in the adult fowl, except that in the embryo the neoplastic cells are often extremely long and slender, and the structure of the growth is very loose. The membranes adapt themselves in a remarkable way to the support of the tumors. In them, the growth is seldom invasive; and while regional metastases are occasionally seen, none occur by the blood-

stream, despite the predilection of the growth for this path of distribution in adult hosts. In the more resistant structures of the embryo itself, an invasive extension of the sarcoma occurs. Growths originally in the yolk-sac outside the chick may be carried into the latter during the course of development. Secondary growths in the viscera may cause the death of the host some weeks after hatching.

In order to produce tumors in the embryo, the sarcoma cells or the agent engendering the growth must be brought into a direct association with the mesodermal tissues. This necessity is responsible for interesting differences in the location of the growths in the various membranes.

The sarcoma will grow in the membranes of pigeon or duck embryos, whereas in adults of these species it will not do so; and in chicken embryos of different varieties, it grows uniformly well, a finding not obtained in adults. In embryo hosts of all the sorts mentioned, there is a total absence of the cellular reaction which in adults indicates resistance to the tumor's development. Relatively speaking, the embryo seems much more favorable than the adult as a host for the sarcoma.

EXPLANATION OF PLATES.

Plate 17.

Fig. 1. A tumor in the outer allantoid membrane of an eighteen day chick. The growth is situated at the point where tumor tissue was implanted seven days before. It is sessile on the inner surface of the membrane. Note the large blood-vessels supplying it. The longest diameter of the mass measures 1.5 cm.

Fig. 2. Cross-section of a tumor, smaller, but otherwise similar to figure 1. It is a spindle-celled aggregate, attached to the membrane by a narrow base, covered by a single layer of endodermal cells, and supplied by vessels with thin walls. Extensive hemorrhage has occurred into the right half of the growth.

Plate 18.

Fig. 3. Diagram adapted from "The Development of the Chick" by F. R. Lillie (Chicago, 1908). The chick and its membranes at the twelfth day of incubation are represented in cross-section. The mesodermal layer is given in red, and dotted lines show the direction taken by the injection needle. The distribution of the tumors in the various membranes is given in cross-hatched red.

All. and *Am.* = fused allantois and amnion; *Am. C.* = amniotic cavity; *Am.* = amnion; *E. E. B. C.* = extra embryonic body cavity; *Ect.* = ectoderm;

Mes. = mesoderm; *Ent.* = entoderm; *All. I.* = inner allantoid membrane; *All. C.* = allantoid cavity; *Y. S.* = yolk-sac.

FIG. 4. Multiple nodules in the extra-embryonic body cavity, as seen through its wall. The embryo was at its nineteenth day of incubation, and the inoculation had taken place on the eighth day.

PLATE 19.

FIG. 5. Sarcoma in the soft tissues of the leg of an embryo at the eighteenth day of incubation, and the eighth day after implantation.

FIG. 6. Sarcomatous masses on the surface of the right auricle, and the right side of the thorax, respectively. Both are in the track of the injection needle. Chick at the eighteenth day of incubation, and the seventh day after inoculation.

PLATE 20.

FIG. 7. Beginning growth in the outer allantoid membrane, four days after inoculation. The glistening, gray nodule projects sharply on the membrane's inner surface. The photograph is marred by reflections, seen as pale streaks on the membrane and as an irregular, white area to one side of the tumor itself.

FIG. 8. Edge of a sarcomatous mass in the outer allantoid membrane. The tumor is made up of spindle cells in a loose network. About it there is no cellular reaction. From an egg at the eighteenth day of incubation and the eighth day after inoculation.

PLATE 21.

FIG. 9. Cross-section of a sarcomatous nodule in the outer allantoid membrane. The cells are of very attenuated spindle form. Many are in process of amitotic division.

FIG. 10. Implantation nodule on the mesoderm lining the extra-embryonic body cavity.

PLATE 22.

FIG. 11. Marginal portion of a "rice-body" found in the extra-embryonic body cavity of an embryo at the eighteenth day of incubation and the seventh day after inoculation. The mass consists entirely of tumor cells of very attenuated form, without blood-vessels or endo- or ectodermal covering.

FIG. 12. A portion of a sarcoma in the outer allantoid membrane of a duck embryo at the seventeenth day of incubation, and the seventh day after inoculation. The growth is similar to those in the chick.

FIG. 1.

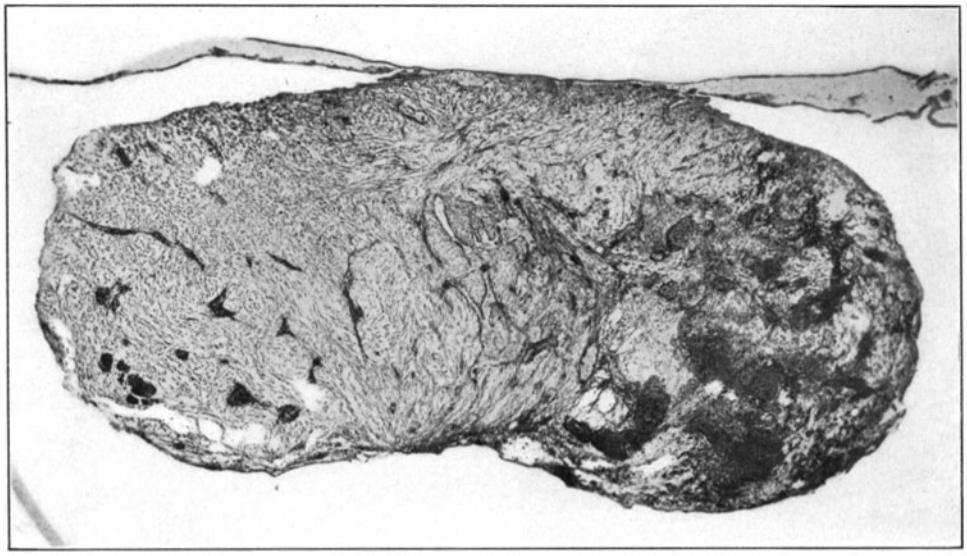

FIG. 2.

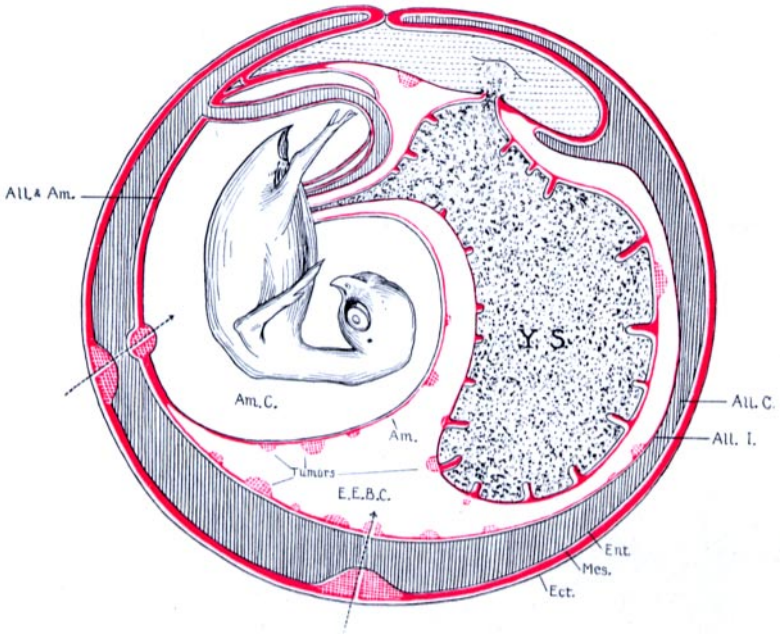

FIG. 3.

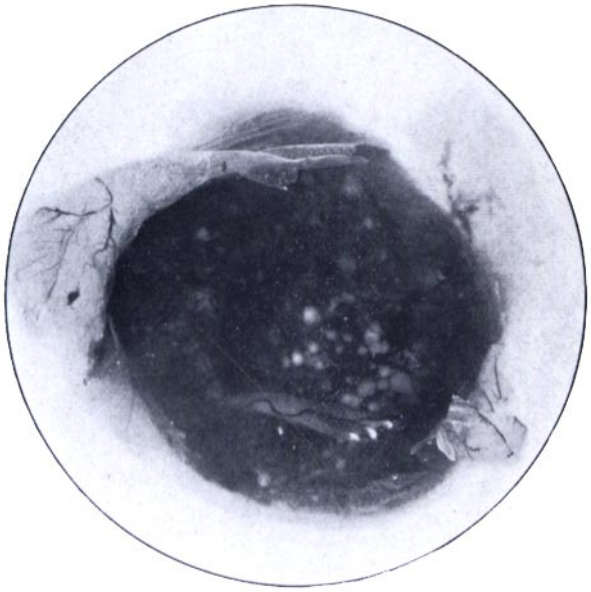

FIG. 4.

FIG. 5.

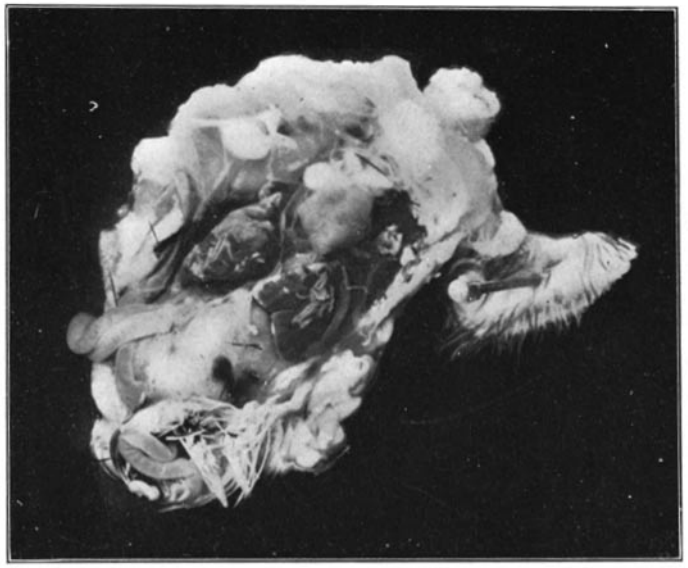

FIG. 6.

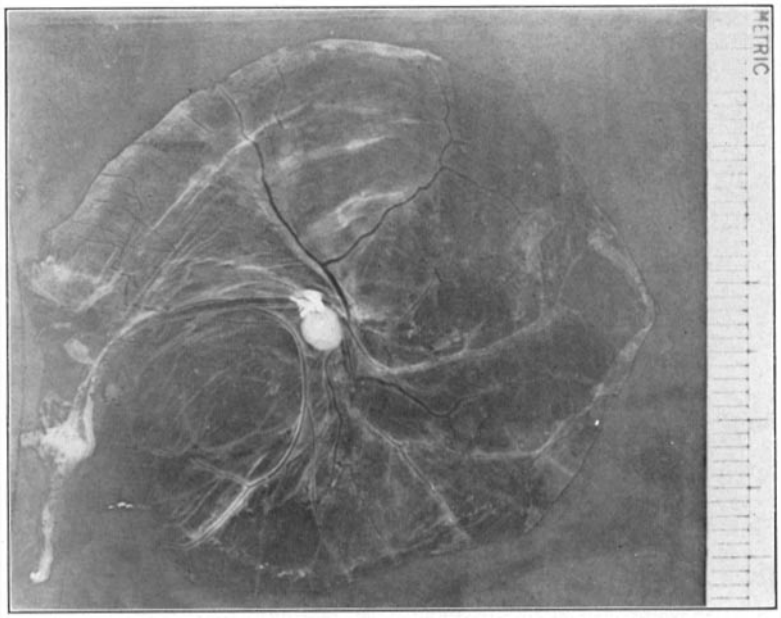

FIG. 7.

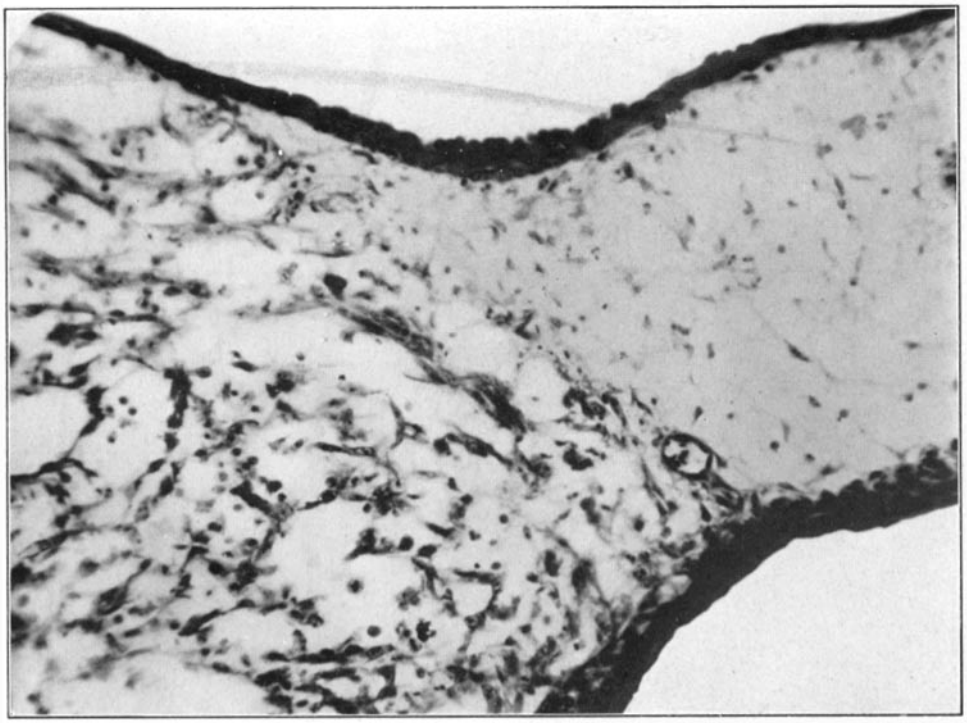

FIG. 8.

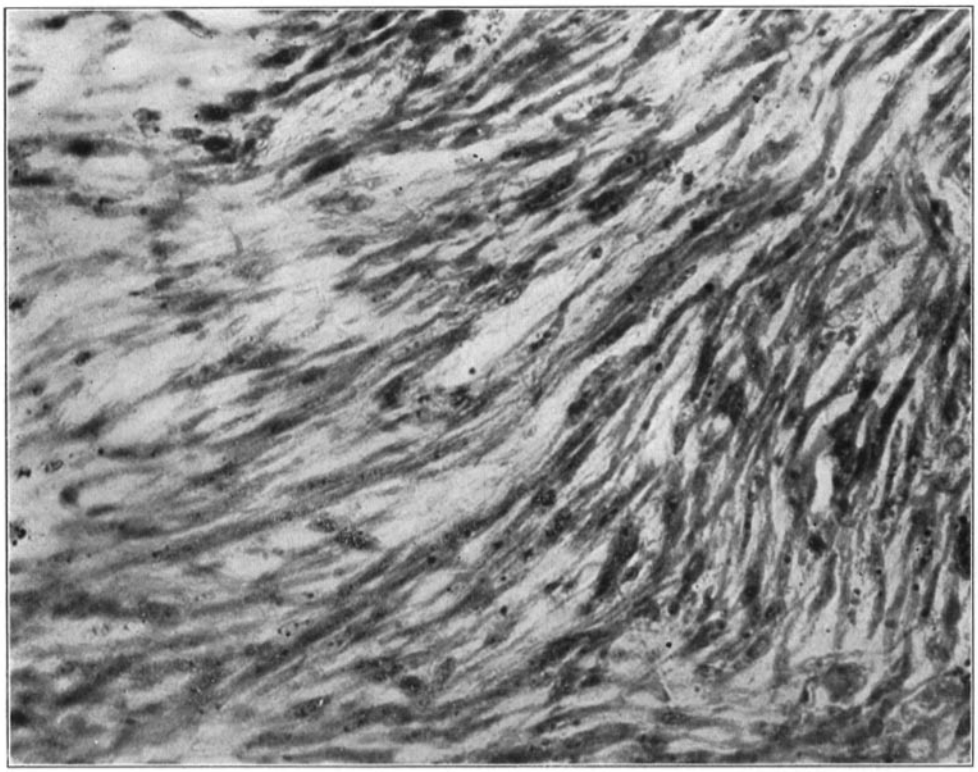

FIG. 9.

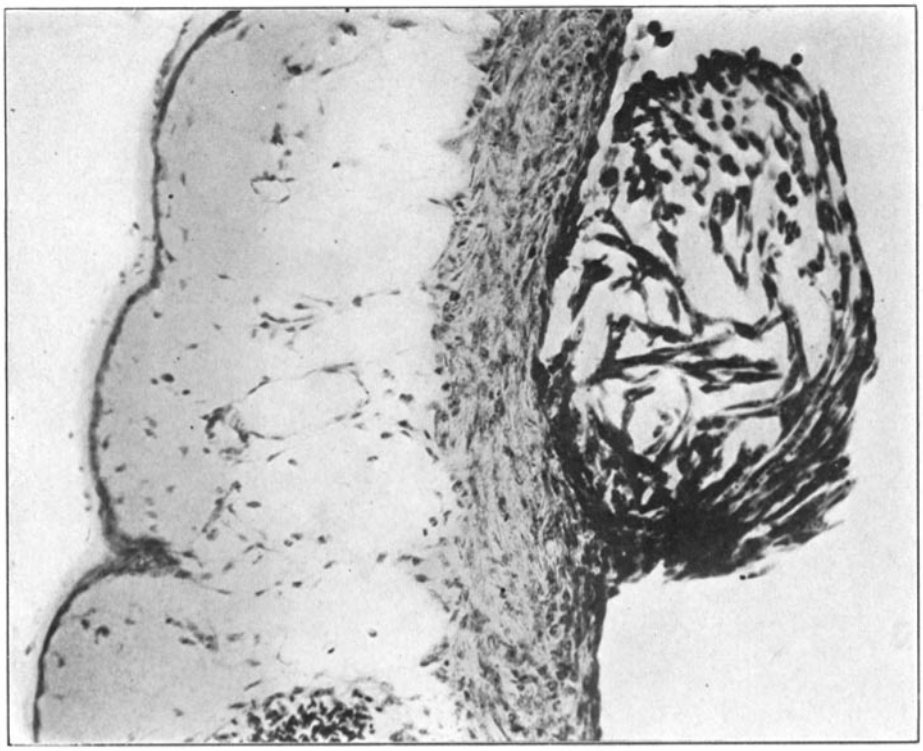

FIG. 10.

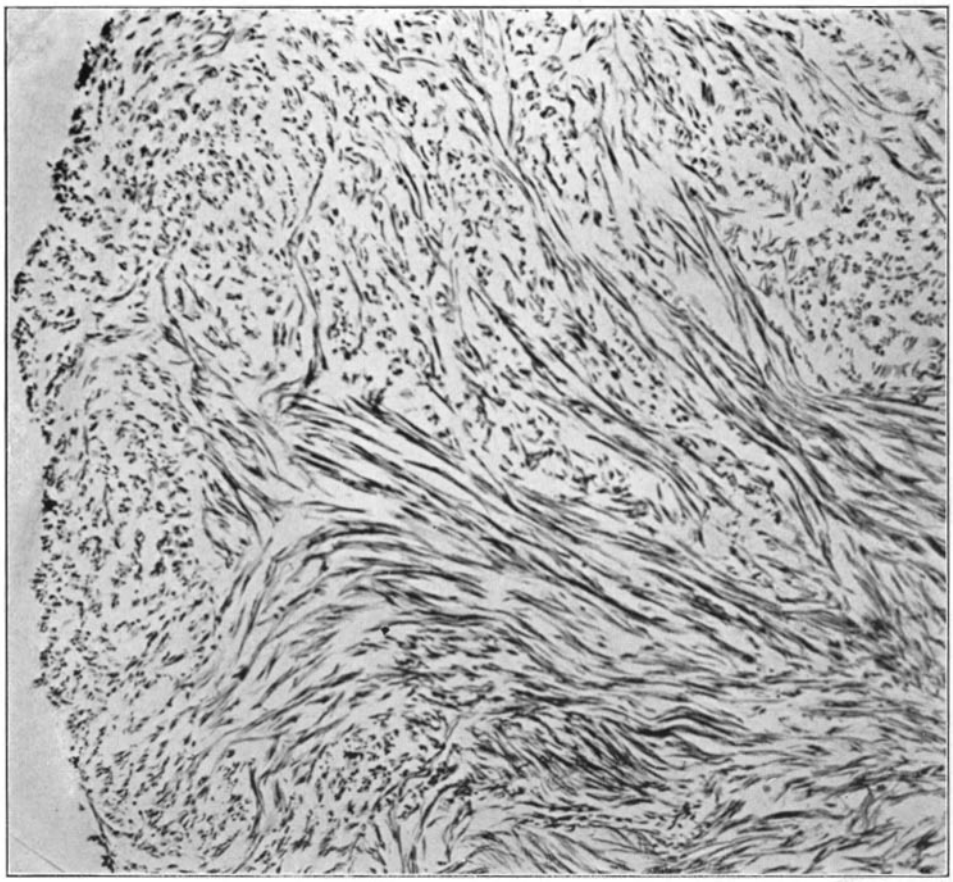

FIG. 11.

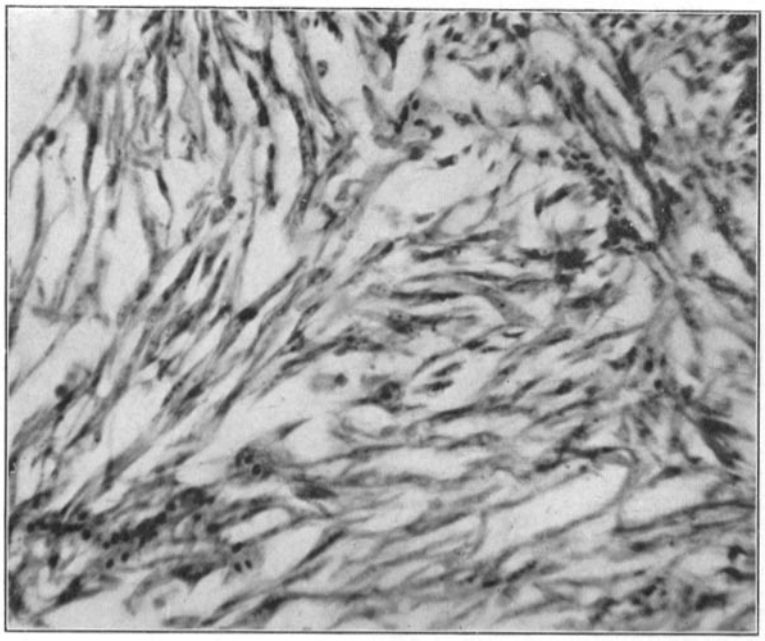

FIG. 12.