

Palatal rugae patterns as bioindicators of identification in Forensic Dentistry

Rugoscopia palatina como bioindicador de identificação em Odontologia Legal

Ismar Eduardo Martins Filho*
Sílvia Helena de Carvalho Sales-Peres**
Arsenio Sales-Peres**
Suzana Papile Maciel Carvalho***

Abstract

Human identification has been studied since century XIV and it has been increasingly advanced. The objective of this study was to simplify the method of identification by means of palatal rugae together with the incisive papilla, the median face, the shape of the arch and the tooth presence or absence. The sample was comprised of 100 models and their respective negative. Three examiners participated of the research, so the study was blind: examiner one was responsible for the election of the initial models; examiner two scanned the copies (database creation); and examiner three renumbered the models in such a manner that they were verified by examiner two and, subsequently, the coincidence of the points was evaluated for a possible identification. Digital models were examined by means of the Photoshop 7.0.1® program. The results, which were found through the analysis of non coincident points, led to a percentage of 100% certainty on the identification, making the identification of all individuals through the method proposed possible. It has been concluded that it is possible to achieve the human identification by means of palatal rugae provided that it has a previous database. It is a useful identification method of identification, taking into account the risk of five criteria that exclude the possibility of errors, since any model was coincident with another in any point.

Key words: Forensic dentistry. Patient identification systems. Forensic medicine.

Introduction

Human identification has become fundamental in all aspects of human relationships, at both social and legal levels. It allows people to preserve their rights and have their duties demanded from both civil and legal standpoints. Identification corresponds to a combination of different procedures to individualize a person or an object¹.

According to Arbenz² (1988), the identification requires demonstrating that a person or one of his or her characteristics being examined is the same as observed in a previous situation.

An important aspect refers to the distinction between recognition and identification³. Recognition may be considered as an empirical, subjective identification without scientific accuracy. In Forensic Medicine or Dentistry, it is usually visually conducted by relatives and friends of the victim, thus making this practice highly susceptible to mistakes and failures. These inaccuracies are inherent to the limitations of the method and to the emotional status of people conducting the recognition, caused by the probable loss of a loved person or by the funereal environment of forensic medical institutes⁴.

The identification is characterized by the utilization of proper techniques and means to find the identity. It may be performed by experienced technicians (law professionals or policemen) or by profes-

* Especialista em Odontologia em Saúde Coletiva pelo HRAC/USP (Centrinho/Bauru) e mestre em Odontologia em Saúde Coletiva pelo Departamento de Odontopediatria, Ortodontia e Saúde Coletiva da Faculdade de Odontologia de Bauru.

** Professores doutores do Departamento de Odontopediatria, Ortodontia e Saúde Coletiva da Faculdade de Odontologia de Bauru.

*** Mestra em Odontologia em Saúde Coletiva pelo Departamento de Odontopediatria, Ortodontia e Saúde Coletiva da Faculdade de Odontologia de Bauru.

sionals with differentiated and specific knowledge in biology (forensic medical or forensic dental), with utilization of a nearly unlimited series of techniques and means to determine the human identity⁴.

Silva⁵ (1938), Carrea⁶ (1955) and Lysell⁷ (1955) presented a system of recording the palatal rugae and incisive papillae. Lysell, as well as Sassouni⁸ (1957), believed that, in general, the palatal rugae are unchanged throughout life, but found that this does not apply in every aspect. In older subjects, there is an evident reduction in the number of rugae. Lysell⁷ (1955) therefore, was unsure if the rugae could be used for identification purposes. The age change was also stressed by⁹.

Sassouni⁸ (1957) stated that it is possible to devise a classification based on the symmetry, number and shape of papillae. When Sassouni⁸ (1957) tested the classification, he was able to identify a person without difficulty. The palatal rugae can be used in the same way as fingerprints; however, as the rugae are composed only of soft tissue, they are not present in skeletons. Fiene¹⁰ (1958) discovered that the palatal rugae could be helpful in anthropological paternity investigations.

In some patients, a prominent exostosis, the torus palatinus, is found in the palatal midline. Its presence is sometimes recorded in dental notes and, therefore, it can be used as an identification mark¹¹.

Five elementary technical requirements should be met to assure the applicability of an identification process:

- *Unicity, individuality or variability*: this is the condition of non-repetition of the combination of personal characteristics in other individuals; i.e. only one individual may present them. The first term seems the most adequate one, since it expressly mentions the fact that each individual presents different impressions from the others. There are no two identical fingerprints, not even among the fingers of a single person.
- *Immutability*: condition of inalterability of characteristics throughout life; i.e. these characteristics are not changed over time. All peculiarities of contours remain the same and are not modified in any case; the only possibility is "disarrangement" of a contour by a scar.
- *Perennity (persistence)*: this is the ability of some elements to resist to the action of time. For example, the papillary crests and consequently their contour appear before the individual is born (sixth month of intrauterine life) and only disappears with cadaveric decomposition. The palatal rugae, which appear around the third month of intrauterine life, are absolutely perennial.
- *Practicability*: this condition makes the process applicable for routine analysis. This

quality meets some requirements such as cost, easy achievement, easy recording, etc. Recording of fingerprints of an individual is simple, fast and requires few instruments. In the case of palatal rugae, its use is enhanced by the low cost and easy achievement.

- *Possibility of classification*: this quality allows the achievement and record keeping of the group of inherent characteristics that may be used for human identification, i.e. the possibility of classification to enhance filing and easy tracking in files. The previous requirements are somewhat related to the latter. In fact, the technique employed for identification might present persistence, immutability, individuality, yet would be worthless if classification was not feasible. Both fingerprints and palatal rugae may be classified to allow rational tracking of these data in files

According to Arbenz² (1988), dactyloscopy is the only method currently available that meets all these requirements; however, it lacks the quality of perennity, since it disappears after skeletization.

Existing studies on the palatal rugae pattern have addressed the comparative anatomy⁶, genetics and heredity^{7,12,13}, forensic dentistry^{6,7,12,14-17} growth and orthodontic studies^{15,18-22}, dental prosthodontics²³⁻²⁷ and anthropology.

Since the study of Lysell⁷ (1955) specific anatomical investigations on the palatal rugae pattern have been reported by at least five authors²³⁻²⁷. They report that the number of rugae remains unchanged throughout life²⁸, the size and detailed arrangement changes with palatal growth and that there are differences among ethnicities²⁸, with¹⁶⁻²⁹, or without differences between genders¹³⁻²⁸.

This study aimed to simplify the method of human identification employing the palatal rugae as bioindicators, with analysis of palatal rugae, incisive papilla and median palatal raphe, besides dental arch shape and presence or absence of teeth as complementary methods.

Subjects and method

The study was approved by the Institutional Review Board of Bauru Dental School, University of São Paulo (process number 06/2006). Written consent was obtained from the individual characters before model examination was initiated.

A probabilistic sample composed of 100 casts of orthodontically treated Brazilian patients aged 8-30 years (55 females and 45 males) was obtained from a private clinic in Bauru, Brazil. The sample size was calculated as suggested by Hauser et al.¹⁹ (1989) and Limsom³⁰ (2004).

Environmental factors leading to denture wear, tooth malpositioning and palatal pathology may

affect the palatal rugae pattern. Thus, only individuals with normal, well-formed oral structures and a reasonable complement of teeth were selected³¹.

All dental casts had been obtained from patients after completion of orthodontic treatment in the private clinic. Impressions were taken with alginate and poured with white stone, which enhanced visualization of the palatal rugae after delineation due to its white shade and hardness.

Delineation of palatal rugae

The delineation of palatal rugae was divided into three parts, including the entire size of the papilla, contour of rugae and length of the median palatal raphe, and was performed with 0.1-mm HB graphite on the dental casts. Before delineation, all bubbles on the palatal aspect of dental casts, produced when the dental cast was poured, were removed with a Le Cron instrument.

Creation of the databank

A databank was created, in which the characteristics of the palatal rugae of each dental cast were stored. The 100 dental casts were digitized with a scanner Genius ColorPage. The digitized dental

casts were stored in the PC of the investigator and copied to a CD-ROM.

Palatal rugae

Analysis comprised the palatal rugae, papilla and median palatal raphe.

The palatal rugae were also evaluated as to their thickness as pronounced (easy visualization) or faint (impaired visualization).

The incisive papilla was evaluated according to its characteristics as elliptical (egg-shaped, larger than longer); triangular (triangle-shaped with the vertex directed toward the incisors); or thin (thin and narrow shape).

The median palatal raphe was classified and recorded on the form according to its size as short (S), medium (M) or long (L), as follows. The short raphe reaches at most a virtual line touching the distal aspects of the right and left canines; the medium raphe crosses this virtual line distally to the canine and reaches at most a virtual line touching the distal aspects of the right and left second premolars; and the long raphe crosses this virtual line and reaches the first molar (Fig. 1).

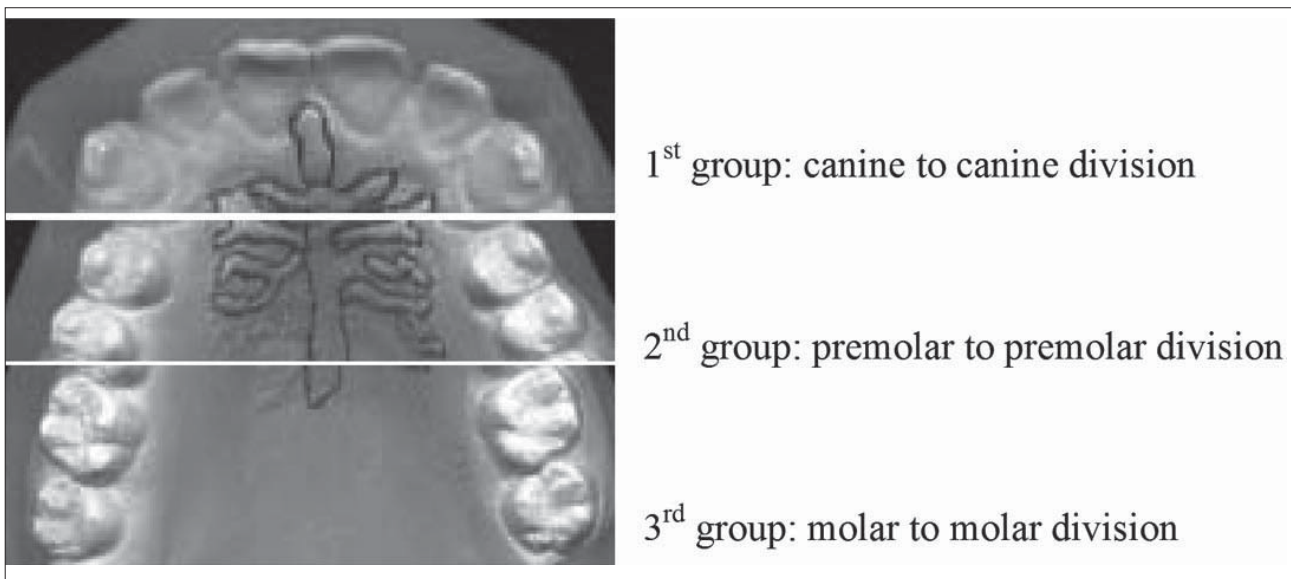


Figure 1 - Division of groups (created by the author)

Dental arch shape

Its shape depends on the alveolar arch and may present four different aspects, according to³²:

- Hyperbolic: when the dental arch segments are divergent throughout their perimeter.
- Parabolic: when the dental arch segments are divergent, yet in a less marked manner.
- Epsilon: when the dental arch segments are parallel to each other.
- Elliptical: when the dental arch segments are convergent.

Presence or absence of teeth

The presence of deciduous and permanent teeth, or the absence of any tooth, was also evaluated (Fig. 2).

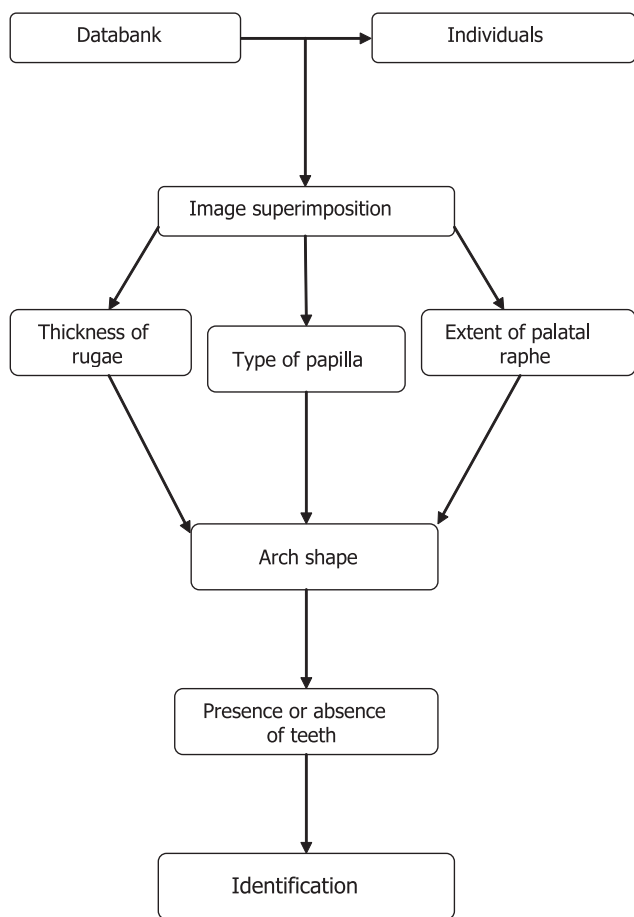


Figura 2 - Flowchart of identification

Achievement of digitized images

After cleaning and delineation, the dental casts were digitized with a scanner Genius ColorPage – HRX6 Slim, at 600 dpi resolution, with the palatal aspect turned towards and as parallel as possible to the scanner surface, in order to avoid image distortion.

Dental casts

Three examiners were selected for the experimental stage. Examiner 1 selected and numbered the dental casts from 1 to 100; then, examiner 2 digitized the dental casts. At the final stage of identification, examiner 3 randomly renumbered the dental casts from 1 to 100 and returned the dental casts to examiner 2, who once again digitized the dental casts. Finally, image superimposition was performed, thus completing the experimental stage.

a) *Utilization of the databank.* At this stage, the databank created from the 100 dental casts was used.

b) *Dental cast identification.* Image superimposition was performed with the software Photoshop 7.0.1; the images were stored in the PC of examiner 2 and copied to a CD-ROM.

c) *Relationship between the databank and renumbered dental casts.* The renumbered dental casts were compared with those existing in the databank to identify the individual.

d) *Analysis of 5 criteria for identification.* Five criteria were analyzed: palatal rugae, incisive papilla, median palatal raphe, dental arch shape and presence or absence of teeth.

Statistical analysis

Descriptive analysis was performed by calculation of relative and absolute frequencies, which were plotted on graphs.

Results

The most important results are described at Figures 3 to 8.

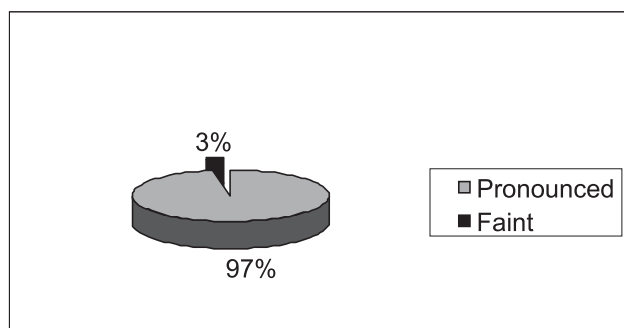


Figure 3 - Percentage of palatal rugae according to their thickness

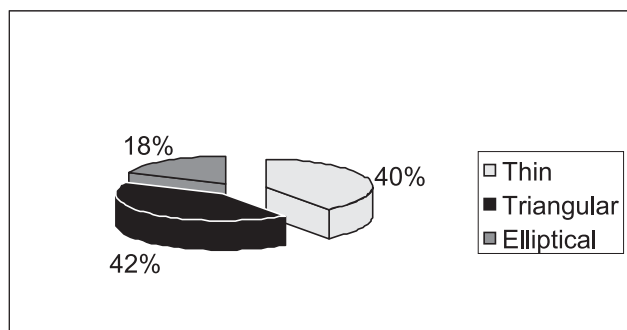


Figure 4 - Percentage of types of incisive papillae

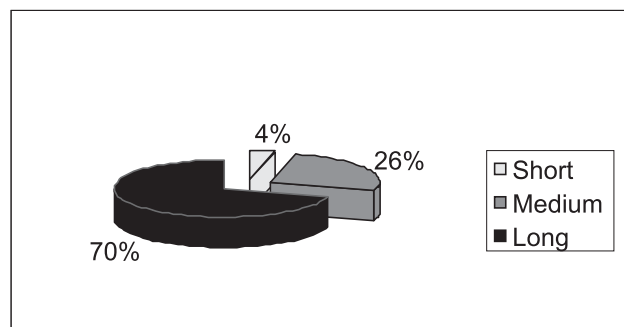


Figure 5 - Percentage of extent of the median palatal raphe, according to its location

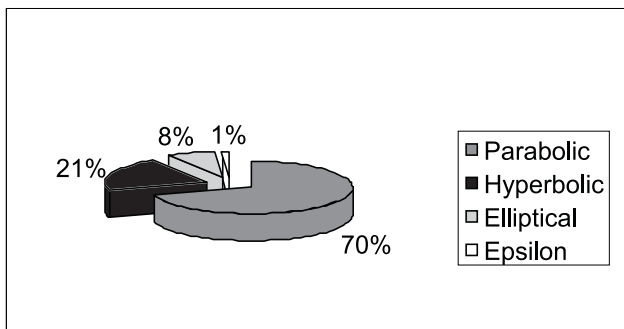


Figure 6 - Percentage of types of dental arch

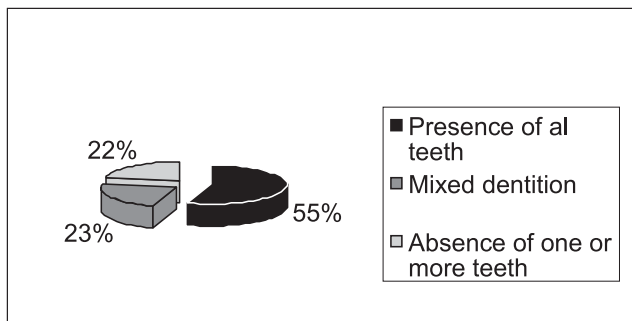


Figure 7 - Percentage of presence or absence of teeth

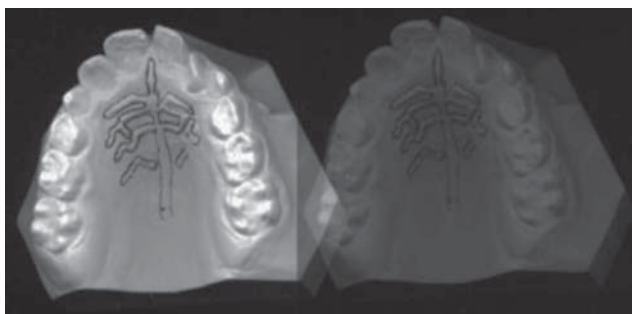


Figure 8 - Image superimposition

Discussion

Many attempts have been made in order to find out safe means for human identification that may allow recognition, avoidance or detection of errors and simultaneously preclude changes or alterations of numbers or individuals³³.

Several signaling processes have been proposed for human identification, some of which are good but complicated, while others are bad and present failures

The traditional methods for human identification include anthropometry, fingerprints, gender determination, age estimation, weighing, and identification by specific characteristics, and blood group differentiation.

Many scientific methods have been published, such as the investigation of bite marks and of the jaws. However, not only the teeth and bones are useful for identification; investigation of mucosal tissues is also important, since these structures pro-

vide interesting data for identification, such as the hard palate and lips, by means of investigation of palatal rugae pattern (rugoscopy) and cheiloscopy.

The analysis of human palatal rugae has been suggested as an alternative method for identification in 1889 by Allen³⁴ (1889). English et al.³⁵ (1988) conducted a study to identify 25 individuals undergoing orthodontic treatment. One hundred dental casts were obtained from these patients and identification was then performed by nine examiners by analysis of the palatal rugae pattern. They concluded that the palatal rugae pattern is characteristic enough to differentiate among individuals.

Hauser et al.¹⁹ (1989) investigated 117 dental casts of individuals from Swaziland aged 12 to 60 years; impressions were obtained from these individuals with addition silicone and the dental casts were poured in plaster. The examiners delineated the palatal rugae and photographed the dental casts. Prominent rugae were observed on the dental casts of this population; the palatal rugae patterns were very similar, since this population is highly homogeneous.

Dental casts have also been used by Limsom³⁰ (2004). Utilization of dental casts presents the advantages of simple analysis, reduced cost and easy achievement in any laboratory; this corroborates the routine work of Brazilian forensic medical institutes, which do not have many resources available to buy sophisticated equipments and materials.

The databank was created from 100 dental casts on the basis of previous studies; consequently, this number is incompatible to constitute a databank for Brazilian standard, which would require a larger sample to represent the population.

The utilization of digital photography, personal computers and specific softwares to edit and use digital images allows a significant improvement in the recognition and identification of individuals; thus, it may be stated that the proposed model allows easy handling.

Kogon and Ling¹⁷ (1973) described a technique of superimposition of photographs that may easily be applied with conventional photography equipment for comparison of palatal rugae. To enhance the identification method, image superimposition was performed on the software Photoshop 7.01.

Considering the benefits of the digital photography cameras use, this procedure would be less costly to forensic medical institutes and public security secretariats, which are in charge of personal identification of citizens, since no photographic films and film development are necessary; this is a fast procedure and does not require specific skills.

Utilization of palatal photographs would be highly viable; however, this would require the development of a specific software for image superimposition and location of landmarks to allow identification.

Analysis of palatal rugae

The present study initially created the data-bank, which was compared to the 50 nominated individuals who were classified and excluded or not by analysis of the palatal rugae.

Souza Lima³⁶ (1964) assessed dental casts of individuals submitted to orthodontic treatment, whose dental casts were obtained at treatment onset and completion to control the evolution of the several types of malocclusion. The author concluded that there are no changes in the morphology or arrangement of palatal rugae. Individuals submitted to surgery exhibited a mild reduction of space among the rugae or even shortening or elongation, depending on the extent of the intervention performed. There was no remarkable damage in any such case.

However, it should be highlighted that the palatal rugae may be changed by different factors, such as wearing complete dentures, procedures that may cause trauma, cleft palate, fibrous tissue, and "calluses"; however, these factors do not impair identification. On the other hand, cleft palate and some surgeries, for example, may be even better, a more effective and often definitive aid for identification.

Dental arch

After the accomplishment of the comparative study of the palatal rugae, the dental arch was assessed and classified as hyperbolic, parabolic, elliptical or epsilon, according to the classification of Testut³² (1944).

Most dental arches in this study were hyperbolic and parabolic, with lower frequency of elliptical and epsilon shapes. The following distribution was observed: 70% hyperbolic, 21% parabolic, 8% elliptical and 1% epsilon.

The presence or absence of teeth was also used as a criterion for classification, since the absence of some teeth is also characterized as an identification method, even though few individuals in this sample showed absence of teeth.

Utilization of the five criteria proposed in this study allows human identification, considering that tooth structures represent signaling elements. The individuality and singularity of the palatal rugae, median palatal raphe, incisive papilla, absence or presence of teeth may be accepted, with standardization and uniformity in data production and collection.

Conclusion

Thus, analysis of palatal rugae pattern combined to the other methods is an important alternative and complementary technique for human identification, providing a significant contribution in cases of criminal investigation.

Resumo

A identificação humana tem sido estudada desde o século XIV e a cada dia se torna mais avançada. O objetivo deste estudo foi simplificar o método de identificação por meio das rugosidades palatinas, envolvendo a papila incisiva, a face mediana, a forma do arco e a presença ou ausência dentária. A amostra foi constituída de cem modelos e seus respectivos negativos. Três examinadores participaram da pesquisa, de forma que o estudo foi cego: o Examinador 1 foi responsável pela eleição dos modelos iniciais; o Examinador 2 confeccionou as cópias em scanner (criação da base de dados); o Examinador 3 renumerou os modelos de maneira que fossem verificados pelo Examinador 2 e, na sequência, a coincidência dos pontos foi analisada para a possível identificação. Os modelos foram digitalizados e examinados por meio do programa Photoshop 7.0.1[®]. Os resultados, encontrados por meio da análise dos pontos não coincidentes, levaram a uma percentagem de 100% de certeza na identificação, sendo possível a identificação de todos os indivíduos por meio do método proposto. Conclui-se que é possível realizar a identificação humana por meio das rugosidades palatinas, desde que se disponha de uma base de dados prévia; é um método útil de identificação, levando em conta cinco critérios que excluem a possibilidade de erros, uma vez que nenhum modelo foi coincidente com outro em qualquer ponto.

Palavras-chave: Odontologia forense. Sistemas de identificação dos pacientes. Medicina forense.

References

1. Vanrell JP. Odontologia legal e antropologia forense. Rio de Janeiro: Guanabara Koogan; 2002.
2. Arbenz GO. Medicina legal e antropologia forense. São Paulo: Atheneu; 1988.
3. Silva M. Compêndio de Odontologia Legal. 4. ed. Rio de Janeiro: Artes Médicas; 1997.
4. Oliveira RN, Daruge E, Galvão LCC, Tumang AJ. Contribuição da odonto-legal para a identificação post-mortem. RBO 1998; 55:117-22.
5. Silva L. Ficha rugoscópica palatina. Brasil Odonto 1938; 14:307-16.
6. Carrea JU. Gaumenfalten-Fotostenogramme, ein neues identifizierungsverfahren. Deutsch Zahnärztliche Zeitschrift 1955; 10:11-7.
7. Lysell L. Plicae palatinae transversae and papilla incisiva in man. A morphologic and genetic study. Acta Odontol Scand 1955; 13:35-47.
8. Sassouni V. Palato print, physioprint and roentgenographic cephalometry as new methods in human identification (preliminary report). J Forensic Sciences 1957; 2:428-42.
9. Dahlberg AA. Conference on genetic aspects of oral structures introduction. J Dent Research 1963; 42:1260-1.
10. Fiene M. Vergleichend-morphologische studien über das Gaumenfaltenrelief von Zwillingen. Fortschr Kieferorthop 1958; 19:229-36.
11. Gustafson G. Forensic Odontology. New York: American Elsevier Publishing Company; 1966. p. 43-4.
12. Keil A. Grundzüge der Odontologie. Berlin: Gebrüder Borntraeger; 1966. p. 118-9.

13. Bamberadeniya K. A study of the rugae pattern and the shape of the incisive papilla in a Sri Lankan population. *Sri Lanka Dent J* 1978; 9:11-23.
14. Krefft S. Die Gaumenfaltenphotostenogramm-Method in der gerichtsmedizinischen identifizierungspraxis und alternativvorschläge zur sicheren personenfeststellung bei unkenntlichen leichen. *Deutsche Zahnärztliche Zeitschrift* 1968; 23:509-15.
15. Antonopoulos AN. The palatal rugae as a guide in the correct arrangement of upper anterior teeth in complete denture construction. *Odontostomato Prodos* 1972; 26:44-60.
16. Comoy JP. La rugoscopie. *Le Chirurgien Dentiste de France* 1973; 43:59-60.
17. Kogon SL, Ling SC. A new technique for palatal rugae comparison in forensic odontology. *Canadian Soc Forensic Science J* 1973; 63:3-10.
18. Friel S. Migration of teeth. *Dent Record* 1949; 69:74-84.
19. Hauser G, Daponte A, Roberts MJ. Palatal Rugae. *J Anat* 1989; 165:237-49.
20. Leuret L. Growth changes of the palate. *J Dent Research* 1962; 41:1391-404.
21. Peavy DC, Kendrick GS. The effects of tooth movement on the palatine rugae. *J Prosthet Dent* 1967; 18:536-42.
22. Van der Linden FPGM. Changes in the position of posterior teeth in relation to ruga points. *Am J Orthod* 1978; 74:142-61.
23. Nidoli G, Ossido G. Riproduzione delle rughe palatine in protesi. *Rassegna Internazionale di Stomatologia Pratica* 1967; 18:147-51.
24. Tassarotti B. Funzione fonetica e rughe palatine. *Dental Cadmos* 1968; 36:633-47.
25. Gerhke W, Marxkors R. Gaumenfaltenmuster und natürliche Frontzähne. *Das Deutsche Zahnärzteblatt* 1979; 24:273-6.
26. Toker KM, Pearson OW. Relationship of tooth position to maxillary ridge anatomy. *J Dental Research* 1971; 50:347-9.
27. Fuhr K, Keil W. Investigation of the relationship between natural teeth and pattern of palatal rugae (abstract). *Quintessence Int* 1975; 6:47-50.
28. Thomas CJ. Incidence of primary rugae in Bushman juveniles. *J Dent Res* 1972; 51:656.
29. Tzatscheva L, Jordanov J. Plicae palatinae transversae und papilla incisive bei den Bulgaren. *Zeitschrift für morphologie und anthropologie* 1978; 62:276-84.
30. Limsom KS. Computerized recording of the palatal rugae pattern and evaluation of its application in forensic identification. *J Forensic Odonto-stomatology* 2004; 22.
31. Thomas CJ, Kotze TJW. The palatal ruga pattern in six southern african human populations. Part I: a description of the populations and a method for its investigation. *J Dental Association of South Africa* 1983; 38(3):158-65.
32. Testut L. *Tratado de Anatomia Humana*. Barcelona: Salvat Editores; 1944.
33. Moya V, Roldán B, Sánchez J. *Odontologia legal y forense*. 1. ed. Barcelona: Masson; p. 277-92.
34. Allen H. The palatal rugae in Man. *Dental Cosmos* 1889; 31:66-80.
35. English WR, Robinson SF, Summit JB, Oesterle LJ, Brannon RB, Morlang WN. Individuality of human palatal rugae. *J Forensic Sci* 1988; 65:43-8.
36. Souza Lima J. *Considerações sobre o estudo das rugosidades palatinas [Tese de Doutorado]*. Belo Horizonte: Faculdade de Odontologia de Minas Gerais; 1964. 101 p.

Corresponding author:

Ismar Eduardo Martins Filho
 Rua Aviador Ribeiro de Barros, 4-20,
 Bl. 2, Apto 13
 17017-490 Bauru - SP
 Fone: (14) 3227-6404
 E-mail: ismarfilho@ig.com.br

Recebido: 16/12/2008 Aceito: 09/07/2009