ORTHORADIOGRAPHY OF THE HEART AND AORTA.

By W. HOPE FOWLER, M.B., F.R.C.S.,
Senior Medical Officer in Charge of the Electrical Department,
Royal Infirmary,
and
W. T. RITCHIE, M.D., F.R.C.P.,
Assistant-Physician, Royal Infirmary.

Apparatus and Technique.—The source of energy we employ for the X-ray tubes is a Snook High Tension Transformer. The orthoradiograph is Groedel's modification of the Levy-Dorn apparatus.

The Snook apparatus, invented by Snook of Philadelphia, introduced by Dr. Leonard into this country, and made by Newton of London, enables this work to be carried on with a minimum of difficulty. It consists of three parts:—The main current, a constant one, is converted into an alternating one by means of a motor convertor or inverted rotary. This interrupted current is fed into the primary of a step-up transformer, which is immersed bodily in a galvanised iron tank filled with an insulating oil. The secondary current is conducted to the high tension rectifier, which, being on the same axle as the rotary, permits of our using the current of right polarity to light up the X-ray tube.

It is possible at the same time to make use of the inverse, or current of wrong polarity, but it is better to eliminate that by a simple arrangement of switches. In the secondary circuit there is developed a current of 10,000 to 125,000 volts, at a milliamperage of 1·5 to 30 or 40 m.a., therefore useful for all purposes—radioscopy, instantaneous or distance radiography. With a current strength of from 2·5 to 5 m.a. we can keep our tubes working for lengthy periods without damage.

The Groedel modification of the Levy-Dorn apparatus, a diagram of which is shown in Fig. 1, consists, firstly, of a heavy upright supporting a quadrilateral framework, in which move the supports bearing the two arms on which are fixed the tube and screen, so balanced that it is a simple matter to move screen and tube in all directions in reference to the patient. The centre of the tube, centre of screen, and pneumatic pen are brought into alignment and firmly fixed. The resultant is a parallel projection of rays, which is carried round the organ under examination, and the outline is made by means of the pen on a sheet of paper fixed to the heavy board at the back of apparatus.

To sum up, by the term orthoradiography is meant the more or less exact measurement of various objects, outlines of which are thrown on to a fluorescent screen by a pencil of X-rays. To obviate the distortion produced by the X-rays, which are propagated from the focal point of the anticathode in straight lines in the form of a divergent cone, it is necessary first of all to eliminate all but the central or ray of normal incidence, and after finding this, it is carried round the outline of the object, in this case the heart and great vessels, and a record is made of the silhouette.

Technique.—If satisfactory observations are to be made, it is necessary that the room in which the examination is conducted should be absolutely dark. Even a small amount of light issuing from any source in front of the observer tends to render his work more difficult and his results less reliable. While each examination is being made, the patient, stripped to the waist, is sitting erect on the orthodiagraph chair, and he faces the fluorescent screen and the observer, so that the sagittal direction of the rays is dorso-ventral. In order to keep the patient's body as far as possible in one fixed position during the whole observation, the clamps at each side of the orthodiagraph chair are firmly applied either to the chest wall or to the upper arms kept in apposition with the latter. The observer, having put on his protective lead-rubber apron and gloves and lead-glass spectacles, sits on a high stool in front of the patient and adjusts the fluorescent screen so that it is as close as possible to the anterior surface of the patient's chest without actually touching it. The lights are then switched off. After absolute darkness has been maintained for about five minutes, in order to render the observer's retina as sensitive as possible, he takes the fluorescent screen in one hand and the bulb of the pneumatic pen in the other; the tube is lighted up, and the observation commences.

At the start the screen is moved rapidly in front of the whole precordial region in order to obtain a general idea of the position, form, and size of the patient's heart. After this preliminary inspection, which need not last more than a few seconds, the patient is directed to hold his breath, and the record is taken. We commence by marking from right to left the upper border of the liver. The fluorescent screen is moved so that its opaque lead central spot coincides in succession with points upon the upper margin of the shadow of the liver, and each of those points is marked upon the surface of the paper by means of the pneumatic

pen. The screen is then carried upwards, its central spot following the right margin of the shadow of the heart and great vessels, then over the apex of the right lung and down its outer margin to the starting-point. The patient is now directed to breathe once or twice, and then to hold his breath again, in the same phase of respiration as that obtaining previously. While he does so the upper limit of the diaphragm on the left side, the outer border and apex of the left lung, and the left margin of the shadow thrown by the great vessels and the heart are marked successively on the paper. We find it most satisfactory to take the record at moments corresponding to full diastole and while the patient is holding his breath at the end of a tranquil inspiration, and subsequently, before switching off, to record the chief points of the cardiac outline during full inspiration and full expiration respectively. If the observer has had some experience in the technique, and if the case presents no special difficulty, such as that occasioned by pulmonary œdema, pleural thickening, or enlarged mediastinal glands, the time required to obtain a simple record of the outline of the heart, lungs, and diaphragm need not exceed thirty seconds. A somewhat longer time is necessarily required if we desire to record the form of the heart during different phases of respiration.

The current having been switched off, the lights are turned on, the percussion outlines of the heart and liver are mapped out upon the patient's chest wall, the fluorescent screen is replaced by the pointer, and by means of the latter, together with the pneumatic pen, the surface outline of the patient's chest, the percussion outlines and important landmarks, such as the episternal notch, the level of the third chondro-sternal articulation, the nipples, the apex-beat, the xiphisternum, the umbilicus, and the lower margins of the ribs anteriorly are marked upon the paper. In many instances it is well to supplement the dorso-ventral examination by screening the patient in various oblique positions, in order to determine more fully the relative size of the different cardiac chambers and to confirm or disprove the presence of an aortic aneurysm.

The Normal Heart.—On dorso-ventral illumination the lateral outlines of the normal heart are clearly and sharply demarcated by contrast with the clear area of the lung on either side. The cardiac outline, although varying somewhat in different patients, according to the sex, age, and weight of the person, the conformation of the chest, and the position of the diaphragm, is of ovoid form, with its long axis directed obliquely downwards from right

to left. On frontal illumination the long axis is directed from above downwards and forwards. On dorso-ventral illumination the long axis tends to be vertical in young persons, whereas it is more horizontal in old age. On the right side the outline presents two curves (Fig. 2). The right lower curve is formed by the right auricle. We regard the right upper curve as being formed by the superior vena cava, and not by the aorta, as stated by Franz M. Groedel.[1] The feeble pulsation or the frequent absence of pulsa-

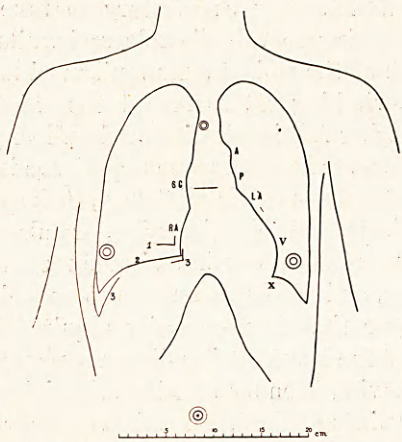

FIG. 2.—NORMAL HEART, FEMALE PATIENT, AGED 32.

1. In deep expiration. 2. In tranquil inspiration. 3. In deep inspiration. *A*, Curve of aorta. *P*, Pulmonary curve. *LA*, Left auricular curve. *V*, Left ventricular curve. *SC*, Curve of superior vena cava. *RA*, Curve of right auricle. The position of the episternal notch, level of third chondro-sternal articulation, the nipples and umbilicus shown. *X* indicates the position of the apex-beat.

tion in the right upper curve in health are presumptive evidence that the normal aorta does not take part in the formation of this curve; and of the correctness of this belief we have satisfied ourselves by inspection of the relations of the superior vena cava and aorta in the cadaver. On the left side there are three, or sometimes four, curves, formed from below upwards by the left ventricle, the left auricular appendix, the conus arteriosus or pulmonary artery, and the arch of the aorta (Fig. 2). In one case of mitral disease with auricular fibrillation the curves which we had marked as left auricular and pulmonary were found at the post-mortem examination to be formed by the left auricular appendix and conus arteriosus respectively. In another

case, one of exophthalmic goitre with marked chronic interstitial myocarditis, the four orthodiagraphic curves on the left side were seen post mortem to be constituted by the left ventricle, the conus arteriosus, the pulmonary artery, and the aorta. In this case the left auricular appendix lay wholly behind the heart.

With the exception of the right upper curve, which is not infrequently somewhat difficult to demarcate precisely, all the curves are clearly defined on the orthodiagraph screen. The left auricular curve in health is often small and inconspicuous. The normal pulmonary curve is larger than the left auricular, but it does not project outwards very prominently. The aortic curve is more marked in adults than in youth, and becomes more pronounced in old age, but the curve of the normal aorta never extends upwards beyond the episternal notch.

Pulsations.—The extent of pulsation of the right auricle, as revealed by the systolic and diastolic excursions of the right lower curve, is slight. In the right upper curve of healthy persons pulsation is either wholly absent or very feeble. There is usually a striking contrast between this phenomenon and the obvious jugular pulsation in the right side of the neck when the patient is recumbent; probably the difference is mainly of postural origin. On the left side the pulsation of the aortic curve is normally greater than that of the pulmonary. The left auricular curve, if present, manifests merely slight pulsatile movement, which it is usually difficult to time definitely as presystolic. The left ventricular curve exhibits the most extensive pulsation. This is particularly evident in the apical portion of the ventricle, where the difference between the margin of the cardiac shadow in systole and in diastole may exceed 1 cm. The apex is the most difficult part of the ventricle to define exactly, for its shadow not merely manifests more ample pulsatile movements, but is also fainter than that of the rest of the ventricle.

Respiratory Movements.—The respiratory movements of the heart are more extensive than the pulsatile. The heart is indeed a freely mobile organ. A consideration of the anatomical relations of the heart, pericardium, and diaphragm indicates that during inspiration the heart becomes longer and narrower, both the apex and the right auriculo-hepatic angle moving downwards and inwards. During expiration, on the contrary, the heart becomes shorter and broader. During tranquil respiration these changes in the form of the heart are more evident at the apex than on the right side, and are of comparatively limited extent. On deep respiration the

change in form is much more obvious, and affects not only the apex and left border, but also the auriculo-hepatic angle and right border of the heart. Fig. 3 illustrates the change of the heart's outline during deep respiration. In this instance the right auriculo-hepatic angle moved 3·2 cm. upwards between full inspiration and full expiration, while the ventriculo-diaphragmatic angle on the left side moved 4·2 cm. upwards and 2·3 cm. outwards, and the main portion of the border of the left ventricle above the apex lay 2·0 cm. further to the left in full expiration than in full

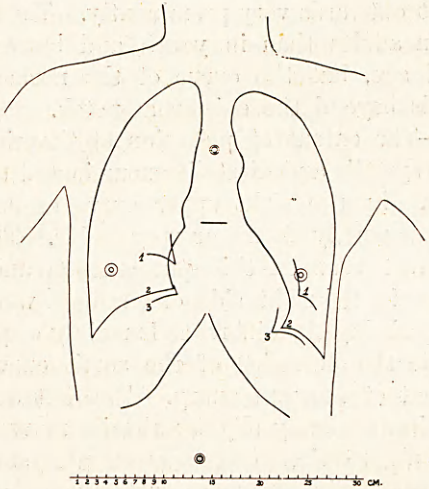

FIG. 3.—MEDICAL STUDENT, AGED 22, TOBACCO ANGINA.

1. In deep expiration. 2. End of tranquil inspiration. 3. Deep inspiration.

inspiration. In another case, a healthy medical man, aged twenty-six, the full respiratory excursion of the right auriculo-hepatic angle was 4·5 cm. and that of the left ventriculo-hepatic angle was 3·8 cm. in the vertical plane, while the respiratory excursion of the left border was 2·5 cm. in the horizontal plane. In other instances the respiratory excursion of the left border did not exceed 1 cm., and in some patients with comparatively limited diaphragmatic movements the respiratory excursion of the left border of the heart did not exceed half a centimetre. As a rule, however, the form of the cardiac outline changes in a striking manner with each deep respiration, and as tranquil respiration is associated with changes of similar nature, although of lesser degree, it is evident that an orthodiagram of a heart loses much of

its value, and may even be misleading, if we do not know in what phase of respiration the record was obtained.

Measurements.—Groedel's[1] methods of measuring the orthodiagraphic silhouette are the simplest and most satisfactory. The long diameter (L.D.) is the distance of the superior cavo-auricular angle from the apex. The maximum distance of the right and left borders respectively (M.R. and M.L.) from the mesial line are also measured, and the sum of these constitutes the transverse diameter (T.D.). The ratio between the size of the heart and the height of the individual is inconstant; that between the size of the heart and the body weight is more constant. Even in health, however, the actual measurements of the heart vary within considerable limits. That the chief factors determining these differences are the sex, age, and weight of the individual is shown by the tables recorded by Groedel,[1] and by Claytor and Merrill.[2] According to Groedel, the average figures for healthy males are—L.D. 14·0, M.R. 4·6, M.L. 8·4, T.D. 13·0; and for females—L.D. 12·9, M.R. 3·9, M.L. 8·0, T.D. 11·9 cm. Claytor and Merrill give the following as average measurements for healthy males:—L.D. 13·7, M.R. 4·0, M.L. 8·1, T.D. 12·1 cm.; and for females—L.D. 12·5, M.R. 3·4, M.L. 7·8, T.D. 11·1 cm. We have used these figures as rough standards wherewith to compare the measurements of our own series of cases. In some instances we have also employed the method of Levy-Dorn and Möller,[3] who take measurements from the patient's right fist as standards for the normal size of his heart. Two measurements are taken—(*a*) from the ulnar side of the metacarpo-phalangeal joint of the little finger to the dorsal surface of the interphalangeal joint of the thumb, and (*b*) the sum of the hand's-breadth and the length of the first phalanx of the middle finger. The length of the normal heart, according to Levy-Dorn and Möller, is on an average 1 cm. less than the figure obtained by either of these two measurements.

But even when allowance has been made for sex, age, and weight, the measurements of the healthy heart may differ considerably, and, moreover, the distance of the apex and left border from the mesial plane varies according to the phase of respiration in which the record was obtained, and consequently we do not feel justified in regarding a heart as enlarged merely because it exceeds by a few millimetres the average for sex, age, and weight.

The Form of the Heart in Pathological Conditions.—Morbid

affections of the heart are more readily detected by alteration of form than by variations in size alone. Not only do one or more of the curves forming the cardiac silhouette often present departures from the normal, but each cardiac lesion is as a rule associated with more or less characteristic changes in the outline, some of which we now proceed to consider.

Mitral Incompetence.—In slight cases, with only lesser signs of cardiac enfeeblement and with compensation fairly well established, we find that the cardiac outline does not present any marked abnormality, except perhaps a slight increase in the prominence of the left auricular or pulmonary curves. If compensation is less fully established these curves become more pronounced. In cases presenting signs of obvious cardiac failure we find a more or less general enlargement of the heart's outline, the left ventricular curve being increased and passing upwards into an unduly prominent curve, which it may be impossible to identify as auricular or pulmonary, except by the character and time of its pulsation. The right auricular curve in cases of simple mitral incompetence is not usually markedly excessive. In our cases of pure mitral incompetence the largest heart was that of a man, aged 50, presenting no cyanosis or œdema, in whom the measurements were L.D. 19·7, M.R. 6·7, M.L. 11·6, and T.D. 18·3 cm. When the tricuspid valve becomes incompetent as well as the mitral we find the heart enlarged in all its diameters. Thus in a man aged 34 the measurements were L.D. 18·0, M.R. 5·5, M.L. 12·0, and T.D. 17·5 cm. In these cases the right auricular curve often bulges outwards very considerably; but in many instances the precise outline of the heart is difficult to determine because of pulmonary œdema.

Mitral Stenosis.—The orthodiagraphic picture of mitral stenosis varies not only according to the degree of associated mitral incompetence, but more markedly according as to whether the auricular musculature is contracting in a co-ordinate fashion or is in fibrillation. In mitral stenosis, if the auricles are contracting at their proper time in the cardiac cycle, a presystolic murmur is usually audible, and the pulse is either rhythmic or at least not wholly arrhythmic. In such cases the orthodiagraphic picture often reveals a somewhat vertical heart (Figs. 4, 5), in which the striking feature is the particularly clear demarcation of the curves from one another. At the same time we observe that the right auricular, the left auricular, and the pulmonary curves are enlarged, especially the latter, and that in some instances the

curve of the left ventricle is small (Fig. 4). Orthodiagrams demonstrate more clearly than is possible by percussion that the relative size and distension of the cardiac chambers *intra vitam* are closely comparable to those found at post-mortem examination. We have also been able to gauge the progress of some of our

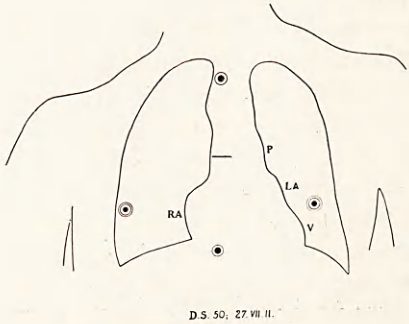

FIG. 4.—MALE, AGED 50, MITRAL STENOSIS, WITH PHYSIOLOGICAL RHYTHM.

cases, and to determine the efficacy of treatment, by comparing orthodiagrams taken at intervals during the patients' stay in hospital. Unless the changes in form and size of the heart's

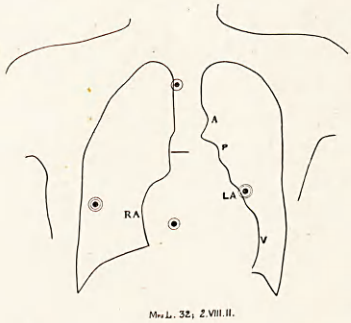

FIG. 5.—FEMALE, AGED 32, MITRAL STENOSIS, WITH PHYSIOLOGICAL RHYTHM.

The pulmonary curve is particularly prominent.

outline are well marked, however, we must be cautious in drawing hasty conclusions from orthodiagrams, because an apparent diminution in the size of the heart may be due, at least in part, to the record having been obtained in a different phase of respiration than when the earlier record was taken.

Auricular Fibrillation.—Cases of auricular fibrillation, with or without mitral stenosis, present a large globular heart in nearly

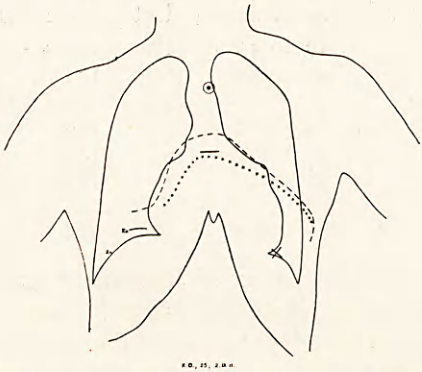

FIG. 6.—FEMALE, AGED 25, MITRAL STENOSIS, WITH AURICULAR FIBRILLATION.

A large globular heart.
- - - - - - The deep percussion dulness of the heart.
× × × × × × The superficial percussion dulness.

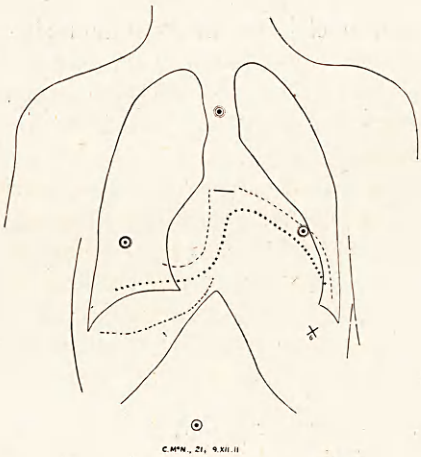

FIG. 7.—MALE, AGED 21, AURICULAR FIBRILLATION.

Record taken during tranquil respiration.
- - - - - - The deep percussion dulness.
× × × × × × The superficial percussion dulness in full expiration.
— · — · — · — The superficial percussion dulness in full inspiration.

every instance of our series (Figs. 6 and 7). In ten consecutive cases the following measurements were recorded:—

Sex	Age	M.R.	M.L.	T.D.	L.D.
Male . .	21	4·5	12·0	16·0	18·0 cm.
,, . .	24	6·2	10·4	16·6	18·5 ,,
,, . .	27	5·2	9·6	14·8	15·8 ,,
,, . .	31	5·0	9·0	14·0	15·0 ,,
,, . .	40	6·7	12·3	19·0	19·5 ,,
,, . .	45	4·5	10·2	14·7	14·0 ,,
Female .	25	6·8	7·3	14·1	14·0 ,,
,, .	34	6·7	10·1	16·8	18·9 ,,
,, .	40	8·4	8·5	16·9	17·5 ,,
,, .	45	4·0	7·9	11·9	13·2 ,,
Average		5·8	9·7	15·4	16·4 ,,

The right auricular curve is lengthened and projects prominently to the right. The left margin is displaced outwards. The curves of the left auricle and the pulmonary artery are either markedly prominent, bulging outwards and upwards towards the left axilla, or, if the dilatation of the left auricle and right ventricle be still more excessive, these curves become fused with each other and with that of the left ventricle. In auricular fibrillation the globular form of the heart is most pronounced in those patients who present such signs of cardiac failure as dyspnœa and cyanosis, yet the globular heart may be observed in cases with relatively trivial cardiac symptoms. In exceptional instances patients who present auricular fibrillation, but who are able to be up and to go about the ward, do not show the globular form of heart, and in them the pulmonary and right and left auricular curves are only moderately enlarged.

Aortic Incompetence.—In cases of simple aortic incompetence the heart is usually but not constantly enlarged. In some cases we found that the form of the cardiac outline did not differ very materially from the normal; in others the long axis of the heart was even more vertical than normal; but in grave cases the "recumbent egg-form" described by Groedel may be seen. In eight cases the following measurements were recorded:—

Sex	Age	M.R.	M.L.	T.D.	L.D.
Male . .	23	4·7	7·5	12·2	14·4 cm.
,, . .	38	4·8	7·8	12·6	15·7 ,,
,, . .	38	5·0	8·0	13·0	16·0 ,,
,, . .	41	5·0	9·2	14·2	14·5 ,,
,, . .	49	5·1	11·4	16·5	18·9 ,,
,, . .	51	5·6	12·5	18·1	17·8 ,,
,, . .	58	5·0	10·3	15·3	16·5 ,,
,, . .	68	4·1	8·7	12·8	14·0 ,,
Average		4·9	9·4	14·3	15·9 ,,

When we compare these measurements with those from cases with auricular fibrillation, it is found that the average measure-

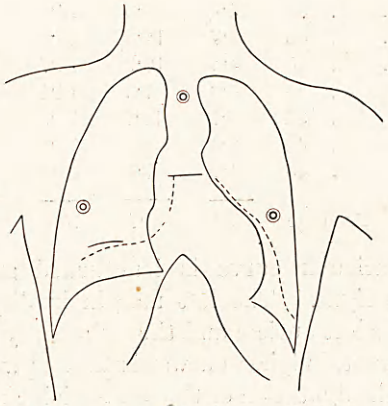

FIG. 8.—MALE, AGED 23, AORTIC INCOMPETENCE.

- - - - - - The deep dulness.

ments in uncomplicated aortic incompetence are less than those in auricular fibrillation.

Although the form of the cardiac outline is not uniformly

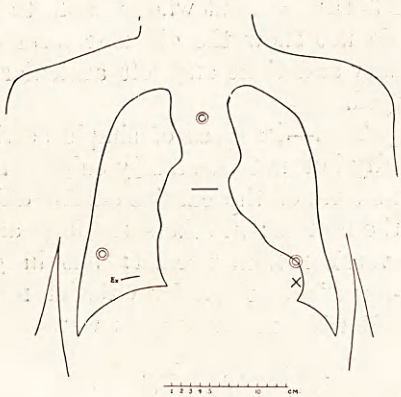

FIG. 9.—MALE, AGED 58, AORTIC INCOMPETENCE.

X, The position of the apex-beat. *Ex*, Upper margin of shadow of liver in full expiration.

identical in all cases of aortic incompetence, those that are shown in Figs. 8 and 9 are probably the most characteristic. In both these figures the long axis of the heart is more horizontal than in health, and the long diameter is excessive owing to dilatation

and hypertrophy of the left ventricle. The pulmonary and auricular curves are not excessively prominent, indicating that neither the right ventricle nor the auricles are unduly distended. The right upper curve, however, is unduly prominent, and may exhibit excessive pulsatile movement, indicating dilatation of the ascending portion of the aortic arch. The uppermost (aortic) curve on the left side is also excessive and pulsates freely. In other instances, when the dilatation of the aortic arch is associated with dilatation of the thoracic aorta, or with undue distension of the conus arteriosus, the cardiac shadow at the level of the third chondro-sternal articulation becomes more diffusely broadened.

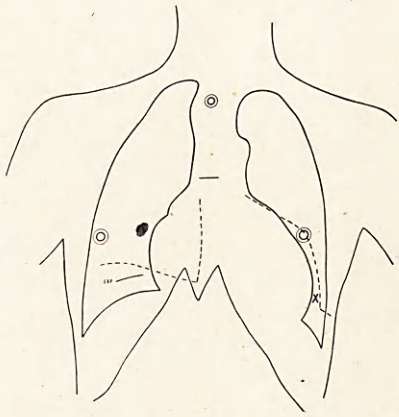

FIG. 10.—MALE, AGED 61, AORTIC AND MITRAL INCOMPETENCE.

X, The position of the apex-beat.
- - - - - - The deep percussion dulness.

In cases such as these it is especially desirable to examine the patient in oblique positions, and particularly in that with the patient turned 45° to the right, in order to exclude the presence of an aneurysm of the aorta. In many cases of aortic incompetence the aortic shadow is found to be unduly dense owing to pathological thickening of the wall of the aorta.

Aortic and Mitral Incompetence.—In these cases the curve of the left ventricle becomes further enlarged, while the curves of the right and left auricles and of the pulmonary artery become more prominent than in cases of pure aortic incompetence. In advanced cases the heart's outline becomes still more globular, and all the diameters are increased (Fig. 10). The average

diameters of four cases were M.R. 6·1, M.L. 11·4, T.D. 17·5, and L.D. 18·5.

In many cases presenting cardiac symptoms, but without any recognisable evidence of valvular lesion, an orthodiagram may be of considerable interest and value. In cases of chronic interstitial myocarditis and of arterial sclerosis, for example, the orthodiagram may reveal enlargement of the left ventricle which was not sufficiently pronounced to be recognisable by palpation or percussion. In cases giving a history of palpitation, tachycardia, or angina, the determination that the heart's outline is wholly normal, or that there is obvious enlargement of the ventricular, pulmonary, or auricular curves, is of great assistance in forming a definite opinion as to the cause of the patient's trouble and as to the prognosis of the case. The size, form, and pulsations of the aortic curve should be studied with particular care in cases of angina pectoris in comparatively young persons. In some of these cases the aorta will be found to be perfectly healthy; in others the aorta bulges too prominently either on the right or the left side, and at the same time the aortic shadow may be unusually dense owing to thickening and calcification of the aortic wall, and the pulsations of the aorta may be of excessive amplitude. In patients who are convalescing from pneumonia, and in whom enfeeblement of the right heart may be suspected, the orthodiagraphic record may demonstrate a pronounced bulging of the pulmonary curve in the absence of any abnormality of the auricular curves. In two of our cases convalescing from acute pericarditis the right auriculo-hepatic angle in the orthodiagram was obtuse.

Some of the irregularities of the heart's action can be observed readily on the orthodiagraph screen. Ventricular extrasystoles are best seen at the apex of the left ventricle. As a rule, the auricular pulsations are not sufficiently well seen on the screen to enable one to determine by this means alone whether the auricles are beating rhythmically or not; but in a recent case of complete heart-block we could see very clearly that the right auricle was beating rhythmically about eighty times per minute, whereas the rhythmic pulsations of the left ventricle and the aorta were at the rate of only thirty-three per minute.

In the diagnosis of aortic aneurysm the orthodiagraph enables us to define the exact site and size of the aneurysm in a manner that is seldom possible by means of palpation and percussion (Fig. 12). We have found the orthodiagraph of especial assistance in cases of deep-seated aneurysm of the thoracic aorta (Fig. 11).

During the past year we have compared the percussion outlines of the heart with the orthodiagraphic outline in many of our cases, and we find that percussion has usually failed to afford us accurate indications of the size of the heart. We find that the

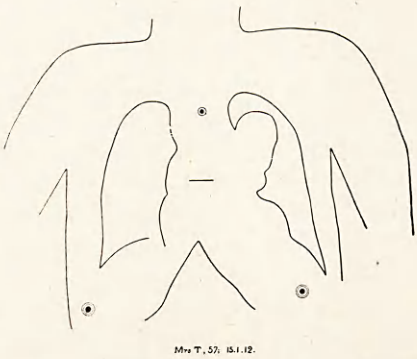

Fig. 11.—Aneurysm of Descending Thoracic Aorta.

left border of the heart and the upper limit of the liver, as ascertained by a firm percussion stroke, are usually placed too far to the left and too high respectively. The error is often slight and

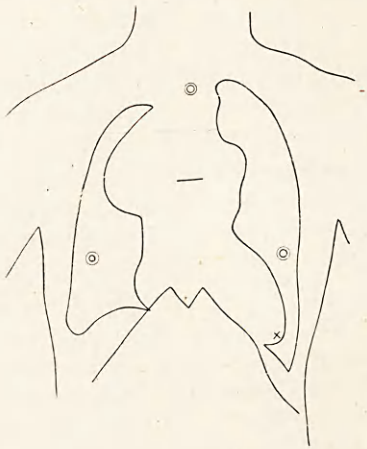

Fig. 12.—Male, aged 68, Aneurysm of Thoracic Aorta.

trivial in the case of the normal heart, but when the heart is much enlarged the percussion outline is often quite erroneous. What the late Sir William Gairdner called a carefully minimised percussion stroke is, in our opinion, better than a firm stroke for the

delimitation of an organ such as the heart. But even by means of the most carefully adjusted percussion stroke, the precise form and size of the heart cannot be determined as accurately as by means of the orthodiagraph. We have to remember that the heart lies obliquely in the thorax, the base lying further back than the apex, and consequently the determination, by means of percussion, of the upper or basal part of the heart, including the left auricle and conus arteriosus, must necessarily offer special difficulty. Further, we find that the enlarged heart is as a rule more difficult to percuss out accurately than the normal heart; that the right border as ascertained by percussion is more often erroneously demarcated than the left; and that except in cases of pericardial effusion the left percussion border is almost certainly inexact if it lies well outside a clearly defined apex-beat. The latter is often the best guide we have regarding the size and degree of enlargement of the left ventricle.

In conclusion, we desire to express our sincere thanks to the trustees of the Clinical Medicine Research Laboratory of the Royal Infirmary of Edinburgh for much kind advice and assistance in the course of our work in the laboratory, and to our colleague, Mr. Archibald M'Kendrick, to whom we are indebted for the drawing reproduced in Figure 1.

REFERENCES.—[1] *Die Röntgendiagnostik der Herz- und Gefässerkrankungen*, Berlin, 1912. [2] *Amer. Journ. Med. Sci.*, 1909, cxxxviii. 549; 1910, cxl. 506. [3] *Zeitschr. f. klin. Med.*, 1911, lxxii. 563.

ROYAL COLLEGE OF SURGEONS OF EDINBURGH.—The following gentlemen have been admitted Fellows of the College after examination:—B. G. S. Acharya, M.B., C.M.(Madras), London; Amos Walter Bowman, M.B., Ch.B.(Melbourne), Victoria, Australia; Claud James Brookes, M.B., Ch.B.(St. And.), London; William Frederick Buist, M.B., Ch.B.(Edin.), L.R.C.S.E., Edinburgh; Hamilton Drummond, M.B., Ch.B.(Durh.), Newcastle-on-Tyne; Gerhard Friedrich Fismer, M.B., Ch.B.(Edin.), Cape Town; Hugo Flecker, M.B., C.M.(Sydney), M.R.C.S.(Eng.), L.R.C.P.(Lond.), London; Davis Heron, M.B., Ch.B.(Edin.), Captain, I.M.S.; Herbert Hutson, M.B., Ch.B., M.D.(Edin.), Edinburgh; John M'Intyre, L.R.C.S.E., Glasgow; S. N. Mukhopadhyay, L.M.&S.(Calcutta), L.R.C.S.E., Calcutta; James Murphy, L.R.C.S.E., Midleton, Co. Cork; William Roberts, M.B.(Toronto), Newfoundland; John Crawford Robertson, M.B., C.M., M.D.(Glas.), Maryborough, Queensland, Australia; Archer Ryland, M.R.C.S.(Eng.), L.R.C.P.(Lond.), London; Neil Campbell Scott, M.B., Ch.B.(Glas.), Bristol; and George Hulseberg Sinclair, M.B., Ch.B.(Edin.), Derby.