

## Bronchiolitis obliterans organising pneumonia in a patient with ulcerative colitis

C R SWINBURN, G J JACKSON, I COBDEN, T ASHCROFT, G N MORRITT,  
P A CORRIS

*From the Regional Cardiothoracic Unit and the Department of Histopathology, Freeman Hospital, Newcastle upon Tyne*

**ABSTRACT** A young woman with ulcerative colitis developed pneumonia, which responded to corticosteroids. Histological examination showed this to be bronchiolitis obliterans organising pneumonia.

Various pulmonary disorders have been reported as extra-intestinal manifestations of ulcerative colitis. These include chronic bronchial suppuration and bronchiectasis<sup>1-3</sup> (which may be steroid responsive<sup>3</sup>), pulmonary vasculitis,<sup>4</sup> and severe steroid responsive pneumonia complicated by pyoderma gangrenosum.<sup>5</sup> We report a case of severe steroid sensitive pneumonia occurring in a young woman with quiescent ulcerative colitis. Histological examination showed bronchiolitis obliterans organising pneumonia.<sup>6</sup>

### Case report

A 20 year old woman presented in 1983 with weight loss, loose motions, and passage of blood and mucus rectally. Ulcerative colitis was diagnosed on the basis of a barium enema, sigmoidoscopy, and biopsy. Her haemoglobin concentration was 11.0 g/dl and white cell count  $15.5 \times 10^9/l$  with an eosinophil count of  $2.5 \times 10^9/l$ . The erythrocyte sedimentation rate (ESR) was 50 mm in one hour. She was receiving no treatment and her chest radiograph was normal. She was initially treated with sulphasalazine, colifoam enemas, and occasional courses of systemic corticosteroids. In March 1986 mesalazine was substituted for sulphasalazine at a dose of 400 mg twice daily initially; subsequently she was maintained on 800 mg thrice daily.

In March 1987 she presented with fever, anorexia, a dry cough, breathlessness on exertion, and central pleuritic chest pain. On examination she was febrile (38°C) and there was no finger clubbing. Her heart rate was 120 beats/min and bronchial breathing was heard posteriorly in the right chest. A chest radiograph showed peripheral shadowing in the right middle and lower zones. Investigations showed her haemoglobin concentration to be 13.3 g/dl, white cell count  $14.9 \times 10^9/l$ , eosinophil count  $2.2 \times 10^9/l$  and ESR 93 mm in one hour. Erythromycin 500 mg four times daily for two weeks resulted in no symptomatic improvement and a chest radiograph showed increased shadowing (fig 1).

On admission the findings from clinical examination and the blood count were essentially unchanged. Routine biochemical and liver function tests gave normal results except

for increased alkaline phosphatase activity (125 (normal 5-32) IU/l). Bronchial washings were smear and culture negative for acid fast bacilli and no organisms were seen after Gram staining or subsequent culture. Pleural aspiration produced a small amount of straw coloured fluid with a protein content of 43 g/l and no organisms (including acid fast bacilli) were seen after staining or culture. Pleural biopsy was complicated by a hydropneumothorax necessitating underwater seal drainage. The provisional histological report on the biopsy specimen suggested a poorly differentiated adenocarcinoma, so she was transferred to the regional cardiothoracic unit for thoracotomy. At this time the results of her routine blood tests were essentially unchanged except that in addition to the increased alkaline phosphatase activity  $\gamma$  glutamyl transpeptidase activity was now increased at 138 (normal < 40) IU/l and aspartate transaminase at 257 (< 37) IU/l. Further investigations included negative results in an autoantibody screen (other than rheumatoid factor 1:80), normal serum electrophoresis, and normal gammaglobulins,

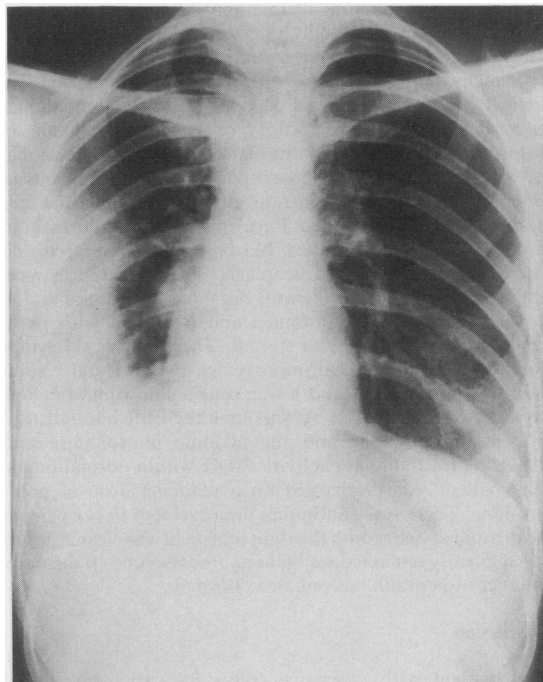


Fig 1 Chest radiograph on admission to hospital showing extensive peripheral shadowing in the right middle and lower zones.

Address for correspondence: Dr C R Swinburn, Regional Cardiothoracic Unit, Freeman Hospital, Newcastle upon Tyne NE7 7DN. (Reprints will not be available.)

Accepted 15 April 1988

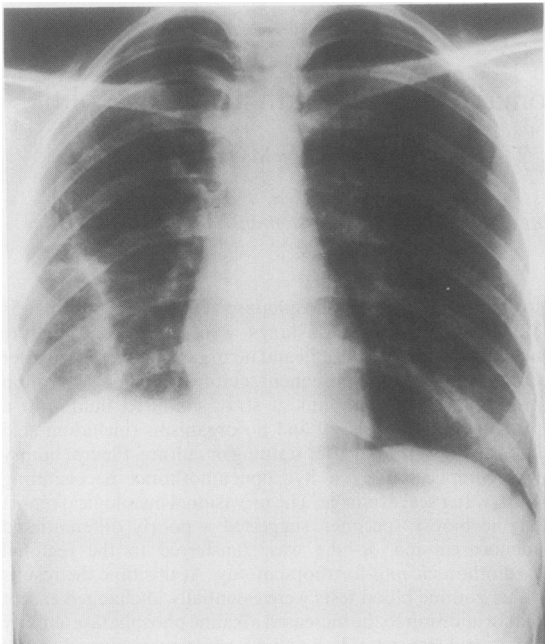


Fig 2 Chest radiograph after treatment with prednisolone 40 mg daily for 7 days.

including IgE. Stool examination showed no parasites and skin testing for common allergens gave negative results.

At thoracotomy the right lung was collapsed with areas of consolidation; the pleura appeared normal. Biopsy specimens of the right lung and pleura were taken. Histologically the pleura showed chronic non-specific inflammation. The lung showed knots of granulation tissue in respiratory bronchioles, alveolar ducts, and occasional alveoli. There were foamy macrophages in the alveoli and an interstitial lymphocytic infiltrate, although a few plasma cells and eosinophils were noted. Purulent exudate was present in non-respiratory bronchioles. No organisms were seen and there was no evidence of neoplasia. The appearances were those of bronchiolitis obliterans organising pneumonia.

Mesalazine was discontinued and treatment with prednisolone 40 mg a day was started. There was rapid symptomatic and radiological improvement with virtual resolution of the right mid and lower zone shadowing after one week's treatment (fig 2). At this time the ESR had fallen to 30 mm in one hour and the alkaline phosphatase and aspartate transaminase activities were within normal limits. The patient was discharged on a reducing dose of prednisolone. There was continuing improvement in her general health and at one month the right lung field was clear. She has subsequently remained well taking prednisolone 10 mg daily and her radiograph has remained normal.

### Discussion

This patient with ulcerative colitis had a severe steroid responsive pneumonitis with the histological features of bronchiolitis obliterans organising pneumonia. Eight patients with a similar disorder were reported in 1983 and the condition was called cryptogenic organising pneumonitis

*Swinburn, Jackson, Cobden, Ashcroft, Morritt, Corris*

because of the absence of an infective or other aetiological agent.<sup>7</sup> In seven patients there was no associated illness, but in one there was evidence of autoimmune disease. Subsequently a retrospective series of 57 patients with a similar clinical syndrome and similar radiological and histological findings was reported, and the condition named bronchiolitis obliterans organising pneumonia.<sup>6</sup> In this larger series the illness was idiopathic in 50 patients, associated with a connective tissue disorder in five, and caused by aspiration in two.

A case of severe steroid responsive pneumonitis in association with ulcerative colitis has been previously reported.<sup>5</sup> The similarity of the clinical and radiological features in this case and our own led us to review the histological sections of the earlier case. This was in many respects similar, showing an intra-alveolar exudate of fibrin and clumps of foamy macrophages in various stages of organisation. The specimen was, however, smaller and included no bronchioles, and so it was not possible to be certain that this case was histologically identical.

Although our patient had peripheral blood eosinophilia, this was present when she was first seen and antedated any drug treatment for her ulcerative colitis. She was not atopic, her serum IgE concentration was within the normal range, and the histological features were not those of eosinophilic pneumonia. Treatment with sulphasalazine has been associated with pulmonary infiltrates,<sup>8</sup> but in this case sulphasalazine had been discontinued a year before the development of the pneumonia. There are no reports of any such adverse reactions to mesalazine, which the patient had tolerated well for a year. None of the previously reported cases of bronchiolitis obliterans organising pneumonia<sup>6,7</sup> were believed to be drug related, and we think that this case was very unlikely to be due to a drug reaction.

Bronchiolitis obliterans organising pneumonia may be a rare association of ulcerative colitis. The importance of this diagnosis lies in its prompt response to corticosteroids.

We are grateful to Professor B Corrin, Brompton Hospital, London, for reviewing the lung biopsy specimen.

### References

- Higgenbottom T, Cochrane GM, Clark TJH, Turner D, Millis R, Seymour W. Bronchial disease in ulcerative colitis. *Thorax* 1980;**35**:581-5.
- Kraft SC, Earle RH, Roester M, Esterly JR. Unexplained bronchopulmonary disease with inflammatory bowel disease. *Arch Intern Med* 1976;**136**:454-9.
- Butland RJA, Cole P, Citron K, Turner-Warwick M. Chronic bronchial suppuration and inflammatory bowel disease. *Q J Med* 1981;**197**:63-75.
- Isenberg JI, Goldstein H, Korn AS, Ozeran RS, Rosen V. Pulmonary vasculitis—an uncommon complication of ulcerative colitis. *N Engl J Med* 1968;**279**:1376-7.
- McCulloch AJ, McEvoy A, Jackson JD, Jarvis EH. Severe steroid responsive pneumonitis associated with pyoderma gangrenosum and ulcerative colitis. *Thorax* 1985;**40**:314-5.
- Epter GR, Colby TV, McLoud TC, Carrington CB, Gaenster EA. Bronchiolitis obliterans organising pneumonia. *N Engl J Med* 1985;**312**:152-8.
- Davison AG, Heard BE, McAllister WAC, Turner-Warwick MEH. Cryptogenic organising pneumonitis. *Q J Med* 1983;**207**:382-94.
- Mosely RH, Barwick KW, Dobuler K, DeLuca VA. Sulphasalazine-induced pulmonary disease. *Dig Dis Sci* 1985;**30**:901-4.

**THORAX**

## **Bronchiolitis obliterans organising pneumonia in a patient with ulcerative colitis.**

C R Swinburn, G J Jackson, I Cobden, T Ashcroft,  
G N Morrill and P A Corris

*Thorax* 1988 43: 735-736  
doi: 10.1136/thx.43.9.735

---

Updated information and services can be found at:  
<http://thorax.bmj.com/content/43/9/735>

---

### **Email alerting service**

*These include:*

Receive free email alerts when new articles cite this article. Sign up in the box at the top right corner of the online article.

---

### **Notes**

---

To request permissions go to:  
<http://group.bmj.com/group/rights-licensing/permissions>

To order reprints go to:  
<http://journals.bmj.com/cgi/reprintform>

To subscribe to BMJ go to:  
<http://group.bmj.com/subscribe/>