

Acta Medica Okayama

Volume 17, Issue 5

1963

Article 3

1963

Studies on the treatment of malignant tumors with fibroblast-inhibiting agent. I. Fibroblast-inhibiting action of chloroquine

Kiyoshi Hiraki*

Ikuro Kimura†

*Okayama University,

†Okayama University,

Studies on the treatment of malignant tumors with fibroblast-inhibiting agent. I. Fibroblast-inhibiting action of chloroquine*

Kiyoshi Hiraki and Ikuro Kimura

Abstract

The effects of chloroquine on the growth and morphology of fibroblasts in tissue culture, and in vivo granulomas were investigated. As the result, the drug was shown to have a potent action to inhibit fibroblast growth, which has led to a possibility of its clinical use to patients with malignant tumors.

Acta Med. Okayama 17, 231-238 (1963)

STUDIES ON THE TREATMENT OF MALIGNANT TUMORS WITH FIBROBLAST-INHIBITING AGENT

I. FIBROBLAST-INHIBITING ACTION OF CHLOROQUINE

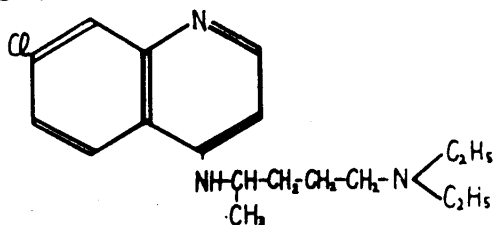
Kiyoshi HIRAKI and Ikuro KIMURA

Department of Internal Medicine, Okayama University Medical School
(Director: Prof. K. Hiraki)

Received for publication, August 10, 1963

Malignant tumors consist of the parenchyma and stroma whose intimate associated growth forms neoplasms. This association of the two elements are also seen in the metastatic tumors. Our attention has been directed to the role of the stromal tissue in supporting cancer cell as already pointed out by FISCHER¹ and on the basis of our idea that damage of the stromal tissue might secondarily results in damage of the cancer cells we have been conducting experimental and clinical studies with animal and human tumors for the past several years. To our best knowledge, no attempt has yet been made to approach malignant tumors from this chemotherapeutic point of view.

Chloroquine, a derivative of quinoline, was used as the agent having a fibroblast-inhibiting action (an action inhibiting growth of fibroblasts), as already been recognized by HABERLAND.² We have employed this agent, because it was shown to exert a powerful fibroblast-inhibiting effect. It is the intent of this paper to report our experimental results indicating the fibroblast-inhibiting effect of chloroquine (Fig. 1).



7-chloro-4-(4'-diethylamino-1'-methylbutylamino)-quinoline

Fig. 1 Structure of chloroquine

MATERIALS AND METHODS

To determine the degree of fibroblast-inhibiting effects of chloroquine, a study was made on the influences of this drug upon the growth and morphology of *in vitro* cultured chick embryo heart fibroblasts, *in vivo* agar granuloma, and granuloma pouch of the animal.

Chick embryo heart fibroblasts were cultured on tissue culture slides No. 2 devised by HIRAKI³; cells taken from heart of 9-day-old chick embryos were cultured in a medium consisting of an equal amount of chick embryo juice, avian

serum and Ringer's solution, with addition of 5% , 500% , and 50,000% of chloroquine diphosphate, respectively, and observation was performed at various time intervals of 12, 24, 36, 48 and 72 hours with respect to the relative growth rate and cell density index. The effects of other derivatives of chloroquine diorotate, chloroquine chondroitin sulfate and chloroquine polygaracturonate were compared at the chloroquine concentration of 2% with those of chloroquine diphosphate at the same concentration.

For the observation of morphological changes of chick embryo heart fibroblasts, roller tubes implanted with rectangular coverslips were used; after 48 hours of culture, chloroquine diphosphate was added at the concentration of 200% and phase contrast microscopy was performed after 72 hours in culture.

Agar granulomas were produced in the back of male Wistar rats by injecting 2 c.c. of 4% agar solution in 1/10M phosphate buffer at pH 7.5 and beginning after 24 hours, chloroquine diphosphate, chloroquine diorotate, chloroquine chondroitin sulfate and chloroquine polygaracturonate were injected daily into the tail vein in the net amount of chloroquine of 15 mg. per kg. of body weight. After 15 days the animals were sacrificed and the granulomas were weighed and examined histologically after being stained with hematoxylin and eosin and van Gieson stain.

Similarly, granuloma pouches⁴ were produced in male Wistar rats by injecting 25 c.c. of air subcutaneously in the back and by injecting 1 c.c. of 0.5% croton oil in corn oil into the air space. Daily intraperitoneal injection of 25 mg of chloroquine diphosphate per kg. of body weight was started after 24 hours and continued for 14 days. When the animals were killed, the total pouch weight, weight of the pouch wall, amount of the exudate, and cell count in the exudate were measured. In addition, the amount of chloroquine of the pouch wall was determined by the method of BRODIE.⁵

RESULTS

1. Effects of chloroquine on the growth of chick embryo heart fibroblasts (Fig. 2): A decrease in the relative growth rate and cell density index was observed in cultures grown in medium containing 50,000% and 500% of chloroquine diphosphate in comparison with the control. Even at the concentration of 5% , a moderate decrease in the relative growth rate was seen. Cultures grown in the medium containing 2% of chloroquine in the form of chloroquine diphosphate, chloroquine diorotate, chloroquine chondroitin sulfate and chloroquine polygaracturonate likewise showed similar depressive effects of the same degree.

2. Morphological changes of chick embryo heart fibroblasts (Photos 1, 2): In the control culture the cells were slender with cytoplasmic processes. The

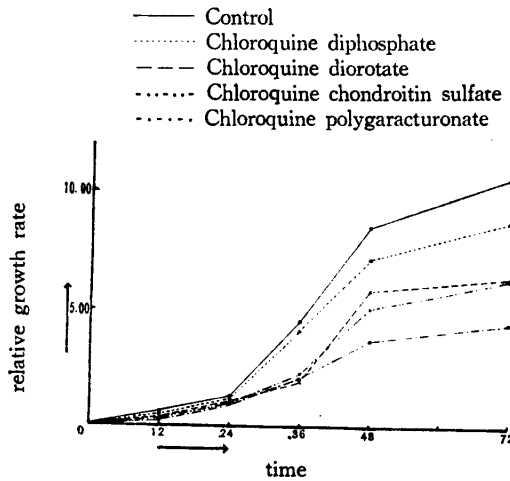


Fig. 2 Relative growth rate of fibroblasts of chick embryo heart in tissue culture added with various chloroquine derivatives (27 % expressed in chloroquine concentration)

cell margin was regular and distinct. Many intracytoplasmic vacuoles were small and uniform in size. There were many mitochondria around the nuclei and in the cytoplasmic process, and they were granular or rod-shaped. The nuclei were oval and had distinct nuclear membrane and nucleoli. The cells cultured in the chloroquine-containing medium, however, showed an increase in the number of intracytoplasmic vacuoles which varied in size and characteristically contained giant vacuoles apparently resulting from confluent smaller vacuoles. No other significant changes were observed.

3. Effects of chloroquine on the growth of agar granulomas (Fig. 3, Photos

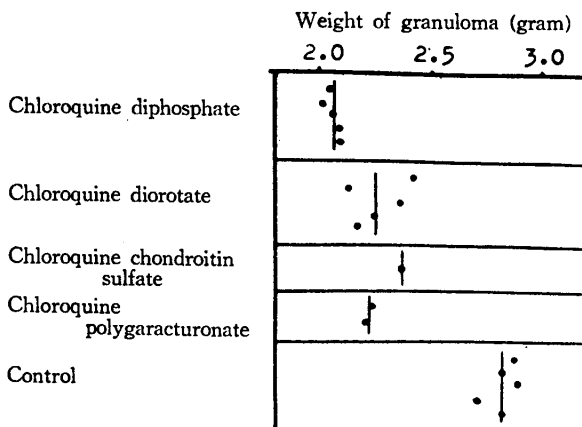


Fig. 3 Effect of chloroquine on agar granuloma (Wistar strain ♂ rat, intravenous injection of 15 mg./kg. expressed in chloroquine dosage)

3, 4): In all the chloroquine-treated groups, there was a reduction in the weight compared with the control. This was particularly striking in granulomas treated with chloroquine diphosphate. Histologically the connective tissue surrounding the agar was thinly developed and van Gieson staining disclosed a poor formation of collagenous fibers in the treated group.

4. Effects of chloroquine on granuloma pouches (Table 1, Fig. 4): The weight of total granuloma pouches and of granuloma wall, amount of exudate and cell counts were all less than those of untreated ones. This seemed to be due to an anti-inflammatory action as well as action of the agent inhibiting fibroblast growth. The amount of chloroquine extractable from these granuloma tissue was found to be larger than that extractable from the normal subcutaneous tissue.

Table 1 Effect of chloroquine on granuloma pouch (continuous intraperitoneal injection for 14 days of chloroquine diphosphate 25 mg./kg.)

Number	Treated group						Control						
	1	2	3	4	5	6	1	2	3	4	5	6	7
Total weight (gram)	3.0	12.0	11.0	17.0	20.0	12.5	28.6	24.0	14.0	19.0	17.5	19.0	26.0
	Average 12.6						Average 21.2						
Weight of wall (gram)	0.8	1.7	2.6	3.4	1.7	1.8	4.0	4.0	2.0	3.2	2.5	3.2	3.5
	Average 2.0						Average 3.2						
Amount of exudate (c. c.)	2.0	10.0	8.0	13.2	18.0	10.4	24.0	19.2	11.6	15.4	14.4	15.2	22.0
	Average 10.3						Average 17.3						
Cell number of exudate ($\times 10^3/\text{mm}^3$)	3.2	4.3	1.8	3.3	5.0	2.0	3.5	6.2	1.8	9.7	2.4	7.6	8.1
	Average 3.27						Average 5.61						

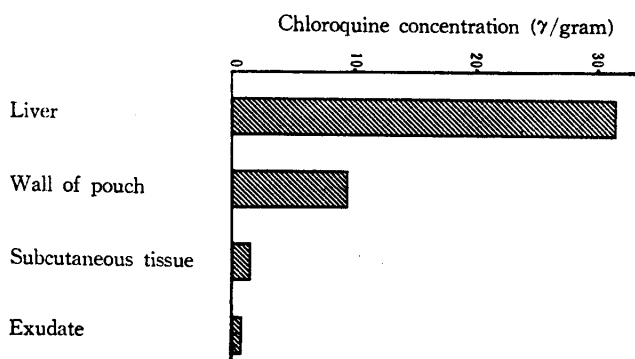


Fig. 4 Chloroquine distribution in the rat with granuloma pouch formation (continuous intraperitoneal injection for 14 days of chloroquine diphosphate 25 mg./kg.)

DISCUSSION

We first recognized excellent therapeutic effects of chloroquine on Wakana disease and bronchial asthma, and in the course of our investigation of the mechanism of drug action, it has been shown that the drug also has a potent fibroblast-inhibiting action.

The agent in a low concentration inhibited considerably the growth of fibroblasts in tissue culture and induced degenerative changes of these cells. The experiment with agar granulomas demonstrated a moderate inhibitory action on fibroblast growth *in vivo*. The drug was shown to have a similar action and furthermore proved to be anti-inflammatory in the experiment using granuloma pouches.

The experiments of HABERLAND² in which several anti-inflammatory agents were tested for the action inhibiting fibroblast growth in tissue culture indicated that chloroquine diphosphate completely inhibited the growth of the cultured fibroblasts at the dilution of 1 : 40,000, namely at the concentration of one tenth of phenylbutazone and prednisone inducing the same effect. In our experiments chloroquine suppressed the growth of fibroblasts at the concentration of as low as 2% in tissue culture medium. This concentration is much lower than serum peak concentrations determined by the method of BRODIE⁵ after oral or intravenous administration of chloroquine in human beings.⁶ Therefore, oral ingestion as well as intravenous injection of 250 mg. of chloroquine diphosphate produces serum levels above the effective range necessary for the drug action. Accordingly, to achieve higher serum concentrations, the drug was given intravenously to patients with malignant tumors, as will be referred to in its clinical application.

Our observations on the inhibitory action of chloroquine on fibroblast growth in agar granulomas and granuloma pouches *in vivo*, along with its effects on cotton pellet granulomas in the HABERLAND's experiments,² have strongly suggested a possible clinical usefulness of the drug in inhibiting the stromal tissue of malignant tumors, which is our eventual aim. Clinically we have already observed a fairly good effect of the drug on hepatic fibrosis. The anti-inflammatory action of the agent as shown in the present experiment with granuloma pouches may be advantageous to this aim. The fact that chloroquine distributed more in the wall of granuloma pouches than in normal subcutaneous tissue may be regarded as showing its affinity to the former, possibly influencing the metabolism of the granulomatous tissue.

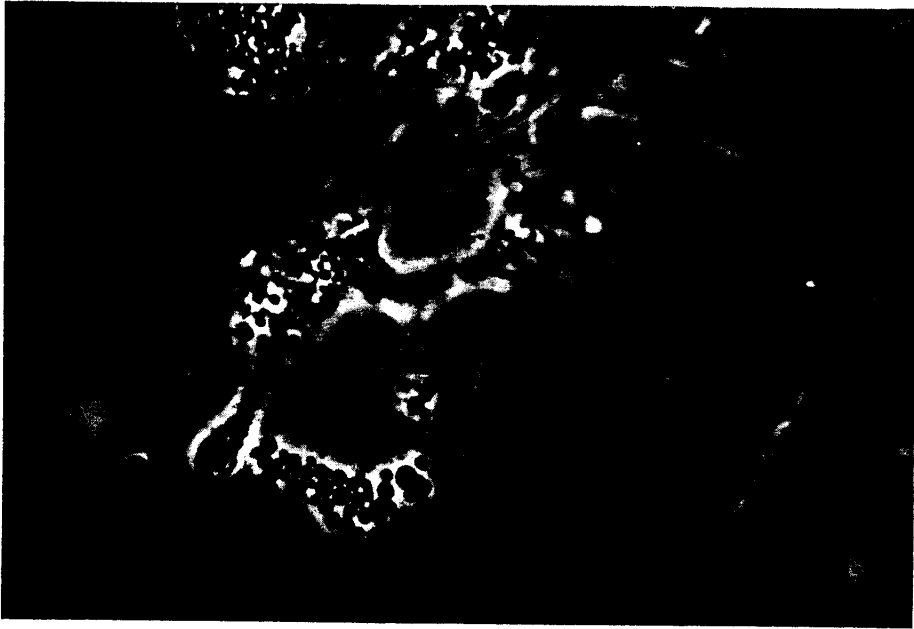SUMMARY

The effects of chloroquine on the growth and morphology of fibroblasts in tissue culture, and *in vivo* granulomas were investigated. As the result, the drug

was shown to have a potent action to inhibit fibroblast growth, which has led to a possibility of its clinical use to patients with malignant tumors.

REFERENCES

- 1) FISCHER, A.: Cytoplasmic growth principles of tissue cells, *Arch. exper. Zellforsch.*, 1, 369, 1925
- 2) HABERLAND, G. L. *et al.*: Pharmakologische Untersuchungen zur Wirkungsweise von Anti-phlogistika, *Zeitschr. f. Rheumaforschung*, 18, 220, 1959
- 3) HIRAKI, K. *et al.*: The method of tissue culture (mainly of the bone marrow) and a simple method of observing living tissue, *Acta Med. Okayama*, 10, 99, 1956
- 4) SELYE, H.: Use of "granuloma pouch" technic in the study of antiphlogistic corticoids, *Proc. Soc. Exp. Biol. Med.*, 82, 328, 1953
- 5) BRODIE, B. B. *et al.*: The estimation of basic organic compounds in biological material, *J. Biol. Chem.*, 168, 299, 319, 1947
- 6) HIRAKI, K. *et al.*: in preparation



[Photo. 1 Normal fibroblasts of chick embryo heart (Phase contrast microscopy)

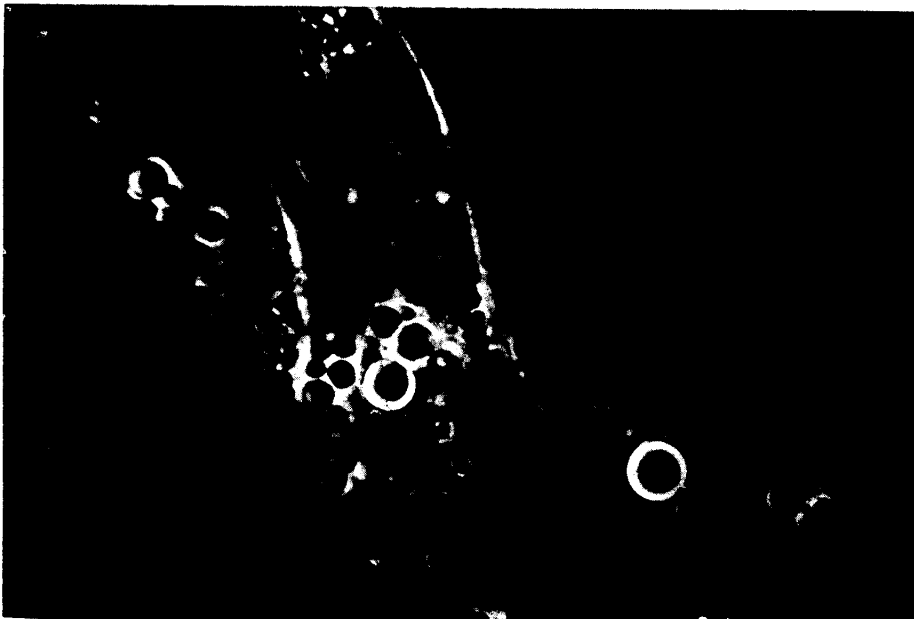


Photo. 2 Fibroblasts of chick embryo heart grown in medium containing chloroquine diphosphate (Phase contrast microscopy)




Photo. 3 Agar granuloma in untreated rat (H. & E. staining)




Photo. 4 Agar granuloma in rat given chloroquine diphosphate (H. & E. staining)