

# Improving Robustness of Cartilage segmentation using IDEAL water and fat images

R. Kokku<sup>1</sup>

<sup>1</sup>MR SW & Apps, GTO-I, Wipro GE Healthcare, Bangalore, Karnataka, India

**INTRODUCTION:** Accurate and reliable quantification of cartilage volume in MRI is required for diagnosis of many degenerative and inflammatory diseases such as osteoarthritis or rheumatoid arthritis. Segmentation techniques are often challenged by the variation in the MRI data and anatomical shape of the cartilage. Many techniques were proposed based on region growing, active contours and model-based guidance to improve the cartilage detection [2-4]. IDEAL[1] water-fat suppression technique enhances the cartilage anatomy with better suppression of fat around it but the robustness challenge remains. In the present work, we propose a novel method using IDEAL water and fat images for robust segmentation of the anatomical features in knee MRI data.

**METHOD:** Shape of the cartilage and muscular tissue around it makes the automated segmentation difficult. With IDEAL water and fat images similar anatomical structures around the cartilage share different intensity characteristics. Femur, Tibia, patella & adipose tissue are dominant structures in fat images where as cartilage, muscle tissue show up as strong features in water images (fig 1). Proposed method smartly detects the shape of the bone & tissues around cartilage from IDEAL images to define guidance region for segmentation. Difference image between the water and fat images is generated to use as mask image (fig 2). This mask image smartly outlines the background, boundaries of anatomical structures. As the cartilage takes the shape of the bone, cartilage ROI is defined using the morphological operation over the Femur and Tibia (fig 3) from the difference mask image. Before the final segmentation, ROI is broken into two quadrants in sagittal view on the bases of adipose tissue and muscular tissue. Cartilage attached to adipose tissue can be easily segmented from the ROI by intensity method. This segmented cartilage characteristics are used to segment the remaining cartilage from muscular tissue. Guidance provided by segmenting the surrounding bone structures and muscular structures improved the accuracy of cartilage segmentation (fig 4).

**RESULTS & DISCUSSION:** For evaluation MR IDEAL image are acquired from four subjects from GE 1.5T scanner. [Acquisition parameters: 256x256x36, spacing 0.625X0.625X2, BW 32.5Khz, Flip angle 10 degrees]. Manual segmentation of the datasets was performed using ITKSnap tool to generate the reference data. Operator variation in the manual segmentation was nullified by averaging the manual segmented results. Efficiency was determined by the accuracy of the segmentation by the proposed solution over the datasets. Speed of segmentation was improved compared to manual segmentation & standard methods [ITK segmentation methods] by the smart usage of ROI for search space classification in the proposed method. Compared to manual segmentation the proposed solution to segment the cartilage is ten fold faster. The accuracy of segmentation was measured by the Dice similarity coefficient (*DSC*). Mean *DSC* of 0.926 was reported for the Femur, Tibia structures and 0.784 for the Cartilage region. Though *DSC* doesn't provide insight of the spatial distribution of segmentation errors, we analyzed the factors influencing the negative classification of region. The boundary images from IDEAL have relatively less signal compared to other images. Region guidance from cartilage around Patella created inconsistencies as the region intensity of adipose tissue is stronger than patella in fat image. Minor variations observed in cartilage segmentation are reviewed by visual inspection and concluded that false positives in the segmentation are low expect in the boundary slices. For higher field strengths we need to take the chemical shift into account on based on the scan prescription and bandwidth before generating the mask using IDEAL fat image.

**CONCLUSION:** Robust image segmentation with prior knowledge of acquired anatomy using IDEAL images is proven. Results indicate accurate segmentation of Femur, Tibia and guidance map used for cartilage segmentation using the variation in IDEAL images can be extended to other anatomical scans. In conclusion, we have developed an efficient, reliable method for the segmentation of knee anatomy using high-resolution IDEAL MR images.

**REFERENCES:** [1] Scott B. Reeder et al, AJR 2003; 180:357-362 [2] S. B. Reeder et al MRM 2006 14 [3] D. Steines et al ,MI SPIE 2002 vol 4684, 1605-7422 [4] Jenny Folkesson et al, 327-334 MICCAI 2005 [5] T Kapur, et al, IEEE MDIA pp 97-106, 1998.

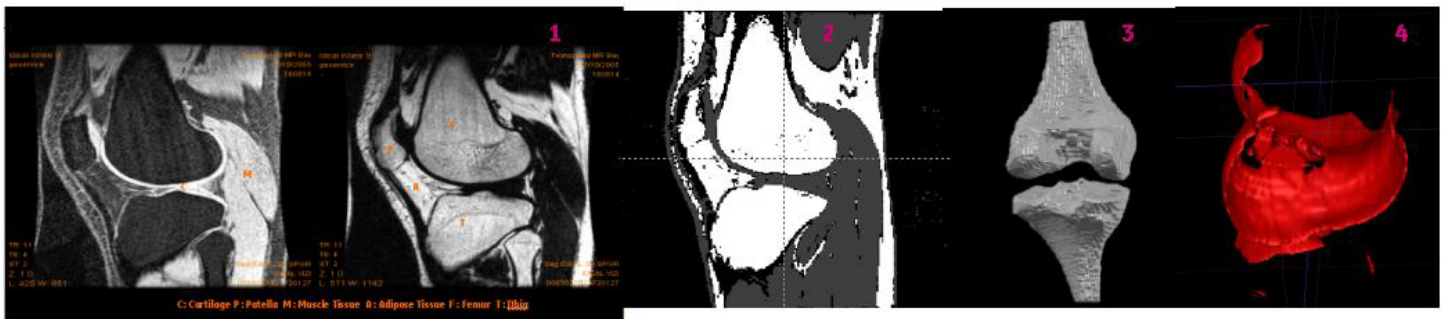


Figure 1: IDEAL water and Fat images with anatomical description indicating the dominant characteristics. Figure 2: ROI map generated from IDEAL images with Femur, Tibia, cartilage & background. Figure 3: Segmented Femur & Tibia for cartilage guidance. Figure 4: Cartilage volume.