

Original Article

Laparoscopic repair of cesarean section scar defect and the surgical outcome in 146 patients

Xuyin Zhang^{1*}, Chaoying Wu^{2*}, Mengyi Yang^{1,3}, Heyang Xu¹, Yuan He⁴, Jingxin Ding¹, Keqin Hua¹

¹Department of Gynecology, The Obstetrics and Gynecology Hospital of Fudan University, Shanghai 200090, China; Shanghai Key Laboratory of Female Reproductive Endocrine Related Diseases, Shanghai 200090, China; ²Department of Gynecology, Changzhou Maternal and Child Health Care Hospital, Changzhou, 213000, Jiangsu Province, China; ³Department of Gynecology, Shanghai First Maternity and Infant Hospital, School of Medicine, Tongji University, Shanghai 200040, China; ⁴Public Health School of Fudan University, Shanghai 200032, China. *Equal contributors.

Received December 5, 2016; Accepted February 3, 2017; Epub March 15, 2017; Published March 30, 2017

Abstract: Objectives: We described laparoscopic repair of previous lower uterine segment caesarean scar defect (PCSD) in a series of 146 patients in our hospital. Methods: From April 2010 to July 2015, 146 patients with PCSD in the Obstetrics and Gynecology Hospital of Fudan University underwent laparoscopic repair of PCSD. The surgical and pregnancy outcome were followed, and the risk factors for successful healing of the repair were analyzed. Results: The patients in the incomplete and complete excision group both had an obviously shortened period after surgery. Single factor analysis showed that the thickness of the residual myometrium, suturing material, and estimated blood loss were correlated with the effects of surgery. Multivariate logistic regression analysis showed that the thickness of the residual myometrium and suturing material were independent risk factors for successful healing of the repair. Thirty-two patients desired for fertility in this study, and 12 of them got pregnant in 13-32 months after surgery, including 8 term cesarean delivery, 2 preterm cesarean delivery, 1 artificial abortion, 1 cesarean scar pregnancy, and 2 were pregnant when this study was summarized. Conclusions: Laparoscopic complete excision of CSD and repair with delayed absorbable material may be performed with fair symptom relief and acceptable post-operative anatomic and functional outcomes.

Keywords: Caesarean section scar diverticulum, cesarean section scar defect, niche, laparoscopic repair

Introduction

The cesarean section rate has increased obviously over recent decades [1, 2]. Previous lower uterine segment caesarean scar defect (PCSD), also known as cesarean Section Scar diverticula or niche, is a late complication after cesarean section delivery. A caesarean scar defect is a late complication of caesarean birth with a wide range of prevalence between 56 and 84% depending on which diagnostic tool and which definition is used [3]. A deficient uterine scar healing after cesarean section is associated with some symptoms, such as postmenstrual spotting, pelvic pain, infertility, cesarean scar ectopic pregnancy, and uterine rupture in the following pregnancy [4-7].

Multiple treatments have been described for repair of PCSD such as oral contraceptives (OCs), laparoscopic repair, hysteroscopic niche resection, vaginal repair, laparoscopic assisted vaginal repair and robotic-assisted laparoscopic repair [7, 8].

Total laparoscopic repair was reported in some patients [9, 10]. However, the reported sample sizes (only 3 and 13 cases) and follow-up of the previous studies were insufficient to draw solid conclusions. So more evidence is needed before surgical niche interventions are implemented on a large scale in daily practice.

Herein we report our retrospective study of laparoscopic niche repair, the surgical, anatomical, and fertility outcome in 146 patients in our cen-

Laparoscopic repair of cesarean section scar defect

Table 1. Clinical characteristics of the two groups

Parameter, mean \pm SD or n	Incomplete excision group (n=45)	Complete excision group (n=101)
Age (y)	27.1 \pm 3.7	26.8 \pm 2.8
Symptoms (n)		
Postmenstrual spotting	43	98
Abdominal pain during menstruation	13	22
Chronic pelvic pain (not in menstrual period)	3	16
Dyspareunia	3	5
Secondary infertility	14	12
The largest diameter covering the dehiscence	13.6 \pm 6.1	10.3 \pm 4.2
Thickness of the residual myometrium (mm_) mean \pm SD	3.8 \pm 3.4	3.8 \pm 1.7

Abbreviations: SD, standard deviation.



Figure 1. Laparoscopic repair of uterine scar diverticulum after cesarean section. When the light of the laparoscope was turned off, red light is visible by laparoscopy at the site of the scar during hysteroscopic examination.

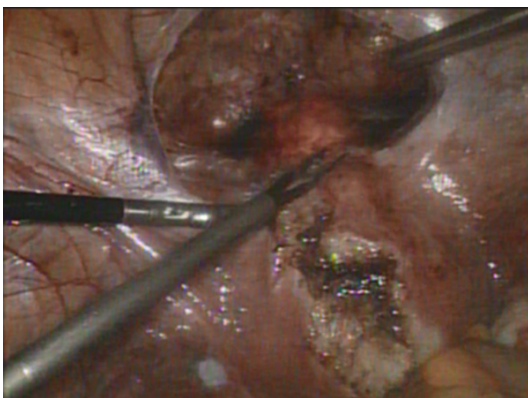

Figure 2. The upper and lower edge of the scar was recognized and marked according to the visible light from hysteroscopy.

ter, and analyzed the risk factors for successful healing of the repair.

Materials and methods

Patients

From April 2010 to July 2015, 146 patients with PCSD in our center underwent laparoscopic repair of PCSD. This retrospective study was permitted by the local ethics committee and written informed consent was obtained in all cases (The ethics committee of OBS & GYN hospital, Fudan University, No 2013-32).

The inclusion criteria included the presence of symptomatic PCSD. The symptoms including irregular menstrual bleeding, prolonged menstrual period, and infertility. The diagnosis of uterine diverticulum was made using transvaginal ultrasound, HSG or MRI. Ultrasound and MRI were used to measure the size and depth of the dehiscent scar and the thickness of the residual myometrium covering the dehiscence. Diagnostic curettages were performed in all patients who had menstrual changes to exclude malignancy in endometrium.

Their obstetric history showed that they had undergone cesarean section for various reasons, such as breech presentation, premature rupture of membrane, preeclampsia and social factors. The first 45 patients underwent incomplete excision (only excised the “ceiling” of the niche). And there was some unsuccessful rate, and we improved our technique, and the rest 101 patients underwent complete excision (excised not only the “ceiling”, but also all the side walls of the niche). Patient characteristics are shown in **Table 1**. Age, parity, number of CS, symptoms, the largest diameter covering the dehiscence, thickness of the residual myometrium were compared between two groups.

Laparoscopic repair of cesarean section scar defect

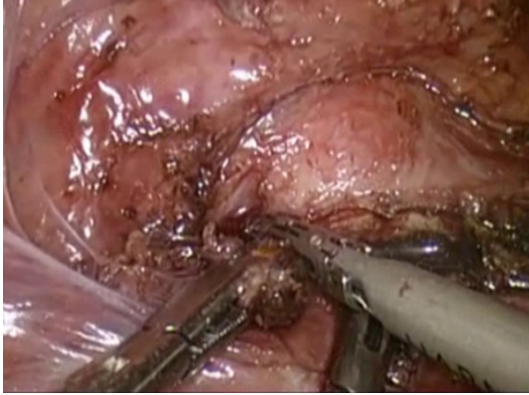


Figure 3. Incomplete of the scar (only excised the “ceiling” of the niche).

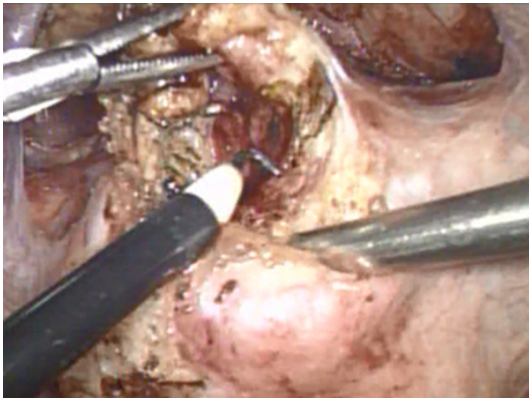


Figure 4. Complete excision (Not only the “ceiling”, but also the lateral wall and the inferior edge of the pseudocavity was total excised).

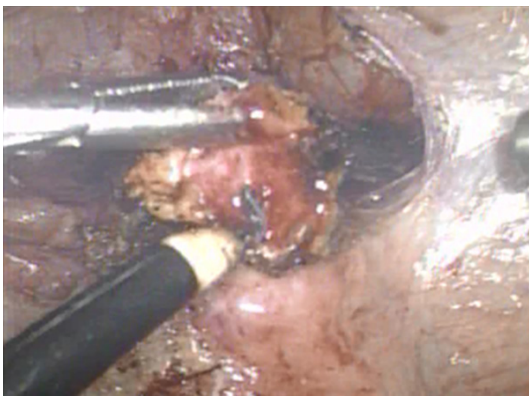


Figure 5. The completely excised niche.

Operative technique

The laparoscopic technique has been described in detail in a previous publication [9]. Herein,

we summarize the most important steps and our revision of the procedure (**Figures 1-5**).

When performing a laparoscopic operation, the peritoneum over the bladder was incised and the bladder was mobilized inferiorly over the cervix.

Hysteroscopic examination was done, and hysteroscopic view of the cervical canal showed an anterior pseudocavity at the level of the dehiscence.

When the light of the laparoscope was turned off, red light is visible by laparoscopy at the site of the scar during hysteroscopic examination. And the upper and lower edge of the scar was recognized.

The scar was excised laparoscopically. The first 45 patients in this study underwent incomplete excision of the fibrotic tissue (only excised the top of the niche). And then we improved our technique, and the rest 101 patients underwent complete excision (Not only the “ceiling”, but also the lateral wall and the inferior edge of the pseudocavity was total excised). When excising the side wall of the niche, the uterine artery should not be injured, and the blood supply should be maintained. The endometrium of the posterior wall of the isthmus should be preserved, and the cervical stent is not needed to prevent from cervical adhesion when the endometrium of the posterior wall was intact.

A running suture or interrupted suture using 1/0 PDS II delayed absorbed material or Vicryl (Ethicon, Somerville, NJ, U.S.A) closed the scar. And great cautious was taken to suture the whole layer of the myometrium and endometrium of the cervical isthmus and every suture entered into the cavity of the cervical canal. An additional mattress suture completed the closure of the scar. Then the scar was covered with peritoneum.

Finally, we confirmed that the diverticulum was not obvious by hysteroscopy and operation was completed.

Clinical outcome measurement

Patients' perioperative data, including operative time, estimated blood loss, hemoglobin decreases, postoperative hospitalization le-

Laparoscopic repair of cesarean section scar defect

Table 2. Perioperative data of the two groups

Parameter, mean \pm SD or n (range)	Incomplete excision group (n=45)	Complete excision group (n=101)	P value
Operating time (min)	79.86 \pm 27.24	84.78 \pm 21.26	0.269
Estimated blood loss (ml)	58.21 \pm 26.57	78.89 \pm 20.67	0.087
Hospital stay (d)	7.31 \pm 3.18	6.88 \pm 2.22	0.892
Complications (n)	0	0	
Transfusion (n)	0	0	
Total Cost (\$)	2017.13 \pm 708.08	2346.91 \pm 587.05	0.130

Abbreviations: SD, standard deviation.

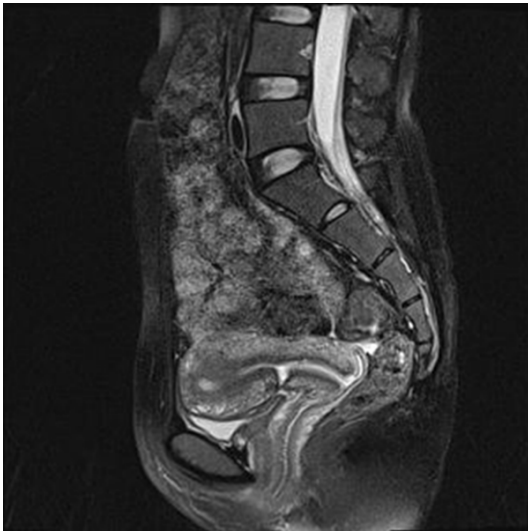

Figure 6. MRI image of one patient before and 6 months after the laparoscopic repair. MRI before surgery showed the presence of a reservoir-like pouch on the anterior wall of the uterine isthmus at the site of a previous cesarean delivery scar.

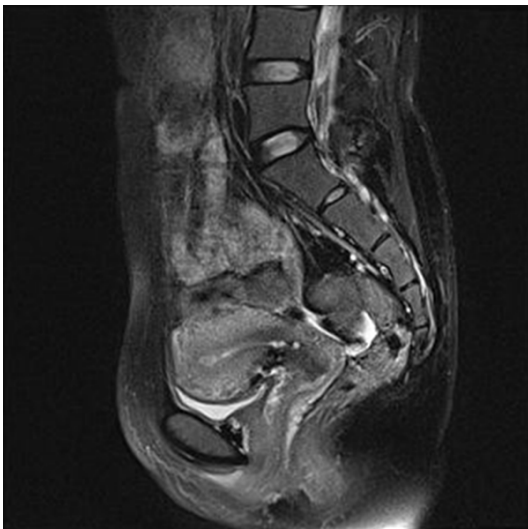

Figure 7. Pouch on the anterior wall of the uterine isthmus was disappeared 6 months after the laparoscopic repair.

length, total cost and intra- and postoperative complications were recorded.

The patients were regularly followed up at 1, 3 and 6 months, then annually after surgery.

MRI before and 6 months after surgery were done in all the patients in the late luteal phase, because the thick endometrium helps to delineate the defect more clearly.

Statistical analysis

SPSS for Windows version 13.0 (SPSS Inc., Chicago, IL) was used for all statistical calculations. Data are expressed as the mean \pm standard deviation (SD). Student's t-test or chi-square tests were used, as appropriate.

Logistic regression analysis was used to identify risk factors for successful healing of the repair. For univariate analysis, the variables (Duration of menstruation before surgery, thickness of the residual myometrium before surgery, number of previous cesarean section, duration from symptom to operation, experienced or inexperienced surgeon, complete or incomplete excision of the scar, estimated blood loss, operating time and different suturing material) were analyzed using the chi-square test. Variables with a *P* value of <0.1 on univariate analysis or by a priori determination to be of clinical importance were subsequently included building the multivariate model. Odds ratios (OR) were reported with a 95% confidence interval. Tests of significance were two-tailed, and significance was defined by $P < 0.05$.

Results

A total of 146 patients were included in the study. During these surgical procedures, no complications occurred and none of the patients needed blood transfusion. Perioperative data are shown in **Table 2**.

The patients were followed-up for an average of 41.18 ± 11.15 (6-69) months after the operation. 3 patients were lost in the follow-up. Postmenstrual spotting and prolonged period was the main symptom of the patients, and the lengths of period in these patients were recorded and analyzed (42/45 in the incomplete

Laparoscopic repair of cesarean section scar defect

Table 3. Follow-up data of the two groups

Parameter, mean ± SD or n (range)	Incomplete excision group (n=42)	Complete excision group (n=97)	P value
Duration of menstruation before surgery (d)	15.11±3.64 (7-22)	14.51±4.29 (7-20)	0.94
Duration of menstruation after surgery (d)	9.02±2.94 (4-18)	7.75±2.77 (4-18)	0.764
Cured (≤7 d)	35.56%	60.98%	0.024
Improved (8 d~10 d)	35.87%	22.53%	
Ineffective (>10 d)	28.57%	16.49%	
Niche detected by MRI 6 months post surgery	32.1%	26.2%	0.092

Abbreviations: SD, standard deviation.

Table 4. Factors influencing the surgical effect of laparoscopic repair of cesarean section scar diverticula

Variable	Surgical effect		Odds ratio (95% CI)	P value
	n	Effective rate (%)		
Duration of menstruation before surgery (d)				
≤14	62	80.33%	1	
>14	77	79.22%	0.93 (0.4-2.15)	0.872
Thickness of the residual Myometrium (mm)				
<3	79	73.42%	1	
≥3	60	88.33%	2.76 (1.68-4.55)	0.026
Number of previous cesarean section (n)				
1	97	80.41%	1	
2	42	78.57%	0.89 (0.37-2.17)	0.805
Duration from symptom to operation (y)				
≤2	25	68%	1	
>2	114	82.46%	2.21 (0.84-5.83)	0.119
Different surgeon				
Inexperienced (≤10 cases/y)	35	71.43%	1	
Experienced (>10 cases/y)	104	82.69%	1.91 (0.78-4.67)	0.160
Complete or incomplete excision				
Complete	97	83.51%	1	
Incomplete	42	71.43%	0.49 (0.21-1.16)	0.110
Estimated blood loss (ml)				
≤60	92	75%	1	
>60	47	89.36%	2.8 (0.98-7.93)	0.040
Operating time (min)				
≤90	98	80.61%	1	
>90	41	78.05%	0.86 (0.35-2.89)	0.730
Suturing material				
Absorbable	27	55.56%	1	
Delayed absorbable	112	85.71%	4.8 (1.9-12.1)	0.001

Abbreviations: OR, Odds ratio.

group, and 97/101 in the complete excision group). Six month after surgery, cured was defined as the duration of the period ≤7 d; improved was defined as 8≤ the duration ≤10 d; Uneffective mean the duration >10 d.

Effective rate equaled cured rate plus improved rate. The clinical effective rate in all patients was 79.86%. The patients in the complete excision group had an obvious shortened period after surgery (P<0.001), and the duration was

Laparoscopic repair of cesarean section scar defect

Table 5. Logistic regression analysis of factors related to surgical effect

Variable	OR	95% CI	P value
Duration of menstruation before surgery (>14 d VS. ≤14 d)	0.607	0.222-1.661	0.331
Thickness of the residual myometrium (≥3 mm VS. <3 mm)	2.959	1.023-8.563	0.045
Number of previous cesarean section (2 times VS 1 times)	1.295	0.456-3.674	0.627
Duration from symptom to operation (>2 year VS. ≤2 year)	1.763	0.577-5.388	0.320
Different surgeon (Inexperienced VS. Experienced)	0.771	0.201-2.951	0.704
Estimated blood loss (>60 ml VS. ≤60 ml)	2.989	0.926-9.651	0.067
Operating time (>90 min VS. ≤90 min)	0.876	0.318-2.411	0.798
Complete or incomplete excision (Incomplete VS. Complete)	0.987	0.348-2.80	0.980
Suturing material (Delayed absorbable VS. Absorbable)	6.204	1.576-24.422	0.009

Abbreviations: OR, Odds ratio.

Table 6. Postoperative pregnancy outcome of patients in the two groups

Parameter, mean ± SD or n (range)	Patients (n=32)
Pregnancy	12 (37.5%)
Term Cesarean delivery	8 (25.0%)
Preterm Cesarean delivery	2 (6.25%)
Artificial Abortion	1 (3.13%)
Cesarean scar pregnancy	1 (3.13%)

7.75±2.77 days (4-18 days). The clinical effective rate was 83.51%. The patients in the incomplete excision group also had an obvious shortened period after surgery ($P<0.001$), and the duration was 9.02±2.94 days (4-18 days). The clinical effective rate was 71.43%. All the patients did MRI before and 6 months after the repair (**Figures 6, 7**). MRI image 6 months after surgery showed there was still small niche in 32.1% and 26.2% of the patients in the incomplete and complete excision group (**Table 3**).

Table 4 shows the results of single factor logistic regression analysis regarding the effect of factors on the surgical effective rate. Single factor analysis showed that the thickness of the residual myometrium (≥3 mm vs <3 mm) (88.33% vs. 73.72%, Odds ratio 0.76, 95% CI 1.68-4.55, $P=0.026$), suturing material (delayed absorbable vs absorbable material), (85.71% vs. 55.56%, Odds ratio 4.8, 95% CI 1.9-12.1, $P=0.001$) and estimated blood loss (≤60 ml vs >60 ml) (75% vs. 89.36%, Odds ratio 2.8, 95% CI 0.98-7.93, $P=0.040$) were correlated with the effects of surgery. Duration of menstruation before surgery, number of previous cesarean section, duration from symptom to operation, experienced (> 10 cases/y) or inexperienced surgeon, complete or incom-

plete excision of the scar and operating time were not related to the surgical effective rate.

Multivariate logistic regression analysis showed that the thickness of the residual myometrium and suturing material were independent risk factors for successful healing of the repair (**Table 5**). The odds ratios for the residual myometrium (≥3 mm vs <3 mm) and suturing material (delayed absorbable vs absorbable material) were 2.959 (95% confidence interval: 1.023-8.563) and 6.204 (95% confidence interval: 2.4-1.576-24.422), respectively.

Twenty-six patients had secondary infertility and thirty-two patients desired for fertility in this study, and 12 of them got pregnant naturally in 13-32 months after surgery. Postoperative pregnancy outcome of patients in the two groups are shown in **Table 6**. There was no uterine rupture. However, there was 1 Cesarean scar pregnancy after incomplete excision of the scar and reconstruction of the uterus, and her MRI 6 months after the surgery showed there was still a small niche measuring 0.7*0.5*0.6 cm with the thickness of the residual myometrium measuring 0.6 cm.

Discussion

In this retrospective study, we described laparoscopic repair of PCSD in a series of 146 patients in our hospital, reported the surgical outcome and pregnancy outcome, and analyzed the risk factors for successful healing of the repair. Our results showed that comparing with the incomplete excision group, the complete excision of PCSD had a significantly higher surgical effective rate, and lower detectable rate of niche 6 months after surgery. Mul-

Laparoscopic repair of cesarean section scar defect

tivariate logistic regression analysis showed that the thickness of the residual myometrium and suturing material were independent risk factors for successful healing of the repair.

Various niche resection and niche repair, including abdominal, laparoscopic, robotic, or vaginal repair [9-18], are currently used to treat symptoms related to the niche in the cesarean scar, in particular to treat abnormal uterine bleeding (AUB).

All of the studies included reported on women with AUB. AUB was reported to be improved in 87% (hysteroscopic resection), 100% (laparoscopic repair), 93% (vaginal repair), and 91% (OCs) of women [9]. Laparoscopic resection and repair in 3 patients with wide and deep PCSD were firstly reported in 2008 by Donnez O et al [9], and all had good postoperative anatomic outcomes. Marotta et al [10] reported laparoscopic repair of PCSD in a series of 13 patients with good anatomic and fertility outcome. However, the sample sizes and follow-up of the previous studies on laparoscopic repair were insufficient, which involves a risk of reporting bias. In this study, we described laparoscopic repair of PCSD in a series of 146 patients, who were followed-up for an average of 41.18 ± 11.15 (6-69) months, which was the largest reported sample size up to now.

All of the studies included reported on women with AUB. AUB was reported to be improved in 87% (hysteroscopic resection), 100% (laparoscopic repair), 93% (vaginal repair), and 91% (OCs) of women [19]. Our results showed that the patients in the incomplete and complete excision group both had an obviously shortened period after surgery ($P < 0.001$), the duration of period after repair was 9.02 ± 2.94 days and 7.75 ± 2.77 days ($P = 0.764$), and the clinical effective rate was 71.43% and 83.51% ($P = 0.024$). MRI image 6 months after surgery showed there was still small niche in 32.1% and 26.2% of the patients in the incomplete and complete excision group. Our effective rate was lower and the anatomic results was less satisfying than those in the previous report, maybe this is due to the large sample size and high detectable rate of PCSD by MRI.

The effective rate in the complete excision group was significantly higher than that in the incomplete excision group, so it is crucial to

make sure to excise all the defect and then repair. The inferior edge of the pseudocavity sometimes was mistakenly considered by some doctors to be the anatomic internal os of the isthmus. But accurately, the cesarean scar is located on the isthmus, which is below the anatomic internal os, and above the histologic internal os. So the defect should be excised to the inferior edge.

The estimated blood loss in the complete excision group was slightly more than that in the incomplete group (78.89 ± 20.67 vs 58.21 ± 26.57 ml, 0.087). Because when complete excision was done, the side wall of the niche was totally excised, which might lead to a higher possibility to injure the uterine artery. And this also explains why in the single factor analysis, estimated blood loss were correlated with the effects of surgery.

Logistic regression analysis was used to identify risk factors for successful healing of the repair. Multivariate logistic regression analysis showed that the thickness of the residual myometrium (Odds ratio 2.959, 95% CI 1.023-8.563) and suturing material (Odds ratio 6.204, 95% CI 1.576-24.422) were independent risk factors for successful healing of the repair. The result implied that deep and large defect has a higher ineffective repair rate. The effective repair rate was significantly higher, when sutured with delayed absorbable material (PDS-II) than with absorbable material (Vicryl). The reason might be that the delayed absorbable material sustains the strength longer and absorbs slower and this provided a longer time for the wound to recover.

The symptom of PCSD includes secondary sterility. Schepker N et al [18] hypothesized that in a similar manner to hydrosalpinx fluid, various fertility impairing reactions can occur in PCSD, e.g. changes in intracavitary pH as well as toxic effects on sperm ascension and embryo nidation, changes in endometrial activity, impaired quality of cervical mucus or "washout" of the blastocysts ready for implantation.

Compared with hysteroscopic revision of PCSD, laparoscopic repair method is suitable for use in all patients, whether or not they have fertility requirements. It corrects the defect and strengthens the uterine wall.

Laparoscopic repair of cesarean section scar defect

Seven studies reported on pregnancy outcomes without an adverse outcome in 52 women after hysteroscopic niche resection, in three women after laparoscopic niche repair, and in one woman after vaginal niche repair [19]. These women were all scheduled for an elective caesarean section, so the success rate for trial of labor after various niche therapies cannot be addressed. A recent study [18] reported uterus reconstruction by mini-laparotomy in 9 patients with PCSD, and natural pregnancy in three out of five patients (60%) with secondary sterility, including 1 term vaginal delivery, 1 preterm vaginal delivery, and 1 C-section due to premature labor. No uterine rupture occurred.

Twenty-six patients had secondary infertility and thirty-two patients desired for fertility in our study, and 12 of them got pregnant in 13-32 months after surgery, including 8 term cesarean delivery, 2 preterm cesarean delivery, 1 artificial abortion and 1 cesarean scar pregnancy. There was no uterine rupture. There was no attempt of term delivery in our study.

There are several limitations to our study. First, this is a retrospective study. Further prospective, large-sample, case-control studies are necessary to confirm the effectiveness of this approach. Second, the effect of this approach was not compared with other minimally invasive approaches.

Conclusion

In conclusion, we described laparoscopic repair of PCSD in a series of 146 patients in our hospital. This technique is safe, allows for future pregnancies, and is effective for the control or elimination of uterine bleeding. Laparoscopic complete excision and repair of PCSD may be performed with fair symptom relief and acceptable postoperative anatomic and functional outcomes.

Acknowledgements

This study was supported by advanced and appropriate technology promotion project of Shanghai health system (2013SY020) and the appropriate technology projects of Shanghai Municipal Hospital (SHDC12012218).

Disclosure of conflict of interest

None.

Authors' contribution

Xuyin Zhang, Yuan He, Jingxin Ding and Keqin Hua participated in the design of the study and performed the statistical analysis. Mengyi Yang, Chaoying Wu and Heyang Xu conceived of the study, and participated in its design and coordination and helped to draft the manuscript. All authors read and approved the final manuscript.

Abbreviations

PCSD, Previous lower uterine segment caesarean scar defect; OCs, oral contraceptives; AUB, abnormal uterine bleeding; SD, standard deviation; OR, Odds ratios.

Address correspondence to: Keqin Hua and Jingxin Ding, Department of Gynecology, The Obstetrics and Gynecology Hospital of Fudan University, 128 Shenyang Road, Shanghai 200090, China. E-mail: huaqin@fudan.ac.cn (KQH); djxdd@sina.com (JXD)

References

- [1] Betrán AP, Meriáldi M, Lauer JA, Bing-Shun W, Thomas J, Van Look P, Wagner M. Rates of caesarean section: analysis of global, regional and national estimates. *Paediatr Perinat Epidemiol* 2007; 21: 98-113.
- [2] Hamilton BE, Miniño AM, Martin JA, Kochanek KD, Strobino DM, Guyer B. Annual summary of vital statistics: 2005. *Pediatrics* 2007; 119: 345-60.
- [3] Bij de Vaate AJ, van der Voet LF, Naji O, Witmer M, Veersema S, Brölmann HA, Bourne T, Huirne JA. Prevalence, potential risk factors for development and symptoms related to the presence of uterine niches following caesarean section: systematic review. *Ultrasound Obstet Gynecol* 2014; 43: 372-382.
- [4] Osser OV, Jokubkiene L, Valentin L. High prevalence of defects in Cesarean section scars at transvaginal ultrasound examination. *Ultrasound Obstet Gynecol* 2009; 34: 90-97.
- [5] Surapaneni K, Silberzweig JE. Cesarean section scar diverticulum: appearance on hysterosalpingography. *AJR Am J Roentgenol* 2008; 190: 870-4.
- [6] Borges LM, Scapinelli A, de Baptista Depes D, Lippi UG, Coelho Lopes RG. Findings in patients with postmenstrual spotting with prior cesarean section. *J Minim Invasive Gynecol* 2010 17: 361-4.
- [7] Tower AM, Frishman GN. Cesarean scar defects: an under recognized cause of abnormal

Laparoscopic repair of cesarean section scar defect

- uterine bleeding and other gynecologic complications. *J Minim Invasive Gynecol* 2013; 20: 562-72.
- [8] van der Voet LF, Vervoort AJ, Veersema S, BijdeVaate AJ, Brölmann HA, Huirne JA. Minimally invasive therapy for gynaecological symptoms related to a niche in the cesarean scar: a systematic review. *BJOG* 2014; 121: 145-156.
- [9] Donnez O, Jadoul P, Squifflet J, Donnez J. Laparoscopic repair of wide and deep uterine scar dehiscence after cesarean section. *Fertil Steril* 2008; 89: 974-80.
- [10] Marotta ML, Donnez J, Squifflet J, Jadoul P, Darii N, Donnez O. Laparoscopic repair of post-cesarean section uterine scar defects diagnosed in nonpregnant women. *J Minim Invasive Gynecol* 2013; 20: 386-91.
- [11] Klemm P, Koehler C, Mangler M, Schneider U, Schneider A. Laparoscopic and vaginal repair of uterine scar dehiscence following cesarean section as detected by ultrasound. *J Perinat Med* 2005; 33: 324-31.
- [12] Kostov P, Huber AW, Rai L, Mueller MD. Uterine scar dehiscence repair in rendez-vous technique. *Gynaecol Surg* 2009; 6: S65.
- [13] Yalcinkaya TM, Akar ME, Kammire LD, Johnston-MacAnanny EB, Mertz HL. Robotic-assisted laparoscopic repair of symptomatic cesarean scar defect: a report of two cases. *J Reprod Med* 2011; 56: 265-70.
- [14] Bradshaw AD, Advincula AP. Robot-assisted repair of cesarean scar defect. *J Minim Invasive Gynecol* 2010; 17: S11.
- [15] La Rosa MF, McCarthy S, Richter C, Azodi M. Robotic repair of uterine dehiscence. *JLS* 2013; 17: 156-60.
- [16] Khoshnow Q, Pardey J, Uppal T. Transvaginal repair of caesarean scar dehiscence. *Aust N Z J Obstet Gynaecol* 2010; 50: 94-5.
- [17] Luo L, Niu G, Wang Q, Xie HZ, Yao SZ. Vaginal repair of cesarean section scar diverticula. *J Minim Invasive Gynecol* 2012; 19: 454-8.
- [18] Schepker N, Garcia-Rocha GJ, von Versen-Höynck F, Hillemanns P, Schippert C. Clinical diagnosis and therapy of uterine scar defects after caesarean section in non-pregnant women. *Arch Gynecol Obstet* 2015; 291: 1417-23.
- [19] Van der Voet LF, Bij de Vaate AM, Veersema S, Brölmann HA, Huirne JA. Long-term complications of caesarean section. The niche in the scar: a prospective cohort study on niche prevalence and its relation to abnormal uterine bleeding. *BJOG* 2014; 121: 236-244.