



# Correlation of clinical and ultrasonographic findings after Achilles tenotomy in idiopathic club foot

S. L. Barker,  
C. B. D. Lavy

From Beit Trust  
CURE International  
Hospital, Blantyre,  
Malawi

**Achilles tenotomy is a recognised step in the Ponseti technique for the correction of idiopathic congenital talipes equinovarus in most percutaneous cases. Its use has been limited in part by concern that the subsequent natural history of the tendon is unknown. In a study of 11 tendons in eight infants, eight tendons were shown to be clinically intact and ten had ultrasonographic evidence of continuity three weeks after tenotomy. At six weeks after tenotomy all tendons had both clinical and ultrasonographic evidence of continuity.**

Idiopathic congenital talipes equinovarus can be managed by the technique described by Ponseti in infants under one year of age with a success rate in excess of 90%.<sup>1-3</sup>

Percutaneous Achilles tenotomy just above the calcaneal insertion may be used in up to 95% of patients based on the hypothesis of Ponseti and others that the tendon appears to re-unite within three weeks.<sup>2,4,5</sup> Two previous studies have demonstrated healing when the tendon was completely sectioned more proximally at the musculotendinous junction in children with cerebral palsy<sup>6</sup> or inadvertently in percutaneous triple hemisection lengthening of tendo Achillis.<sup>7</sup>

We use the Ponseti technique and believe it to be of particular value in countries where there are few surgeons, and operative resources are scarce. One author (CBDL) has been involved in teaching the technique in several other developing countries and has noticed a marked reluctance among clinicians to perform Achilles tenotomy, not because they feel that the technique is difficult, but because they fear the consequences of complete division of a major tendon.

The aim of this study was to test the hypothesis, by clinical assessment and ultrasound imaging, that healing occurs rapidly and spontaneously following mid-substance transverse Achilles tenotomy in infants.

## Patients and Methods

In the first three months of 2005 patients attending a single centre with a *de novo* diagnosis of idiopathic congenital talipes equinovarus with no syndromic association were enrolled in the study. Each foot had already

been treated by serial casting and had reached the point at which tenotomy was considered to be necessary by an orthopaedic surgeon (SLB) according to the criteria of Ponseti<sup>5</sup> whereby the otherwise corrected foot could not be brought into passive dorsiflexion beyond the plantigrade position.

The study was explained to parents/guardians and signed consent obtained with details available in the local Chichewa language. There were eight infants with a total of 11 feet, five boys (two bilateral) and three girls (one bilateral). The mean age at tenotomy was 127 days (45 to 254). Each infant underwent clinical and ultrasonographic assessment before tenotomy was undertaken. Clinical assessment was undertaken with the foot in maximum passive dorsiflexion. Tendo Achillis was palpated and graded as absent, indeterminate or palpable. An ultrasound scan was taken over the posterior/lateral aspect of heel. A Toshiba 'Tosbee' Scanner (Toshiba Medical Systems, Crawley, UK) with 7.5 MHz probe was used longitudinally to determine the integrity of the tendon and positioned away from the proposed tenotomy wound. The result was recorded as normal if the tendon was in continuity, indeterminate if it was not possible to identify a tendon clearly, or absent when discontinuity was noted.

The tenotomy was performed by a medial percutaneous stab incision using a size 15 blade 2 cm above the calcaneum to cut the tendon from front to back according to the Ponseti technique.<sup>5</sup> Care was taken to avoid inserting the blade any deeper than necessary and to position it posteriorly in order to avoid the posterior tibial neurovascular bundle and other tendons.

■ S. L. Barker, MD, FRCS Ed  
(Tr & Orth), Specialist  
Registrar  
Department of Orthopaedic  
Surgery  
Woodend Hospital, Eday  
Road, Aberdeen AB15 6ZQ,  
UK.

■ C. B. D. Lavy, MCh, FCS,  
FRCS, Professor  
Department of Orthopaedic  
Surgery  
College of Medicine, Private  
Bag 360, Blantyre 3, Malawi.

Correspondence should be  
sent to Mr S. L. Barker;  
e-mail: s.barker@nhs.net

©2006 British Editorial  
Society of Bone and  
Joint Surgery  
doi:10.1302/0301-620X.88B3.  
17273 \$2.00

*J Bone Joint Surg [Br]*  
2006;88-B:377-9.  
Received 6 October 2005;  
Accepted 9 November 2005

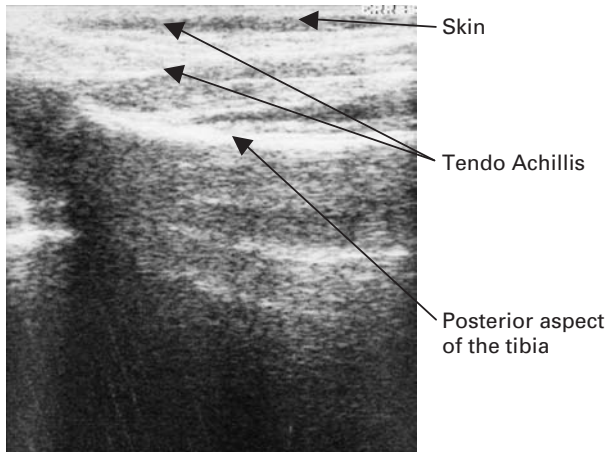


Fig. 1

Ultrasound scan showing the intact tendon before tenotomy, scanned from the posterolateral aspect. Real-time ultrasonography showed continuity of the tendon during flexion and extension of the ankle.

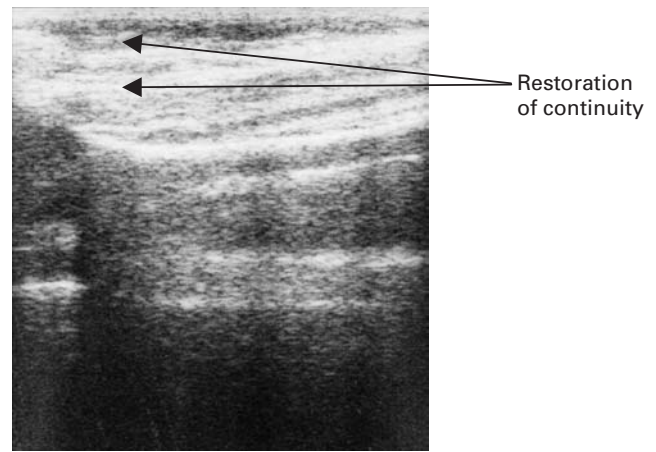


Fig. 3

Ultrasound scan three weeks after sectioning showing healing of the tendon, with continuity seen on real-time ultrasonography.

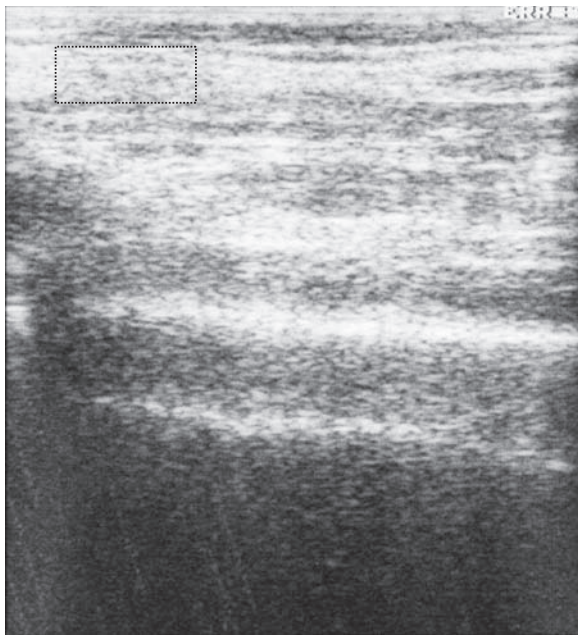


Fig. 2

Ultrasound scan showing the tendon immediately after sectioning. Real-time ultrasonography showed movement between the two ends of the cut tendon. The dotted line shows the region of the haematoma between the cut ends of the tendon.

In each foot clinical evidence of a successful tenotomy was taken as a definitive increase in dorsiflexion at the ankle and lack of a palpable heel cord. Immediately after the tenotomy the ultrasound scan was repeated. The limb was then placed in a moulded plaster. Further clinical and ultrasonographic assessment was undertaken during sched-

**Table I.** Clinical and ultrasonographic findings before and immediately after tenotomy and at three and six weeks after healing

Stage	Number of tendons clinically intact	Number of tendons shown to have continuity by ultrasound
Pre-tenotomy	11	11
Immediately after tenotomy	0	0
Three weeks after tenotomy	8	10
Six weeks after tenotomy	11	11

uled changes of the plaster at three and six weeks after the tenotomy. Provision was made for further three-weekly scans should healing not have been demonstrated by six weeks after the tenotomy.

**Results**

In all feet a palpable tendo Achillis had been noted and pre-operative ultrasound demonstrated a tendon in continuity (Fig. 1). It should be noted that although the structures could be seen in the static image, the tendon could be seen to move independently of the surrounding structures on the dynamic or real-time image. The tenotomy was performed without significant bleeding or complications. Post-tenotomy clinical assessment showed absence of the previously prominent tendon in all feet and a palpable gap in many. Post-tenotomy ultrasonographic assessment showed a gap in the tendon in 11 feet (Fig. 2).

The clinical and ultrasonographic findings before and immediately after tenotomy and at three and six weeks after healing are given in Table I. All tendons showed clinical evidence of an intact heel cord and ultrasonographic evidence of continuity by six weeks. Although the restoration of continuity is best appreciated in a dynamic scan,

Figure 3 shows a captured image of an intact tendon at three weeks.

### Discussion

The Ponseti technique for the treatment of idiopathic congenital talipes equinovarus has been shown to be very effective.<sup>3</sup> It requires little technology and is therefore suited to Africa and other areas with poor technological resources.

Reluctance to consider complete tenotomy of tendo Achillis may stem from three understandable concerns. First, sectioning of a tendon is not a normally-recommended treatment. Secondly, other structures may be inadvertently damaged during tenotomy and lastly the tendon may not heal satisfactorily. A recent report of the use of botulinum toxin A as an alternative way of defunctioning the tendo Achillis<sup>8</sup> is limited by the availability of this toxin and its prohibitive cost in developing countries.

If reluctance to use percutaneous tenotomy cannot be overcome, the rate of tenotomy will be lower with a greater risk of failed correction. The indications for surgical tenotomy in orthopaedic surgery are limited and are usually reserved for fixed shortening of a muscle or muscle group. An infant with idiopathic congenital talipes equinovarus is a 'special case' by virtue of the abnormal gastrosoleal muscle complex in the calf. There is a definite risk of iatrogenic damage to adjacent structures if the tenotomy knife is used injudiciously. This can be obviated or significantly reduced in developed countries by the use of an open technique under general anaesthesia, but elsewhere in the world there is a risk of or lack of general anaesthesia. Complications of percutaneous tenotomy have been described,<sup>9</sup> but in our study none were experienced, although the number of patients treated was small.

To overcome the final objection to tenotomy there must be a plausible mechanism to explain regeneration of the tendon and experimental evidence for it. Healing of the tendon has classically been described as involving extrinsic or

intrinsic factors or a combination of the two. Recent research has suggested that embryonic mechanisms may be responsible for healing in the adult tendon.<sup>10,11</sup> Thus the rapid healing in infants aged one to two months in whom progenitor cells are abundant, could involve the same mechanism.

Our study has shown that tendo Achillis can heal spontaneously and rapidly within six weeks. It does not comment on the strength of the healed tendon, but late rupture after this procedure has not been reported.

The authors are grateful to the staff of the Clubfoot Clinic at Beit CURE International Hospital, Malawi.

No benefits in any form have been received or will be received from a commercial party related directly or indirectly to the subject of this article.

### References

1. Lehman WB, Mohaideen A, Madan S, et al. A method for the early evaluation of the Ponseti (Iowa) technique for the treatment of idiopathic clubfoot. *J Pediatr Orthop* 2003;12:133-40.
2. Herzenberg JE, Radler C, Bor N, et al. Ponseti versus traditional methods of casting for idiopathic clubfoot. *J Pediatr Orthop* 2002;22:517-21.
3. Colburn M, Williams M, Colburn M, Williams M. Evaluation of the treatment of idiopathic clubfoot by using the Ponseti method. *J Foot Ankle Surg* 2003;42:259-67.
4. Scher DM, Feldman DS, van Bosse HJ, Sala DA, Lehman WB. Predicting the need for tenotomy in the Ponseti method for correction of clubfeet. *J Pediatr Orthop* 2004;24:349-52.
5. Ponseti IV. *Congenital clubfoot: fundamentals of treatment*. Oxford: Oxford University Press, 1996.
6. Weigl D, Copeliovitch L, Itzchak Y, Strauss S. Sonographic healing stages of Achilles tendon after tenomuscular lengthening in children with cerebral palsy. *J Pediatr Orthop* 2001;21:778-83.
7. Berg EE. Percutaneous Achilles tendon lengthening complicated by inadvertent tenotomy. *J Pediatr Orthop* 1992;12:341-3.
8. Alvarez CM, Tredwell SJ, Keenan SP, et al. Treatment of idiopathic clubfoot utilizing botulinum A toxin: a new method and its short-term outcomes. *J Pediatr Orthop* 2005;25:229-35.
9. Dobbs MB, Gordon JE, Walton T, Schoenecker PL. Bleeding complications following percutaneous tendoachilles tenotomy in the treatment of clubfoot deformity. *J Pediatr Orthop* 2004;24:353-7.
10. Lin TW, Cardenas L, Soslowsky LJ. Biomechanics of tendon injury and repair. *J Biomech* 2004;37:865-77.
11. Ingraham JM, Hauck RM, Ehrlich HP. Is the tendon embryogenesis process resurrected during tendon healing? *Plast Reconstr Surg* 2003;112:844-54.