

## Allergic Fungal Rhinosinusitis

Ashok K Gupta, Nishit Shah, Mohan Kameswaran, Davinder Rai, TN Janakiram, Hemant Chopra, Ravi Nayar Arvind Soni, NK Mohindroo, C Madhu Sudana Rao, Sandeep Bansal, KR Meghnadh, Neelam Vaid Hetal Marfatia Patel, Sanjay Sood, Sunita Kanojia, Kshitij Charaya, SC Pandhi, SBS Mann

### ABSTRACT

Allergic fungal rhinosinusitis (AFRS) has always remained a topic of discussion at all rhinology meets. Despite so much of literature available, the nature of this disease, its diagnosis, pathogenesis, classification and appropriate management continue to generate debate and controversy even after three decades of research and investigation. AFRS is an endemic disease in North and South India. In spite of this, there has been no optimal management protocol for this disease being followed in India yet. To overcome this, a national panel was conducted on AFRS at the ENT Surgical Update 2011, held at Postgraduate Institute of Medical Education and Research, Chandigarh with experts from all over the country so that a consensus can be achieved regarding the workup and management of AFRS.

**Keywords:** Rhinosinusitis, Allergic fungal sinusitis, Management protocol.

**How to cite this article:** Gupta AK, Shah N, Kameswaran M, Rai D, Janakiram TN, Chopra H, Nayar R, Soni A, Mohindroo NK, Rao CMS, Bansal S, Meghnadh KR, Vaid N, Patel HM, Sood S, Kanojia S, Charaya K, Pandhi SC, Mann SBS. Allergic Fungal Rhinosinusitis. Clin Rhinol An Int J 2012;5(2): 72-86.

**Source of support:** Nil

**Conflict of interest:** None declared

### INTRODUCTION

Allergic fungal rhinosinusitis (AFRS) was recognized for the first time in 1976 when in some patients thick, dark, inspissated mucus was noticed filling the paranasal sinuses, similar both grossly and microscopically to that seen in the bronchial passages of patients with allergic bronchopulmonary aspergillosis (ABPA).<sup>1-3</sup> It is invariably associated with nasal polyposis and the presence of allergic fungal mucin. Allergic fungal mucin is thick and tenacious macroscopically having a brown or greenish black color. This mucus consists of onion-skin laminations of necrotic eosinophils in various stages of degeneration, occasional small hexagonal crystals of lysophospholipase (Charcot-Leyden crystals) and scanty fungal hyphae on histology. It is a nontissue invasive fungal process, representing an allergic/hypersensitivity response to the presence of extramucosal fungi within the sinus cavity in which a strong IgE-mediated hypersensitivity to fungal elements drives the inflammatory process. *Aspergillus* and the dematiaceous fungi are most commonly found in AFRS mucus.<sup>4-6</sup> The preferred terminology for this condition is now 'allergic fungal rhinosinusitis' or AFRS though once it was called 'allergic' *Aspergillus* sinusitis. There are a lot of variations

seen in patients with similar clinical presentation as AFRS. It has been noted that in some cases, the eosinophilic mucin from the sinuses does not have identifiable fungal elements.<sup>6,7</sup> Ferguson described an AFRS-like condition with slightly different clinical features and proposed the term 'eosinophilic mucin rhinosinusitis' (EMRS) to describe cases in which fungus was not identified histologically.<sup>8</sup>

On the other hand some patients with clinical features of AFRS may have demonstrable fungus within their eosinophilic mucin, but no allergy.<sup>9</sup> There have been cases isolated with no allergy; no fungi in mucin but still have eosinophilic mucin. Ponikau et al postulated that most, if not all, CRS was a hypersensitivity response to fungi and that fungi could be universally cultured from nasal secretions also further clouded the distinction between AFRS and AFRS-like CRS.<sup>10</sup> The nature of this disease, its diagnosis, pathogenesis, classification and appropriate management continue to generate debate and controversy even after three decades of research and investigation.

### PATHOGENESIS

AFRS was described as distinct clinical entity by Millar in 1981<sup>3</sup> and Katzenstein<sup>2</sup> in 1983 characterized by atopy, sinonasal polyposis and the presence of allergic mucin. It was thought that the fungus in the sinuses would have potential for tissue invasion so extensive surgical debridement followed by the use of systemic antifungal agents was the treatment of choice those days. The realization that AFRS may represent an immunological response to presentation of a fungal antigen within a susceptible host leads to the discontinuation of such treatment. As in ABPA, an atopic host is exposed to fungi through normal nasal respiration, thus providing an initial antigenic stimulus. Gel and Coombs type I (IgE) and III (immune complex) mediated reactions trigger an intense eosinophilic inflammatory response. Any anatomic obstruction, such as septal deviation or turbinate hypertrophy, accentuates the already inflamed mucosa which in turn leads to obstruction of sinus ostia resulting in stasis of mucus within the sinuses. This, in turn, creates an ideal environment for further proliferation of the fungus, thus increasing the antigenic exposure. This sets up a vicious cycle and produces a lot of allergic mucin.

This immunological aspect in the pathogenesis was supported by studies by Manning and Holman.<sup>11</sup> In their

first study on eight patients, culture-positive bipolaris AFRS were prospectively compared with 10 controls with chronic rhinosinusitis. All eight patients with AFRS had positive skin test reactions to bipolaris antigen, as well as significant levels of bipolaris specific IgE and IgG by *in vitro* testing. Eight of the 10 control demonstrated negative results to both skin and serologic testing, suggesting that the presence of allergy to fungus as being important in the pathogenesis of AFRS.

In another study by them<sup>11</sup> sinus mucosal specimens from 14 patients with AFRS were compared with those from 10 controls with chronic rhinosinusitis. Immunohistochemical analysis for eosinophilic mediators (major basic protein and eosinophilic derived neurotoxin) and a neutrophil-derived mediator (neutrophil elastase) was performed to compare the underlying inflammatory processes within each cohort. Inflammatory mediators derived from eosinophils predominated over neutrophil-derived mediators in the AFRS group, whereas significant differences were not present within the control group. The relative predominance of eosinophil-derived inflammatory mediators as compared to neutrophil-derived inflammatory mediators further support the association between non-infectious (i.e. immunologically mediated) inflammation and AFRS, and helps to differentiate this disease from other forms of chronic rhinosinusitis. This is further supported by the study by Stewart and Hunsaker<sup>12</sup> in which they analyzed fungal-specific serum IgE and IgG levels in nonatopic controls, allergic rhinitis patients, non-AFRS polyp patients, AFRS-like patients and AFRS patients. It was found that in patients with AFRS and AFRS-like group there was elevated serum levels of IgE and IgG to multiple fungi.

The concept of eosinophilic activation associated with AFRS was further supported by Feger et al<sup>13</sup> who studied eosinophilic cationic protein (ECP) levels in the serum and mucin of patients with AFRS. No differences in serum ECP were detected between patients with AFRS and controls, but ECP levels were significantly higher in mucin from patients with AFRS as compared to controls.

These studies by Manning et al<sup>11</sup> and Feger et al<sup>13</sup> while supporting that AFRS represents an immunologically-mediated disorder rather than an early stage of invasive fungal disease fuelled further speculation regarding the pathophysiology of AFRS.

In 1999 a 'unifying hypothesis' of CRS was proposed by Ponikau et al.<sup>10</sup> They used a specially designed culture technique, and found that 93% of 101 consecutive patients with CRS demonstrated the presence of fungi obtained from nasal lavage and surgically obtained specimen. In contrast to prior AFRS studies, conventional IgE-mediated allergy

to fungi was not consistently observed. It was therefore proposed that virtually all cases of chronic rhinosinusitis were associated with sensitization to colonizing fungi. It was further suggested that the term 'allergic fungal rhinosinusitis' be replaced with 'eosinophilic fungal rhinosinusitis' (EFRS).<sup>10</sup> These findings have led to their belief that IgE-mediated inflammation is not crucial to the development of AFRS, and that eosinophilic chemotaxis and activation may result from a T lymphocyte-mediated inflammatory cascade. One potential problem with the common etiology that was proposed by the authors was the fact that fungi were also observed in 100% of normal control subjects.

In a study on humoral immune response in patients with EMCRS including AFRS Pant et al<sup>9</sup> found that patients with AFRS had increases in fungal-specific IgE and total IgE but these were no different from a control group with allergic rhinitis. Though there was a poor correlation between fungal species present in the eosinophilic mucin of AFRS patients and the specific fungal allergy (42%) but elevated fungal-specific IgG3 was a distinguishing serologic feature that separated EMCRS and AFRS patients from those with fungal allergic rhinitis and other forms of CRS. Moreover, serum IgE levels could be used to distinguish EMCRS from AFRS. Another clinically important distinguishing feature of AFRS is type 1 hypersensitivity. Therefore, type 1 hypersensitivity to fungal antigens, as assessed by specific allergy tests, helps to distinguish AFRS from other forms of EMCRS and has implications for treatment.

Recently in 2009 Luong et al<sup>14</sup> found that peripheral blood mononuclear cells from AFRS patients are stimulated by fungal antigens to secrete TH2-type cytokines.

In spite of all these studies supporting humoral immune factors, the underlying pathophysiology in AFRS remains steeped in controversy. Although it appears clear that the eosinophil plays an important role in the development of both AFRS and some forms of chronic rhinosinusitis, the factors that ultimately trigger eosinophilic inflammation remain in question.

In summary, it can be said that initiation of the inflammatory reaction leading to AFRS is a multifactorial event, governed by IgE-mediated sensitivity (atopy), humoral expression, exposure to specific fungi and aberration of local mucosal defence mechanisms.

## Epidemiology and Clinical Presentation

It is estimated that approximately 5 to 10% of those patients with chronic rhinosinusitis actually carry a diagnosis of AFRS.<sup>2</sup> It is most common among adolescents and young adults (mean age; 21.9 year).<sup>11</sup> The incidence of AFRS

appears to be impacted by geographic factors. On review of literature it was found that the majority of sites reported cases of AFRS to be located in temperate regions with relatively high humidity. In United States most cases are found in the southern central region of the country along the Mississippi basin.<sup>15</sup> In India, fungal sinusitis is maximally reported from North India<sup>16-18</sup> and South India.<sup>19</sup>

Initially, *Aspergillus* was believed to be the causative organism in AFRS, but dematiaceous fungi were most commonly found in AFRS mucus, in different studies conducted in the United States.<sup>20,21</sup> In other parts of the world, *Aspergillus* is still found to be a common isolate in cases of AFRS and nonallergic eosinophilic fungal sinusitis.<sup>17,22</sup> Identification of the specific fungal organism is important only for making a diagnosis, it does not have any prognostic value nor does it make any difference in the planning of the treatment protocol.

AFRS occurs in adolescents and young adults who often have asthma that is exacerbated by their sinusitis. All patients are immunocompetent and have a strong history of atopy. All have nasal polyps and chronic sinusitis. There is no increased aspirin sensitivity despite the association with asthma and nasal polyps.

The development of nasal airway obstruction is gradual and the patient is unaware of its presence and presents only when there is complete nasal obstruction or may develop more serious symptoms like headaches and visual disturbances. Facial dysmorphism if present is also often so slow that its identification escapes notice of the patient and family members. The slow accumulation of allergic fungal mucin imparts unique and predictable characteristics to the disease. Allergic fungal mucin is sequestered within involve paranasal sinus cavities. As its quantity increases, the involved paranasal sinus begins to resemble and behave in a way consistent with a mucocele (sometimes referred to as a fungal mucocele).<sup>23</sup> With time, bony remodeling and decalcification may occur, causing the disease to mimic 'invasion' into adjacent anatomic spaces. The location of bone destruction seems to be determined simply by the location of the disease, and this destruction often gives rise to exophthalmos, facial dysmorphism or intracranial extension without tissue invasion.<sup>24</sup>

In cases of allergic fungal sinusitis, the mechanism of vision loss has thus, far been assumed to be secondary to direct compression or direct inflammation of the optic nerve. Gupta et al hypothesized that there may be aberrant anatomical pathways present in the region of the optic canal could have been responsible for direct inflammation of the nerve in the absence of obvious bony erosion apart from mechanical compression of the optic nerve, a local immunological reaction to fungal antigens might be responsible for the visual loss seen in allergic fungal sinusitis.<sup>25</sup>

## Diagnostic Criteria

A patient with AFRS classically is a young (mean age is 22 years), immunocompetent patient with unilateral or asymmetric involvement of the paranasal sinuses, a history of atopy, nasal casts and polyposis, and a lack of significant pain.<sup>11</sup> Nasal casts are green to black rubbery formed elements made of allergic mucin. The presentation may be dramatic, with a significant number of patients presenting with proptosis, telecanthus or gross facial dysmorphism.<sup>17</sup> The diagnosis for AFRS is usually derived from the clinical, radiological, microbiological and histopathological information combined together. There has been a lot of debate regarding the diagnostic criteria for AFRS.

A number of different attempts at establishment of diagnostic criteria have been proposed, most of which focus upon some combination of the radiologic, immunologic, clinical and histologic manifestations of the disease. Allphin et al<sup>6</sup> felt that the combination of opacified paranasal sinuses on radiography, characteristic histologic findings of allergic mucin, and laboratory evidence of allergy was sufficient to differentiate AFRS from other forms of rhinosinusitis. Loury and Schaefer<sup>26</sup> proposed a more specific set of diagnostic criteria, which included eosinophilia, immediate skin reactivity or serum IgE antibodies to fungal antigen, elevated total IgE level, nasal mucosal edema or polyposis, histopathologic findings of allergic mucin containing noninvasive fungal hyphae, and characteristic radiological findings.

In 1994, Bent and Kuhn published their diagnostic criteria centered on the histologic, radiographic and immunologic characteristics of the disease<sup>27</sup> and they still remain the standard and most widely accepted worldwide.

According to Bent and Kuhn patients must meet all the major criteria for diagnosis, while the minor criteria support the diagnosis. The major criteria include a history of type I hypersensitivity by history, skin testing or *in vitro* testing; nasal polyposis; characteristic computed tomography (CT) scan findings; the presence of eosinophilic mucin without invasion and a positive fungal stain of sinus contents removed at the time of surgery. The minor criteria include a history of asthma, unilateral predominance of disease, radiographic evidence of bone erosion, fungal cultures, presence of Charcot-Leyden crystals in surgical specimens and serum eosinophilia (Table 1).

**Table 1: Bent and Kuhn's diagnostic criteria**

Major	Minor
Type I hypersensitivity	Asthma
Nasal polyposis	Unilateral disease
Characteristic CT findings	Bone erosion
Eosinophilic mucin without invasion	Fungal cultures
Positive fungal stain	Charcot-Leyden crystals
	Serum eosinophilia



## Histology of Allergic Fungal Mucin

Microscopic picture on hematoxylin and eosin (H&E) staining of mucin is an important diagnostic tool and would show typical inflammatory infiltrate composed of eosinophils, eosinophilic breakdown products or Charcot-Leyden crystals, lymphocytes and plasma cells.<sup>27</sup> The mucosa will be hypertrophic and hyperplastic but should not have evidence of necrosis, giant cells, granulomas or invasion into surrounding structures. It is important to note that examination of the unique allergic fungal mucin itself, and not the surrounding mucosa, is the most reliable indicator of disease. Grossly, this thick, highly viscous, variably colored mucin has been described as being similar to peanut butter or axle grease.<sup>28</sup> H&E staining accentuates the mucin and cellular components of allergic fungal mucin. Using this stain, background mucin will often take on a chondroid appearance, whereas eosinophils and Charcot-Leyden crystals are heavily stained and become easily detected. Fungi fail to stain with H&E, however, and may be implicated only by their resulting negative image against an otherwise stained background. Given that fungal hyphae are frequently rare, scattered, and fragmented within allergic mucin, identification is extremely difficult unless specific histological stains are used. Fungal elements are recognized for their unique ability to absorb silver. This property is the basis for various silver stains, such as Grocott's or Gomori's methenamine silver (GMS) stain, which turn fungi black or dark brown. The use of a fungal stain complements the findings of initial H&E stain and is extremely important in the identification of fungi.<sup>28</sup>

Fungi commonly identified in the electron microscopy are from the dematiaceous family and *Aspergillus* species,<sup>6</sup> Dematiaceous fungi include the genera *Alternaria*, *Bipolaris*, *Cladosporium*, *Curvularia*, *Drechslera* and *Helminthosporium*. These fungi are darkly pigmented due to dihydroxynaphthalene melanin in the cell walls of the hyphae or conidia.

Fungal hyphae do not invade tissue: The presence of fungal tissue invasion has been considered incompatible with a diagnosis of AFRS. Many patients with polypoid CRS and eosinophilic mucin lack other important clinical characteristics of AFRS: Demonstrable fungi and fungal allergy. These patients should not be classified as having AFRS. In a study Dhiwakar et al<sup>18</sup> pointed out that the combination of nasal polyps, CT scan hyperattenuation and elevated titers of anti-*Aspergillus* IgE have high predictive value for AFRS, though considered in isolation they are not specific. There is a lot of overlap that exists between AFRS, EMCRS and CRS from other causes, but Bent and Kuhn<sup>27</sup> criteria can still distinguish between these.

## Immunologic Findings

The original reports describing AFS focused on the fungus *Aspergillus*. Miller et al<sup>3</sup> described immediate cutaneous reactivity to *Aspergillus fumigatus* antigen in all five patients in their original case series. Katzenstein et al<sup>2</sup> found specific IgE and immunoglobulin G (IgG) to *Aspergillus* in their series. The total IgE level has served as a useful tool to follow the clinical activity of allergic bronchopulmonary aspergillosis. Based on similar IgE behavior associated with recurrence of AFRS, total IgE levels have been proposed as a useful indicator of AFRS clinical activity. Total IgE values are generally elevated in AFRS, often to more than 1,000 U/ml<sup>13,29,30</sup> elevated in all patients with AFRS and corresponded with the results of fungal cultures. In contrast, levels of fungal-specific IgE were not elevated within the control group of patients with chronic rhinosinusitis. Moreover, patients with AFRS appear to demonstrate a broad sensitivity to a number of fungal and nonfungal antigens. Mabry et al have reported their experience, which indicates that patients with AFRS are allergic to multiple fungal antigens, as well as many typical nonfungal antigen.<sup>31</sup> Patients with AFRS generally demonstrate positive skin test and *in vitro* (RAST) responses for both to fungal and nonfungal antigens. Manning et al first demonstrated the sensitivity of RAST, who compared 16 patients with histologically confirmed AFRS with a control group with chronic rhinosinusitis. Levels of fungal-specific IgE were uniformly elevated in patients with AFRS and corresponded with the results of fungal cultures.<sup>32</sup>

Morpeth et al<sup>33</sup> in their review on AFS literature noted the following immunologic findings: 48% with positive skin tests to fungi, 44% with elevated total IgE, 40% with peripheral eosinophilia, 33% with elevated specific IgG, and 28% with serum precipitins to fungal antigens. Schubert and Goetz found that 67% of their patients had an elevated total IgE (greater than 199 IU/ml). The mean total IgE for their patients was 668 IU/ml. All patients have positive skin tests for aeroallergens with specific IgE to their presumably causal mold and two-thirds of patients having elevated specific IgG to molds.<sup>30</sup>

Nonspecific inflammatory findings in the surgical debris removed from AFS patients include elevated levels of eosinophilic cationic protein and major basic protein. This indicates eosinophilic degranulation.

Ponikau et al<sup>10</sup> postulated that there is a nonspecific eosinophilic response in these patients to the presence of fungal elements in the nose and sinuses. We need further studies to confirm these findings, because if the inflammatory process in AFS is actually driven mostly by a nonspecific eosinophilic reaction rather than by specific IgE, then steroids will continue to be the primary medical therapy

and immunotherapy with fungal antigen extracts will have no role. If the etiology of AFS is a specific IgE-mediated immunologic response then appropriate immunotherapy may be initiated and would be efficacious.

### Fungal Culture

Fungal cultures provide only supportive evidence helpful in the diagnosis and subsequent treatment of AFRS, but must be interpreted with caution and the diagnosis of AFRS is not established or eliminated based on the results of these cultures as yield is variable from 64 to 100%.<sup>19</sup> A diagnosis of AFRS in the presence of a negative fungal culture is possible but there may be a situation when a positive fungal culture fails to confirm the diagnosis of AFRS, because it may merely represent the presence of saprophytic fungal growth.

A panel of international experts in 2004 convened to establish working diagnosis for chronic rhinosinusitis which included AFRS. The impact of IgE-mediated sensitivity to fungus in AFRS was acknowledged by the panel and they proposed diagnostic criteria based upon the combination of histologic, immunologic, clinical and radiologic factors<sup>34</sup> (Table 2).

### RADIOLOGICAL FEATURES

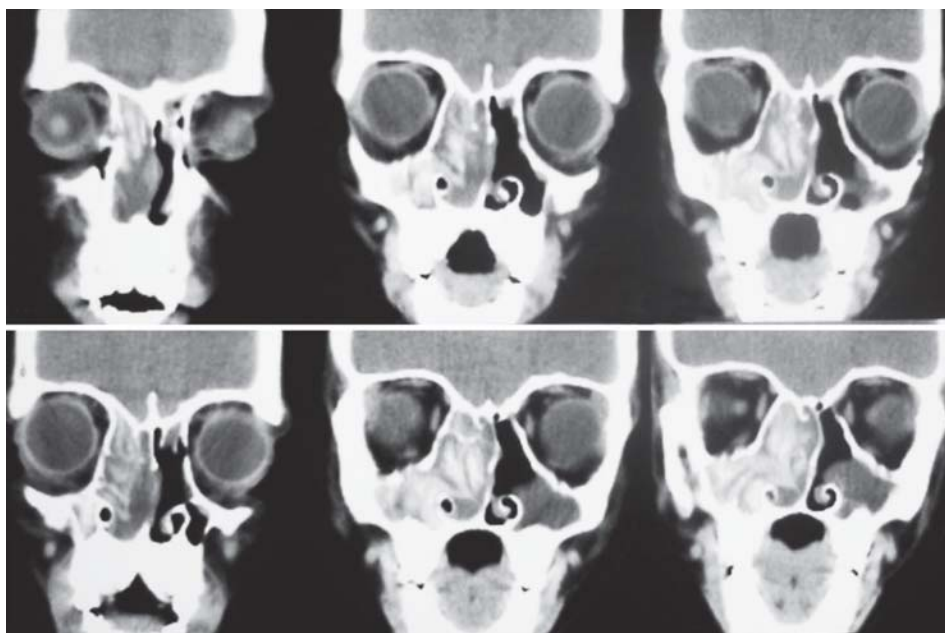
AFRS has characteristic features on CT scan or MRI considered extremely important for diagnosis. CT scan shows multiple opacified sinuses with central hyperattenuation, sinus mucocele formation and erosion bone. Ghegan et al<sup>35</sup> showed that 56% of AFRS cases presented with radiographic evidence of skull base erosion or intraorbital extension, whereas similar findings were only noticed in 5% of other cases of chronic sinusitis. Zinreich

**Table 2: Diagnostic criteria for AFRS (2004)**

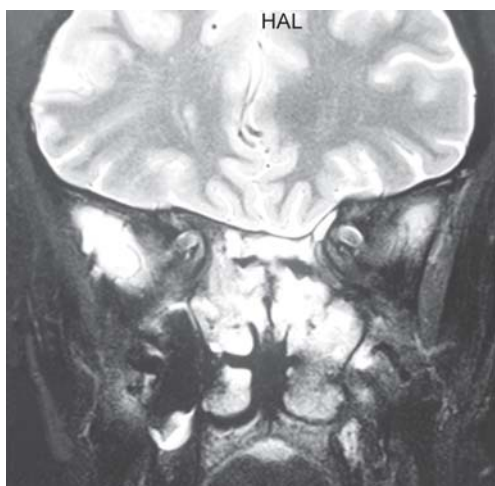Symptoms	Requires $\geq$ one of the following: <ul style="list-style-type: none"> <li>• Anterior and/or posterior nasal drainage</li> <li>• Nasal obstruction</li> <li>• Decreased sense of smell</li> <li>• Facial pain-pressure-fullness</li> </ul>
Objective findings	Requires all of the following: <ul style="list-style-type: none"> <li>• Presence of allergic mucin (fungal hyphae with degranulating eosinophils on histopathology)</li> <li>• Evidence of fungal-specific IgE</li> <li>• No histologic evidence of invasive fungal disease</li> </ul>
Radiologic findings	Highly recommended: <ul style="list-style-type: none"> <li>• Sinus CT demonstrating</li> <li>• Bone erosion</li> <li>• Sinus expansion</li> <li>• Extension of disease into adjacent anatomic areas</li> </ul> Possible, but not required: <ul style="list-style-type: none"> <li>• Fungal culture</li> <li>• Total serum IgE</li> <li>• Imaging by more than one technique</li> </ul>
Other diagnostic measures	

et al have described the CT and MRI findings in patients with AFRS. There is characteristic serpiginous attenuation in CT scan particularly in bone window.<sup>36</sup> Ferromagnetic elements produced by fungi are believed to be the cause of this heterogeneous destruction. The combination of hyperattenuation and bony erosion on CT scan and type 1 hypersensitivity may be considered as preoperative predictors of AFRS<sup>36</sup> (Fig. 1).

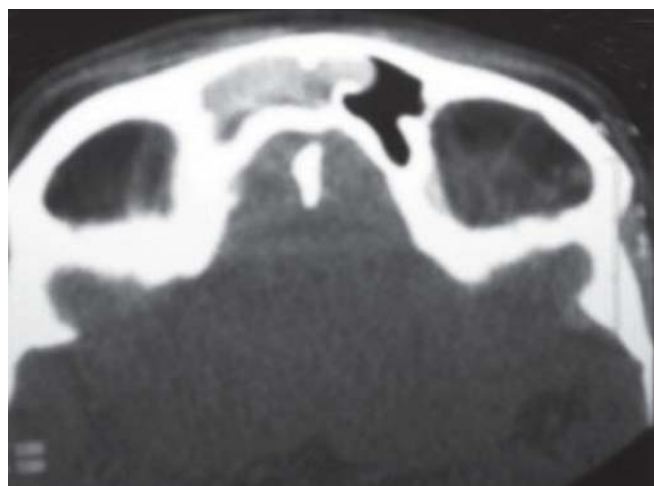MRI is complimentary to CT scan and done in cases with intraorbital or intracranial extension of disease on CT scan. On MRI, there is a central low signal on T1 and T2 imaging by sinuses that correspond with areas of eosinophilic mucin (Fig. 2). Peripheral high-signal intensity



**Fig. 1:** CT scans showing characteristic hyperattenuation seen in AFRS



**Fig. 2:** T2 weighted MRI showing demonstrates hypointense regions surrounded by mucosal inflammation



**Fig. 4:** CT scan showing hetrodense shadow in frontal sinus suggestive of AFRS

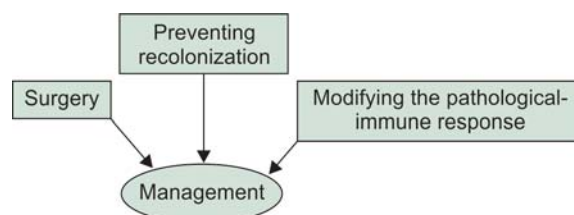
corresponds with inflamed mucosa.<sup>37-39</sup> MRI demonstrates hypointense regions surrounded by mucosal inflammation in T2 weighted images. Manning et al in a series of 10 cases of AFRS, demonstrated that hypointense central T1 signal, central T2 signal void, and the presence of increased peripheral T1/T2 enhancement was highly specific for AFRS as compared with other forms of fungal sinusitis (invasive fungal sinusitis and fungal ball) and mucocoele.<sup>38</sup>

CT findings of sinus expansion with central areas of irregular high attenuation should prompt suspicion for AFS. Bony erosion noted is likely due to pressure resorption but may be due to the effect of inflammatory mediators. Although the CT scan and MRI findings in AFRS are considered important in diagnosis, definitive diagnosis requires histologic verification and other clinical information (Figs 3 and 4).

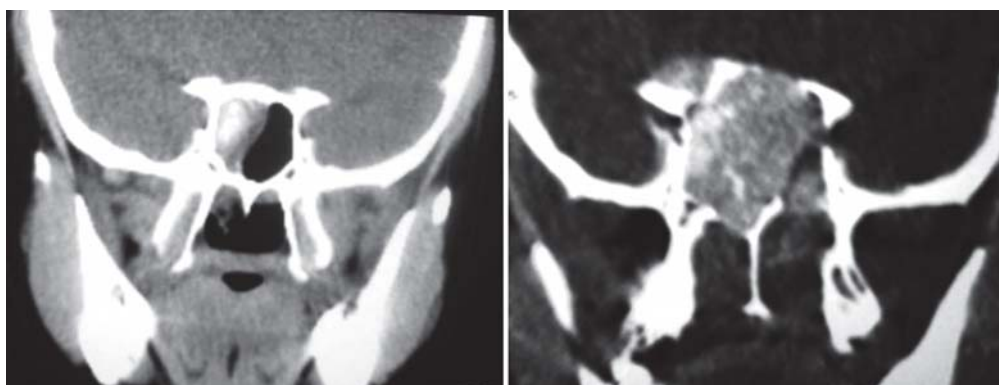### Treatment

With the better understanding and recognition of the disease process, the treatment of AFRS has also evolved from aggressive radical surgery and toxic antifungal medications to conservative endoscopic surgery and adjunctive medical therapy directed at suppressing inflammation and reducing

the burden of fungal antigen in the nose. The recognition of AFRS now, to be a noninvasive, immunologically mediated hypersensitivity to fungal antigens has lead to the treatment options to be considered accordingly.



The treatment of AFRS is surgical extirpation of the allergic mucin and fungal muck and providing drainage and aeration of the sinuses. External radical approaches with removal of the sinus mucosa were done earlier<sup>40,41</sup> but with the advent of nasal endoscopes, most cases are amenable to tissue preserving endoscopic approach.<sup>28</sup> External surgeries are not necessary except in rare circumstances and obliterative procedures should be avoided. Nasal polyposis is inherent to AFRS and can range from subtle to extensive, distortion of local anatomy and loss of useful surgical landmarks which increases the risks of complications during surgery. Image guidance can be an important tool for



**Fig. 3:** CT scan showing hetrodense shadow in sphenoid sinuses suggestive of AFRS



facilitating a complete surgery as missing diseased cells with eosinophilic mucin would decrease the effectiveness of medical treatment and increase the chances of recurrence.<sup>42</sup>

In cases of recurrence, if the medical management fails to clear an exacerbation, eosinophilic mucin accumulation and polyposis, then surgical treatment is warranted which would need a more aggressive surgery and wide sinusotomies. Regardless of the completeness of surgical exenteration, recurrences are common. Hence, the need for medical adjuncts following surgery is mandatory.

Medical treatment for AFRS is essential to obtain long-term symptom control, retard polyp formation and delay or prevent revision surgery. Different forms of medical therapies ranging from immunotherapy to systemic steroids have been used for treating AFRS though randomized blinded clinical trials are lacking. Systemic anti-inflammatory agents are usually required in the treatment of AFRS and appear to be the most effective medical therapy. Systemic steroids are at least transiently effective for the treatment of polypoid rhinosinusitis as shown by a few placebo controlled, randomized trials<sup>43,44</sup> so may be used as an adjunct after surgery. The side effect profile of systemic corticosteroids warrants careful consideration when they are used in a long-term approach to control AFRS. Therefore, as a general rule, systemic steroids are best confined to the perioperative period and for use in short bursts to suppress recurrent polyps and address acute exacerbations of disease. Topical intranasal steroids play an important role in the long-term medical management of AFRS. Topical delivery avoids or minimizes most of the acute and chronic long-term toxicities of corticosteroids, yet is successful in maintaining control of inflammation for prolonged periods. Topical steroids have been shown to be effective in the treatment of nasal polyp disease in AFRS<sup>45</sup> and in higher doses than normal.<sup>46</sup> Budesonide has been tried in the form of atomized spray as it would deliver a larger total dose of steroid compared with conventional steroid nasal sprays.<sup>47</sup> Unfortunately, although topical intranasal steroids appear to be effective, they are often not sufficient to completely eliminate the use of systemic steroids.

The recognized toxicity of repeated courses of systemic steroids has led to a search for nonsteroid treatment alternatives. Macrolides<sup>30</sup> and leukotriene receptor antagonists or synthesis inhibitors have also been tried for polypoid CRS because of their safety and possible steroid-sparing effect though it lacks effective control.<sup>48</sup>

Systemic antifungal therapy for AFRS was initially proposed to control the theoretical potential for progression to invasive forms of fungal sinusitis. The early use of amphotericin B yielded to the use of less toxic agents, such as ketoconazole, itraconazole and fluconazole, but the poor *in vivo* activity of these agents against dematiaceous fungi

was soon discovered.<sup>11</sup> The role of antifungals had been controversial and one view is that these are too expensive and toxic for routine use, but some studies however, reported good result with the use of systemic itraconazole therapy.<sup>49-51</sup> None of these studies however, gave any evidence that antifungals decrease reliance on systemic steroids. Moreover, the efficacy of agents such as itraconazole may not be due to a reduced fungal burden in the nose, but rather due to the anti-inflammatory properties of the molecule or its inhibition of prednisone metabolism. Antifungal treatments are sometimes employed for AFRS with the aim of decreasing the fungal exposure within the sinonasal cavities.<sup>46,52</sup> Like systemic antifungals, there have been no trials of topical antifungals specifically for AFRS. Randomized, controlled trials have failed to show a significant therapeutic benefit of topical antifungal (amphotericin) for the treatment of chronic polypoid rhinosinusitis.<sup>53</sup> Despite the purported fungal cause of AFRS, antifungal therapies need further investigation to establish their efficacy before their use is widely adopted.

Immunotherapy is another treatment modality that holds potential as an effective treatment option for AFRS. The anti-inflammatory effect of specific allergen immunotherapy has the potential to decrease reliance on systemic steroids in the treatment of AFRS or may reduce the need for revision surgery. Although the relative importance of type 1 hypersensitivity in AFRS continues to be debated, the rationale for immunotherapy is that AFRS is at least partially a result of allergen-specific IgE-mediated inflammation. The evidence to support the use of immunotherapy was incidental<sup>54,55</sup> In a nonrandomized not double blinded study on comparing AFRS patients treated with and without immunotherapy with an average 33 months of follow-up, Folker et al showed that the immunotherapy treated patients had better endoscopic mucosal appearance, lower CRS survey scores, required fewer courses of oral steroids (0 vs 2), and showed less reliance on nasal steroids (27 vs 73%). At present therapy for AFRS is directed toward reducing inflammation and reducing fungal antigen exposure.<sup>5</sup> Significant uncertainty about the ideal treatment approach will persist as long as high-level evidence from randomized, controlled trials is lacking.

## Follow-up

Follow-up of the patients can be done according to the following criteria:

- Visual analog scale:* Clinical symptoms like nasal obstruction, olfactory dysfunction, rhinorrhea, facial pain, sneezing, headache and visual symptoms are evaluated with a visual analog scale (VAS) ranging from 0 (no symptoms) to 10 (maximum symptoms). The severity of each symptoms collected from the results of

the VAS can be graded into four categories according to the results of the VAS.

- b. *Endoscopic physical findings*: Objective assessment by rigid nasal endoscopy following surgery can be done by a standard endoscopic staging system described by Kupferberg et al:
- Stage 0: No evidence of disease
  - Stage 1: Mucosal edema ± allergic mucin
  - Stage 2: Polypoid mucosa ± allergic mucin
  - Stage 3: Polyposis with allergic mucin
- c. Objective CT score- can be done based on Lund Mackay staging system that attributes points based on sinomucosal disease, opacification and obstruction:
- 0 point: No abnormality
  - 1 point: Partial opacification
  - 2 points: Total opacification

Points are calculated by adding for each sinus and on both sides.

#### *Interpretation of Lund and Mackay Staging System*

- 0 to 4: Normal
- 5 to 9: Minimal
- 10 to 14: Moderate
- 15 to 24: Severe

#### **Recurrence of Disease**

The potential for AFRS recidivism is well-recognized and ranges from 10 to 100% depending on the length of follow-up. To emphasize the importance of long-term surveillance, Bent et al pointed out that in their experience the often-dramatic initial response to surgical therapy was eventually replaced by recurrence of AFRS in the absence of ongoing therapy.<sup>27</sup> Similarly Kupferberg et al followed the appearance of sinonasal mucosa of 24 patients treated with combined medical and surgical therapy for AFRS. Nineteen of 24 eventually developed recurrence of disease after discontinuation of systemic steroids, but they observed that endoscopic evidence of disease generally preceded return of subjective symptoms. AFRS recidivism appears to be influenced by long-term postoperative therapy.<sup>56</sup>

**Indian perspective:** *Consensus arrived by a national panel on AFRS at the ENT Surgical Update 2011, held at Postgraduate Institute of Medical Education and Research, Chandigarh.*

#### **Preoperative Workup and Preparation**

*Imaging:* CT scan of nose, paranasal sinuses with orbits, axial, coronal and sagittal sections is mandatory in all patients to be taken up for surgery. Patients having intraorbital or intracranial extension of disease on CT scan to be subjected to a MRI. CT findings of sinus expansion

with central areas of irregular high attenuation should prompt suspicion for AFS.

*Workup for general anesthesia:* All routine hematological and biochemical investigations necessary to obtain fitness for surgery to be done.

*Preoperative steroids:* Oral prednisolone in a dose of 0.5 mg/kg body weight to be started 2 weeks preoperatively. Oral deflazacort to be preferred in diabetic patients in a dose of 0.5 mg/kg.

#### **Surgical Management**

Consensus was reached that endoscopic sinus surgery to be preferred, reserving the open approach for rare circumstances. The role of surgery in patients of AFRS is to remove all the obstructing inspissated allergic mucin and to address the diseased mucosa establishing a permanent aeration of the sinuses. Early surgery warranted in all cases especially in all patients especially having intraorbital or intracranial extension of disease.

#### **Postoperative Management**

The experts were of the opinion that oral prednisolone or deflazacort in a dose of 0.5 mg/kg body weight should be used for 3 to 6 months. Topical steroidal sprays to be continued for 6 months and then as and when required. In the topical steroids, fluticasone furoate has a better compliance than mometasone or budesonide. The role of systemic antifungals in patients with intracranial and intraorbital extension of disease was debated. These are being used but because of lack of scientific evidence, all the panelists were of the opinion that further studies are required before any conclusion can be drawn. This protocol would be reviewed again after one year. Saline douches to be continued preferably lifelong. Further, it was deliberated that leukotriene receptor antagonists are not effective. Thirty percent of the experts were of the opinion that these are not effective and 30% said they are effective while the rest 40% had not used them. Role of immunotherapy in India has yet not been established.

#### **Follow-up**

Postoperative endoscopic suction and clearance to be done weekly for 1 month bimonthly for 3 months, once a month for 6 months and then 3 monthly for 5 to 6 years. It was further proposed to get postoperative CT scan after 6 weeks and then as and when required.

#### **Recurrent Disease**

The first line of treatment for recurrence is medical therapy in the form of oral and topical steroids. If the patient fails



medical therapy, revision endoscopic surgery to be done after adequate imaging. Patient to be labeled as disease-free, if there is no radiological evidence of disease on CT scan for 5 years.

## DISCUSSION

Fungus is ubiquitous, present in all our surroundings and the air we inhale. Most healthy people do not react to the presence of fungus due to a functioning immune system. However, in rare instances, fungus may cause inflammation in the nose and the sinuses. Fungal sinusitis can manifest in various forms, differing in pathology, symptoms, course, severity and the treatment required.

A simplified classification of fungal sinusitis is as follows:

- A. Noninvasive fungal sinusitis
  - i. Fungus ball
  - ii. Allergic fungal sinusitis
  - iii. Nonallergic fungal sinusitis
- B. Invasive fungal sinusitis
  - i. Acute invasive fungal sinusitis
  - ii. Chronic invasive fungal sinusitis
  - iii. Granulomatous invasive fungal sinusitis.

We would be restricting ourselves to AFRS. AFRS is a distinct form of chronic polypoid rhinosinusitis characterized by accumulation of eosinophilic mucin with fungal hyphae in the sinuses, type 1 hypersensitivity to fungi, and a propensity for mucocele formation and bone erosion (Figs 5 and 6).

As mentioned earlier, approximately 5 to 10% of those patients with chronic rhinosinusitis carry a diagnosis of AFRS.<sup>2</sup> It is most common among adolescents and young adults (mean age, 21.9 year).<sup>11</sup> The incidence of AFRS appears to be impacted by geographic factors. In India, AFRS is reported from North and South India because of hot and humid conditions.<sup>17-19</sup>

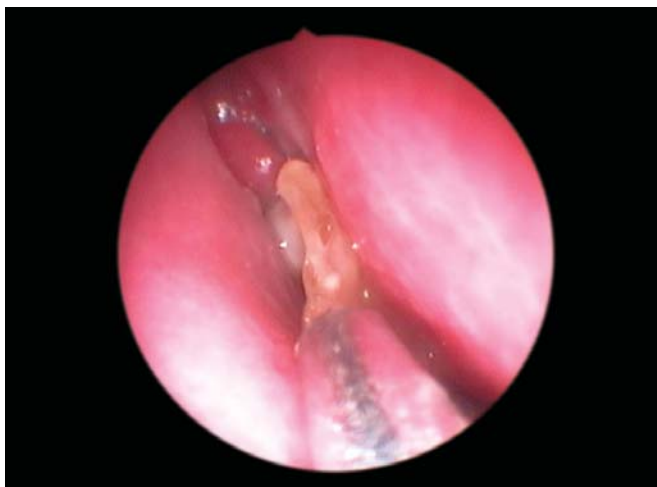

Fig. 5: Endoscopic picture showing thick, tenacious allergic mucin

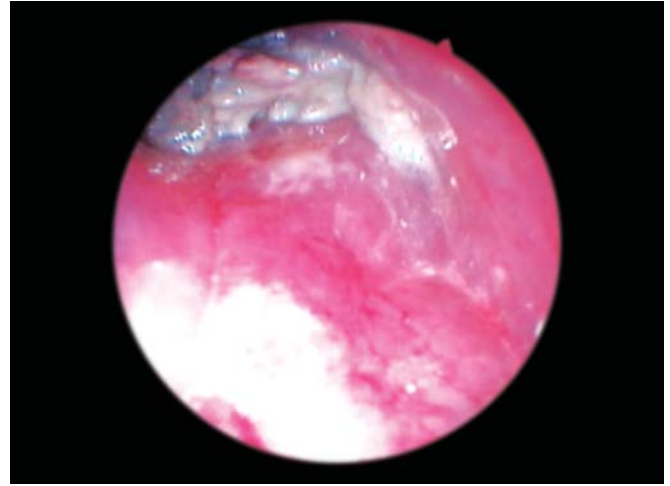


Fig. 6: Endoscopic picture showing fungal muck

Patients with AFRS usually present with rhinosinusitis symptoms lasting months or years and they may not seek medical attention until complete nasal obstruction, headaches, visual disturbances or facial distortion develop. Proptosis or telecanthus are frequently seen at presentation, especially in younger patients.<sup>17,28,57,58</sup> (Figs 7 to 9).

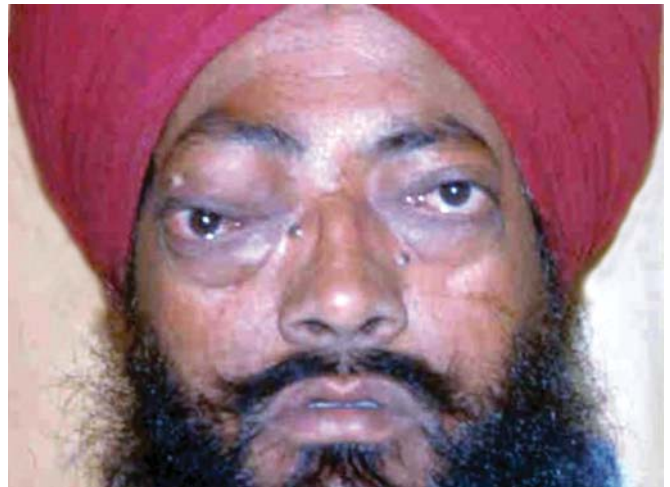

Fig. 7: Clinical photograph showing proptosis of eye

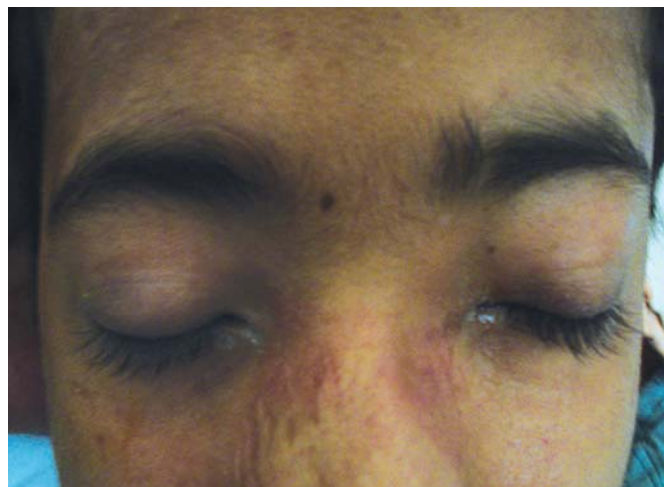
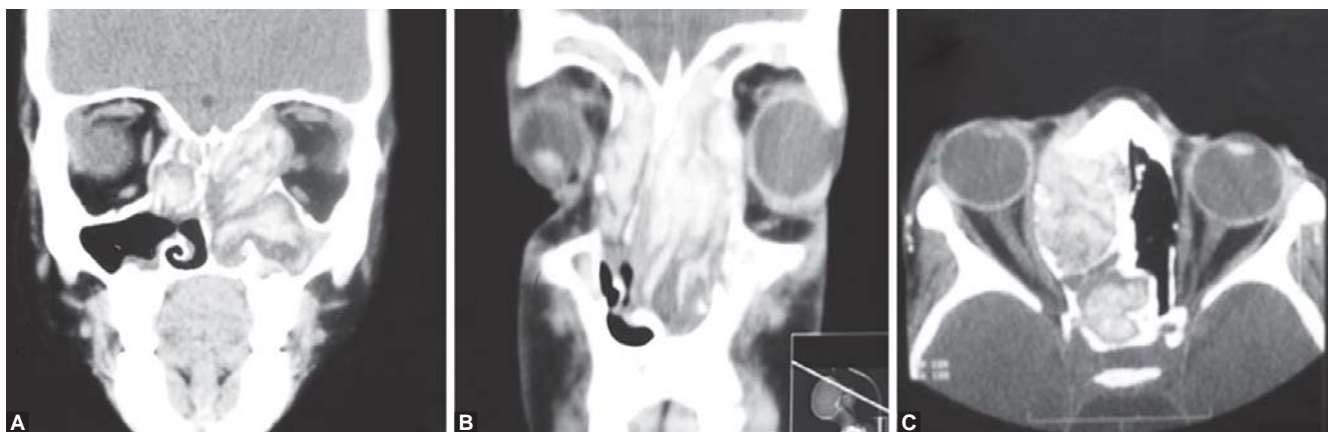


Fig. 8: Clinical photograph showing telecanthus

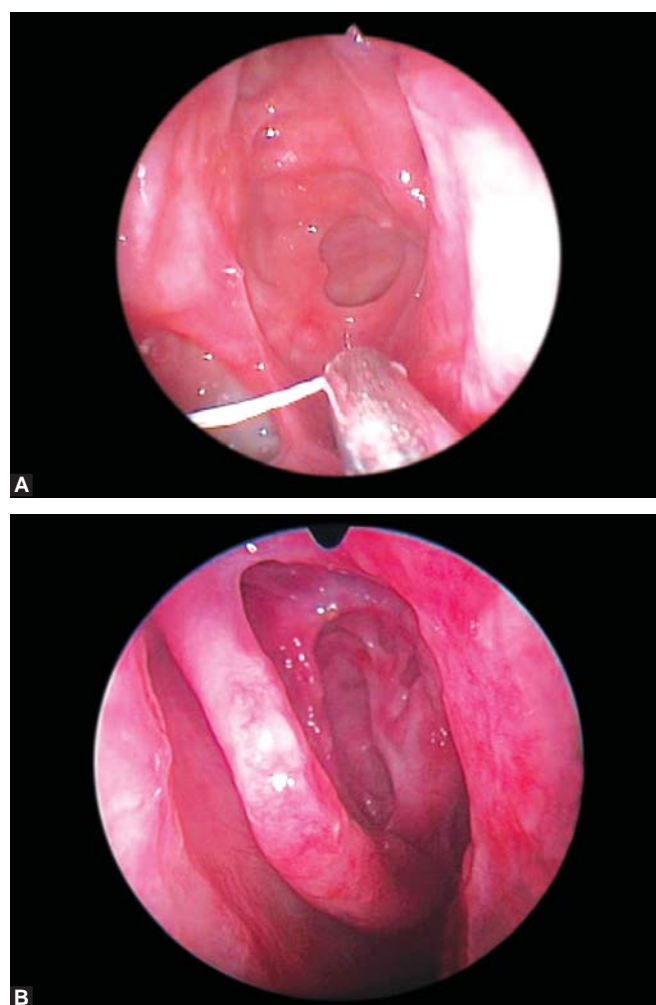


**Figs 9A to C:** (A and B) Coronal sections CT scan showing intraorbital extension, (C) axial section CT scan showing intraorbital extension

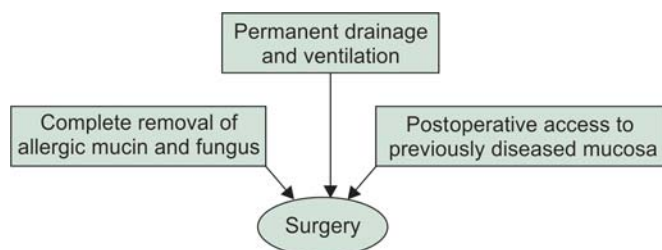
Gupta et al in a study compared AFRS in adults and children and found that clinical profile of both the groups was the same except for higher incidence of proptosis in pediatric cases (60% as compared to 20% in adults) and high chances of having coexistent asthma and rhinobronchial allergy in adults (50% compared to 1% in children). There was higher incidence of facial deformities in the children compared to adults in their study with proptosis in 60%, telecanthus in 40% and nasal pyramid widening in 18% children and 20, 9 and 0% in adults respectively.<sup>17</sup> McClay has reported an incidence of 42% facial deformities in children compared to 10% in adults.<sup>57</sup> Gupta et al found a higher incidence of facial deformities, proptosis, intraorbital/intracranial extension and a higher rate of recurrence in children, with an earlier presentation, therefore, suggesting a more aggressive nature of AFS in children than adults mandating an early diagnosis, proper management and regular follow-up in these cases.<sup>17</sup> On radiology the involvement of the sinuses has been found to be asymmetrical in 70% of the children compared to 30% in adults<sup>17</sup> and similar findings have been found by other authors.<sup>16,57</sup> The involvement of orbit was seen more commonly with the children (68%) compared to adults (33%) Similarly, the intracranial extension was seen more often in children than adults.<sup>17</sup> It is in accordance with the findings by McClay et al.<sup>57</sup> Overall bony erosion was seen in 88% of the children compared to 36% in adults. Various studies quote a range of 20 to 90% incidence of bone erosion.<sup>59</sup> McClay reported an incidence of 25% bone erosion in children compared with 23% in adults.<sup>57</sup>

The treatment of AFRS is surgical extirpation of the allergic mucin and fungal muck and providing drainage and aeration of the sinuses with endoscopic sinus surgery being preferred over external approaches (Figs 10 and 11).

Preoperative steroids have been proved beneficial in obtaining a better operative field as well as having a better disease control.<sup>28,30</sup>



**Figs 10A and B:** Endoscopic pictures show well-healed postoperative cavities



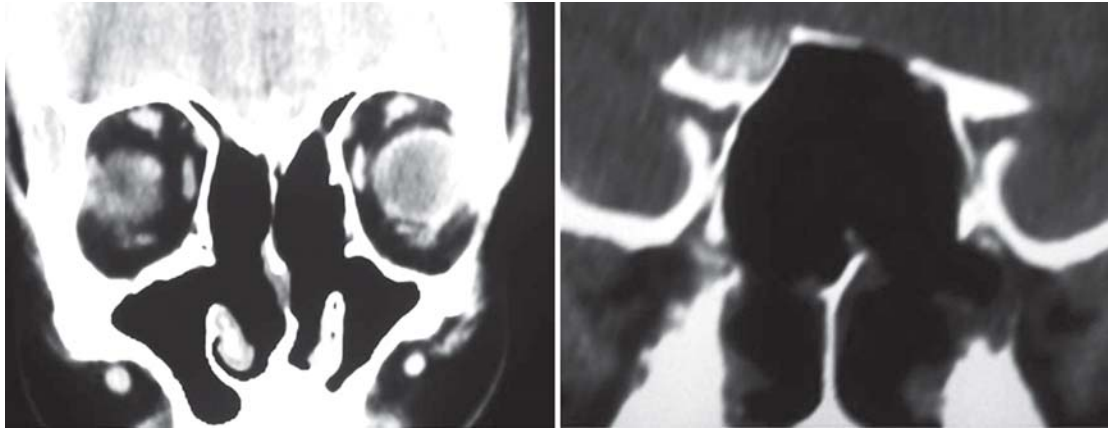
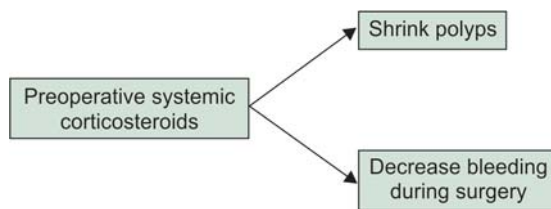


Fig. 11: CT scan showing postoperative maxillary and sphenoid sinuses



Kennedy et al conducted a prospective study to evaluate the effect of preoperative high dose systemic corticosteroids and radiographic and endoscopic appearance of AFRS.<sup>60</sup> They reported a marked reduction of Lund-Mackay scores following high dose steroids.<sup>61</sup> They advocated minimally invasive endoscopic sinus surgery following therapy with steroids. Furthermore, a short course of preoperative systemic corticosteroids will shrink polyps and decrease bleeding during surgery<sup>28</sup> Kinsella et al who reviewed a series of 15 patients who underwent variable postoperative medical therapy for AFRS found that of the seven patients who had no recurrence at 6 months follow-up, four had been administered oral steroid for 2 to 4 weeks postoperatively. None of the eight patients with recurrent disease had received oral steroid.<sup>62</sup> Similar encouraging results were found by DeShazo and Swain.<sup>63</sup> Both groups of researchers while recommending the use of oral steroids in the postoperative period based on anecdotal evidence highlighted the need for prospective, controlled studies. Schubert and Goetz<sup>30</sup> further studied the role of systemic corticosteroids in the postoperative management AFRS, demonstrating a significant increase in the time to revision sinus surgery in those patients with AFRS who received prolonged courses of postoperative corticosteroids. Postoperative corticosteroid therapy in this study ranged from 2 to 12 months, with improved outcomes recorded among those patients who were placed on longer courses of therapy. Kupferberg et al in a review of 28 patients with AFRS stressed the role of systemic corticosteroids after endoscopic sinus surgery. Patients who received

corticosteroids postoperatively had less recurrence compared to the patients who did not receive steroids. They recommended oral prednisolone at a dose of 40 mg/day for 4 days, 30 mg/day for 4 days and 20 mg/day for 1 month. The dose was then adjusted to the lowest possible dose at which the patient could be maintained at stage 0.<sup>56</sup> Kuhn and Javer followed a protocol lasting about 7 months with prednisolone being administered in a tapering dose starting at 40 mg/day and maintained at 0.1 mg/kg day for the last 2 months of treatment.<sup>46</sup> The long duration of therapy was essentially to maintain a recurrence free state. The use of concomitant high-dose inhaled steroid was also emphasized. However, long-term treatment with systemic corticosteroids increases the risk of both acute and long-term morbidity particularly in children. The effect of corticosteroids in growth and bone development are extremely important in the pediatric population. Studies have shown that long-term systemic steroid usage can cause developmental growth delay and bone demineralization. In a study by Chesney et al children with childhood glomerular disease receiving prednisone were 5.3% shorter and had 16.7% more demineralization than matched control subjects.<sup>64</sup> Shegren et al experimentally proved that alternate day dosing lessened the effect of corticosteroids but still cause premature closure of epiphyseal plates. Linear growth may be inhibited by a little as 5 mg of prednisone per day or 30 mg every other day.<sup>65</sup> Schubert et al reported no adverse effects among their series of 67 patients with AFRS treated for up to 1 year with systemic corticosteroids, but long-term follow-up for this form of therapy is lacking.<sup>30</sup> In view of these side effects, the panel recommended steroids in the form of prednisolone to be started 2 weeks preoperatively and 3 to 6 months postoperatively in a dose of 0.5 mg/kg body weight rather than 1 mg/kg body weight.<sup>66</sup>

Topical intranasal steroids play an important role in the long-term medical management of AFRS. Topical delivery avoids or minimizes most of the acute and chronic



long-term toxicities of corticosteroids, yet is successful in maintaining control of inflammation for prolonged periods.

Macrolides<sup>30</sup> and leukotriene receptor antagonists or synthesis inhibitors have also been tried for polypoid CRS because of their safety and possible steroid-sparing effect though it lacks effective control.<sup>48</sup>

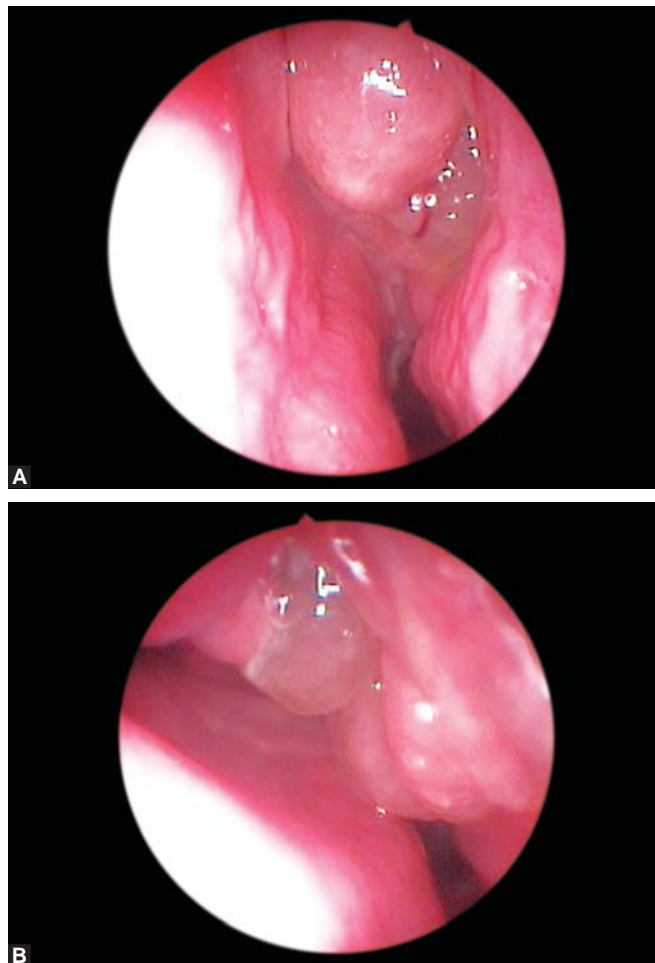
Systemic antifungal therapy for AFRS was initially proposed to control the theoretical potential for progression to invasive forms of fungal sinusitis. The early use of amphotericin B yielded to the use of less toxic agents, such as ketoconazole, itraconazole and fluconazole, but the poor *in vivo* activity of these agents against dematiaceous fungi was soon discovered.<sup>11</sup> Systemic antifungals are too expensive and toxic for routine use, but some studies however, reported good result with the use of systemic itraconazole therapy<sup>49-51,67</sup> probably because of their anti-inflammatory properties. Randomized, controlled trials have failed to show a significant therapeutic benefit of topical antifungal (amphotericin) for the treatment of chronic polypoid rhinosinusitis.<sup>53</sup>

In accordance with the literature, the panel concluded that leukotriene receptor antagonists are not effective and antifungal irrigation has no role while systemic antifungals have any role except in repeated recurrences. The advantages and usefulness of saline douches was emphatically stressed by the panel and preferably to be continued lifelong.

Immunotherapy may be an effective treatment option for AFRS as it is at least partially a result of allergen-specific IgE-mediated inflammation. Although subcutaneous immunotherapy has clearly demonstrated efficacy in allergic rhinitis and asthma<sup>68,69</sup> randomized, controlled trials that examine the efficacy of immunotherapy specifically for AFRS are lacking. There are chances of worsening of disease due to introduction of foreign extraneous fungal antigens and damage to tissues due to type III Gel and Coomb's occasionally. Moreover, there is lack of availability of pure extracts to specific fungal antigens in India. In view of lack of substantial high-level evidence from randomized, controlled trials, a consensus was reached at the meeting that immunotherapy in the current form has no role in AFRS.

In cases of recurrence, if the medical management fails to clear an exacerbation, eosinophilic mucin accumulation and polyposis, then surgical treatment is warranted which would need a more aggressive surgery and wide sinusotomies (Figs 12A and B).

The panel categorically emphasized the importance of long-term surveillance in cases of AFRS and a follow-up schedule by nasal endoscopic examination and CT scan was suggested to look for recurrence and recidivism. AFRS recidivism appears to be influenced by long-term



**Figs 12A and B:** Endoscopic pictures showing recurrence of the disease

postoperative therapy. Schubert et al reported the long-term clinical outcome of 67 patients following initial surgical therapy for AFRS. Patients treated with at least 2 months of oral corticosteroids were compared with those who received no corticosteroids. At 1 year after initial surgery, patients treated with oral corticosteroid were significantly less likely to have experienced recurrent AFRS.<sup>30</sup> It is important to realize that AFRS recidivism remains high despite appropriate postoperative medical therapy. Nasal endoscopy at regular intervals is the best way to monitor the activity of disease, and patients should be encouraged to return early for any symptom exacerbation.

### KEY POINTS

Indian perspective: Consensus arrived by a national panel on AFRS at the ENT surgical update 2011, held at PGI, Chandigarh.

1. CT scan of nose and PNS with axial, coronal and sagittal sections mandatory for endoscopic sinus surgery.
2. Role of preoperative steroids: Oral prednisolone to be started in normal patients and deflazacort in diabetics in a dose of 0.5 mg/kg body weight preoperatively.

3. Early surgery warranted in all cases especially in patients having intraorbital or intracranial extension of disease.
4. Endoscopic approach to be preferred for surgery.
5. The role of surgery in patients of AFRS is to remove all the obstructing inspissated allergic mucin and to address the diseased mucosa establishing a permanent aeration of the sinuses.
6. Postoperative steroids: Oral prednisolone or deflazacort in a dose of 0.5 mg/kg body weight for 3 to 6 months. Topical steroidal sprays to be continued for 6 months and then as and when required.
7. Fluticasone furoate has a better compliance than mometasone or budesonide.
8. No antifungal irrigation or any systemic antifungals have any role except in repeated recurrences.
9. Saline douches to be continued preferably lifelong.
10. Leukotriene receptor antagonists are not effective.
11. No role of immunotherapy in India yet.
12. Follow-up: Postoperative endoscopic suction and clearance weekly for 1 month bimonthly for 3 months, once a month for 6 months and then 3 monthly for 5 to 6 years. Postoperative CT scan after 6 weeks and then as and when required.
13. Recurrent disease: Medical therapy in the form of oral and topical steroids to be tried first and if medical therapy fails, to be considered for endoscopic surgery.
14. Patient to be labeled as disease-free, if there is no radiological evidence of disease on CT scan for 5 years.
10. Ponikau JU, Sherris DA, Kern EB, Homburger HA, Frigas E, Gaffey TA, Roberts GD. The diagnosis and incidence of allergic fungal sinusitis. *Mayo Clin Proc* 1999;74(9):877-84.
11. Manning SC, Holman M. Further evidence for allergic pathophysiology in AFRS. *Laryngoscope* 1998;108:1485-96.
12. Stewart AE, Hunsaker DH. Fungus-specific IgG and IgE in allergic fungal rhinosinusitis. *Otolaryngol Head Neck Surg* 2002;127:324-32.
13. Feger T, Rupp N, Kuhn F, et al. Local and systemic eosinophil activation. *Ann Allergy Asthma Immunol* 1997;79:221-25.
14. Luong A, Davis LS, Marple BF. Peripheral blood mononuclear cells from allergic fungal rhinosinusitis adults express a Th2 cytokine response to fungal antigens. *Am J Rhinol Allergy* 2009;23:281-87.
15. Ferguson BJ, Barnes L, Bernstein JM, Brown D, Clark CE 3rd, Cook PR, et al. Geographical variation in AFRS. *Otolaryngol Clin North Am* 2000;33:441-49.
16. Gupta AK, Ghosh S. Sinonasal aspergillosis in immunocompetent Indian children: An eight year experience, *Mycoses* 2003;46:455-61.
17. Gupta AK, Bansal S, Gupta A, Mathur N. Is fungal sinusitis more aggressive in children than adults? - A study of 200 cases. *Int J Pediatr Otorhinolaryngol* 2006;70(4):603-08.
18. Dhiwakar M, Thakar A, Bahadur S, Sarkar C, Banerji U, Handa KK, et al. Prospective diagnosis of allergic fungal sinusitis. *Laryngoscope* 2003;113:688-94.
19. Rupa V, Jacob M, Mathews MS, Seshadri MS. A prospective, randomised, placebo-controlled trial of postoperative oral steroid in AFRS. *Eur Arch Otorhinolaryngol* 2009;10:1075-78.
20. Ence BK, Gourley DS, Jorgensen NL, et al. Allergic fungal sinusitis. *Am J Rhinol* 1990;4(5):169-78.
21. Manning SC, Schaefer SD, Close LG, et al. Culture-positive allergic fungal sinusitis. *Arch Otolaryngol Head Neck Surg* 1991;117:174-78.
22. Singh NN, Bhalodiya NH. Allergic fungal sinusitis-earlier diagnosis and management. *J Laryngol Otol* 2005;119:875-81.
23. Marple BF. Allergic fungal sinusitis. *Curr Opin Otolaryngol* 1999;7:383-87.
24. Marple BF, Gibbs SR, Newcomer MT, Mabry RL. Allergic fungal sinusitis-induced visual loss. *Am J Rhinol* 1999;13:191-95.
25. Gupta AK, Bansal S, Gupta A, Mathur N. Visual loss in the setting of allergic fungal sinusitis: Pathophysiology and outcome. *J Laryngo and Otol* 2007;121(11):1055-59.
26. Lorry MC, Schaefer SD. Allergic *Aspergillus* sinusitis. *Arch Otolaryngol Head Neck Surg* 1993;119:1042-43.
27. Bent JP 3rd, Kuhn FA. Diagnosis of allergic fungal sinusitis. *Otolaryngol Head Neck Surg.* 1994;111(5):580-88.
28. Marple BF. Allergic fungal rhinosinusitis: Current theories and management strategies. *Laryngoscope* 2001;111(6):1006-19.
29. Manning S, Mabry R, Schaefer S, et al. Evidence of IgE-mediated hypersensitivity in allergic fungal sinusitis. *Laryngoscope* 1993;103:717-21.
30. Schubert MS, Goetz DW. Evaluation and treatment of allergic fungal sinusitis. II: Treatment and follow-up. *J Allergy Clin Immunol* 1998;102:395-402.
31. Mabry RL, Marple BF, Folker RJ, Mabry CS. Immunotherapy for allergic fungal sinusitis: Three years' experience. *Otolaryngol Head Neck Surg* 1998;119:648-51.
32. Mabry R, Manning S. Radioallergosorbent microscreen and total immunoglobulin E in allergic fungal sinusitis. *Otolaryngol Head Neck Surg* 1995;113:721-23.

## REFERENCES

1. Safirstein B. Allergic bronchopulmonary aspergillosis with obstruction of the upper respiratory tract. *Chest* 1976;70:788-90.
2. Katzenstein AL, Sale SR, Greenberger PA. Allergic *Aspergillus* sinusitis: A newly recognized form of sinusitis. *J Allergy Clin Immunol* 1983;72:89-93.
3. Miller JW, Johnston A, Lamb D. Allergic aspergillosis of the maxillary sinus [abstract]. *Thorax* 1981;36:710.
4. Erwin GE, Fitzgerald JE. Case report: Allergic bronchopulmonary aspergillosis and allergic fungal sinusitis successfully treated with voriconazole. *J Asthma* 2007;44:891-95.
5. Folker RJ, Marple BF, Mabry RL, et al. Treatment of allergic fungal sinusitis: A comparison trial of postoperative immunotherapy with specific fungal antigens. *Laryngoscope* 1998;108:1623-37.
6. Allphin AL, Strauss M, Addul-Karin FW, et al. Allergic fungal sinusitis: Problems in diagnosis and treatment. *Laryngoscope* 1991;101:815-20.
7. Cody DT, Neel HB, Ferreiro JA, et al. Allergic fungal sinusitis: The mayo clinic experience. *Laryngoscope* 1994;104:1074-79.
8. Ferguson BJ. Eosinophilic mucin rhinosinusitis: A distinct clinicopathologic entity. *Laryngoscope* 2000;110:799-813.
9. Pant H, Kette FE, Smith WB, et al. Eosinophilic mucus chronic rhinosinusitis: Clinical subgroups or a homogeneous pathogenic entity? *Laryngoscope* 2006;116:1241-47.

33. Morpeth JF, Rupp NT, Dolen WK, Bent JP, Kuhn FA. Fungal sinusitis: An update. *Ann Allergy Asthma Immunol* 1996;76:128-40.
34. Meltzer EO, Hamilos DL, Hadley JA, et al. Rhinosinusitis: Establishing definitions for clinical research and patient care. *JACI* 2004;114:S155-212.
35. Ghegan MD, Lee FS, Schlosser RJ. Incidence of skull base and orbital erosion in allergic fungal rhinosinusitis (AFRS) and non-AFRS. *Otolaryngol Head Neck Surg* 2006;134:592-95.
36. Zinreich SJ, Kennedy DW, Malat J, et al. Fungal sinusitis: Diagnosis with CT and MR imaging. *Radiology* 1988;169:439-44.
37. Aribandi M, McCoy VA, Bazan C. Imaging features of invasive and noninvasive fungal sinusitis: A review. *Radiographics* 2007;27:1283-96.
38. Manning SC, Merkel M, Kriesel K, et al. Computed tomography and magnetic resonance diagnosis of allergic fungal sinusitis. *Laryngoscope* 1997;107:170-76.
39. Zinreich SJ, Kennedy DW, Malat J, et al. Fungal sinusitis: Diagnosis with CT and MR imaging. *Radiology* 1988;169:439-44.
40. Killingsworth SM, Wetmore SJ. *Curvularia/Drechslera* sinusitis. *Laryngoscope* 1990;100:932-37.
41. Zieske LA, Kopke RD, Hamill R. Dematiaceous fungal sinusitis. *Otolaryngol Head Neck Surg* 1991;105:567-77.
42. Marple BF, Mabry RL. Allergic fungal sinusitis: Learning from our failures. *Am J Rhinol* 2000;14:223-26.
43. Hissaria P, Smith W, Wormald PJ, et al. A short course of systemic steroids in sinonasal polyposis: A double-blind, randomized, placebo controlled trial with evaluation of outcome measures. *J Allergy Clin Immunol* 2006;118:128-33.
44. Van Zele T, Gevaert P, Holtappels G, et al. Oral steroids and doxycycline: Two different approaches to treat nasal polyps. *J Allergy Clin Immunol* 2010;125:1069-76.
45. Joe S, Thambi R, Huang J. A systematic review of the use of intranasal steroids in the treatment of chronic rhinosinusitis. *Otolaryngol Head Neck Surg* 2008;139:340-47.
46. Kuhn FA, Javer AR. Allergic fungal sinusitis: A four-year follow-up. *Am J Rhinol* 2000;14:149-56.
47. Kanowitz SJ, Batra PS, Citardi MJ. Topical budesonide via mucosal atomization device in refractory postoperative chronic rhinosinusitis. *Otolaryngol Head Neck Surg* 2008;139:131-36.
48. Schubert MS. Antileukotriene therapy for allergic fungal sinusitis. *J Allergy Clin Immunol* 2001;108(3):466-70.
49. Swift, Denning. Skull base osteitis following fungal sinusitis. *J Laryngol Otol* 1998;112:92-97.
50. Denning DW, Van Wye JE, Lewiston NJ. Adjunctive treatment of allergic bronchopulmonary aspergillosis with itraconazole. *Chest* 1991;100:813-19.
51. Heykants J, Van de Velde V, Van Rooy P. The clinical pharmacokinetics of itraconazole: An overview. *Mycoses* 1989;32:67-87.
52. Erwin GE, Fitzgerald JE. Case report: Allergic bronchopulmonary aspergillosis and allergic fungal sinusitis successfully treated with voriconazole. *J Asthma* 2007;44:891-95.
53. Weschta M, Rimek D, Formanek M, et al. Topical antifungal treatment of CRFS with nasal polyps: A randomized, double blind clinical trial. *J Allergy Clin Immunol* 2004;113:1122-28.
54. Goldstein MF, Dunksy EH, Dvorin DJ, et al. Allergic fungal sinusitis: A review with four illustrated cases. *Am J Rhinol* 1994;8:13-18.
55. Quinn J, Wickern G, Whisman B, et al. Immunotherapy in allergic Bipolaris sinusitis: A case report. *J Allergy Clin Immunol* 1995;95:201
56. Kupferberg SB, Bent JP, Kuhn FA. The prognosis of AFRS. *Otolaryngol Head Neck Surg* 1997;117:35-41.
57. McClay JE, Marple B, Kapadia L, et al. Clinical presentation of allergic fungal sinusitis in children. *Laryngoscope* 2002;112(3):565-69.
58. Manning SC, Vuitch F, Weinberg AG, et al. Allergic aspergillosis: A newly recognized form of sinusitis in the pediatric population. *Laryngoscope* 1989;99:681-85.
59. Nussenbaum B, Marple BF, Schwade ND. Characteristics of bone erosion in allergic fungal sinusitis. *Otolaryngol. Head Neck Surg* 2001;124:150-54.
60. Kennedy DW, Wrighted Goldberg AN. Objective and subjective outcomes in surgery for chronic sinusitis. *Laryngoscope* 2000;110:29-31.
61. Lund VJ, Mackay IS. Staging in rhinosinusitis. *Rhinology* 1993;107:183-84.
62. Kinsella A, Bradfield JJ, Gourley WK, et al. AFRS. *Clin Otolaryngol* 1996; 21:389-92.
63. DeShazo RD, Swain RE. Diagnostic criteria for AFRS. *J Allergy Clin Immunol* 1995;96:24-35.
64. Chesney RW, Mazess RB, Rose P, et al. Effect of prednisone on growth and bone mineral content in childhood glomerular disease. *AJOC* 1978;132:768-72.
65. Sheagren JN, Jowsey J, Bird DC, et al. Effects on bone growth of daily versus alternate-day corticosteroid administration—an experimental study. *J Lab Clin Med* 1977;89:120-30.
66. Ikram M, Abbas A, Suhail A, Onali MA, Akhtar S, Iqbal M. Management of allergic fungal sinusitis with postoperative oral and nasal steroids: A controlled study. *Ear Nose Throat J* 2009 April;88(4):E08.
67. Rains BM, Mineck CW. Treatment of allergic fungal sinusitis with high dose itraconazole. *Am J Rhinol* 2003;17(1):1-8.
68. Calderon MA, Alves B, Jacobson M, et al. Allergen injection immunotherapy for seasonal allergic rhinitis. *Cochrane Database Syst Rev* 2007;1:CD001936.
69. Abramson MJ, Puy RM, Weiner JM. Allergen immunotherapy for asthma. *Cochrane Database Syst Rev* 2003;4:CD001186.

## ABOUT THE AUTHORS

### Ashok K Gupta (Corresponding Author)

Professor and Head, Department of Otolaryngology and Head and Neck Surgery (Unit II), Postgraduate Institute of Medical Education and Research, Chandigarh, India, Phone: +91-9814198850 e-mail: drashokpgi@hotmail.com

### Nishit Shah

Senior Consultant, Department of Otolaryngology and Head and Neck Surgery, Bombay Hospital, Mumbai, Maharashtra, India

### Mohan Kameswaran

Director and Senior Consultant, Department of Otolaryngology and Head and Neck Surgery, Madras ENT Research Foundation, Chennai Tamil Nadu, India



### **Davinder Rai**

Senior Consultant and Vice Chairman, Department of Otolaryngology  
Sir Gangaram Hospital, New Delhi, India

### **TN Janakiram**

Consultant, Department of Otolaryngology and Head and Neck  
Surgery, Royal Pearl Hospital, Trichy, Tamil Nadu, India

### **Hemant Chopra**

Professor and Head, Department of Otolaryngology, Dayanand  
Medical College, Ludhiana, Punjab, India

### **Ravi Nayar**

Professor and Head, Department of Otolaryngology and Head and  
Neck Surgery, St John's Hospital, Bengaluru, Karnataka, India

### **Arvind Soni**

Senior Consultant, Department of Otolaryngology and Head and Neck  
Surgery, Apollo Hospitals, New Delhi, India

### **NK Mohindroo**

Professor and Head, Department of Otolaryngology and Head and  
Neck Surgery, Indra Gandhi Medical College, Shimla, Himachal  
Pradesh, India

### **C Madhu Sudana Rao**

Consultant, Department of Otolaryngology and Head and Neck  
Surgery, Madhumani Nursing Home, Nandyal, Andhra Pradesh, India

### **Sandeep Bansal**

Assistant Professor, Department of Otolaryngology and Head and  
Neck Surgery, Postgraduate Institute of Medical Education and  
Research, Chandigarh, India

### **KR Meghnadh**

Head, Department of ENT, MAA ENT Hospital, Hyderabad, Andhra  
Pradesh, India

### **Neelam Vaid**

Associate Professor, Department of Otolaryngology, KEM Hospital  
Pune, Maharashtra, India

### **Hetal Marfatia Patel**

Associate Professor, Department of Otolaryngology, KEM Hospital  
Pune, Maharashtra, India

### **Sanjay Sood**

Consultant, Department of ENT, Holy Family Hospital, New Delhi  
India

### **Sunita Kanojia**

Clinical Assistant, Department of Otolaryngology, Bombay Hospital  
Mumbai, Maharashtra, India

### **Kshitij Charaya**

Senior Resident, Department of Otolaryngology and Head and Neck  
Surgery, Postgraduate Institute of Medical Education and Research  
Chandigarh, India

### **SC Pandhi**

Former Consultant, Department of Otolaryngology and Head and Neck  
Surgery, Postgraduate Institute of Medical Education and Research  
Chandigarh, India

### **SBS Mann**

Former Director, Government Medical College and Hospital  
Chandigarh, Former Head, Department of Otolaryngology and Head  
and Neck Surgery, Postgraduate Institute of Medical Education and  
Research, Chandigarh, Director-Principal, Miri Piri Institute of  
Medical Sciences and Research, Shahabad Markanda, Haryana, India