

---

# Cataract Surgery in Patients with Uveitis: Preoperative and Surgical Considerations

---

Alejandro Rodriguez-Garcia and C. Stephen Foster

Additional information is available at the end of the chapter

<http://dx.doi.org/10.5772/intechopen.71031>

---

## Abstract

Cataract is one of the most frequent visual impairment complications of uveitis, accounting for up to 40% of the visual loss seen in these patients. In general, uveitis patients differ from the general cataract population in that they are younger and have a higher rate of comorbidities, however the rates of inflammatory sequelae vary markedly among uveitic entities. Cataract development may be influenced by the cause and duration of uveitis, the degree of inflammation control, and the use of corticosteroid therapy. Cataract surgery in patients with uveitis represents a serious challenge due to pre-existing ocular comorbidities that may limit the visual outcome and difficult the surgical procedure; the need for preoperative control of inflammation; and the efficacy of postoperative management to avoid immediate and late ocular complications. A detailed ophthalmologic exam prior to surgery is essential to know the status of pre-existing pathologic changes, adjust the medical therapy to achieve absolute control of inflammation, establish a surgical plan, and deliver an objective visual prognosis to the patient or the relatives. The key point to surgical success is the absolute control of inflammation, meaning no cells in the anterior chamber for at least 3 months prior to surgery. Today, minimally invasive phacoemulsification with acrylic foldable intraocular lens implantation is the standard of care for most patients with uveitis. It must be taken into consideration that higher rates of intraoperative and postoperative complications may occur. Vision-limiting pathology related to pre-existing uveitis complications are the major contributing factors for limited postoperative visual outcome.

**Keywords:** uveitis, cataract, phacoemulsification, intraocular lens, steroids, macular edema, glaucoma

---

## 1. Introduction

Cataract represents a significant burden in the management and visual outcome of uveitis patients. Up to 40% of the visual loss seen in these patients is either solely or largely due to cataract [1]. Lens opacification is caused by repeated episodes or sustained intraocular inflammation characterized by the release of free oxygen radicals, lysosomal enzymes, immune complex deposition on the lens capsule, hypoxia, and altered composition of the aqueous humor [2]. The development of cataract depends on the type of uveitis, the degree and duration of the inflammatory process, and on the prolonged and excessive use of corticosteroids [3–5].

Cataract surgery in patients with uveitis represents a serious challenge for the anterior segment surgeon [6, 7]. Nowadays, clear cornea phacoemulsification with intraocular lens (IOL) implantation is the standard of care for most patients with uveitis [8, 9]. However, despite remarkable progress on surgical techniques and IOL materials, certain specific considerations should be taken into account regarding patient selection, preoperative preparation, as well as perioperative and postoperative management for successful long-term results [10, 11]. Nearly one-third of all uveitic eyes have small pupils, which represent a surgical technical difficulty [2]. In such cases, higher rates of additional intraoperative maneuvers are required to obtain proper visualization and phacoemulsification of the cataract [4, 12, 13]. And, while surgery is associated with an improvement in best corrected visual acuity (BCVA), higher rates of both, intraoperative and postoperative complications have been reported [14, 15]. Moreover, it has been shown that the final BCVA in uveitic eyes is worse than in non-uveitic ones [14]. Therefore, identifying the cause of uveitis and pre-existing pathologic changes that affect the visual outcome, achieving absolute control of inflammation before surgery, careful surgical planning, and solving intraoperative and postoperative complications are crucial to obtain a successful result (BCVA  $\geq$  20/40).

## 2. Epidemiology

Cataract is the most common ocular complication in children with chronic uveitis with an estimated rate from 35 to 52.0% [16]. In juvenile idiopathic arthritis (JIA)-associated uveitis, the prevalence varies from 40 to 60% and the incidence of new-onset cataract formation has been estimated as 0.04/eye-year [17, 18]. On the other hand, in adult patients it is one of the most frequent complications of uveitis with a prevalence rate as high as 50% as seen in Fuchs uveitis [6, 14, 19, 20]. In HLA-B27-associated anterior uveitis, the most common cause of uveitis in adults, cataract formation is the third most frequent complication with an estimated prevalence of 14%, and an incidence rate of 0.091 during follow-up time (**Table 1**) [21]. Cataract prevalence varies among different causes of uveitis and depends on multiple factors including etiology, localization of the inflammatory process, time elapsed between the onset and diagnosis of uveitis, the degree of inflammation, the clinical course, and the use of corticosteroids [1, 18, 22, 23].

Cause of uveitis	Cataract prevalence range (median)	Successful outcome BCVA $\geq$ 20/40 (Snellen)	Frequent complications	References
Fuchs uveitis	15–75% (50%)	83%	Intraoperative AC hemorrhage (3.6–76%) Hyphema Ocular hypertension (glaucoma) (3–35%) PCO (14.6%) Progressive vitreous opacification	[20, 27, 48, 49]
Herpetic uveitis	15–75% (24%)	72.2%	Viral reactivation Iris posterior synechiae Secondary glaucoma	[63, 151–153]
Juvenile idiopathic arthritis-associated uveitis	40–60% (50%)	60–70% (67%)	Exuberant postoperative inflammation Iris posterior synechiae Secondary glaucoma (25%) CME Cyclitic membrane Hypotony (Phthisis bulbi)	[4, 17, 18, 25, 26, 81, 95, 97–99, 101, 110]
HLA-B27 associated uveitis	9.2–20.1%	NA	Recurrent uveitis CME Iris synechiae	[21]
Pars planitis	36–42% (40%)	50–83%	Persistent vitritis (haze) CME (50%) Glaucoma (10%) PCO (10%) IOL Cocooning (29%) ERM Optic nerve atrophy	[23, 28, 140, 154]
Adamantiades-Behcet disease	21–26% (38.5%)	72.5% (42.4%)	Exuberant inflammation (12.5%) Iris posterior synechiae (17.5%) CME (12.5%) ERM (7.5%) Papillitis (optic nerve atrophy) (5%) PCO (37.5% most common)	[148, 155, 156]
Vogt-Koyanagi-Harada disease	10–35%	68%	Exuberant inflammation Iris anterior and posterior synechiae Pupillary membrane PCO (76%) Macular scarring	[135, 157]

Cause of uveitis	Cataract prevalence range (median)	Successful outcome BCVA $\geq$ 20/40 (Snellen)	Frequent complications	References
Sympathetic ophthalmia	31.8%	67.79% (72.2%)	PCO (77.7%) Glaucoma	[158]
Sarcoidosis	21%	61%	PCO (57.1%) Recurrent uveitis CME Glaucoma	[159]

AC = anterior chamber; PCO = posterior capsule opacification; CME = cystoid macular edema; ERM = epiretinal membrane.

**Table 1.** Prevalence, visual outcome, and complications of cataract surgery in uveitis.

### 3. Clinical characteristics of diverse forms of uveitis

In general, the uveitic population differs from the general population suffering from cataract in that they are younger and have a higher rate of comorbidities [15]. However, the rates of inflammatory sequelae vary markedly among uveitic entities [7, 24]. For this reason, each uveitis syndrome must be analyzed separately with respect to ocular complications and visual outcome [6, 14] (**Table 1**). While Fuchs uveitis regularly has the best visual prognosis and the least postoperative complications, JIA-associated uveitis has one of the most fear prognosis due to frequent pre-existing pathology, difficulties in reaching absolute control of inflammation, and multiple intraoperative and postoperative complications [4, 25–27].

### 4. Preoperative evaluation

A correct classification and etiologic diagnosis of the uveitic entity is very helpful to establish the appropriate surgical strategy and to determine the prognosis [8]. Moreover, a complete preoperative ophthalmologic examination is essential since pre-existing pathology will have significant therapeutic and prognostic visual implications [16, 28]. For instance, corneal opacity, vitreous haze, macular edema, and optic nerve atrophy usually result in a poor visual outcome [6, 19]. Therefore, it is very important that the patient and/or their relatives have an objective report on the status of the eye to be operated in order to have a realistic expectation of the final visual result. Ancillary diagnostic tests are always necessary to detect pre-existing pathologic changes that will allow us to render a more accurate visual prognosis. In most cases, it is helpful to perform a macular function test. Several methods are available for this purpose including the potential acuity meter (PAM), the laser interferometer (LI), and the focal electroretinogram (fERG) [29, 30]. The PAM test has proven an accuracy of 84% in patients with poor visual acuity (<20/40) [30]. On the other hand, LI has shown a

lower accuracy (65%) and a tendency for over-predicting vision compared to the PAM in these patients [29, 30]. Focal cone ERG is very sensitive for detecting macular pathology, showing 91% accuracy in eyes with poor visual acuity [30].

Linear A-B ultrasound is necessary to identify vitreous hemorrhage and opacity, as well as posterior segment changes like, retinal detachment, optic nerve swelling, and sclerochoroidal thickness [31]. Another very useful device is high-frequency ultrabiomicroscopy (UBM), which generates high-resolution images at an almost histological level. *In vivo* image sections may be obtained up to 3–6 mm in depth, permitting visualization of anterior segment structures [32]. Frequent indications for UBM in uveitis include uveitis-glaucoma-hyphema syndrome (UGH), sclerouveitis, herpetic anterior uveitis, pars planitis, pseudophakic uveitis, hypotony, peripheral toxocariasis, and ciliary body pathology [32, 33].

Retina fluorescein angiography (FA) allows the detection of many different forms of posterior segment inflammatory changes. It is used to evaluate the activity and extent of chorioretinitis and optic nerve involvement; identify macular edema and choroidal neovascularization; diagnose certain posterior uveitic entities with typical features; evaluate retinal vascular involvement and neovascularization; and to monitor the therapeutic response [34]. However, many inflammatory changes occur in the peripheral retina where visualization may be difficult with conventional angiography. Wide field scanning laser ophthalmoscopy performs ultra-wide angle FA allowing clear identification of peripheral lesions and accurate documentation of disease progression [35]. This recently new image technology has replaced conventional angiography for the diagnosis and monitoring of intermediate and many forms of posterior uveitis [35].

Indocyanine green angiography (ICGA) allows the detection of choroidal inflammation. Two patterns of choroidal vasculitis have been described: primary inflammatory choriocapillaropathy and stromal inflammatory vasculopathy [36]. The first pattern is characterized by non-perfusion of the choriocapillaris found in entities like, multiple evanescent white dot syndrome, acute posterior multifocal placoid pigment epitheliopathy, multifocal choroiditis, and serpiginous choroidopathy [36]. The choroidal stromal inflammatory vasculopathy pattern is seen in active Vogt-Koyanagi-Harada disease (VKH), ocular sarcoidosis, tuberculosis, and birdshot chorioretinopathy [37]. In Behcet's disease, as in other forms of uveitis, both ICGA vascular patterns may be seen at different stages of inflammation [38].

Today, the most frequently used imaging technique to detect and monitor macular inflammatory changes is optical coherence tomography (OCT). With an axial resolution in the 5–7  $\mu\text{m}$  range, it provides close to an *in-vivo* histologic view of the retina [39]. There are several types of OCT available for clinical purposes. The spectral-domain OCT is the most used method [40]. It allows high-speed, accurate images of the retina, particularly macular pathology like, cystoid and diffuse macular edema, subretinal fluid accumulation, epiretinal membrane formation, macular holes, and choroidal neovascularization [41]. Longer wavelength OCT systems, including the swept-source technology and en-face imaging, enhance the detection of subtle microstructural changes in chorioretinal disorders by improving imaging of the choroid [42–44]. A technique that produces high-resolution cross-sectional images of the entire choroid called enhanced depth imaging technique (EDI-OCT) has identified increased subfoveal

choroidal thickness in patients with active Behcet [45] and VKH disease, as well as loss of focal hyperreflectivity of the inner choroid in the acute and convalescent phases of VKH [46].

Once the preoperative evaluation is completed, a postoperative visual prognosis may be assumed, therapeutic adjustments may be applied, and a surgical plan is prepared based on pre-existing pathologic findings.

## 5. Preoperative preparation and therapeutic strategies

The key to surgical success in patients with uveitic cataract is the absolute control of inflammation, meaning no cells in the anterior chamber for at least 3 months prior to surgery [7]. This requisite is crucial to obtain an optimal surgical result and to minimize postoperative complications [7, 24]. Active uveitis at the time of cataract surgery has been associated with worse visual outcomes [15, 47]. Moreover, postoperative cystoid macular edema (CME) is more likely to develop in eyes with active inflammation within a 3-month period before surgery (relative risk 6.19) than those under control [41]. However, this general consensus of no cells in the anterior chamber prior to surgery has its exemptions [2]. In Fuchs uveitis, minimal but persistent anterior chamber cells and flare are frequently found despite intensive and sustained treatment with topical corticosteroids [48]. Hence, anti-inflammatory treatment is not indicated for the low-grade anterior chamber reaction seen in Fuchs uveitis and only occasionally, a short-course of corticosteroids is indicated for symptomatic exacerbations [49]. Other exemptions are related to the necessity for prompt surgical intervention in cases like, lens-induced uveitis, cyclitic membrane formation with hypotony, persistent vitreous opacity or hemorrhage, and retinal detachment [50, 51].

Preoperative management depends specifically on the type and etiology of uveitis. For inactive idiopathic anterior non-granulomatous uveitis as for Fuchs uveitis, topical administration of prednisolone acetate 1% four times a day, starting 3–7 days before surgery may be sufficient to avoid an outburst of postoperative inflammation [24]. On the contrary, patients with JIA-associated uveitis, anterior granulomatous uveitis, intermediate, posterior, and panuveitis also require oral prednisone (1.0 mg/kg/day) starting 3 days before surgery and continued for a week after cataract removal and then tapered slowly according to the inflammatory status [52, 53]. Preoperative oral steroids have been shown to be effective in reducing the risk of CME [41]. If patients are on immunosuppressive chemotherapy and/or biologics, they should be continued at current dosage [11]. In case that systemic corticosteroids are contraindicated (e.g., diabetes mellitus, metabolic disease, acid-peptic disease, obesity, or osteoporosis), periocular administration (transseptal or sub-Tenon's) of triamcinolone acetonide (40 mg/ml) should be considered [54, 55]. Alternative immunosuppressive agents like, cyclosporin-A, tacrolimus, or anti-metabolites may be administered to these patients considering that most of these medications require a longer period of time (usually 4–6 weeks) to reach an optimal therapeutic effect [56].

The use of topical non-steroidal anti-inflammatory drugs (NSAIDs) like, ketorolac 0.4%, nepafenac 0.15%, or bromfenac 0.09%, have become a standard of care practice for the perioperative

management of inflammation, pain, surgical-induced miosis, and cystoid macular edema in uneventful and also in uveitic cataract surgery [57–59]. A systematic review found high-quality evidence that topical NSAIDs are more effective than topical steroids in preventing the short-term pseudophakic CME in non-uveitic cataract surgery [60]. On the other hand, a recent evidence-based review conducted by the American Academy of Ophthalmology found that the claimed made about the synergistic effect of combined topical steroids and NSAIDs remains unproven [61]. In addition, NSAIDs have only a short-term therapeutic effect on prompt visual recovery and reduction of established CME, but no effect on the long-term visual outcome [57, 58, 61]. There is good collective clinical evidence and rationale that the application of a topical NSAID 3 days before surgery reduces CME and improves vision in the short-term [61]. Because the COX-2 enzyme is inducible and mostly responsible for the inflammatory process, the selective inhibitory effect of nepafenac and bromfenac makes them more suitable for this purpose [62]. Nepafenac has shown the shortest time to reach maximal concentration and the greatest aqueous humor peak concentration compared to ketorolac and bromfenac in eyes having cataract surgery [62]. After the surgical procedure, topical NSAIDs use is usually extended for 4–6 weeks [1, 10].

There are other special conditions in uveitis in which certain specific actions should be taken before cataract extraction is performed. Such is the case of herpetic uveitis in which prophylactic anti-viral therapy with acyclovir or valacyclovir should be administered at least 1 week before surgery in order to avoid recurrent viral infection [63, 64]. Other special consideration is the preoperative management of prominent band keratopathy interfering with cataract visualization which may be treated with EDTA 1–2% calcium chelation, or Excimer laser PTK before cataract surgery [65, 66].

Cataract and glaucoma frequently coexist as uveitis complications, and a combined surgical procedure may be associated with an increased risk of glaucoma surgery failure [67, 68]. In such cases, it may result better to perform a clear cornea small-incision cataract extraction first, followed later on by filtration surgery or a valve implantation with anti-metabolites [69, 70]. One must consider that uveitic glaucoma eyes operated for trabeculectomy with mitomycin-C which had previous cataract surgery or granulomatous uveitis, have a higher risk of surgical failure (RR = 2.957, P = 0.0344, and RR = 3.805, P = 0.0106, respectively) [71]. A higher risk of glaucoma surgical failure has also been associated with idiopathic, intermediate, and Fuchs uveitis; active intraocular inflammation at the time of surgery; and relapse of uveitis [72]. Moreover, the success rate of filtration surgery in uveitic eyes is significantly lower than that of non-uveitic, and many patients with successful intraocular pressure (IOP) control still require anti-glaucoma therapy to maintain adequate IOP levels in the postoperative period [72].

Posterior vitrectomy and cataract extraction may be an alternative for patients with prominent posterior segment pathology including vitreous opacity, hemorrhage, cystoid macular edema, and tractional retinal detachment [73]. There is reasonable evidence that cataract phacoemulsification combined with posterior vitrectomy has a favorable visual outcome for some patients with refractory inflammation, particularly those with significant vitreous opacity and chronic macular edema [13, 74]. In children, this combined surgical approach has been used for JIA-associated uveitis, pars planitis, and other forms of posterior uveitis [75].

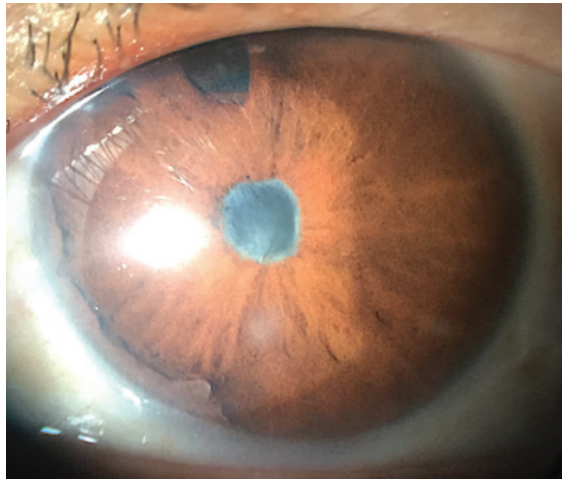


However, this technique is not exempt of serious postoperative complications like, glaucoma, macular edema, and exuberant inflammation [75, 76]. For specific cases with various ocular complications, multiple combined surgical strategies have been postulated including phacoemulsification with IOL implantation, posterior vitrectomy, intravitreal sustained-release corticosteroid injection, and glaucoma tube implantation with promising results [77].

## 6. Surgical technique and intraoperative maneuvers

Nowadays, small clear corneal incision phacoemulsification surgery is preferred over extracapsular cataract extraction (ECCE) and lensectomy for most patients with uveitis [78, 79]. Since cataract surgery in these patients is frequently complicated by corneal opacification, iris synechiae, pupillary and cyclitic membranes, among others, the surgical technique should be minimally invasive with precise and delicate maneuvers [10, 24] (**Figure 1**). Most studies report a higher rate of additional maneuvers, notably iris and pupillary manipulation within a range between 19 and 67% of eyes [4–6, 25].

Dealing with unexpected intraoperative complications like, corneal stromal edema; anterior chamber hemorrhage; pigment dispersion; posterior capsule rupture with vitreous exposure is key to achieve the best surgical outcome possible [6, 19, 75]. The first challenge that the surgeon faces is an adequate exposure and visualization of the cataract. Iris synechiolysis, pupillary membrane removal, and pupil distension with iris hooks or iris stretch devices are frequently required for proper cataract visualization [80, 81]. There is no general consensus on what is the best way to deal with the pathologic changes of the anterior segment encountered in uveitic eyes. However, it is generally agreed that



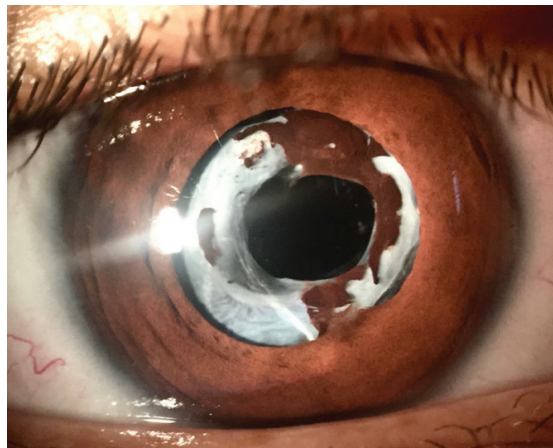
**Figure 1.** Anterior segment appearance of a patient with Vogt-Koyanagi-Harada disease showing extensive peripheral anterior and posterior synechiae, shallow anterior chamber and a pupillary membrane in front of a secondary cataract.



attempts should be made to minimize surgical maneuvers in order to lessen tissue manipulation and trauma as possible [6, 24, 26].

The capsulorhexis should measure between 5 and 6 mm in diameter because smaller apertures are frequently associated with capsular phimosis and posterior iris synechiae to the anterior capsule remnant [82–84] (**Figure 2**). On the other hand, larger diameter capsulorhexis may affect the IOL centration and stability [83]. The phacoemulsification technique may vary depending on the density and zonular status of the cataract, but an effort should be made to use the less ultrasound power and time possible, to perform vigorous cortical and posterior capsule cleaning, and to avoid posterior capsule rupture [11, 19]. Avoiding the latter is crucial to obtain a good postoperative result, especially in chronic and recurrent uveitis like, herpetic uveitis, pars planitis, VKH disease, toxoplasmosis, among others [6, 24, 85]. In these cases, posterior capsule rupture with vitreous exposure may be a contraindication for IOL implantation due to a high probability of postoperative excessive and persistent inflammation [12, 86]. In uveitic eyes with encapsulated and subluxated IOLs with extensive fibrosis, IOL removal may be necessary at some point of the postoperative period to control severe inflammation and reduce its consequences [87–89]. For eyes with extensive membrane formation in the anterior vitreous, vitrectomy after performing a posterior central capsulorhexis must be considered [90].

Decision making regarding the type of IOL to be used; anterior or posterior chamber IOL implantation; possible IOL sulcus fixation; combined filtration surgery, MIGS, or valve implantation; central posterior capsulorhexis after PC-IOL implantation with anterior vitrectomy; lensectomy, as well as posterior vitrectomy with or without retinal surgery are frequently met during uveitic cataract surgery, and the surgeon must be prepared to make the best decision for the particular case [91–94]. The implantation of a foldable IOL “in the bag” is ideal for most cases of uveitis with certain exceptions [4, 95]. Until now, it is not clear how to proceed in children with uveitic cataract, and randomized controlled trials (RCT) are necessary to elucidate



**Figure 2.** Patient with ankylosing spondylitis and HLA-B27-associated uveitis after cataract surgery showing capsular phimosis and partial adherence of the pigmented epithelium of the iris to the anterior capsule remnant.

this matter [4, 25, 26, 81]. Historically, uveitic cataract surgery during childhood has been associated with a higher rate of surgical complications, particularly excessive postoperative inflammation [6, 10]. In the past, this situation made that the preferred surgical techniques for cataract extraction in this group including ECCE with posterior pars plana vitrectomy or lensectomy [4, 95]. However, recent evidence favors the implantation of foldable PC-IOLs in children with uveitis, including patients with JIA-associated iridocyclitis [25, 26, 96–101].

Intraocular corticosteroids can be administered during surgery. Intracameral dexamethasone phosphate (400 µg/0.1 ml) or intravitreal triamcinolone (4 mg/0.1 ml) injection (IVTA) may be administered intraoperatively, except in advanced secondary glaucoma or known steroid-responsive patients [4, 102]. A prospective and comparative RCT between oral corticosteroids and preservative-free IVTA injection showed no differences in postoperative anterior chamber reaction, IOP levels, and central macular thickness (CMT) [103]. Another study found a better effect of IVTA versus orbital floor TA on macular edema and postoperative inflammation after cataract surgery in patients with uveitis [55]. However, IVTA injections have a temporary effect therefore, may require repeated injections which are not exempt of serious ocular complications like, elevated IOP (30–43% eyes), bacterial endophthalmitis, vitreous hemorrhage, and retinal detachment [104]. For those eyes at higher risk for intravitreal injection, sub-Tenon's or transseptal TA can be administered at the end of surgery [19].

Intravitreal steroid sustained-release devices containing fluocinolone acetonide 0.59 mg or dexamethasone phosphate 0.7 mg have proven to be beneficial for the control of inflammation, prevention of CME, or reduction of CMT if applied a few days to weeks before or during cataract surgery [105]. Although no general consensus exists on the appropriate surgical time, it seems reasonable to perform the cataract surgery within 4–6 weeks from the last steroid implantation [105–107]. The most fear complication of sustained-release steroid devices is ocular hypertension (OHT). A meta-analysis found that 66% of eyes develop OHT after the implantation of the 0.59 mg fluocinolone acetonide device, compared to 32% following 4 mg IVTA, and only 15% with the 0.7 mg dexamethasone implant [108]. Risk factors for developing OHT include, pre-existing glaucoma, higher baseline IOP, younger age, OHT following previous injection, uveitis, higher steroid dosage, and fluocinolone implant [108]. A new sustained-release implant containing 0.19 mg fluocinolone acetonide has shown promising results improving visual acuity and reducing CMT with a significant reduction of IOP compared to the dexamethasone implant and IVTA [109].

## 7. Considerations for intraocular lenses

The general consensus regarding cataract surgery in patients with uveitis is that implantation of IOLs may be safely performed when ocular inflammation is completely abolished for a minimum period of 3 months [4, 7]. However, a debate still exists if an IOL should be implanted in specific circumstances like, lens-induced uveitis, JIA-associated iridocyclitis, young children with posterior or panuveitis, and intraoperative rupture of the posterior capsule with vitreous exposure [25, 26, 91, 110]. The implantation of an IOL triggers different intraocular responses including inflammation and foreign body reaction, as well as

activation of the complement and coagulation cascades [83, 111–113]. These reactions along with the breakdown of the blood-aqueous barrier induced by surgery may increase cellular adhesion and lens epithelial cell (LEC) proliferation on the anterior surface of the IOL, resulting in anterior capsule phimosis, fibrosis, and posterior capsule opacification (PCO) [114]. With the advent of technologic development, many advances have been made to reduce IOL-induced reactions and to improve their biocompatibility [115]. The inflammatory response induced by IOLs is inversely related to its biocompatibility, so the higher the biocompatibility, the lower the inflammatory response [15, 83, 115]. Even though they were considered biologically inert, the first IOLs made of polymethyl-methacrylate (PMMA) were capable of producing foreign body reaction, as well as activate the complement and coagulation cascades [113, 116].

Different strategies have been used to reduce the host response, including the modification of the IOL surface by making it hydrophilic, like in heparin-coated PMMA IOLs, or hydrophobic such as surface passivated [83]. Heparin surface-modified IOLs have improved biocompatibility compared with unmodified PMMA IOLs in eyes at risk for severe postoperative inflammation, including those with uveitis [117, 118].

Foldable IOLs may be hydrophobic, including silicone IOLs or hydrophilic, and both surfaces have demonstrated to be relatively inert [114, 119]. Hydrophobic surfaces resist cell adhesion while hydrophilic ones reduce electrostatic forces and cellular adhesion, preventing the attraction of inflammatory cells and their activation, as well as adherence of fibroblasts to the IOL surface [120, 121].

Anterior capsule phimosis has been related to the degree of fibrotic reaction produced by pro-inflammatory cytokines released by residual LEC [122, 123]. Careful vacuuming the undersurface of the anterior capsule helps to reduce the number of LEC [82, 124]. Capsular phimosis has been reported more frequently with hydrogel (poly-HEMA) than acrylic, and silicone IOLs [83, 125]. Foreign body giant cell precipitates are less frequently seen in hydrophilic than on hydrophobic IOL surfaces and heparin-coated PMMA IOLs [115, 126]. The frequency of posterior capsule opacification (PCO) is highest with PMMA IOLs, less with silicone and minimal with acrylic IOLs [124, 127].

Few studies have evaluated the visual outcome following cataract surgery in uveitis with silicone IOL implantation. Overall, only 30% of eyes have achieved 20/40 of better vision with silicone IOLs, fewer than any other type of IOL [15]. Silicone was the first material available for foldable IOLs, but its use has declined particularly because it cannot be used for a monobloc open-loop designed, the preferred choice for preloaded injectors that allow implantation through small corneal incisions [128].

With the advent of acrylic foldable IOLs, the biocompatibility issue has become a minor concern, but controversy still exists of which material, hydrophilic or hydrophobic is best suitable for patients with uveitis [120, 126, 129]. Since the lens is surrounded by aqueous humor, it was thought that hydrophilic materials were more biocompatible than hydrophobic for patients with uveitis [89, 92]. However, there is insufficient evidence to determine the effects of different types of IOL materials, including hydrophobic and hydrophilic acrylic IOLs in patients with uveitis [129]. Results from the largest RCT provide only preliminary evidence

that acrylic IOLs may perform better than silicone IOLs in terms of improving vision and reducing the chances of postoperative inflammation and complications [129, 130]. A large multicenter RCT with standardized outcome measurements is necessary to properly address the surgical outcome of patients with uveitic cataract.

## 8. Immediate postoperative management

The postoperative management is as important as the preoperative preparation and the surgical procedure itself. Since the first postoperative moments, intense topical corticosteroids (1% prednisolone acetate hourly), topical NSAIDs (anti-COX-2 selective), topical wide spectrum antibiotics (fourth generation fluoroquinolones), overnight steroid ointment, as well as mydriatic-cycloplegic combinations (e.g., 1% tropicamide + 5% phenylephrine every 6-hours × 5–7 days) should be administered [11, 24, 131]. Topical corticosteroids are wined down according to the grade of anterior chamber inflammatory reaction, the presence of glaucoma, or OHT in steroid-responders [54]. In case the patient was given systemic corticosteroids, they should be maintained at immunosuppressive levels (1 mg/kg/day) for 7–10 days before reducing them slowly to a minimum dose of 7.5 mg/day [56]. In case the patient is on immunosuppressive chemotherapy or biologic therapy, it should be continued at maintenance dose [19, 131]. Systemic anti-virals used for herpetic uveitis should be kept at therapeutic dose for 7–14 days postoperative, and then reduced to prophylactic levels (acyclovir, 600–800 mg/day and valacyclovir 500–1000 mg/day) for several weeks to months before stopping them [63, 64, 132].

## 9. Postoperative complications and their management

Postoperative complications after cataract surgery in patients with uveitis are relatively frequent [8]. The reported prevalence of complications is higher in ECCE than in phacoemulsification [78, 79, 133]. The risk for postoperative complications also depends on the type of uveitis and the degree of ocular involvement [8, 12, 85] (**Table 1**). Despite all preventive measurements taken before and during surgery, the most frequent and fear postoperative complication is the outburst of inflammation out of expected proportions [5]. Significant inflammation characterized by >2+ anterior chamber cells, extensive protein exudation with fibrin and plasmoid bodies formation, as well as fibrinoid membranes covering the pupil, and hypopyon may be seen [7, 19, 24, 134]. This aggressive inflammatory response is commonly associated with early postoperative iris synechiae formation and pupillary inflammatory membranes, particularly in disorders like JIA-associated uveitis, and VKH, among others [4, 6, 131, 135]. The best way to deal with this unexpected postoperative inflammatory response consists on avoiding it by previous absolute control of inflammation and the implementation of perioperative measurements discussed before. Nevertheless, in those cases in which a significant inflammatory reaction occurs, an adjustment to the systemic prednisone dose and the administration of atropine 1% will help to control the inflammation [52–54].

Other immediate postoperative complications that may be seen are hyphema and significant pigment dispersion throughout the anterior segment [19, 24]. Pigment dispersion is related to a variety of factors including, surgical trauma, small pupil, and age [24, 83, 91]. In both cases, regular tonometry is mandatory for opportune detection of severe OHT related to clogging of the trabecular meshwork by ghost cells or pigment, respectively [6]. If anti-glaucoma therapy is required, prostaglandin analogs as well as alpha-adrenergic drugs should be avoided as possible because they may exacerbate the inflammatory process [69]. In some patients with corneal stromal edema and Descemet folds due to high IOP, oral carbonic anhydrase inhibitors (e.g., acetazolamide 250 mg, 3–4 times a day) may be administered [69]. If the IOP becomes uncontrollable with medical therapy, filtration surgery or valve implantation should be considered to avoid further optic nerve damage [69, 136]. Finally, an excessive postoperative inflammatory process may produce significant vitreous opacity and membrane formation [5]. Once acute infectious endophthalmitis has been ruled out in such cases, aggressive anti-inflammatory therapy with systemic, periocular, and even intravitreal corticosteroids should be administered [52, 54, 55, 106]. If vitreous condensation and organization persist, a pars plana vitrectomy with or without intravitreal corticosteroid injection should be performed [13, 73, 75, 137].

In the late postoperative period, ocular complications are usually related with recurrent intra-ocular inflammation occurring from 8.3 to 53% of cases [8, 12, 85, 133]. Recurrent postoperative uveitis may produce anterior and/or posterior iris synechiae which may cause an angle or pupillary block glaucoma, respectively [69].

Certainly one of the most frequent ocular complications observed in this late period is posterior capsule opacification seen in up to 58% of cases [82, 83, 85, 124, 133]. Nd-Yag laser capsulotomy usually resolves this problem, but in some cases retrolental hyaloid-vitreous opacification or significant deposition of pigment and inflammatory debris on the IOL surface may occur therefore, recurrent low-energy Nd-Yag laser and other operative procedures may be needed for polishing the IOL [82, 138]. It must be considered that Nd-Yag laser capsulotomy in patients with uveitis is associated with a higher risk for vision-threatening complications, including OHT, CME, IOL damage or luxation, as well as retinal detachment [40, 139].

Another very important visual-threatening postoperative complication is macular edema occurring from 33 to 56% after ECCE and from 12 to 59% after phacoemulsification [12, 85, 133, 140]. The appearance of CME depends on multiple factors including the cause of uveitis and the type of surgical procedure performed [41]. Treatment of uveitic macular edema (UME) includes the administration of periocular injections of depot corticosteroids [54, 141]. However, as stated before, IVTA has shown to be superior to orbital floor injection for the treatment of UME [55, 142]. OHT is a potential complication of both types of steroid administration and should always be considered, particularly after repeated intravitreal injections [55, 108, 143]. Sustained-delivery corticosteroid devices may also be administered for this purpose [105, 106, 144]. In patients with bilateral UME, steroid-responders or those who do not accept periocular or intravitreal corticosteroid injections, oral prednisone along with oral carbonic anhydrase inhibitor (e.g., acetazolamide 250 mg every 12 hours) may be administered [54]. Epiretinal membrane formation is more commonly seen in patients with chronic

UME with a prevalence ranging from 15 to 56% [12, 145, 146]. Treatment consists of pars plana vitrectomy and internal limiting membrane delamination [73, 146, 147].

Other less common, but serious complications is retinal detachment and hypotony [5, 26]. Hypotony may be related to the retinal detachment per se, or to a low aqueous humor production due to inflammation of the ciliary process, or tractional detachment of the ciliary body due to cyclitic membrane formation [26]. Postoperative hypotony may evolve to phthisis bulbi [10, 88]. Both complications should be attended immediately by retinopexy, and/or posterior vitrectomy with cyclitic membrane and sometimes intraocular lens removal, as well as peri- or intraocular corticosteroid administration [87, 88].

## 10. Prognosis and visual outcome

The outcome of cataract surgery in patients with uveitis is less predictable than in other causes of cataract. Many factors may contribute to this uncertainty including, pre-existing pathologic changes, intraoperative technical challenges, the impact of postoperative exuberant inflammation, and the reversibility of postoperative complications derived from it [14]. Vision-limiting pathology related to pre-existing uveitis complications, especially macular edema and optic neuropathy are probably the major contributing factors for limited postoperative visual outcome [8, 15, 85].

Different studies suggest that visual prognosis varies according to uveitis subtypes [5, 15, 26]. For instance, the proportion of eyes achieving 20/40 or better vision is better in Fuchs uveitis and worse in Behcet's disease, VKH disease, or sympathetic ophthalmia [20, 27, 47, 148]. In general, diseases that spare the posterior segment have a better prognosis than those affecting it, particularly macular and optic nerve involvement [5, 6, 8, 85]. In addition, acute uveitic entities tend to be associated with better outcome than chronic ones [12].

Uveitic cataract surgery has been associated with worse postoperative visual acuity, higher IOP, and more than double prevalence of UME when compared with non-uveitic cataract surgery [14]. Moreover, the visual outcome following uveitic cataract extraction is not as good as that of age-related cataract surgery with the exception of Fuchs uveitis [27, 149]. Systematic reviews found a successful visual outcome (20/40 or better) in 96% of eyes with age-related cataract surgery compared to 70% in uveitic eyes undergoing either phacoemulsification or ECCE [15, 149]. ECCE and phacoemulsification seem to have similar visual outcomes compared to half less successful rate after pars plana lensectomy [15]. With respect to the comparable visual results reported between ECCE and phacoemulsification, it must be taken into account that most ECCE trials have more exclusion criteria than phacoemulsification studies, favoring better visual outcomes [15, 85, 150].

Finally, regarding IOL implantation, more eyes (71%) undergoing cataract surgery with IOL implantation than eyes left aphakic (52%) achieved a BCVA  $\geq$  20/40 vision postoperatively [14]. Eyes receiving acrylic IOLs or heparin surface-modified PMMA had better visual outcomes than those receiving non-heparin-PMMA or silicone IOLs [14, 15, 83, 94].



## Author details

Alejandro Rodriguez-Garcia<sup>1\*</sup> and C. Stephen Foster<sup>2,3,4</sup>

\*Address all correspondence to: [immuneye@gmail.com](mailto:immuneye@gmail.com)

1 Tecnológico de Monterrey, Escuela de Medicina y Ciencias de la Salud, Institute of Ophthalmology and Visual Sciences, Ocular Immunology and Uveitis Service, Monterrey, Mexico

2 Massachusetts Eye Research and Surgery Institute, Waltham, MA, USA

3 Ocular Immunology and Uveitis Foundation, Weston, MA, USA

4 Department of Ophthalmology, Harvard Medical School, Boston, MA, USA

## References

- [1] Durrani OM. Degree, duration, and causes of visual loss in uveitis. *The British Journal of Ophthalmology*. 2004;**88**:1159-1162
- [2] Hooper PL, Rao NA, Smith RE. Cataract extraction in uveitis patients. *Survey of Ophthalmology*. 1990
- [3] Urban RC, Cotlier E. Corticosteroid-induced cataracts. *Survey of Ophthalmology*. 1986;**31**:102-110
- [4] Foster CS, Barrett FR. Cataract development and cataract surgery in patients with juvenile rheumatoid arthritis-associated iridocyclitis. *Ophthalmology*. 1993;**100**:809-817
- [5] Elgohary MA, McCluskey PJ, Towler H, Okhravi N, Singh RP, Obikpo R, Lightman SS. Outcome of phacoemulsification in patients with uveitis. *The British Journal of Ophthalmology*. 2007;**91**:916-921
- [6] Agrawal R, Murthy S, Ganesh SK, Phaik CS, Sangwan V, Biswas J. Cataract surgery in uveitis. *International Journal of Inflammation*. 2012;**2012**:1-16
- [7] Foster CS, Fong LP, Singh G. Cataract surgery and intraocular lens implantation in patients with uveitis. *Ophthalmology*. 1989;**96**:281-288
- [8] Yoeruek E, Deuter C, Gieselmann S, Saygili O, Spitzer MS, Tatar O, Bartz-Schmidt KU, Szurman P. Long-term visual acuity and its predictors after cataract surgery in patients with uveitis. *European Journal of Ophthalmology*. 2010;**20**:694-701
- [9] Pershing S, Kumar A. Phacoemulsification versus extracapsular cataract extraction: Where do we stand? *Current Opinion in Ophthalmology*. 2011;**22**:37-42
- [10] Jancevski M, Foster CS. Cataracts and uveitis. *Current Opinion in Ophthalmology*. 2010;**21**:10-14



- [11] Foster CS, Rashid S. Management of coincident cataract and uveitis. *Current Opinion in Ophthalmology*. 2003;**14**:1-6
- [12] Estafanous MF, Lowder CY, Meisler DM, Chauhan R. Phacoemulsification cataract extraction and posterior chamber lens implantation in patients with uveitis. *American Journal of Ophthalmology*. 2001;**131**:620-625
- [13] Walker J, Rao NA, Ober RR, Liggett PE, Smith REA. Combined anterior and posterior approach to cataract surgery in patients with chronic uveitis. *International Ophthalmology*. 1993;**17**:63-69
- [14] Chu CJ, Dick AD, Johnston RL, Yang YC, Denniston AK. Cataract surgery in uveitis: A multicentre database study. *The British Journal of Ophthalmology*. 2017;**101**:1132-1137
- [15] Mehta S, Linton MM, Kempen JH. Outcomes of cataract surgery in patients with uveitis: A systematic review and meta-analysis. *American Journal of Ophthalmology*. 2014;**158**:676-692
- [16] Rosenberg KD, Feuer WJ, Davis JL. Ocular complications of pediatric uveitis. *Ophthalmology*. 2004;**111**:2299-2306
- [17] Thorne JE, Woreta F, Kedhar SR, Dunn JP, Jabs DA. Juvenile idiopathic arthritis-associated uveitis: Incidence of ocular complications and visual acuity loss. *American Journal of Ophthalmology*. 2007;**143**:840-846
- [18] Thorne JE, Woreta FA, Dunn JP, Jabs DA. Risk of cataract development among children with juvenile idiopathic arthritis-related uveitis treated with topical corticosteroids. *Ophthalmology*. 2010;**117**:1436-1441
- [19] Rojas B, Zafirakis P, Foster SC. Cataract surgery in patients with uveitis. *Current Opinion in Ophthalmology*. 1997;**8**:6-12
- [20] Jones NP. Cataract surgery in Fuchs' heterochromic uveitis: Past, present, and future. *Journal of Cataract & Refractive Surgery*. 1996;**22**:261-268
- [21] Loh AR, Acharya NR. Incidence rates and risk factors for ocular complications and vision loss in HLA-B27-associated uveitis. *American Journal of Ophthalmology*. 2010;**150**:534-542
- [22] Tomkins-Netzer O, Talat L, Bar A, Lula A, Taylor SR, Joshi L, Lightman S. Long-term clinical outcome and causes of vision loss in patients with uveitis. *Ophthalmology*. 2014;**121**:2387-2392
- [23] Niederer RL, Sharief L, Bar A, Lightman SL, Tomkins-Netzer O. Predictors of long-term visual outcome in intermediate uveitis. *Ophthalmology*. 2017;**124**:393-398
- [24] Meier FM, Tuft SJ, Pavésio CE. Cataract surgery in uveitis. *Ophthalmology Clinics of North America*. 2002;**15**:365
- [25] Terrada C, Julian K, Cassoux N, Prieur AM, Debre M, Quartier P, LeHoang P, Bodaghi B. Cataract surgery with primary intraocular lens implantation in children with uveitis: Long-term outcomes. *Journal of Cataract & Refractive Surgery*. 2011;**37**:1977-1983

- [26] Quiñones K, Cervantes-Castañeda RA, Hynes AY, Daoud YJ, Foster CS. Outcomes of cataract surgery in children with chronic uveitis. *Journal of Cataract & Refractive Surgery*. 2009;**35**:725-731
- [27] Tejwani S, Murthy S, Sangwan VS. Cataract extraction outcomes in patients with Fuchs heterochromic cyclitis. *Journal of Cataract & Refractive Surgery*. 2006;**32**:1678-1682
- [28] Heinz C, Schoonbrood S, Heiligenhaus A. Intermediate uveitis in children and young adults: Differences in clinical course, associations and visual outcome. *The British Journal of Ophthalmology*. 2014;**98**:1107-1111
- [29] Cuzzani OE, Ellant JP, Young PW, Gimbel HV, Rydz M. Potential acuity meter versus scanning laser ophthalmoscope to predict visual acuity in cataract patients. *Journal of Cataract & Refractive Surgery*. 1998;**24**:263-269
- [30] Fish GE, Birch DG, Fuller DG, Straach RA. Comparison of visual function tests in eyes with maculopathy. *Ophthalmology*. 1986;**93**:1177-1182
- [31] Gupta V, Al-Dhibi HA, Arevalo JF. Retinal imaging in uveitis. *Saudi Journal of Ophthalmology*. 2014;**28**:95-103
- [32] Tran VT, Lehoang P, Herbort CP. Value of high-frequency ultrasound biomicroscopy in uveitis. *Eye (Lond)*. 2001;**15**:23-30
- [33] Ciardella AP, Prall FR, Borodoker N, Cunningham ET. Imaging techniques for posterior uveitis. *Current Opinion in Ophthalmology*. 2004;**15**:519-530
- [34] Khairallah M, Jelliti B. Fluorescein angiography in uveitis. *Acta Ophthalmologica*. 2011;**89**(s248):0-0. DOI: 10.1111/j.1755-3768.2011.4231.x
- [35] Kaines A, Tsui I, Sarraf D, Schwartz S. The use of ultra wide field fluorescein angiography in evaluation and management of uveitis. *Seminars in Ophthalmology*. 2009;**24**:19-24
- [36] Bouchenaki N, Cimino L, Auer C, Tao Tran V, Herbort CP. Assessment and classification of choroidal vasculitis in posterior uveitis using indocyanine green angiography. *Klinische Monatsblätter für Augenheilkunde*. 2002;**219**:243-249
- [37] Herbort CP. Fluorescein and indocyanine green angiography for uveitis. *Middle East African Journal of Ophthalmology*. 2009;**16**:168-187
- [38] Klaeger A, Tran TV, Hiroz CA, Morisod L, Herbort CP. Indocyanine green angiography in Behcet's uveitis. *Retina*. 2000;**20**:309-314
- [39] Hassenstein A, Bialasiewicz AA, Richard G. Optical coherence tomography in uveitis patients. *American Journal of Ophthalmology*. 2000;**130**:669-670
- [40] Nazari H, Dustin L, Heussen FM, Sadda S, Rao NA. Morphometric spectral-domain optical coherence tomography features of epiretinal membrane correlate with visual acuity in patients with uveitis. *American Journal of Ophthalmology*. 2012;**154**:78-86
- [41] Bélair ML, Kim SJ, Thorne JE, Dunn JP, Kedhar SR, Brown DM, Jabs DA. Incidence of cystoid macular edema after cataract surgery in patients with and without uveitis using optical coherence tomography. *American Journal of Ophthalmology*. 2009;**148**:128-135

- [42] Copete S, Flores-Moreno I, Montero JA, Duker JS, Ruiz-Moreno JM. Direct comparison of spectral-domain and swept-source OCT in the measurement of choroidal thickness in normal eyes. *The British Journal of Ophthalmology*. 2014;**98**:334-338
- [43] Tan CS, Cheong KX, Lim LW, Sadda SR. Comparison of macular choroidal thicknesses from swept source and spectral domain optical coherence tomography. *The British Journal of Ophthalmology*. 2016;**100**:995-999
- [44] Chee SP, Chan SWN, Jap A. Comparison of enhanced depth imaging and swept source optical coherence tomography in assessment of choroidal thickness in Vogt-Koyanagi-Harada disease. *Ocular Immunology and Inflammation*. 2016;**2012**:1-5
- [45] Kim M, Kim H, Kwon HJ, Kim SS, Koh HJ, Lee SC. Choroidal thickness in Behçet's uveitis: An enhanced depth imaging-optical coherence tomography and its association with angiographic changes. *Investigative Ophthalmology & Visual Science*. 2013;**54**:6033-6037
- [46] Nakayama M, Keino H, Okada AA, Watanabe T, Taki W, Inoue M, Hirakata A. Enhanced depth imaging optical coherence tomography of the choroid in Vogt-Koyanagi-Harada disease. *Retina*. 2012;**32**:2061-2069
- [47] Lin CP, Yeh PT, Chen PF, Yang CM, Cataract HFR. Extraction surgery in patients with uveitis in Taiwan: Risk factors and outcomes. *Journal of the Formosan Medical Association*. 2014;**113**:377-384
- [48] Ram J, Kaushik S, Brar GS, Gupta A, Gupta A. Phacoemulsification in patients with Fuchs' heterochromic uveitis. *Journal of Cataract & Refractive Surgery*. 2002;**28**:1372-1378
- [49] Bonfioli AA, Curi ALL, Oréfice F. Fuchs' heterochromic cyclitis. *Seminars in Ophthalmology*. 2005;**20**:143-146
- [50] Marak GE. Phacoanaphylactic endophthalmitis. *Survey of Ophthalmology*. 1992;**36**:325-339
- [51] Kerkhoff FT, Lamberts QJ, van den Biesen PR, Rothova A. Rhegmatogenous retinal detachment and uveitis. *Ophthalmology* 2003;**110**:427-431
- [52] Rodríguez-García A. When should I consider using systemic corticosteroids to treat uveitis? Curbside Consultation in Uveitis: 49 Clinical Questions. In: *Curbside Consultation in Ophthalmology Series*. C. Stephen Foster (editor). SLACK Incorporated. Thorofare, NJ, USA. 2012:27-30. ISBN: 978-1-55642-998-9
- [53] Meacock WR. Steroid prophylaxis in eyes with uveitis undergoing phacoemulsification. *The British Journal of Ophthalmology*. 2004;**88**:1122-1124
- [54] Rothova A. Corticosteroids in uveitis. *Ophthalmology Clinics of North America*. 2002;**15**:389-394
- [55] Roesel M, Tappeiner C, Heinz C, Koch JM, Heiligenhaus A. Comparison between intravitreal and orbital floor triamcinolone acetonide after phacoemulsification in patients with endogenous uveitis. *American Journal of Ophthalmology*. 2009;**147**:406-412

- [56] Jabs DA, Rosenbaum JT, Foster CS, Holland GN, Jaffe GJ, Louie JS, Nussenblatt RB, Stiehm ER, Tessler H, Russell NVG, Whitcup SM, Yocum D. Guidelines for the use of immunosuppressive drugs in patients with ocular inflammatory disorders: Recommendations of an expert panel. *American Journal of Ophthalmology*. 2000;**130**:492-513
- [57] Donnenfeld ED, Perry HD, Wittpenn JR, Solomon R, Nattis A, Chou T. Preoperative ketorolac tromethamine 0.4% in phacoemulsification outcomes: Pharmacokinetic-response curve. *Journal of Cataract & Refractive Surgery*. 2006;**32**:1474-1482
- [58] Kim SJ, Flach AJ, Jampol LM. Nonsteroidal anti-inflammatory drugs in ophthalmology. *Survey of Ophthalmology*. 2010;**55**:108-133
- [59] Rodríguez-García A, Hernández-Camarena JC, López-Jaime GR, Nava-García JA. Effect of topical nonsteroidal anti-inflammatory drugs on pupillary size during uncomplicated cataract surgery. *Journal of Refractive Surgery*. 2017;**33**:236-242
- [60] Kim SJ, Schoenberger SD, Thorne JE, Ehlers JP, Yeh S, Bakri SJ. Post-cataract prevention of inflammation and macular edema by steroid and nonsteroidal anti-inflammatory eye drops. *Ophthalmology*. 2014;**121**:1915-1924
- [61] Kim SJ, Schoenberger SD, Thorne JE, Ehlers JP, Yeh S, Bakri SJ. Topical nonsteroidal anti-inflammatory drugs and cataract surgery: A report by the American Academy of Ophthalmology. *Ophthalmology*. 2015;**122**:2159-2168
- [62] Walters T, Raizman M, Ernest P, Gayton J, Lehmann R. In vivo pharmacokinetics and in vitro pharmacodynamics of nepafenac, amfenac, ketorolac, and bromfenac. *Journal of Cataract & Refractive Surgery*. 2007;**33**:1539-1545
- [63] Rodriguez A, Power WJ, Neves RA, Foster CS. Recurrence rate of herpetic uveitis in patients on long-term oral acyclovir. *Documenta Ophthalmologica*. 1995;**90**:331-340
- [64] Barron BA, Gee L, Hauck WW, Kurinij N, Dawson CR, Jones DB, Wilhelmus KR, Kaufman HE, Sugar J, Hyndiuk RA, Laibson PR, Stulting D, Asbel PA. Herpetic eye disease study: A controlled trial of oral acyclovir for herpes simplex stromal keratitis. *Ophthalmology*. 1994;**101**:1871-1882
- [65] Najjar DM, Cohen EJ, Rapuano CJ, Laibson PREDTA. Chelation for calcific band keratopathy: Results and long-term follow-up. *American Journal of Ophthalmology*. 2004;**137**:1056-1064
- [66] Stewart OG, Morrell AJ. Management of band keratopathy with excimer phototherapeutic keratectomy: Visual, refractive, and symptomatic outcome. *Eye (Lond)*. 2003;**17**:233-237
- [67] Bohnsack BL, Freedman SF. Surgical outcomes in childhood uveitic glaucoma. *American Journal of Ophthalmology*. 2013;**155**:134-142
- [68] Carreño E, Villarón S, Portero A, Herreras JM, Maquet JA, Calonge M. Surgical outcomes of uveitic glaucoma. *Journal of Ophthalmic Inflammation and Infection*. 2010;**1**:43-53
- [69] Siddique SS, Suelves AM, Baheti U, Foster CS. Glaucoma and uveitis. *Survey of Ophthalmology*. 2013;**58**:1-10

- [70] Shimizu A, Maruyama K, Yokoyama Y, Tsuda S, Ryu M, Nakazawa T. Characteristics of uveitic glaucoma and evaluation of its surgical treatment. *Clinical Ophthalmology* (Auckland, NZ). 2014;**8**:2383
- [71] Iwao K, Inatani M, Seto T, Takihara Y, Ogata-Iwao M, Okinami S, Tanihara H. Long-term outcomes and prognostic factors for trabeculectomy with mitomycin C in eyes with uveitic glaucoma: A retrospective cohort study. *Journal of Glaucoma*. 2014;**23**:88-94
- [72] Park UC, Ahn JK, Park KH, Phacotrabeulectomy YHG. With mitomycin C in patients with uveitis. *American Journal of Ophthalmology*. 2006;**142**:1005-1012
- [73] Androudi S, Ahmed M, Fiore T, Brazitikos P, Foster CS. Combined pars plana vitrectomy and phacoemulsification to restore visual acuity in patients with chronic uveitis. *Journal of Cataract & Refractive Surgery*. 2005;**31**:472-478
- [74] Soheilian M, Mirdehghan SA, Peyman GA. Sutureless combined 25-gauge vitrectomy, phacoemulsification, and posterior chamber intraocular lens implantation for management of uveitic cataract associated with posterior segment disease. *Retina*. 2008;**28**:941-946
- [75] Pålsson S, Nyström A, Sjödel L, Jakobsson G, Byhr E, Andersson Grönlund M, Zetterberg M. Combined phacoemulsification, primary intraocular lens implantation, and pars plana vitrectomy in children with uveitis. *Ocular Immunology and Inflammation*. 2015; **23**:144-151
- [76] Shinoda K, O'hira A, Ishida S, et al. Posterior synechia of the iris after combined pars plana vitrectomy, phacoemulsification, and intraocular lens implantation. *Japanese Journal of Ophthalmology* 2001;**45**:276-280
- [77] Ahmad ZM, Hughes BA, Abrams GW, Mahmoud TH. Combined posterior chamber intraocular lens, vitrectomy, Retisert, and pars plana tube in noninfectious uveitis. *Archives of Ophthalmology*. 2012;**130**:908-913
- [78] Chee SP, Ti SE, Sivakumar M, Tan D. Postoperative inflammation: Extracapsular cataract extraction versus phacoemulsification. *Journal of Cataract & Refractive Surgery*. 1999; **25**:1280-1285
- [79] Oshika T, Yoshimura K, Miyata N. Postsurgical inflammation after phacoemulsification and extracapsular extraction with soft or conventional intraocular lens implantation. *Journal of Cataract & Refractive Surgery*. 1992;**18**:356-361
- [80] Oetting TA, Omphroy LC. Modified technique using flexible iris retractors in clear corneal surgery. *Journal of Cataract & Refractive Surgery*. 2002;**28**:596-598
- [81] Lam LA, Lowder CY, Baerveldt G, Smith SD, Traboulsi EI. Surgical management of cataracts in children with juvenile rheumatoid arthritis-associated uveitis. *American Journal of Ophthalmology*. 2003;**135**:772-778
- [82] Dana MR, Chatzistefanou K, Schaumberg DA, Foster CS. Posterior capsule opacification after cataract surgery in patients with uveitis. *Ophthalmology*. 1997;**104**:1387-1394

- [83] Rauz S, Stavrou P, Murray PI. Evaluation of foldable intraocular lenses in patients with uveitis. *Ophthalmology*. 2000;**107**:909-919
- [84] Rahman I, Jones NP. Long-term results of cataract extraction with intraocular lens implantation in patients with uveitis. *Eye (Lond)*. 2004;**19**:191-197
- [85] Okhravi N. Assessment of visual outcome after cataract surgery in patients with uveitis. *Ophthalmology*. 1999;**106**:710-722
- [86] Ram J, Gupta A, Kumar S, Kaushik S, Gupta N, Severia S. Phacoemulsification with intraocular lens implantation in patients with uveitis. *Journal of Cataract & Refractive Surgery*. 2010;**36**:1283-1288
- [87] Adán A, Gris O, Pelegrín L, Torras J, Corretger X. Explantation of intraocular lenses in children with juvenile idiopathic arthritis-associated uveitis. *Journal of Cataract & Refractive Surgery*. 2009;**35**:603-605
- [88] Foster CS, Stavrou P, Zafirakis P, Rojas B, Tesavibul N, Baltatzis S. Intraocular lens removal from [corrected] patients with uveitis. *American Journal of Ophthalmology*. 1999;**128**:31-37
- [89] Abela-Formanek C, Amon M, Schild G, Schauersberger J, Kolodjaschna J, Barisani-Asenbaum T, Kruger A. Inflammation after implantation of hydrophilic acrylic, hydrophobic acrylic, or silicone intraocular lenses in eyes with cataract and uveitis: Comparison to a control group. *Journal of Cataract & Refractive Surgery*. 2002;**28**:1153-1159
- [90] Lam DS, Law RW, Wong AK. Phacoemulsification, primary posterior capsulorhexis, and capsular intraocular lens implantation for uveitic cataract. *Journal of Cataract & Refractive Surgery*. 1998;**24**:1111-1118
- [91] Holland GN, Van Horn SD, Margolis TP. Cataract surgery with ciliary sulcus fixation of intraocular lenses in patients with uveitis. *American Journal of Ophthalmology*. 1999;**128**:21-30
- [92] Papaliadis GN, Nguyen QD, Samson CM, Foster CS. Intraocular lens tolerance in surgery for cataracta complicata: Assessment of four implant materials. *Seminars in Ophthalmology*. 2002;**17**:120-123
- [93] Diamond JG, Kaplan HJ. Uveitis: Effect of vitrectomy combined with lensectomy. *Ophthalmology*. 1979;**86**:1320-1327
- [94] Tomlins PJ, Sivaraj RR, Rauz S, Denniston AK, Murray PI. Long-term biocompatibility and visual outcomes of a hydrophilic acrylic intraocular lens in patients with uveitis. *Journal of Cataract & Refractive Surgery*. 2014;**40**:618-625
- [95] Magli A, Forte R, Rombetto L, Alessio M. Cataract management in juvenile idiopathic arthritis: Simultaneous versus secondary intraocular lens implantation. *Ocular Immunology and Inflammation*. 2014;**22**:133-137
- [96] Nemet AY, Raz J, Sachs D, Friling R, Neuman R, Kramer M, Suresh K, Oandi MD, Vidushi S, Assia EI. Primary intraocular lens implantation in pediatric uveitis: A comparison of 2 populations. *Archives of Ophthalmology*. 2007;**125**:354-360

- [97] Ganesh SK, Sudharshan S. Phacoemulsification with intraocular lens implantation in juvenile idiopathic arthritis. *Ophthalmic Surgery, Lasers & Imaging*. 2010;**41**:104-108
- [98] Kotaniemi K, Penttila H. Intraocular lens implantation in patients with juvenile idiopathic arthritis-associated uveitis. *Ophthalmic Research*. 2006;**38**:318-323
- [99] Probst LE, Holland EJ. Intraocular lens implantation in patients with juvenile rheumatoid arthritis. *American Journal of Ophthalmology*. 1996;**122**:161-170
- [100] Lundvall A, Zetterström C. Cataract extraction and intraocular lens implantation in children with uveitis. *The British Journal of Ophthalmology*. 2000;**84**:791-793
- [101] Grajewski RS, Zurek-Imhoff B, Roesel M, Heinz C, Heiligenhaus A. Favourable outcome after cataract surgery with IOL implantation in uveitis associated with juvenile idiopathic arthritis. *Acta Ophthalmologica*. 2011;**90**:657-662
- [102] Okhravi N, Morris A, Kok HS, Menezo V, Dowler JG, Hykin PG, Lightman S. Intraoperative use of intravitreal triamcinolone in uveitic eyes having cataract surgery: Pilot study. *Journal of Cataract & Refractive Surgery*. 2007;**33**:1278-1283
- [103] Dada T, Dhawan M, Garg S, Nair S, Mandal S. Safety and efficacy of intraoperative intravitreal injection of triamcinolone acetonide after phacoemulsification in cases of uveitic cataract. *Journal of Cataract & Refractive Surgery*. 2007;**33**:1613-1618
- [104] van Kooij B, Rothova A, de Vries P. The pros and cons of intravitreal triamcinolone injections for uveitis and inflammatory cystoid macular edema. *Ocular Immunology and Inflammation*. 2006;**14**:73-85
- [105] Larochelle MB, Smith J, Dacey MS. Dexamethasone intravitreal implant in the treatment of uveitic macular edema in the perioperative cataract setting: A case series. *American Journal of Ophthalmology*. 1999;**166**:149-153
- [106] Chieh JJ, Carlson AN, Jaffe GJ. Combined fluocinolone acetonide intraocular delivery system insertion, phacoemulsification, and intraocular lens implantation for severe uveitis. *American Journal of Ophthalmology*. 2008;**146**:589-594
- [107] Arcinue CA, Cerón OM, Foster CSA. Comparison between the fluocinolone acetonide (Retisert) and dexamethasone (Ozurdex) intravitreal implants in uveitis. *Journal of Ocular Pharmacology and Therapeutics*. 2013;**29**:501-507
- [108] Kiddee W, Trope GE, Sheng L, Beltran-Agullo L, Smith M, Strungaru MH, Baath J, Buys YM. Intraocular pressure monitoring post intravitreal steroids: A systematic review. *Survey of Ophthalmology*. 2013;**58**:291-310
- [109] Shah SP, Yarian DL, Prenner J, Friedman ES, Wheatley ES, Fine HF, Mantopoulos D, Roth DB. One-year results of fluocinolone acetonide intravitreal implant for diabetic macular edema in highly treated eyes. Presented at: American Society of Retina Specialists 35th Annual Meeting, Boston, MA. 11-15 August 2017
- [110] Holland GN. Intraocular lens implantation in patients with juvenile rheumatoid arthritis-associated uveitis: An unresolved management issue. *American Journal of Ophthalmology*. 2014;**122**:255-257



- [111] Apple DJ. Influence of intraocular lens material and design on postoperative intracapsular cellular reactivity. *Transactions of the American Ophthalmological Society*. 2000;**98**:257-283
- [112] Mondino BJ, Nagata S, Glovsky MM. Activation of the alternative complement pathway by intraocular lenses. *Investigative Ophthalmology & Visual Science*. 1985;**26**:905-908
- [113] Sievers H, von Domarus D. Foreign-body reaction against intraocular lenses. *American Journal of Ophthalmology*. 1984;**97**:743-751
- [114] Majima K. An evaluation of the biocompatibility of intraocular lenses. *Ophthalmic Surgery, Lasers and Imaging*. 1996;**27**:946-951
- [115] Amon M, Menapace R. In vivo documentation of cellular reactions on lens surfaces for assessing the biocompatibility of different intraocular implants. *Eye (Lond)*. 1994;**8**:649-656
- [116] Mondino BJ, Rajacich GM. Comparison of complement activation by silicone intraocular lenses and polymethyl-methacrylate intraocular lenses with polypropylene loops. *Archives of Ophthalmology*. 1987;**105**:989-990
- [117] Stavrou P, Murray PI. Heparin surface modified intraocular lenses in uveitis. *Ocular Immunology and Inflammation*. 1994;**2**:161-168
- [118] Percival P. Use of heparin-modified lenses in high-risk cases for uveitis. *Developments in Ophthalmology*. 1991;**22**:80-83
- [119] Kang S, Kim MJ, Park SH, Joo CK. Comparison of clinical results between heparin surface modified hydrophilic acrylic and hydrophobic acrylic intraocular lens. *European Journal of Ophthalmology*. 2008;**18**:377-383
- [120] Ravalico G, Baccara F, Lovisato A, Tognetto D. Postoperative cellular reaction on various intraocular lens materials. *Ophthalmology*. 1997;**104**:1084-1091
- [121] Umezawa S, Shimizu K. Biocompatibility of surface-modified intraocular lenses. *Journal of Cataract & Refractive Surgery*. 1993;**19**:371-374
- [122] Kurosaka D, Ando I, Kato K, Oshima T, Kurosaka H, Yoshino M, Nagamoto T, Ando N. Capsule contraction syndrome. *Journal of Cataract & Refractive Surgery*. 1999;**25**:930-935
- [123] Nishi O, Nishi K, Imanishi M, Tada Y, Shirasawa E. Effect of the cytokines on the prostaglandin E2 synthesis by lens epithelial cells of human cataracts. *The British Journal of Ophthalmology*. 1995;**79**:934-938
- [124] Hollick EJ, Spalton DJ, Ursell PG, Meacock WR, Barman SA, Boyce JF. Posterior capsular opacification with hydrogel, polymethylmethacrylate, and silicone intraocular lenses: Two-year results of a randomized prospective trial. *American Journal of Ophthalmology*. 2000;**129**:577-584
- [125] Lüke C, Dietlein TS, Jacobi PC, Konen W, Krieglstein GK. Massive anterior capsule shrinkage after plate-haptic silicone lens implantation in uveitis. *Journal of Cataract & Refractive Surgery*. 2001;**27**:333-336

- [126] Hollick EJ, Spalton DJ, Ursell PG, Pande MV. Biocompatibility of poly (methyl-methacrylate), silicone, and AcrySof intraocular lenses: Randomized comparison of the cellular reaction on the anterior lens surface. *Journal of Cataract & Refractive Surgery*. 1998;**24**:361-366
- [127] Hollick EJ, Spalton DJ, Ursell PG, Pande MV, Barman SA, Boyce JF, Tilling K. The effect of polymethylmethacrylate, silicone, and polyacrylic intraocular lenses on posterior capsular opacification 3 years after cataract surgery. *Ophthalmology*. 1999;**106**:49-55
- [128] Bellucci R. An introduction to intraocular lenses: Material, optics, haptics, design and aberration. In: *Cataract. ESASO Course Series*. Güell JL, editor. Basel, Karger; 2013;**3**:38-55. ISBN: 978-3-318-02410-4 (Print) eISBN: 978-3-318-02411-1 (Online). <https://doi.org/10.1159/000350902>
- [129] Leung TG, Lindsley K, Kuo IC. Types of intraocular lenses for cataract surgery in eyes with uveitis. *Cochrane Database of Systematic Reviews*. 2014;(3):CD007284. DOI:10.1002/14651858.CD007284.pub2
- [130] Alio JL, Chipont E, BenEzra D, Fakhry MA, International Ocular Inflammation Society, Study Group of Uveitic Cataract Surgery. Comparative performance of intraocular lenses in eyes with cataract and uveitis. *Journal of Cataract & Refractive Surgery*. 2002;**28**:2096-2108
- [131] Foster CS, Vitale AT. Cataract surgery in uveitis. *Ophthalmology Clinics of North America*. 1993;**6**:139-146
- [132] Schuster AK, Harder BC, Schlichtenbrede FC, Jarczok MN, Tesarz J. Valacyclovir versus acyclovir for the treatment of herpes zoster ophthalmicus in immunocompetent patients. *Cochrane Database of Systematic Reviews*. 2016;**11**:CD011503
- [133] Krishna R. Long-term follow-up of extracapsular cataract extraction and posterior chamber intraocular lens implantation in patients with uveitis. *Ophthalmology*. 1998; **105**:1765-1769
- [134] Pande MV, Spalton DJ, Kerr-Muir MG, Marshall J. Postoperative inflammatory response to phacoemulsification and extracapsular cataract surgery: Aqueous flare and cells. *Journal of Cataract & Refractive Surgery*. 1996;**22**(Suppl 1):770-774
- [135] Moorthy RS, Rajeev B, Smith RE, Rao NA. Incidence and management of cataracts in Vogt-Koyanagi-Harada syndrome. *American Journal of Ophthalmology*. 2014; **118**:197-204
- [136] Merayo-Llodes J, Power WJ, Rodriguez A, Pedroza-Seres M, Foster CS. Secondary glaucoma in patients with uveitis. *Ophthalmologica*. 1999;**213**:300-304
- [137] Kiryu J, Kita M, Tanabe T, Yamashiro K, Miyamoto N, Ieki Y. Pars plana vitrectomy for cystoid macular edema secondary to sarcoid uveitis. *Ophthalmology*. 2001; **108**:1140-1144
- [138] Liesegang TJ, Bourne WM, Ilstrup DM. Secondary surgical and neodymium-YAG laser discissions. *American Journal of Ophthalmology*. 1985;**100**:510-519

- [139] Steinert RF, Puliafito CA, Kumar SR, Dudak SD, Patel S. Cystoid macular edema, retinal detachment, and glaucoma after Nd:YAG laser posterior capsulotomy. *American Journal of Ophthalmology*. 1991;**112**:373-380
- [140] Ganesh SK, Babu K, Biswas J. Phacoemulsification with intraocular lens implantation in cases of pars planitis. *Journal of Cataract & Refractive Surgery*. 2004;**30**:2072-2076
- [141] Choudhry S, Ghosh S. Intravitreal and posterior subtenon triamcinolone acetate in idiopathic bilateral uveitic macular oedema. *Clinical & Experimental Ophthalmology*. 2007;**35**:713-718
- [142] Maca SM, Abela-Formanek C, Kiss CG, Sacu SG, Benesch T, Barisani-Asenbauer T. Intravitreal triamcinolone for persistent cystoid macular oedema in eyes with quiescent uveitis. *Clinical & Experimental Ophthalmology*. 2009;**37**:389-396
- [143] Young S, Larkin G, Branley M, Lightman S. Safety and efficacy of intravitreal triamcinolone for cystoid macular oedema in uveitis. *Clinical & Experimental Ophthalmology*. 2001;**29**:2-6
- [144] Cunningham Jr ET, de Smet MD, Yeh S, Albini TA, Zierhut M. Sustained-release corticosteroids for uveitis. *Ocular Immunology and Inflammation* 2015;**23**:421-424
- [145] Gilbert C, Hiscott P, Unger W, Grierson I, McLeod D. Inflammation and the formation of epiretinal membranes. *Eye (Lond)*. 1988;**2**(Suppl 6):144-156
- [146] Dev S, Mieler WF, Pulido JS, Mitra RA. Visual outcomes after pars plana vitrectomy for epiretinal membranes associated with pars planitis. *Ophthalmology*. 1999;**106**:1086-1090
- [147] Radetzky S, Walter P, Fauser S, Koizumi K, Kirchhof B, Jousseaume AM. Visual outcome of patients with macular edema after pars plana vitrectomy and indocyanine green-assisted peeling of the internal limiting membrane. *Graefes Archive for Clinical and Experimental Ophthalmology*. 2004;**42**:273-278
- [148] Berker N, Soykan E, Elgin U, Ozkan SS. Phacoemulsification cataract extraction and intraocular lens implantation in patients with Behcet's disease. *Ophthalmic Surgery, Lasers & Imaging Retina*. 2004;**35**:215-218
- [149] Powe NR, Schein OD, Gieser SC. Synthesis of the literature on visual acuity and complications following cataract extraction with intraocular lens implantation. *Archives of Ophthalmology*. 1994;**112**:239-252
- [150] Foster RE, Lowder CY, Meisler DM, Zakov ZN. Extracapsular cataract extraction and posterior chamber intraocular lens implantation in uveitis patients. *Ophthalmology*. 1992;**99**:1234-1241
- [151] Tugal-Tutkun I, Ötük-Yasar B, Altinkurt E. Clinical features and prognosis of herpetic anterior uveitis: A retrospective study of 111 cases. *International Ophthalmology*. 2010;**30**:559-565
- [152] Miserocchi E, Waheed NK, Dios E, Christen W, Merayo J, Roque M, Foster CS. Visual outcome in herpes simplex virus and varicella zoster virus uveitis: A clinical evaluation and comparison. *Ophthalmology*. 2002;**109**:1532-1537

- [153] Marsh RJ, Cooper M. Ocular surgery in ophthalmic zoster. *Eye (Lond)*. 1989;**3**:313-317
- [154] Kaufman AH, Foster CS. Cataract extraction in patients with pars planitis. *Ophthalmology*. 1993;**100**:1210-1217
- [155] Tugal-Tutkun I, Onal S, Altan-Yaycioglu R, Altunbas HH, Urgancioglu M. Uveitis in Behçet disease: An analysis of 880 patients. *Ophthalmology*. 2004;**138**:373-380
- [156] Kadayifçılar S, Gedik Ş, Eldem B, İrkeç M. Cataract surgery in patients with Behçet's disease. *Journal of Cataract & Refractive Surgery*. 2002;**28**:316-320
- [157] Ganesh SK, Babu K, Biswas J. Cataract surgery in patients with Vogt-Koyanagi-Harada syndrome. *Journal of Cataract & Refractive Surgery*. 2004;**30**:95-100
- [158] Ganesh SK, Sundaram PM, Biswas J, Babu K. Cataract surgery in sympathetic ophthalmia. *Journal of Cataract & Refractive Surgery*. 2004;**30**:2371-2376
- [159] Akova YA, Foster CS. Cataract surgery in patients with sarcoidosis-associated uveitis. *Ophthalmology*. 1994;**101**:473-479