ORIGINAL RESEARCH

Relationship between the size of patency file and apical extrusion of sodium hypochlorite

Izabel CG Camões, Milton R Salles[1], Mourão Vieira M Fernando[2], Lílian F Freitas, Cinthya C Gomes[3]

Department of Clinical Dentistry, Center of Medical Sciences, Fluminense Federal University, Niterói, RJ, [1]Department of Inorganic Chemistry, Federal University of Rio de Janeiro, Rio de Janeiro, RJ, [2]Private Endodontic Practice, [3]Specialization Course in Endodontics, Fluminense Federal University, Niterói, RJ, Brazil

Received : 21-08-08
Review completed : 29-01-09
Accepted : 25-02-09
PubMed ID : ***
DOI: 10.4103/0970-9290.59443

ABSTRACT

Background: Sodium hypochlorite (NaOCl) is the most widely used endodontic irrigant because of its excellent antimicrobial, organic tissue dissolving, and lubricating properties. However, it is highly cytotoxic to the periapical tissues.

Aim: This study evaluated *in vitro* the extrusion of 5.25% NaOCl through the apical foramina of mesiobuccal (MB) root canals of maxillary first molars in two experimental conditions: Before apical debridement and after apical debridement with different instrument sizes to ensure direct access to the apical foramen (apical patency).

Materials and Methods: Coronal accesses were prepared in 17 teeth and the apical foramina of the distobuccal and palatal root canals were sealed. The teeth were held in acrylic receptacles with the roots turned upwards to reproduce their position in the maxillary dental arch. The receptacles were filled with a starch/KI solution (a reagent that changes its color to blue after contacting NaOCl) covering the roots. The experiment had two phases: P1: Irrigation of the MB canals with 5.25% NaOCl without previous establishment of apical patency; P2: Canal irrigation after use of size 10 K-file and size 15 Flexofile as patency files. Only specimens with no NaOCl extrusion in P1 were assigned to P2. NaOCl was delivered pressureless at the canal entrance. The moment that the starch/KI solution contacted NaOCl was captured on digital photographs.

Results and Conclusions: There was no NaOCl extrusion in nine specimens in P1, but all of these teeth had irrigant extrusion in P2. The 5.25% NaOCl used as an endodontic irrigant showed great capacity to extrude beyond both intact and small-sized apical foramina of MB root canals of maxillary first molars.

Key words: Apical extrusion, patency file, periapical tissues, sodium hypochlorite

The endodontic treatment is based on the complete removal of an irreversibly inflamed pulp tissue, cleaning, shaping, and three-dimensional obturation of the root canal system in order to preserve the tooth in the dental arch associated to a healthy periodontium as a single functional unit.[1,2]

The presence of microorganisms and their by-products and toxins in the root canals is the main cause of injury to the pulp and periradicular tissues and persistence of pulpal and periapical pathologies. The goal of root canal therapy is therefore to eliminate the bacteria from the complex root canal system anatomy and seal the canal space to prevent bacterial reentry. The use of endodontic irrigants with antimicrobial properties during endodontics is essential for the elimination of pathogens. In addition, the flushing action produced by endodontic irrigation provides lubrication of the canal dentinal walls, dissolution, and removal of pulp tissue remnants, odontoblastic processes, blood cell fragments, and contaminated inorganic debris that are produced during instrumentation and compacted into the dentinal tubules. This is an essential approach to avoid canal reinfection.

Sodium hypochlorite (NaOCl) is one of the most widely used endodontic irrigants for the chemomechanical preparation of root canals because of its excellent antimicrobial action and capacity of dissolving organic materials.[3-6] However, its optimal organic tissue-dissolving property is nonselective. This means that NaOCl may dissolve both vital and necrotic pulp remnants indistinguishably, as well as periapical tissues, if allowed entering the periradicular space due to inadvertent extrusion from the root canal system, possibly causing severe inflammatory response and tissue necrosis. It has been reported that an accidental contact of anything but small amounts of NaOCl with the periradicular tissues leads to the development of ulcerative and tissue necrosis processes.[7-9] It has also been shown that physiologic conditions, such as immature teeth, and physiopathological conditions, namely external/internal root resorption, root communicating with the maxillary sinus or covered by thin membranes, facilitate irrigant extrusion to the periapical space and/or maxillary sinus.[7,10,11]

Address for correspondence:
Prof. Dr. Izabel Coelho Gomes Camões,
E-mail: icamoes@netbotanic.com.br

In view of this, several studies[7,11,12] have addressed the adverse effects of NaOCl used as an irrigant during chemomechanical preparation of root canals, especially in maxillary teeth, because of their close relation with the maxillary sinuses. Nevertheless, none of these studies have determined the size of the patency file from which on the solution may extrude to the periapical tissues. Therefore, the purpose of this study was to evaluate *in vitro* the extrusion of 5.25% NaOCl irrigant through the apical foramina of mesiobuccal (MB) root canals of maxillary first molars in two experimental conditions: Before apical debridement and after establishment of apical patency with files of different sizes.

MATERIALS AND METHODS

Seventeen human maxillary first molars obtained from the tooth bank of the Fluminense Federal University were cleaned of organic tissue remnants and calculus and stored in 0.5% thymol solution (Botânica, Niterói, RJ, Brazil) until use. The teeth were chosen based on their similar dimensional morphology and were examined under × 40 magnification to confirm that the root apexes were fully formed. Radiographs were taken to confirm the absence of canal obliterations.

Conventional coronal accesses were prepared with a size 4 spherical diamond bur and an Endo Z bur (Dentsply, Maillefer, Tulsa, OK, USA) at high-speed air turbine (WandH Trend TC-95 BC; WandH Dentalwerk Bürmoos GmbH, Austria).

Seventeen transparent acrylic receptacles (Maíz, BA, Brazil) were obtained and perforated using a heated #2 suprafill spatula (Duflex/SS White, Rio de Janeiro, RJ, Brazil) to make a circle with diameter close to that of the molar crown. The apical foramina of the distobuccal and palatal root canals of all teeth were sealed with epoxy resin (Durepoxi; Alba Adesivos, Ind. Com., São Paulo, SP, Brazil). Next, each tooth was individually attached to the acrylic receptacles with epoxy resin and epoxy adhesive (Araldite; Ciba Geigy S.A., São Paulo, SP, Brazil) in such a way that the roots were positioned inside the acrylic receptacles and the crowns remained outside. Figure 1 illustrates the custom-made apparatus.

Each tooth/acrylic receptacle apparatus was fixed on a small clamp (Myford Ltd., Nottingham, UK) with its open end (containing the roots) turned upwards and the molar crown turned downwards in order to simulate the tooth's position in the maxillary dental arch. This apparatus was designed to allow filling of the receptacle with a specific reagent for NaOCl (starch/KI solution, supplied by the Inorganic Chemistry Institute of the Federal University of Rio de Janeiro, Brazil) without leakage. The starch/KI solution used in this study was prepared by dissolving 0.5 g of KI in 100 ml of a recently prepared starch solution. The starch/KI solution releases iodine when excess oxidant is added and changes its color to blue. It should be used within 24 h after preparation and should be stored in a dark lightproof flask. The starch/KI solution was delivered at the open end of the tooth/acrylic receptacle apparatus and the roots remained completely submerged in the solution [Figure 2].

The experiment was divided into two phases: Phase 1–irrigation of the MB canals with 5.25% NaOCl solution without previous establishment of apical patency; phase 2-irrigation of the MB canals after use of a size 10 K-file and a size 15 Flexofile (Kerr, Orange, CA, USA) as patency files. Only specimens without NaOCl extrusion in phase 1 were assigned to phase 2. The size 15 file was used only if no NaOCl extrusion occurred with the size 10 file. Each file was introduced passively into the canal until its tip was visible at the apical foramen [Figure 3]. NaOCl was delivered with a 25 × 0.7 22 G metallic needle (BD Plastipak, Argentina) attached to a 5-ml disposable syringe (Injex, São Paulo, SP Brazil). The needle was loosely placed at the MB canal entrance and the irrigant was injected pressureless. A total of 3 ml was used per tooth. Extrusion of NaOCI through the apical foramina was indicated by reaction between NaOCI and starch/KI solution that is shown as a colour change to blue. Figures 4 and 5 illustrate the color change reaction in teeth without apical debridement and with use of a patency file, respectively.

The moment at which the starch/KI solution reacted with NaOCl changing its color was captured by a digital camera (Fuji S7000 Finepix; Tokyo, Japan) mounted on a tripod and the digital photographs were stored in a computer for further analysis of the results.

RESULTS

As the goal of this study was to assess the extrusion of NaOCl irrigating solution to the periapical tissues through the apical foramina of MB root canals either explored or not with patency files of different sizes, a model of probability was chosen for analysis of the results.

The probability of NaOCl to pass beyond the apical foramen as a function of its diameter was calculated by dividing the number of specimens with extrusion by the total number of specimens. Table 1 shows the results of the 17 specimens. The probabilities of extrusion of NaOCl under the experimental conditions were as follows: Irrigation without previous establishment of apical patency = 8/17 (47.06%); irrigation after use of a size 10 K-file as a patency file = 7/9 (77.78%); irrigation after use of a size 15 Flexofile as a patency file = 2/2 (100%).

DISCUSSION

Sodium hypochlorite has been systematically used as an endodontic irrigant since the 1970s at concentrations ranging from 0.5 to 5.25%. NaOCl not only dissolves organic tissue remnants but also has antibacterial activity and provides lubrication of intracanal walls for instrumentation.[3,11,13-18]

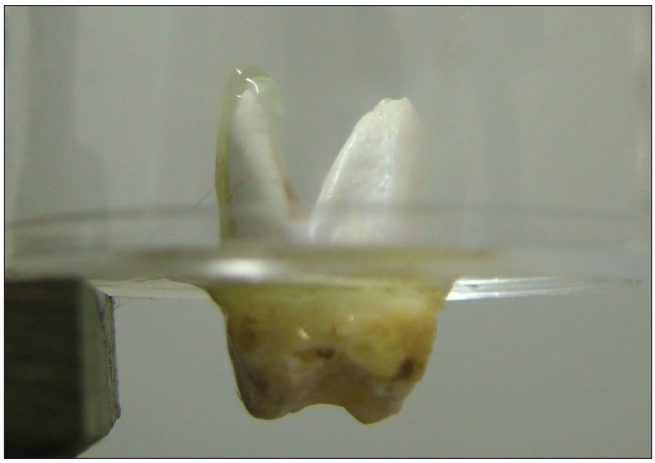

Figure 1: Custom-made apparatus used in the experiment. Tooth fixed in a transparent acrylic receptacle with the crown positioned downwards and the roots positioned upwards inside the receptacle

Table 1: Results from the 17 specimens

S. No.	Before instrumentation	After instrumentation with 10 K-file	After instrumentation with 15 flexofile
1	Extrusion		
2	No extrusion	Extrusion	
3	Extrusion		
4	No extrusion	No extrusion	Extrusion
5	Extrusion		
6	No extrusion	No extrusion	Extrusion
7	Extrusion		
8	No extrusion	Extrusion	
9	Extrusion		
10	No extrusion	Extrusion	
11	Extrusion		
12	No extrusion	Extrusion	
13	Extrusion		
14	No extrusion	Extrusion	
15	No extrusion	Extrusion	
16	No extrusion	Extrusion	
17	Extrusion		

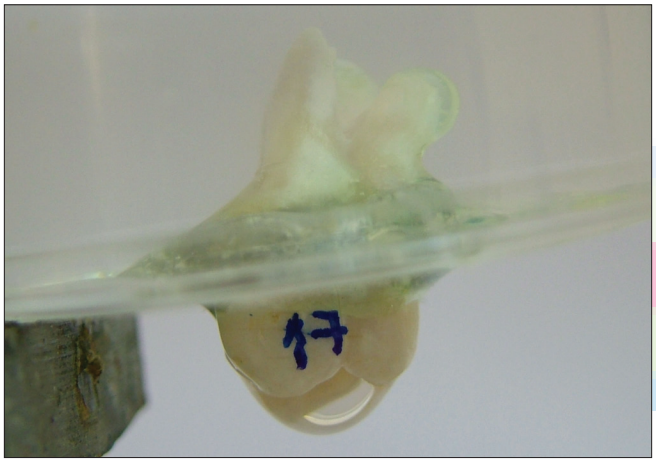

Figure 2: Custom-made apparatus filled with the NaOCl-specific reagent (starch/KI solution) in which the roots were completely immersed

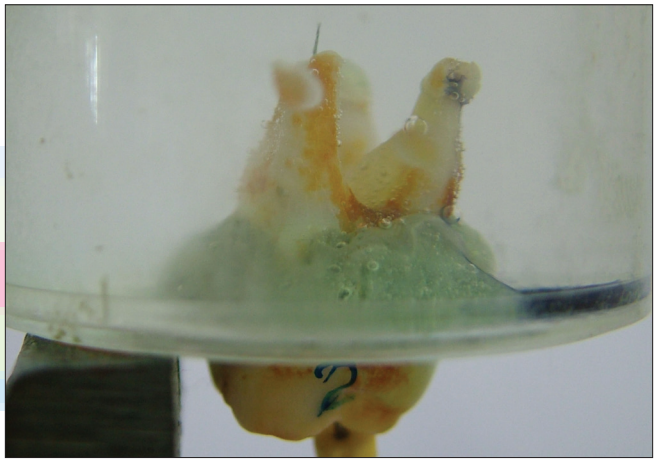

Figure 3: Mesiobuccal root canal exploration and establishment of apical patency with a size 10 K-file

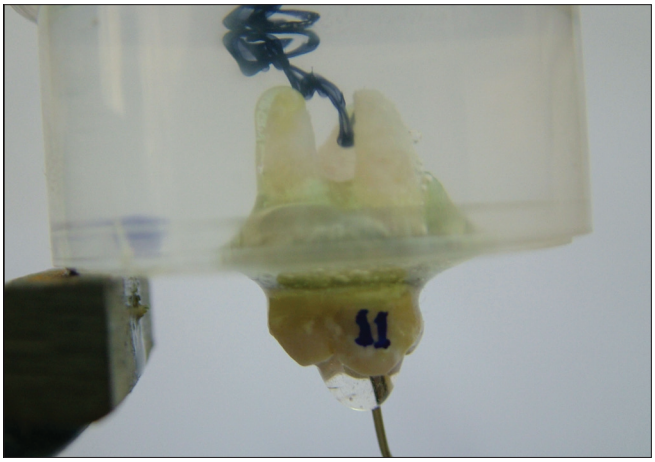

Figure 4: Change of color of the starch/KI solution after direct contact with the NaOCl solution extruded through the apical foramen of the MB root canal, with no canal exploration or use of patency file

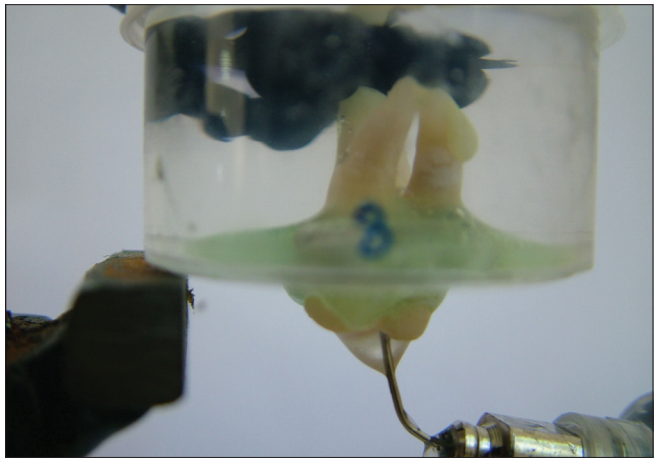

Figure 5: Starch/KI solution showing color change after direct contact with the NaOCl extruded through the apical foramen of the MB root canal after canal exploration and establishment of apical patency with a size 10 K-file

Nevertheless, NaOCl is highly cytotoxic to the periapical tissues and might cause severe adverse effects in case of inadvertent injection beyond the apical foramen. Tissue response depends on the host, concentration of the solution, and extruded amount.[7,8,11,12,19-22] Some *in vitro* studies[12,23,24] have demonstrated that NaOCl solution may leach out of the apical foramen into the periradicular space. The findings of these studies are consistent with the outcomes of a series of case reports relative to the apical extrusion of NaOCl.[7,11,19,22,25]

Correlation between apical extrusion of NaOCl and a series of variables has already been established, including the depth to which the irrigation needle is introduced into the canal,[7,10,23,26] instrumentation technique,[21] and establishment of apical patency.[24] Some authors[27-29] believe that the use of very thin irrigation needles is necessary because in this way the irrigating solution is flushed only coronally to the extent of penetration into the root canal. However, the present study focused on investigating whether the irrigation with NaOCl solution delivered at the entrance of MB canals of maxillary first molars would be sufficient to cause irrigant extrusion to the periapical tissues. The MB canals of maxillary first molars were selected because they are atresic, which poses more difficulty to injection beyond the root apex. In addition, due to their position in the maxillary dental arch, injection of the irrigant into these canals does not have the aid of the gravity force.

Although some authors[14,30] have reported that the irrigating solution cannot reach 3 mm beyond the needle tip when the root canal preparation is smaller than size 30 file, the results of the present study showed that apical debridement is not always necessary for the irrigant to reach the periapical tissues, since NaOCl extrusion occurred in 8 out of 17 specimens without previous establishment of apical patency. It was also observed that, in all specimens examined in the present study, the insertion of a size 15 file into the canals for apical debridement, i.e., to ensure direct access to the apical foramen, was sufficient for the occurrence of irrigant extrusion to the periapical region even with the needle placed loosely at MB canal entrance and the irrigant injected pressureless. These outcomes differ from those of previous authors,[14,30] who affirmed that the irrigation solution can only reach until or beyond the apex when root canal preparation is performed with instruments greater than size 30.

As far as it could be ascertained, there are no articles investigating the relationship between the extrusion of NaOCl endodontic irrigants and the patency file size.

Although *in vivo* studies on the extrusion of endodontic irrigants cannot be performed due to ethical and deontological reasons, several authors[12,23,24] have tried to reproduce *in vitro* the physiologic conditions as close as possible to those found in the oral environment. It was thus of interest to conduct an *in vitro* study that would investigate this relationship and somehow contribute to improve the clinical endodontic procedures and hence the short-, medium-, and long-term success of the treatment.

The custom-made apparatus developed for this *in vitro* study with MB root canals of maxillary first molars simulated, under laboratorial conditions, the position of the teeth in the dental arch. In teeth with pulp necrosis, the root canal content is in advanced stage of decomposition and the canal space is practically empty, which provides similar conditions to those found in the present study. However, the findings of the present study cannot be extrapolated to the clinical situation because the pressure exerted by the intercellular fluid and the periapical tissues may provide some resistance to NaOCl extrusion and thus limit its direct contact with the periradicular tissues and structures.

In this study, NaOCl extrusion through the apical foramina was determined with the use of a NaOCl-specific reagent (starch/KI solution), which, in contact with NaOCl, changes its color to blue due to iodine release. The reaction between the starch/KI solution and NaOCl revealed irrigant extrusion even when the apical foramina were intact or very narrow, which contributed decisively for the reached conclusions.

The outcomes of the present study surpassed our initial expectations because, in some specimens, NaOCl extruded beyond the apical foramina even without apical debridement (no use of patency files) and injection of the irrigant without pressure at the root canal entrance. This demonstrates how easily endodontic irrigants might reach the apical canal third and even get in contact with the periradicular tissues.

Under the tested *in vitro* conditions, 5.25% NaOCl used as an endodontic irrigant showed a great capacity to extrude beyond intact and small-sized apical foramina of MB root canals of maxillary first molars, as apical extrusion occurred with and without previous use of patency files of different sizes.

REFERENCES

1. Schilder H. Cleaning and shaping the root canal. Dent Clin North Am 1974;18:269-96.
2. Contreras MA, Zinman EH, Kaplan SK. Comparison of the first file that fits at the apex, before and after early flaring. J Endod 2001;27:113-6.
3. Kuruvilla J, Kamath P. Antimicrobial activity of 2.5% sodium hypochlorite and 0.2% chlorhexidine gluconate separately and combined as endodontic irrigants. J Endod 1998;24:472-6.
4. Cohen S, Burns RC. Pathways of the pulp. 8th ed. Mosby; 2002. p. 68-9.
5. Abbot PV, Heijkoop PS, Cardaci SC, Hume WR, Heithersay GS. An SEM study of the effects of different irrigations sequences and ultrasonics. Int Endod J 1991;24:308-16.
6. Ciucchi B, Khettabi M, Holz J. The effectiveness of different endodontic irrigation procedures on the removal of smear layer: A scanning electron microscopic study. Int Endod J 1989;22:21-8.
7. Hulsmann M, Hahn W. Complications during root canal irrigation-literature review and case reports. Int Endod J 2000;33:186-93.
8. Gallas-Torreira MM, Reboiras-López MD, García-García A, Gándara-Rey J. Mandibular nerve paresthesia caused by endodontic treatment. Med Oral 2003;8:299-303.

9. Witton R, Brennan PA. Severe tissue damage and neurological deficit following extravasation of sodium hypochlorite solution during routine endodontic treatment. Br Dent J 2005;198:749-50.
10. Juárez RP, Lucas ON. Complicaciones ocasionadas por la infiltrácion accidental con una solución de hipoclorito de sodio. Rev ADM 2001; LVIII(5) : 173-176.
11. Ehrich DG, Brian JD Jr, Walker WA. Sodium hypochlorite accident: Inadvertent injection into the maxillary sinus. J Endod 1993;19:180-2.
12. Ferraz CCR, Gomes NV, Gomes BP, Zaia AA, Teixeira FB, Souza-Filho FJ. Apical extrusion of debris and irrigants using two hand and three engine-driven instrumentation techniques. Int Endod J 2001;34:354-8.
13. Gambarini G, De Luca M, Gerosa R. Chemical stability of heated sodium hypochlorite endodontic irrigants. J Endod 1998;24:432-4.
14. Lopes H, Siqueira Jr. F. Endodontics: biology and technique. Medsi: Rio de Janeiro; 1999.
15. Bairan EJ, Caldera MM. Una visión actualizada del uso del hipoclorito de sódio en endodoncia (2000). Available from: http:// www.carlosboveda.com/Odontologosfolder/odontoinvitadoold/odontoinvitado_18.htm (last access on 2008 Jul 28).
16. Spanó JC, Santos T, Barbin EL, Guimarães LT, Pécora JD. Solvent action of sodium hypochlorite on bovine pulp and physicochemical properties of resulting liquid. Braz Dent J 2001;12:154-7.
17. Weber CD, McClanahan SB, Miller GA, Diener-West M, Johnson JD. The effect of passive ultrasonic activation of 2% chlorhexidine or 5.25% sodium hypochlorite irrigant on residual antimicrobial activity in root canals. J Endod 2003;29:562-4.
18. Okino LA, Siqueira EL, Santos M, Bombana AC, Figueiredo JA. Dissolution of pulp tissue by aqueous solution of chlorhexidine digluconate and chlorhexidine digluconate gel. Int Endod J 2004;37:38-41.
19. Gatot A, Arbelle J, Liebermen A, Yamai-Inbar I. Effects of sodium hypochlorite on soft tissues after its inadvertent injection beyond the root apex. J Endod 1991;17:573-4.
20. Tanomaru Filho M, Leonardo MR, Silva LA, Aníbal FF, Faccioli LH. Inflammatory response to different irrigating solutions. Int Endod J 2002;35:735-9.
21. Usman N, Baumgartner JC, Marshall JG. Influence of instrument size on root canal debridement. J Endod 2004;30:110-2.
22. Serper A, Ozbek M, Çalt S. Accidental sodium hypochlorite-induced skin injury during endodontic treatment. J Endod 2004;30:180-1.
23. Brown DC, Moore BK, Brown CE Jr, Newton CW. An *in vitro* study of apical extrusion of sodium hypochlorite during endodontic canal preparation. J Endod 1995;21:587-91.
24. Lambrianidis T, Tosoumidou E, Tzoanopoulou M. The effect of maintaining apical patency on periapical extrusion. J Endod 2001;27:696-8.
25. Gernhardt CR, Eppendorf K, Kozlowski A, Brandt M. Toxicity of concentrated hypochlorite used as an endodontic irrigant. Int Endod J 2004;37:272-80.
26. Ektefaie MR, David HT, Poh CF. Surgical resolution of chronic tissue irritation caused by extruded endodontic filling material. J Can Dent Assoc 2005,71:487-90.
27. Brown JI, Doran JE. An *in vitro* evaluation of the particle flotation capability of various irrigating solutions. J Calif Dent Assoc 1975;3:60-3.
28. Abou-Rass M, Piccinino MV. The effectiveness of four clinical irrigation methods on the removal of tooth canal debris. Oral Surg Oral Med Oral Pathol 1982;54:323-4.
29. Walton ER, Rivera EM, Torabinejad M. Principles and practice of endodontics. Philadelphia: W.B. Saunders Company; 1997.
30. Berbert A. Practical Endodontics. São Paulo: Savier; 1980.

How to cite this article: Camões ICG, Salles MR, Fernando MVM,Freitas LF, Gomes CC. Relationship between the size of patency file and apical extrusion of sodium hypochlorite. Indian J Dent Res 2009;20:426-30.

Source of Support: Nil, **Conflict of Interest:** None declared.