

High prevalence of muscular sarcocystosis in cattle and water buffaloes from Selangor, Malaysia

Latif, B.¹, Vellayan, S.¹, Heo, C.C.¹, Kannan Kutty, M.¹, Omar, E.¹, Abdullah, S.¹ and Tappe, D.²

¹Faculty of Medicine, Universiti Teknologi MARA, Sungai Buloh, Malaysia

²Institute of Hygiene and Microbiology, University of Würzburg, Würzburg, Germany

*Corresponding author email: bahalatif@yahoo.com

Received 19 July 2013; received in revised form 13 August 2013; accepted 24 August 2013

Abstract. The prevalence of sarcocystosis in cattle and water buffaloes from peninsular Malaysia was investigated in abattoirs in Selangor state, February, 2011, to March, 2012. Fresh muscle samples were collected from the tongue, heart, oesophagus, diaphragm and skeletal muscles of 102 cattle and 18 water buffaloes. Each sample was initially screened by light microscopy and then fixed for further histopathological analysis. Out of 120 animals examined, 49 (40.8%) harboured the microscopic type of *Sarcocystis* spp. The positivity rate for cattle was 36.2% and for water buffaloes 66.7%. In cattle, the organs highly infected were the skeletal muscles and diaphragm (27% each), followed by tongue and esophagus (24.3% each), and the heart (8%). In water buffaloes, the heart was most often infected (66.7%), followed by the oesophagus (50%) and skeletal muscle (33.3%); no sarcocysts were detected in the tongue and diaphragm. The shape of the sarcocyst was fusiform to oval with a mean cyst size of 151.66 x 75.83 µm and wall thickness of 2.47 µm in cattle, and 114 x 50.81 µm cyst size and the wall thickness of 1.11 µm in water buffaloes, consistent with *Sarcocystis cruzi* and *Sarcocystis levinei*, respectively. Remaining tissue from cattle was subjected to parasite-specific 18S rRNA gene PCR and *Sarcocystis cruzi* was confirmed, at least exemplarily. The peripheral merozoites and the banana-shaped bradyzoites (15.23 x 2.2 µm in cattle and 11.49 x 2.45 µm in water buffalo hosts) were easily recognized. In conclusion, a high positivity rate was found in Malaysian meat-producing animals with possible implications for meat consumption and human health.

INTRODUCTION

Sarcocystosis is a zoonotic disease caused by coccidian protozoa of the genus *Sarcocystis*. The parasites are found in tissue cysts of mammals, birds and reptiles, and have a two-host life-cycle (Dubey *et al.*, 1989). The definitive host is usually a predator and the intermediate host its respective prey. In the gut of the definitive host, the parasite undergoes gamogony and is passed with the faeces into the environment as sporocysts containing the infective sporozoites. After ingestion by the intermediate host, schizogony takes place in vascular endothelial cells, and several generations of merozoites are released. These stages eventually invade muscle cells and form the

typical tissue sarcocysts. *Sarcocystis* spp. are considered one of the most prevalent parasites of livestock and can cause clinical disease in these animals, including anorexia, anemia, loss of weight, muscle weakness, lymphadenopathy, abortion, and eventually death in severe infections (Fayer, 2004). Tissue sarcocysts occur either as microscopically or as macroscopically visible structures in animal intermediate hosts (Dubey *et al.*, 1989). Three *Sarcocystis* sp. are known to infect cattle as intermediate hosts, namely *Sarcocystis cruzi*, *Sarcocystis hirsuta*, and *Sarcocystis hominis*, whereas the two species which use water buffaloes are *Sarcocystis fusiformis* and *Sarcocystis levinei* (Dubey, 1976; Dubey & Lindsay, 2006). *Sarcocystis cruzi* and *S. levinei*,

which utilize canids as final host and which are dispersed into the environment by faecal matter, are more frequently found and regarded as more pathogenic than *S. hirsuta* and *S. fusiformis*, which are shed by feline feces (Dubey *et al.*, 1989; Fayer, 2004). Humans can become definitive host for two *Sarcocystis* species: *Sarcocystis hominis*, whose intermediate host is cattle, and *Sarcocystis sui hominis*, whose intermediate hosts are domesticated pigs and wild boars. Consumption of undercooked or raw meat infected with the sarcocysts leads to intestinal sarcocystosis in humans with diarrhoea, nausea, and other gastrointestinal symptoms.

In Malaysia, sarcocystosis was reported in various wild animals, such as the slow loris, *Nycticebus coucang* (Zaman, 1970), the Malaysian long-tailed macaque, *Macaca fascicularis* (Prathap, 1973), several rodents (Ambu *et al.*, 2011), including the domestic rat, *Rattus norvegicus* (Zaman & Colley, 1975), the moon rat, *Echinosorex gymnurus* (Dissanaike & Poopalachelvam, 1975; Kan & Dissanaike, 1976), the house rat, *Rattus rattus diardii* (Kan & Dissanaike, 1977), various field rats, *Rattus annandalei*, *Rattus exulans* and *Rattus jalorensis* (Lai, 1977), the bandicoot, *Bandicota indica* (Kan, 1979), as well as in captive wild and zoo animals (Latif *et al.*, 2010). In livestock, *Sarcocystis* infection was reported in cattle, water buffaloes and sheep (Dissanaike *et al.*, 1977; Dissanaike & Kan, 1978; Kan & Dissanaike, 1978; Norlida *et al.*, 2012). All these previous reports from Malaysia were incidental findings in tissue samples during necropsy, and no systematic prevalence studies have been performed in meat-producing animals in the country so far. Already in 1991, sarcocystosis was seen as a potential emerging food-borne zoonosis in Malaysia because of high human seroprevalence and results from human autopsy cases (Kan & Pathmanathan, 1991). In the two recent years, about 100 international travellers visiting a Malaysian island contracted invasive muscular sarcocystosis by a yet to be identified *Sarcocystis* species from an unknown animal host (Esposito *et al.*, 2012; Tappe *et al.*, 2013). The present study aims to investigate the prevalence of sarcocystosis

among cattle and water buffaloes in peninsular Malaysia, and to determine the organs most often infected. Moreover, the role of the infected livestock in zoonotic infection and the risk for human health is discussed.

MATERIALS AND METHODS

Sample collection

One hundred and two muscle tissues samples consisting of tongue, heart, oesophagus, skeletal muscles and diaphragm were collected from Droughtmaster and Brahman breeds of cattle and 18 local Indian water buffaloes (*Bubalus bubalus*) slaughtered in the Shah Alam-Selangor abattoir, Selangor state, close to the capital Kuala Lumpur, peninsular Malaysia. The study was conducted from February, 2011 to March, 2012. All animals were adult males, aged > 5 years. Each sample weighted approximately 20 mg and was transferred by self-sealed plastic bags to the parasitology laboratory at the Faculty of Medicine, Universiti Teknologi MARA. The samples were stored at 4°C until further study.

Microscopic and molecular examinations

Three tissue pieces, about 2-3 mm³ from each organ, were squeezed firmly between two glass slides (Latif *et al.*, 1999) and examined by light microscopy at a magnification of x100. Positive samples were fixed in 10% buffered neutral formalin and then embedded in paraffin. Tissue blocks were sectioned with 3-5 µm slice thickness and stained with haematoxylin and eosin. The slides were visually screened for sarcocysts by experienced staff, and the results were recorded accordingly. Polymerase chain reaction (PCR) on parasite 18S rRNA gene was performed on native remaining tissue from cattle (n=7) that was microscopically positive for *Sarcocystis*. In brief, primers SAD2F (5'-GGAAGCGATTGGAACC-3') and SAD2R (5'-CCTTGGTCCGTGTTTCA-3'; Wünschmann *et al.*, 2011) were used in a 50 µl reaction volume with 200 pM of each primer, 25 µl of 2X Phusion Flash PCR Master Mix (Thermo Scientific, USA), and 2 µl DNA template. PCR was carried out with an initial

denaturation step at 94°C for 2 minutes, followed by 40 cycles of 30 seconds at 95°C, 30 seconds annealing at 55°C, and 1 minute extension at 72°C, with a 10 minutes final extension at 72°C. Gel electrophoresis was performed for visualisation of the PCR products. Amplicons were then sequenced and compared with database entries by BLAST analysis (www.ncbi.nlm.nih.gov/blast).

RESULTS

Out of 120 animals examined, 49 (40.8%) showed the microscopic type of the *Sarcocystis* spp. tissue cyst. The positivity rate was 36.2 % (37 cases) in the two cattle breeds combined and 66.7% (12 cases) in water buffaloes. Regarding the breed of cattle, 24 Droughtmaster (36.3%) and 13 Brahman (36.1%) were positive for sarcocystosis (Table 1). The infection rate of organs for the two cattle breeds combined was 27% each in skeletal muscle and diaphragm, followed by tongue and oesophagus (24.3% each), and the heart (8%). In water buffaloes, the infection rate was 66.7% in the heart, followed by the oesophagus (50%), and skeletal muscle (33.3%). However, there was no infection detected in the tongue and diaphragm (Table 1, Figure 1).

The microcyst was fusiform to oval in shape, and the mean size of the cyst in cattle was 151.66 x 75.83 µm, with a wall thickness of 2.47 µm. PCR studies of parasite 18S rRNA

genes in all 7 selected microscopically positive tissue samples from cattle identified *S. cruzi* as causative agent after sequencing (93–97% homology). In water buffaloes, the sarcocyst measured 114 x 50.81 µm, with a wall-thickness of 1.11 µm. Two stages were recognized in the sarcocysts, the peripheral merozoites and the banana-shaped bradyzoites, which measured 15.23 x 2.2 µm in cattle and 11.49 x 2.45 µm in water buffaloes, respectively.

DISCUSSION

Sarcocystosis among livestock, such as cattle and water buffaloes investigated here, is of human health importance. Our study revealed that a high proportion of meat-producing cattle and water buffaloes in peninsular Malaysia are infected with *Sarcocystis*, likely *S. cruzi* in cattle and *S. levinei* in water buffaloes. In Malaysia, the occurrence of two species of *Sarcocystis* in cattle, *S. hirsuta* and *S. cruzi*, and two species in water buffaloes, *S. fusiformis* and *S. levinei*, was reported several decades ago (Dissanaike & Kan, 1978). It was shown by light microscopy in a study from Brazil that the cyst of *Sarcocystis cruzi* has a thin wall (< 1 µm) and a size of 240 x 73 µm (Hilda *et al.*, 2001). However, in our study, the wall was thicker (2.47 µm), but the cysts had a roughly comparable size (151.66 x 75.83 µm), and PCR from remaining tissue revealed *S. cruzi* as the causative agent, at least exemplarily in some cases. *Sarcocystis cruzi* can be

Table 1. Distribution of *Sarcocystis* spp. cysts among cattle and buffaloes

Breed	Number Examined	Number Positive (%)	Tongue	Heart	Oesophagus	Skeletal Muscle	Diaphragm
DM cattle ^a	66	24 (36.3)	6 (25)	3 (12.5)	6 (25)	3 (12.5)	8 (33.4)
BR cattle ^a	36	13 (36.1)	3 (23)	Neg.	3 (23)	7 (53.8)	2 (15.3)
LI buffalo ^b	18	12 (66.7)	Neg.	8 (66.7)	6 (50)	4 (33.3)	Neg.
Total	120	49 (40.8)	9 (7.5)	11 (9.2)	15 (12.5)	14 (11.7)	10 (8.3)

DM, Droughtmaster Breed; BR, Brahman Breed; LI, Local Indian Water Buffalo Breed; Neg., Negative
^aTwo animals each had multiple sites of infection; ^bSix animals had multiple sites of infection

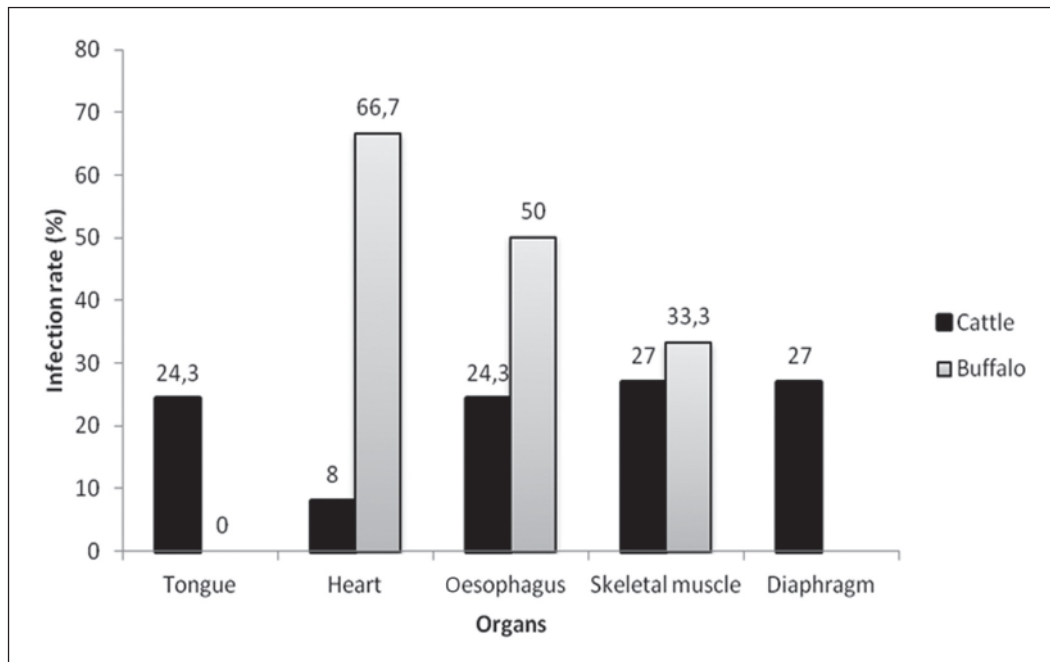


Figure 1. Distribution of *Sarcocystis* spp. tissue cysts among cattle and buffaloes according to organ infected

differentiated morphologically from the two thick-walled cattle *Sarcocystis* sp., *S. hominis* (wall thickness of 5.9 μm , cyst size of 787 x 112 μm) and *S. hirsuta* (wall thickness 4.7 μm , cyst size of 1,900 x 160 μm). The size of the bradyzoites found in cattle sarcocysts in our study (15.23 x 2.2 μm) was also comparable with those of *S. cruzi* (11–14 x 2.5–3.5 μm) (Dubey, 1976), and thus, in total, *S. cruzi* is most probable. In water buffaloes, the sarcocysts were smaller, and the reported cyst size of *S. levinei* in buffaloes is 900 x 100 μm with bradyzoites measuring 17.8 x 4.2 μm (Dissanaike & Kan, 1978). Based on microscopic measurements, however, it is not possible to determine the exact species of *Sarcocystis* responsible for infection. Structure, size, and shape of the parasitic tissue cyst depend on maturation of the cysts, type of the host cell, and intermediate host species (Prakas *et al.*, 2013). Further ultrastructural and systematic PCR studies are therefore in progress to molecularly identify the species of *Sarcocystis* that infect cattle and buffaloes, and other livestock, in peninsular Malaysia.

In our study the infection rate with *Sarcocystis* spp. in cattle and water buffaloes was considerably lower than investigators have found in Iraq [cattle, 98%; buffaloes, 83% (Latif *et al.*, 1999)], Iran [cattle, 100% (Hamidinejat *et al.*, 2010)], Mongolia [cattle, 90% (Fukuyo *et al.*, 2002)], and in Brazil [cattle, 92% (Hilda *et al.*, 2001)] In Malaysia, the number of stray dogs as definitive host for some parasite species is much lower, thus possibly explaining the lower prevalence of the disease. It was experimentally confirmed that dogs are the definitive hosts of *S. cruzi* and *S. levinei* from cattle and buffaloes, respectively (Dissanaike & Kan, 1978). *Sarcocystis hirsuta* and *S. fusiformis* transmitted by felids have been found less frequently than *S. cruzi* and *S. levinei*, because of low sporocyst production in felids (Dubey *et al.*, 1989; Fayer, 2004), and possibly because felids tend to bury their faeces.

In cattle from the abattoir investigated here, the infection rate was highest in the skeletal muscle, and thus in tissue used for consumption as food. The infection rates between the two cattle breeds differed,

however, for infections of the heart, skeletal muscle and diaphragm, which may be attributed to differences in susceptibility or small sample sizes in our study. As nearly one third of the bovine skeletal muscular tissue samples was infected, there is a high chance for humans to contract intestinal disease if meat is not properly cooked before consumption. There are only few studies concerning the relation between human intestinal sarcocystosis, clinical symptoms, and transmission from animal intermediate hosts. For example, the transmission of three species responsible for cattle sarcocystosis (*S. cruzi*, *S. hirsuta*, and *S. hominis*) to human volunteers in Brazil through the consumption of raw beef was reported (Hilda *et al.*, 2001). The patients developed abdominal pain, nausea and diarrhoea.

In contrast to cattle, the heart was the organ most often infected in water buffaloes. Humans in Malaysia consume heart and other meat of water buffaloes and therefore, this finding is also significant. In total, the infection rate in water buffaloes in our study was nearly twice as high as the rate in cattle, possibly reflecting the grazing habits in water of these animals. Also, a longer infectivity of shed sporocysts from canine faeces in aqueous environments can be assumed.

In conclusion, our study shows a high prevalence of muscular sarcocystosis in Malaysian cattle and water buffaloes. Meat destined for human consumption, especially cattle skeletal muscle and water buffalo heart, shows high infection rates in the respective animals. As the majority of the Malaysian population is accustomed to a non-vegetarian diet including meat from cattle, buffaloes, sheep and goats, human intestinal disease can develop after consumption of raw or undercooked meat. As a preventive measure, animal meat should therefore always be properly cooked before consumption. In addition, it seems advisable to continuously monitor meat of these animals which act as an intermediate host and thus reservoir of *Sarcocystis* parasites. For infection control and as a public health measure, canids and felids should be kept away from grazing cattle and water buffaloes by fencing or similar techniques. This study

has only investigated the occurrence of sarcocystosis in two different meat-producing animal species in a single Malaysian state. Further studies are necessary to describe the full extend of sarcocystosis in meat-producing animals in Malaysia, including other livestock such as sheep and goat, and in several Malaysian states. More extensive molecular studies are underway to determine the *Sarcocystis* species responsible for infection of different livestock in Malaysia.

Acknowledgments. We would like to thank the management of Shah Alam-Selangor abattoir for permitting the sample collection from slaughtered animals. We owe our special thanks to Prof. Dato' Dr. Khalid Yusoff, Dean of Faculty of Medicine, UiTM, for the facilities and his encouragement. Our thanks also extend to Ms. Nurul Fariza Rossle for technical assistance.

REFERENCES

- Ambu, S., Yeoh, E., Mak, J.W. & Chakravarthi, S. (2011). Prevalence of *Sarcocystis* spp. in rodents in Peninsular Malaysia. *International e-Journal of Science, Medicine and Education* **5**: 29–38.
- Dissanaike, A.S. & Kan, S.P. (1978). Studies in *Sarcocystis* in Malaysia. I. *Sarcocystis levinei* n. sp. from the water buffalo *Bubalus bubalus*. *Zeitschrift für Parasitenkunde* **55**: 127-138.
- Dissanaike, A.S., Kan, S.P., Retnasabapathy, A. & Baskaran, G. (1977). Development stages of *Sarcocystis fusiformis* (Raillet, 1897) and *Sarcocystis* spp. of the water buffalo in the small intestines of cats and dogs respectively. *Southeast Asian Journal of Tropical Medicine and Public Health* **8**: 417.
- Dissanaike, A.S. & Poopalachelvam, M. (1975). *Sarcocystis booliati* n. sp. and a parasite of undetermined taxonomic position, *Octoplasma garnhami* n. sp. from the moonrat, *Echinosorex gymnurus*. *Southeast Asian Journal of Tropical Medicine and Public Health* **6**: 175-185.

- Dubey, J.P. (1976). A review of *Sarcocystis* of domestic animals and of other coccidia of cats and dogs. *Journal of the American Veterinary Medicine Association* **169**: 1061-1078.
- Dubey, J.P. & Lindsay, D.S. (2006). Neosporosis, Toxoplasmosis and Sarcocystosis in ruminants. *Veterinary Clinics of North America: Food Animal Practice* **22**: 645-671.
- Dubey, J.P., Speer, C.A. & Fayer, R. (1989). Sarcocystosis of animals and man. Boca Raton, FL, *CRC Press* **1-91**, 143-144.
- Esposito, D.H., Freedman, D.O., Neumayr, A. & Parola, P. (2012). Ongoing outbreak of an acute muscular Sarcocystis-like illness among travellers returning from Tioman Island, Malaysia, 2011-2012. *Eurosurveillance* **8**: 17(45).
- Fayer, R. (2004). *Sarcocystis* spp. in human infections. *Clinical Microbiology Reviews* **17**: 894-902.
- Fukuyo, M., Battsetseg, G. & Byambaa, B. (2002). Prevalence of *Sarcocystis* infection in meat-producing animals in Mongolia. *Southeast Asian Journal of Tropical Medicine and Public Health* **33**: 490-495.
- Hamidinejat, H., Jalali, M. & Nabavi, L. (2010). Survey on *Sarcocystis* infection in slaughtered cattle in south-west of Iran, emphasized on evaluation of muscle squash in comparison with digestion method. *Journal of Animal and Veterinary Advances* **9**: 1724-1726.
- Hilda, F., de Pena, J., Ogassawara, S. & Sinhorini, I.L. (2001). Occurrence of cattle *Sarcocystis* species in raw kibbe from Arabian food establishments in the city of São Paulo, Brazil, and experimental transmission to humans. *Journal of Parasitology* **87**: 1459-1465.
- Kan, S.P. (1979). Ultrastructure of the cyst wall of *Sarcocystis* spp. from some rodents in Malaysia. *International Journal of Parasitology* **9**: 457-480.
- Kan, S.P. & Dissanaik, A.S. (1976). Ultrastructure of *Sarcocystis booliati* from the moon rat, *Echinosorex gymnurus*, in Malaysia. *International Journal of Parasitology* **6**: 321-326.
- Kan, S.P. & Dissanaik, A.S. (1977). Ultrastructure of *Sarcocystis* sp. from the Malaysian house rat, *Rattus rattus diardii*. *Zeitschrift für Parasitenkunde* **52**: 219-227.
- Kan, S.P. & Dissanaik, A.S. (1978). Studies on *Sarcocystis* in Malaysia. II. Comparative ultrastructure of the cyst wall and zoites of *Sarcocystis levinei* and *Sarcocystis fusiformis* from the water buffalo, *Bubalus bubalus*. *Zeitschrift für Parasitenkunde* **57**: 107-116.
- Kan, S.P. & Pathmanathan, R. (1991). Review of sarcocystosis in Malaysia. *Southeast Asian Journal of Tropical Medicine and Public Health* **22** Suppl: 129-134.
- Lai, P.F. (1977). *Sarcocystis* in Malaysian field rats. *Southeast Asian Journal of Tropical Medicine and Public Health* **8**: 417-419.
- Latif, B., Al-Delemi, J.K., Mohammed, B.S., Al-Bayati, S.M. & Al-Amiry, A.M. (1999). Prevalence of *Sarcocystis* spp. in meat producing animals in Iraq. *Veterinary Parasitology* **84**: 85-90.
- Latif, B., Vellayan, S., Omar, E., Abdullah, S. & Desa, N.M. (2010). Sarcocystosis among wild captive and zoo animals in Malaysia. *Korean Journal of Parasitology* **48**: 213-217.
- Norlida, O., Zarina, M., Latif, B., Abo, R. & Al-Sultan, I. (2012). A histopathological appraisal of ovine sarcocystosis in Kelantan. *Journal of Advanced Biomedicine and Pathobiology Research* **2**: 137-142.
- Prakas, P., Kutkiene, L., Butkauskas, D., Sruoga, A. & Zalakevicius, M. (2013). Molecular and morphological investigations of *Sarcocystis corvusi* sp. nov. from the jackdaw (*Corvus monedula*). *Parasitology Research* **112**: 1163-1167.
- Prathap, K. (1973). Sarcocystis in the Malaysian long-tailed monkey, *Macaca fascicularis*. *Transactions of the Royal Society of Tropical Medicine and Hygiene* **67**: 615.

- Tappe, D., Ernestus, K., Rauthe, S., Schoen, C., Frosch, M., Müller, A. & Stich, A. (2013). Initial patient cluster and first positive biopsy findings in an outbreak of acute muscular Sarcocystis-like infection in travellers returning from Tioman island, Peninsular Malaysia, in 2011. *Journal of Clinical Microbiology* **51**: 725-726.
- Wünschmann, A., Armien, A.G., Reed, L., Gruber, A.D. & Olias, P. (2011). *Sarcocystis calchasi*-associated neurologic disease in a domestic pigeon in North America. *Transboundary and Emerging Diseases* **58**: 526-530.
- Zaman, V. (1970). *Sarcocystis* sp. in the slow loris, *Nycticebus coucang*. *Transactions of the Royal Society of Tropical Medicine and Hygiene* **64**: 195-196.
- Zaman, V. & Colley, F.C. (1975). Light and electron microscopic observations of the life cycle of *Sarcocystis orientalis* sp.n. in the rat (*Rattus norvegicus*) and in Malaysian reticulated python (*Python reticulatus*). *Zeitschrift für Parasitenkunde* **47**: 169-185.