JSCR Journal of Surgical Case Reports

Journal of Surgical Case Reports, 2018;9, 1–4

doi: 10.1093/jscr/rjy240
Case Report

CASE REPORT

Traumatic arteriovenous fistula formation secondary to crush injury

Vinu Perinjelil*, Tareq Maraqa, Alex Chavez Yenter, Helen Ohaeri, Leo Mercer, Anish Bansal, and Gul Sachwani-Daswani

1 Hurley Plaza, 7 B Trauma Services, Flint, MI 48503, USA

*Correspondence address. 1 Hurley Plaza, 7 B Trauma Services, Flint, MI 48503, USA. Tel: +1-810-262-6689; E-mail: VPerinj1@hurleymc.com

Abstract

We describe a patient who suffered a crush injury after a motor vehicle accident leading to complex pelvic injuries complicated by an AV fistula. Traumatic arteriovenous (AV) fistulas from blunt, non-penetrating injuries are uncommon and rarely described in medical literature. A CT followed by pelvic angiogram performed by interventional radiology revealed a traumatic fistula which was then treated by embolization. Patient underwent exploratory laparotomy, craniotomy and open reduction internal fixation of pelvis and was stabilized prior to discharge to rehabilitation.

INTRODUCTION

Arterial injuries can be complicated by the development of arteriovenous fistulas (AVF) which occur as abnormal communications between arteries and veins due to traumatic vessel injury. Few reports record the incidence of traumatic AVF from blunt injuries. Treatment of traumatic fistulas rely on therapeutic combinations of surgical ligation and trans arterial embolization, however this diagnosis can be commonly overlooked if presenting with occult findings. Our case highlights the case of a patient who suffered complex pelvic injuries complicated by a traumatic AV fistula in a motor vehicle accident.

CASE PRESENTATION

An 84-year-old male was brought by EMS to the emergency room due to a crush injury while pinned under a vehicle for nearly 30 min. The patient was conscious with a Glascow Coma Scale (GCS) of 15, breathing spontaneously, with moderate hypothermia (T = 33.4) and hemodynamically unstable (blood pressure = 108/87, heart rate = 88, oxygen saturation = 100). Patient complained of pain and loss of sensation in his right upper extremity and pain throughout the right lower abdomen, back, right hip and right leg. On physical examination, diffuse tenderness was present at the right hip and pelvis and bruising was present on the right groin and bilateral thighs. Patient had an unstable pelvis on physical exam. The clinical picture of hemodynamic instability, hypothermia and pelvic findings indicated a pelvic fracture and pelvic x-ray demonstrated an open book fracture of the pelvis with multiple fractures throughout the pelvic ring (Fig. 1). Pelvic binder was applied. Patient was transported to computed tomography (CT) yet only CT of the head could be performed before the patient became hypotensive. Patient received packed red blood cells (PRBCs) and fresh frozen plasma (FFP) in the trauma bay which responded to blood product resuscitation. Remaining CT scans were completed which revealed chronic subdural hematoma.

CT abdomen/pelvis with contrast was performed and a blush of contrast was noted posterior to the right pubic bone. Prior to taking patient for exploratory surgery, he was transferred to the interventional radiology suite where a pelvic angiogram was performed revealing an abnormal blush localized to the distal branches of the right iliolumbar artery (Fig. 2). Delayed phase of the angiogram demonstrated early venous filling consistent with a traumatic arteriovenous fistula

Received: June 13, 2018. **Accepted:** August 28, 2018

Published by Oxford University Press and JSCR Publishing Ltd. All rights reserved. © The Author(s) 2018.
This is an Open Access article distributed under the terms of the Creative Commons Attribution Non-Commercial License (http://creativecommons.org/licenses/by-nc/4.0/), which permits non-commercial re-use, distribution, and reproduction in any medium, provided the original work is properly cited. For commercial re-use, please contact journals.permissions@oup.com

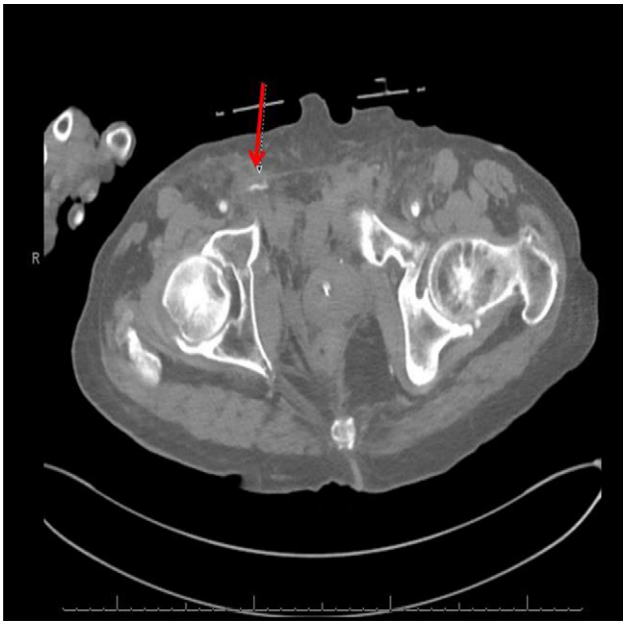

Figure 1: Computed tomography (CT) (axial view) of the abdomen and pelvis demonstrating blush of contrast from distal branch of the right internal iliac artery.

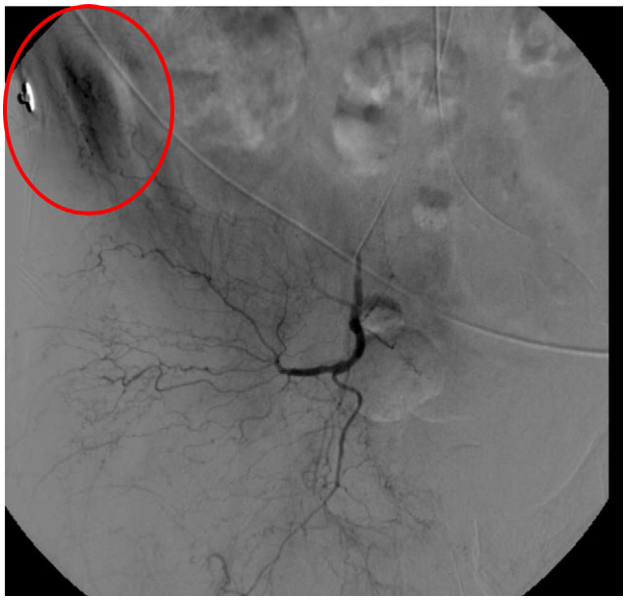

Figure 2: CT angiogram delayed phase of angiogram shows early venous filling consistent with AV fistula.

which was embolized with 300–500 μ of embospheres and three 3 × 2 microcoils (Figs 3 and 4).

After resolution of the traumatic arteriovenous fistula (Fig. 2), a second blush from the right distal internal pudendal artery was identified and successfully treated with Gelfoam slurry. Subsequently, patient underwent exploratory laparotomy which revealed mesenteric and retroperitoneal hematomas. He also underwent craniotomy for evacuation of the subdural hematoma and open reduction internal fixation of the anterior and posterior pelvis. After discharge in fair condition

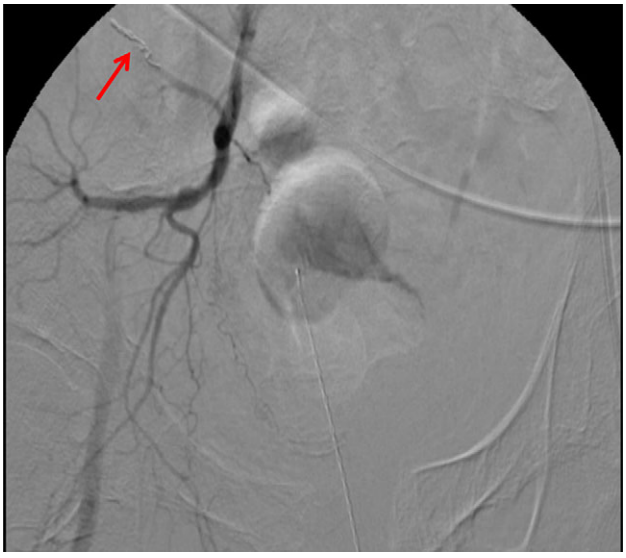

Figure 3: CT angiogram demonstrating microcoil embolization of AV fistula.

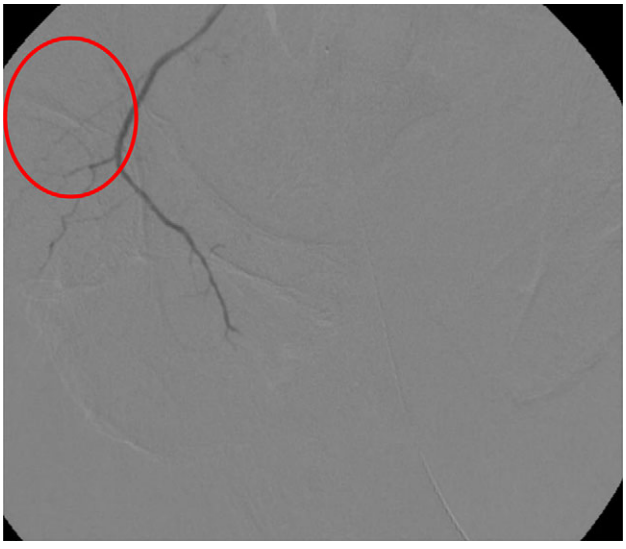

Figure 4: CT angiogram demonstrating successful embolization of AV fistula.

to a subacute rehabilitation facility, patient developed a deep venous thrombosis managed by Coumadin.

DISCUSSION

AVF result in shunting of blood creating a low-resistance and high-flow system which bypasses capillary vasculature and denies tissue perfusion [1]. AV fistulae can be clinically asymptomatic (15%) or present as a machinery murmur with or without palpable thrill (61%) or a pulsatile mass (20%) [2]. Overall, 85% of AV fistulae manifest within 8 weeks of development, and of those 'late presenters' who presented after that time, 96% had a machinery murmur [2]. Table 1 shows the time spans from injury to intervention of AV fistulas recorded in literature.

In a study which focused on traumatic AV fistulae in general (n = 202), there was only one reported fistula (0.005%) in the

Table 1 Review of pelvic injuries with associated traumatic AV fistulas.

Associated pelvic injury	Time span from injury to intervention	Comments
Pubic diastasis, sacral fracture	4 h	The case presented in this case report, AVF between right iliolumbar artery and vein
Separated pubic symphysis, right sacroiliac subluxation [3]	15 h	Traumatic AV fistula between left internal pudendal artery and vein;
Pelvic bone fracture, bulbar urethral lesion [4]	46 days	Pseudoaneurysm associated with AV fistula connected to Santorini plexus
Blunt injury to leg [5]	3 months	Pseudoaneurysm in left distal superficial femoral artery with fistula connection to femoral vein
Severe blunt trauma to left side of pelvis [6]	1.5 years	Multiple small AV fistulae between left internal iliac artery and vein
Pelvic fractures, injury to posterior trunk of internal iliac artery [7]	13 years	Large AV fistula on posterior trunk of internal iliac artery; 4 years of cardiac failure secondary to AV fistula unresponsive to digitalis and diuretics
Iliac bone fracture with post-traumatic heterotopic bone [8]	20 years	AV fistula between right internal iliac artery and vein at level of sciatic notch; hypertrophy of gluteal muscles, otherwise asymptomatic at time of diagnosis
Fracture at the superior and inferior rami of the right pubic bone [9]	No intervention	Right reno-caval AVF, AVF closed spontaneously, but kidney was rendered atrophic and non-functional

Table 2 Incidence of selected traumatic outcomes.

Study focus	Greater incidence	Lesser incidence
Pelvic trauma [9]	Blunt injuries	Penetrating injuries
Acute AV fistulae [2]	Penetrating injuries	2% Blunt injuries
	Extra-pelvic locations	0.005% Pelvic location
Blunt abdominal trauma [4]	Extra-pelvic injuries	20% with Pelvic fracture
Vascular injury [10]	Extra-pelvic fistulae	5.8% Traumatic AV fistulae
	Other fracture	1.8% Pelvic fracture
	Other vessel involvement	0.01% Involvement of internal iliac artery

anatomical distribution of the pelvis [2]. More common locations of AV fistula formation were the cervicomediastinal region, upper limb, thorax, abdomen and lower limb. Another study which focused on vascular injuries in general (n = 387) reported traumatic AV fistulae in 5.8% of cases, in contrast to arterial thrombosis, complete and partial vascular rupture and traumatic pseudoaneurysm [3]. This study also showed that pelvic fracture and involvement of the internal iliac artery were both rare occurrences, and we illustrate those rare cases in literature here (Table 2). Our patient had diffuse non-penetrating trauma resulting in vascular, osseous and soft tissue injuries which intersects minorities of both trauma and vascular cases.

While blunt pelvic trauma is more common than penetrating pelvic trauma [4], most causes of acute AV fistulae are penetrating trauma (98%) [2]. Involvement of pelvic injury is as rare as 20% as evidenced in a study by Fitzgerald of 200 abdominal injuries [4]. Furthermore, no reports have documented the incidence of AVF from crush injuries. Crush injuries, a result of compression to the body from objects can lead to systemic manifestations like muscle damage, hemodynamic instability, organ dysfunction and metabolic abnormalities. The need to identify and appropriately treat vascular injuries early even in those with blunt injuries is critical. Sequelae of untreated AV fistulae include hyperdynamic congestive heart failure [2, 5, 6], hemihypertrophy of ipsilateral musculature, lower extremity ulcerations [7], impotence [6], pre-capillary pulmonary artery hypertension [6], dilation of the afferent arteries and efferent veins, with a possible formation of pulsatile varices or veno-lymphatic trophic complications [7]. If the AV fistula is associated with a pseudoaneurysm, additional complications include thrombosis, embolism, infection and rupture [8].

Current treatments of AVF are embolization, surgery or a combination with preoperative embolization followed within 48 hours by surgery [8]. Traumatic AV fistulas are diagnosed by arteriography for definitive diagnosis, and there is a statistically improved survival rate when transcathether arterial embolization occurs within three hours of arrival to the hospital [9]. An arteriogram consistent with an AV fistula would show early filling of a vein adjacent to a contrast opacified artery, exhibiting a connection between the two vessels [9]. Materials used for embolization in the trauma setting are most commonly coils, microcoils or Gelfoam [9]. In the setting of an AV fistula, coil may be the most appropriate agent as they allow precise embolization [10]. and a combination of coils and Gelfoam can be used if the patient is severely coagulopathic [10]. Complications of AV fistula embolization range from 2 to 11.2% [2, 10] and include recurrent fistulae, repeat bleeding, tissue ischemia, paresthesias, poor wound healing and deep infections [10].

CONFLICT OF INTEREST STATEMENT

None declared.

REFERENCES

1. Patel R, Nicholson AA. Arteriovenous fistulas: etiology and treatment. *Endovasc Today* 2012;**11**:45–51.
2. Robbs JV, Carrim AA, Kadwa AM, Mars M. Traumatic arteriovenous fistula: experience with 202 patients. *Br J Surg* 1994;**81**:1296–9.
3. Wilkins LR, All J, Angle JF. Transcatheter embolization for trauma of the pelvis. *Endovasc Today* 2014;**13**:60–7.
4. Fitzgerald JB, Crawford ES, De Bakey ME. Surgical considerations of non-penetrating abdominal injuries: an analysis of

200 cases. *Am J Surg* 1960;**100**:22–9. https://doi.org/10.1016/0002-9610(60)90533-X.
5. Kim DS, Kim SW, Lee HS, Byun KH, Choe MS. Distal femoral arteriovenous fistula with iliac vein thrombosis after blunt trauma. *Vasc Spec Int* 2017;**33**:37–9. doi:10.5758/vsi.2017.33.1.37.
6. Khoury MB, Contractor FM. Impotence caused by traumatic pelvic arteriovenous communication—a case report. *Angiology* 1988;**39**:849–51. https://doi-org.proxy2.cl.msu.edu/10.1177/000331978803900910.
7. Chen JK, Johnson PT, Fishman EK. Diagnosis of clinically unsuspected posttraumatic arteriovenous fistulas of the pelvis using CT angiography. *Am J Roentgenol* 2007;**188**:W269–73. doi:10.2214/AJR.05.1230.
8. Li Z, Zhao L, Wang K, Cheng J, Zhao Y, Ren W. Characteristics and treatment of vascular injuries: a review of 387 cases at a Chinese center. *Int J Clin Exp Med* 2014;**7**:4710–19.
9. Ray CE, Biffl WL. Neurovascular interventions in the trauma patient. *Semin Interv Radiol* 2002;**19**:377–78. DOI:10.1055/s-2002-36750.
10. Shi J, Gomes A, Lee E, Kee S, Moriarty J, Cryer H, et al. Complications after transcatheter arterial embolization for pelvic trauma: relationship to level and laterality of embolization. *Eur J Orthop Surg Traumatol* 2016;**26**:877.