

REGENERATION VS. REPAIR: AN IN VIVO STUDY OF THE BIOMECHANICAL AND HISTOLOGICAL PROPERTIES OF ADULT AND FETAL TENDON WOUNDS

Michele Favata (1), Pedro K. Beredjikian (1), Jeffrey S. Cartmell (1), Colleen L. Flanagan (1), Timothy M. Crombleholme (2), Louis J. Soslowsky (1)

(1) McKay Orthopaedic Research Laboratory
University of Pennsylvania
Philadelphia, PA

(2) Children's Hospital of Philadelphia
Philadelphia, PA

INTRODUCTION

The healing process in the fetus is fundamentally different from adult wound repair. Previous studies have established that adult skin wounds heal with scar formation whereas fetal skin wounds heal scarlessly, with complete restoration of normal tissue architecture [1]. While the ability to effect scarless repair of dermal injuries has obvious appeal for cosmetic reasons, scarless wound healing holds great promise for injuries to other tissue types as well. Connective tissue injuries account for 45% of the almost 33 million musculoskeletal injuries that occur in the United States each year [2]. These injuries often fail to heal, or else do so by formation of scar tissue, which is less organized than normal tissue and exhibits inferior mechanical properties even long after the initial injury has occurred [3]. Scarring is also responsible for the formation of adhesions, which develop between a healing tendon and its surrounding structures and prevent normal movement of the joint. Whether early gestational fetal tendon is capable of healing scarlessly, with normal geometry and mechanical properties, is not currently known. The objective of our study is to compare the healing properties of adult and fetal tendons. We hypothesized that fetal tendon injured during the second trimester of pregnancy would heal scarlessly through a regenerative pathway, exhibiting normal histology, geometry, and mechanical properties, while adult tendons would heal via scar formation in a reparative pathway.

MATERIALS AND METHODS

Time-dated pregnant ewes at 80-85 days of gestation (term 145 days) were anesthetized prior to laparotomy and hysterotomy (IACUC approved). Following uterus externalization, each of the fetal limbs was exposed. A longitudinal incision was made mid-diaphysis over the 4th metacarpal or metatarsal. A partial, mid-substance tenotomy (approx. 50% of width) was carefully made on the lateral extensor tendon with a custom scalpel blade. No repair was attempted and wound location was marked with India ink or charcoal. Analogous 50% tenotomies without repair were created in each of the maternal limbs for comparison. Sheep were sacrificed at 7 days post-surgery.

For histology, fetal and adult tendon wound segments from each fetal (n=4) and adult (n=3) animal were harvested. Adjacent tissue from the medial extensor tendons served as unwounded controls. Specimens were sectioned and stained with H&E or evaluated immunohistochemically using TGF- β 1 antibodies. H&E sections were graded semi-quantitatively for presence of inflammatory cells, collagen fiber continuity and collagen fiber organization (0=normal, 1=slight, 2=moderate, 3=marked changes compared to established standards). Sections were graded independently by three investigators and the scores averaged. The three histologic parameters were combined to produce an overall histologic grade for each tendon [4].

To quantitate collagen fiber orientations, 3 sections from 4 wounded and 4 unwounded 80-day specimens were viewed under polarized light. Images were taken at 5° increments and digitally analyzed using an automated system [5]. To calculate cross-sectional area, tendon wound thickness and width were measured [6].

For biomechanical studies, specimens were immersed in a 37°C PBS bath and preconditioned. Either a tensile test to failure (at 0.1%/sec) or a stress relaxation test (to 5% strain at 25%/sec followed by 1200 seconds of relaxation) was performed (n=4-5 each).

Differences within and between both age groups were determined using t-tests.

RESULTS

Based on macroscopic observations, the adult wounds exhibited significant scarring. The fetal tendons, however, showed no signs of scar formation. The wound location could only be identified by the presence of India ink or charcoal used to mark the wound location.

Histologically, a gap with granulation tissue and inflammatory cells was visible in the site of wounding in the adult tendons. In the 80-day fetal tendons, however, no abnormalities were noted near the wound and normal collagen architecture was completely restored (Figure 1). These changes are reflected in the overall histologic grade (Figure 2). Immunoassays revealed low levels of TGF- β 1 in the wounded and unwounded 80-day specimens, whereas expression of this growth factor was noticeably upregulated in the adult wounds.

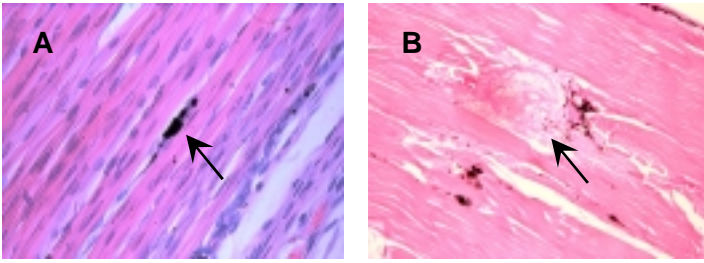


Figure 1: A) H&E section of wounded fetal tendon, 400X. Note the absence of any abnormalities near the charcoal marking the wound (arrow). B) H&E section of wounded adult tendon, 50X. Note the disruption of collagen architecture at the wound (arrow).

Quantitative polarized light analysis showed that the ratio of wounded/unwounded values of entropy (a measure of fiber orientation randomness) was 0.92 ± 0.07 . The wounded/unwounded ratio for the coefficient of variation (a measure of fiber distribution spread) was 0.90 ± 0.15 . In addition, there were no statistical differences in the entropy or coefficient of variation between the wounded and unwounded tendons. These results indicate a high degree of similarity in the injured and control 80-day specimens. This analysis could not even be performed on the adult specimens due to a lack of collagen in the wound space (Figure 3).

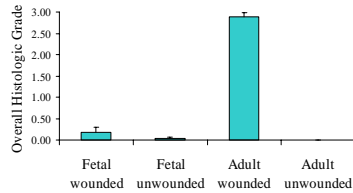


Figure 2: Overall histologic grade of wounded and unwounded adult and fetal tendons (0=normal, 3=marked changes).

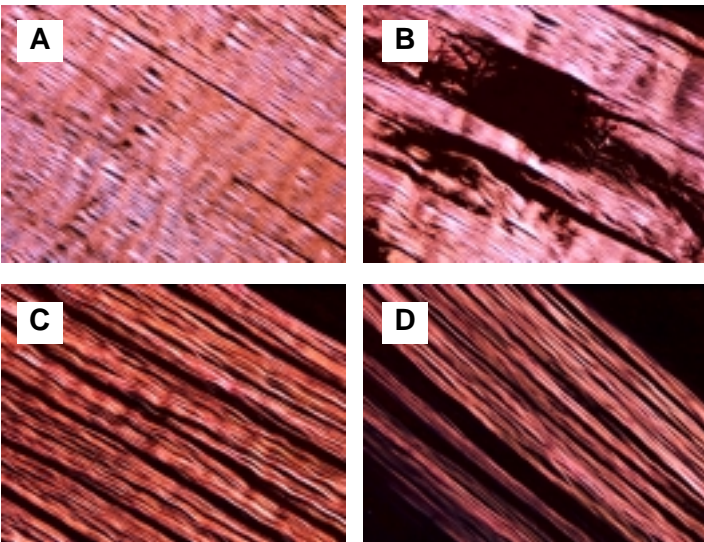


Figure 3: Tendon viewed under polarized light. A) Unwounded adult, 50X. B) Wounded adult, 50X. C) Unwounded fetal, 200X. D) Wounded fetal, 200X. Note the similarity between the wounded and unwounded fetal specimens.

Geometrically, the cross-sectional area increased significantly in the wounded adult tendons, but not in the fetal group (Table 1). Biomechanically, significant decreases were found in the ultimate stress and modulus when comparing the wounded to the unwounded tendons in both groups (Table 1, Figure 4). However, no significant differences were found in the wounded/unwounded ratios for ultimate stress and

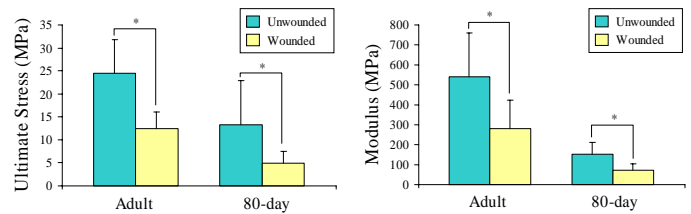


Figure 4: Material properties of wounded and unwounded tendons * $p \leq 0.05$

modulus between the two groups. There were also no differences between the equilibrium/peak stress ratios (from stress relaxation experiments) within the groups (Table 1), nor were there differences in the wounded/unwounded ratio of this value between groups.

Table 1: Geometric and mechanical properties of wounded (W) and unwounded (UW) tendons. (data as mean \pm SD)

		Area (mm ²)	Ultimate Stress (MPa)	Modulus (MPa)	Equ. Stress/ Peak Stress
80-day fetal	UW	0.3 \pm 0.2	13.3 \pm 11.1	151 \pm 63	0.3 \pm 0.2
	W	0.3 \pm 0.04	4.9 \pm 2.8	70 \pm 32	0.2 \pm 0.2
	<i>p</i>	0.8	0.04	0.05	0.09
Adult	UW	5.4 \pm 1.0	24.5 \pm 7.3	539 \pm 221	0.3 \pm 0.1
	W	9.2 \pm 0.2	12.4 \pm 3.6	282 \pm 141	0.3 \pm 0.1
	<i>p</i>	0.001	0.003	0.01	0.2

DISCUSSION

We hypothesized that injured fetal tendons would heal regeneratively with restoration of normal properties, whereas adult tendons would heal reparatively with scar formation. Our gross observations as well as our qualitative and quantitative histological analyses support this. 80-day tendon wounds appeared normal while adult tendon wounds showed considerable alterations. Furthermore, the significantly increased cross-sectional area of the wounded adult tendon is consistent with the presence of scar tissue, as is the increased expression of TGF- β 1 in the adult wound. In addition to normal histology and geometry in the 80-day tendon wounds, we anticipated restoration of normal mechanical properties. Unexpectedly, these tendons demonstrated a limited recovery that was no better than that of the adult tendons at 7 days. However, it is likely that restoration of mechanical integrity may lag in time behind architectural reconstruction, especially at this relatively early time point post-injury. Additionally, the minimal loading environment in the womb may have an adverse effect on tissue remodeling. Future studies will further examine the mechanisms through which fetal tendons heal differently than their adult counterparts.

REFERENCES

1. Longaker et al: J Ped Surg, 25:63-8, 1990.
2. Butler et al: CORR, 367S:S324-S332, 1999.
3. Woo et al: AJSM, 15:22-9, 1987.
4. Soslowky et al: JSES, 9(2):79-84, 2000.
5. Thomopoulos et al: TORS, 27:246, 2002.
6. Soslowky et al: CORR, 304:10-7, 1994.

ACKNOWLEDGEMENTS

This study supported by the NIH, OREF and the Whitaker Foundation. The authors thank H. Brink, S. Mehta, S. Stalling and A. Radu.