PROTECTED PENETRATING KERATOPLASTY: SURGICAL TECHNIQUE AND ENDOTHELIAL RESPONSE

QUERATOPLASTIA PENETRANTE PROTEGIDA: TÉCNICA QUIRÚRGICA Y RESPUESTA DEL ENDOTELIO

LÓPEZ-PLANDOLIT S[1], ETXEBARRÍA J[1], ACERA A[2], CASTIELLA G[3], DURÁN JA[4]

ABSTRACT

Purpose: To describe the technique and to evaluate the safety of protected penetrating keratoplasty (PPK).
Methods: A technique for penetrating keratoplasty is described. The postoperative endothelial cell counts of 17 eyes in which this operative technique was used were compared with those in 24 eyes in whom the standard operative technique for penetrating keratoplasty (PK) was used. The post-operative time periods were grouped as follows: 3-6 months, 7-12 months and >12 months. For statistical analysis, the Mann-Whitney U non-parametric test was employed.
Results: There was no case where tissue extrusion occurred during the procedure. The endothelial cell count was similar in both groups for the 3-6 month period (PK = 2,086, SD 566; PPK = 1,858, SD 671; p = 0.2702) and >12 months period (PK = 1,574, SD 745; PPK = 1,419, SD 810; p = 0.2882). There was a significant difference in the 7-12 month period (PK = 2,255, SD 831; PPK = 1,569, SD 623; p = 0.0397).
Conclusions: The described technique of PPK may reduce the risk of per-operative complications.

RESUMEN

Objetivo: Describir la técnica y conocer la seguridad de una cirugía de queratoplastia penetrante protegida (QPP).
Métodos: Se describe una técnica de QPP. Se compara la evolución postoperatoria del endotelio corneal de 17 ojos intervenidos con esta técnica, comparándola con la de 24 ojos intervenidos con queratoplastia penetrante estándar (QP), en tres periodos de tiempo: 3-6 meses, 7-12 meses y más de 12 meses. Para el análisis estadístico se realizó el test no paramétrico de la U de Mann-Whitney.
Resultados: En ninguno de los casos intervenidos con técnica de QPP se apreció extrusión de tejidos o estructuras intraoculares. El recuento endotelial no mostró diferencia estadísticas en el período de 3-6 meses (QP = 2.086 DE 566; QPP = 1.858 DE 671; p = 0,2702) y el de más de 12 meses (QP = 1.574 DE 745; QPP = 1.419 DE 810; p = 0,2882). Existió diferencia significativa en el período de 7-12 meses (QP = 2.255 DE 831; QPP = 1.569 DE 623; p = 0,0397).
Conclusiones: La QPP que se describe puede reducir el riesgo de ciertas complicaciones perquirúrgi-

Received: March 1, 2007. Accepted: March 6, 2008.
Clinical and Surgical Ophthalmology Institute. Bilbao. Spain.
[1] Graduate in Medicine. Cruces Hospital.
[2] Graduate in Biology.
[3] Graduate in Medicine.
[4] Ph.D. in Medicine. University of the Basque Country.

Correspondence:
Silvia López-Plandolit
Instituto Clínico-Quirúrgico de Oftalmología
C/. Virgen de Begoña, 34
48006 Bilbao
Spain
E-mail: silviaplandolit@terra.es

Damage to the endothelium is not increased compared with that seen following the standard PK procedure *(Arch Soc Esp Oftalmol 2008; 83: 231-236).*

Key words: Penetrating keratoplasty, corneal endothelium, surgical technique.

cas. El endotelio no muestra un sufrimiento significativo cuando se compara con la técnica de QP estándar.

Palabras clave: Queratoplastia penetrante, endotelio corneal, técnica quirúrgica.

INTRODUCTION

At present and even though penetrating keratoplasty (PK) continues to be the standard corneal transplant technique, lamellar keratoplasty is attaining greater relevance. One of the reason for the increased popularity of this technique is the enhanced surgical safety afforded by the improved integrity of the ocular structure during the intervention. However, lamellar keratoplasty cannot be applied in cases of total involvement of the corneal thickness. In these cases, and particularly when there is a larger surgical risk associated to penetrating surgery (eyes with significant alterations of the anterior segment, for instance), the quest for enhanced surgical safety has led to a re-emergence of keratoplasty protected techniques (KPT).

Protected keratoplasty techniques were first described in 1937 by Filatov (1), with some variants introduced in recent times (2). Basically, these variants aim at avoiding the simultaneous opening of the entire cornea, thus reducing the risk of extrusion of the ocular structures.

This paper describes a protected keratoplasty technique and analyses the endothelial count in the post-op follow up, comparing it with that of conventional penetrating keratoplasty.

SUBJECTS, MATERIAL AND METHODS

A retrospective study of 41 eyes is presented (corresponding to like number of patients) submitted to 2 different keratoplasty techniques:

– Penetrating keratoplasty (PK): n=24.

– Protected penetrating keratoplasty (PPK): n=17.

Endothelial microscopy was made with a Topcon SP-2000P (Topcon, Tokyo, Japan). Explorations were obtained in three post-op stages:

– Short term: 3-6 months (mean = 5 months).

– Medium term: 7 - 12 months (mean = 11 months).

– Long term: over 12 months (mean = 24.5 months).

The mean age was of 59 SD 20.66 years in the PK group and 73 SD 13.54 years in the PPK group (graph 1). As regards the root pathology, it was also different in each group (graph 2). Thus:

– The PK group had as predominant pathology Fuchs' endothelial dystrophy followed by keratocone and herpetic corneal disease.

– The PPK group had a prevalence of endothelial decompensation secondary to previous surgery.

The mean corneal conservation time was of 3.36 days, without statistical differences between both groups.

For the statistical analysis the Mann-Whitney «U» non-parametric test was utilized because the N value was below 30, considering a significance level of $P<0.05$.

Surgical technique

The limited incision keratoplasty was made with peribulbar anesthesia associated with IV 10% manitol. The surgery was started in the conventional manner:

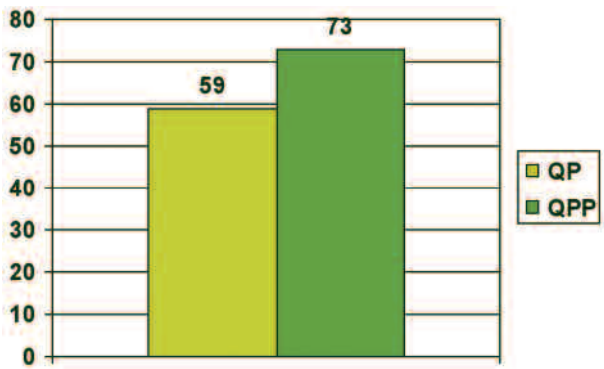

Gráf. 1: Mean age in both groups.

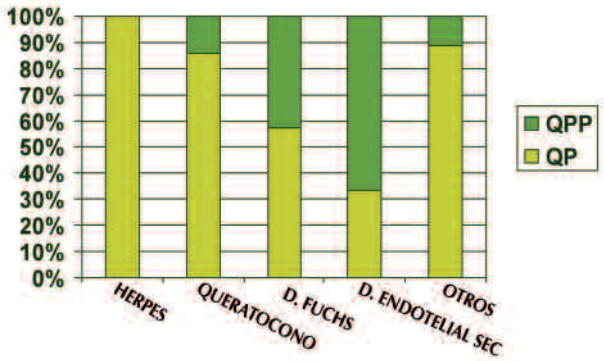

Gráf. 2: Keratoplasty root pathology in both groups.

1. The donor cornea was trephinated with a punch and the receiving cornea with a suction trephinator, leaving a deep mark without entering the anterior chamber.

2. The scleral ring is not needed. The trephination diameter in the receiving cornea is in the range of 7.5-7.75 mm, both with a donor trephination 0.25-0.5 mm larger.

3. It is recommended to mark the references in the receiving ring for positioning the points. Once the groove is made, the epithelium of the receiving cornea is removed. The anterior chamber is accessed by 1 mm paracenthesis at 11 o'clock.

4. The chamber is filled with high density viscoelastic material (figs. 1 and 2).

5. At this stage, maneuvers such as synechtomy, iridoplasty or IOL manipulation can be performed.

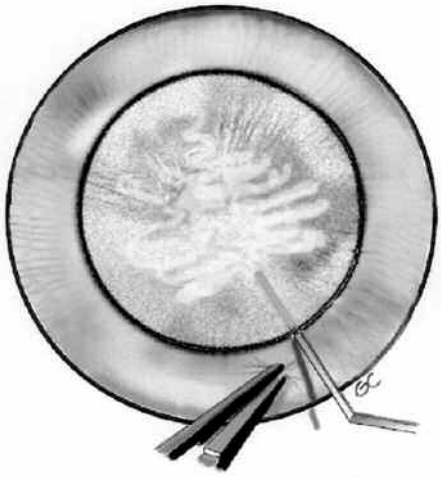

Fig. 2: Introduction of high density viscoelastic.

6. A new incision is made at 10 o'clock, avoiding contact with the previous incision. From the first incision we advance up to 4 o'clock. At this point, it is possible to perform additional maneuvers requiring a broader incision.

7. The 10 o'clock incision is widened to 5 o'clock (figs. 3 and 4).

8. Viscoelastic material is placed on the surface of the receiving cornea and the graft is placed on top of it and affixed with symmetrical points at 7:30 and 1:30 hours (fig. 5).

9. Having affixed the two points, the bridge between 10 and 11 o'clock is cut and a third point is placed at that location (fig. 6).



Fig. 1: After a non-perforating deep trephination, an initial incision is made at 11 hours.

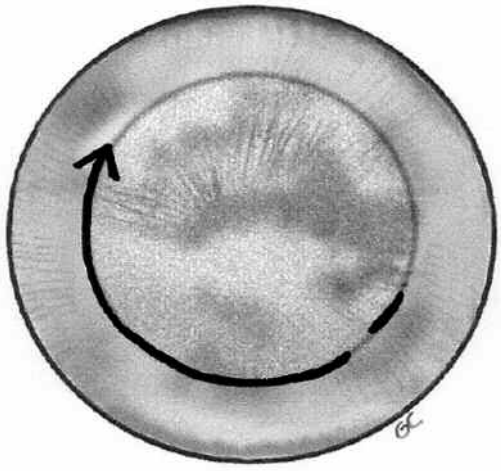

Fig. 3: After a second incision at 10 o'clock, we advance with the scissors from the first incision up to 4 o'clock.

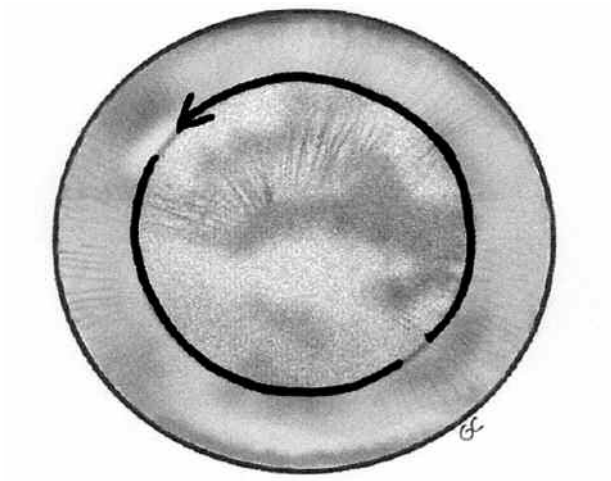

Fig. 4: The 10 o'clock incision is widened up to 5 o'clock. The cornea to be removed is maintained together by two bridges.

10. Finally, the bridge between 4 and 5 o'clock is sectioned and the receiving button removed below the graft, maintaining viscoelastic at all times between both tissues.

11. A 4th point is placed and then the suture of the graft is completed with continuous suture (fig. 7).

The penetrating keratoplasty was performed with the standard technique. In both techniques, a first interrupted 4-stitch suture was made, completed later with a further 16 stitches or a nylon 10/0 continuous suture. The interventions were made by one of the two surgeons (JAD and JEE).

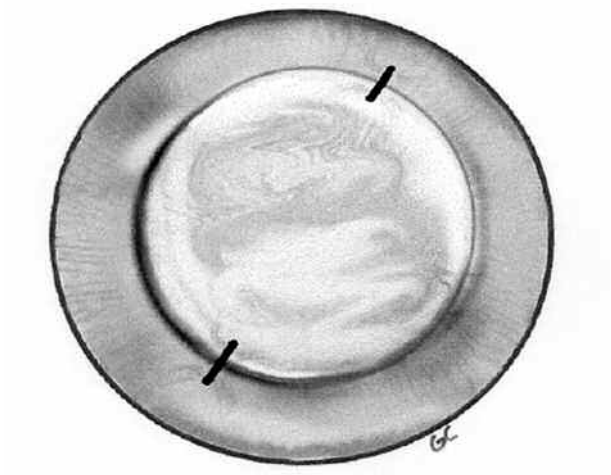

Fig. 5: Graft fixation with two symmetrical points at t 7:30 and 1:30 hours.

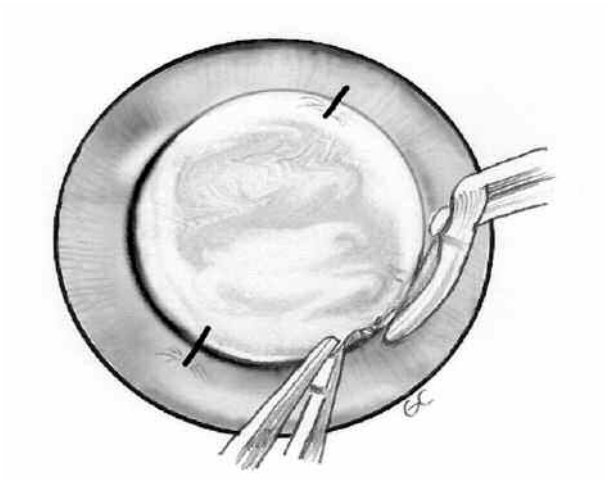

Fig. 6: Cut the bridge of the receiving button between 10 and 11 o'clock.

RESULTS

No relevant complications arose in any of the interventions and the post-op developed within normality. At the end of the study we had 21 transparent corneae in the PK group and 12 in the PPK group.

The endothelial counts in the various exploration periods were:

Short term (3-6 months): PK = 2.086 SD 566; PPK = 1.858 SD 671. No significant differences (p = 0.2702) (fig. 8).

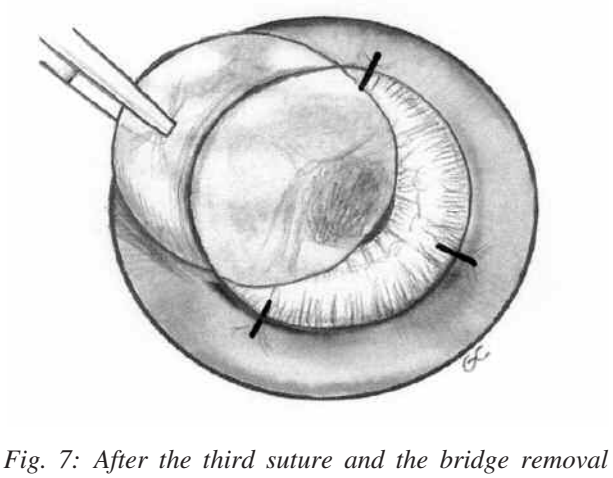

Fig. 7: After the third suture and the bridge removal between 4-5 o'clock, the receiving button below the graft is removed, always maintaining viscoelastic between both tissues.

Medium term (7-12 months): PK = 2.255 SD 831; PPK = 1.569 SD 623. significant difference (p = 0.0397) (fig. 9).

Long term (over 12 months): PK = 1574 SD 745; PPK de 1.419 SD 810. No significant difference (p=0.2882) (fig. 10).

DISCUSSION

To a large extent, the difficulties and risks associated to penetrating keratoplasty are determined by the presence of alterations in the anterior segment. In these cases it would be desirable to make the smallest possible incision during surgery, which is impossible in conventional penetrating keratoplasty techniques.

Lamellar techniques are arising as alternatives. However, said techniques cannot be applied in all cases (4) regardless of their valuable contribution to corneal surgery.

In some indications with anterior segment alterations (anterior synechiae, presence of vitreous, anterior chamber lenses) we propose the utilization of a PPK technique. We have modified Filatov's technique, including high density viscoelastic between the graft and the patient cornea in an attempt to reduce the trauma of the donor endothelial membrane because this was the main limitation of said technique.

Thus, limited incision keratoplasty provides greater surgical safety since it avoid the total opening of the cornea by maintaining at least two areas joined to the eye in all stages, which limits the risk of tissue prolapse and ensures confinement thereof within the eye. In addition, it features the advantage of not requiring special instruments or requiring longer surgical times than conventional techniques. The use of high density viscoelastic and IV manitol enhances the safety of the procedure.

The main drawback of the PPK technique is the damage to the graft endothelium because it is supported on the receiving cornea. In fact and contrary to not very positive endothelial counts, the propor-

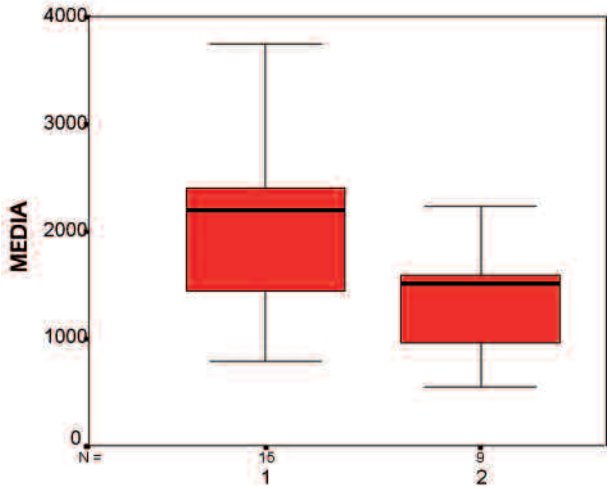

Fig. 9: Mean endothelial count between 6 and 12 months in the PK group (1 in the x-axis) and PPK (2 in the x-axis).

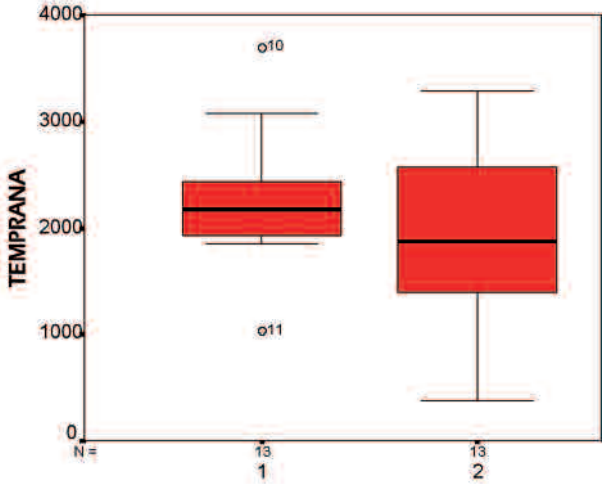

Fig. 8: Mean endothelial count in the first 6 months in the PG group (1 in the x-axis) and PPK (2 in the x-axis).

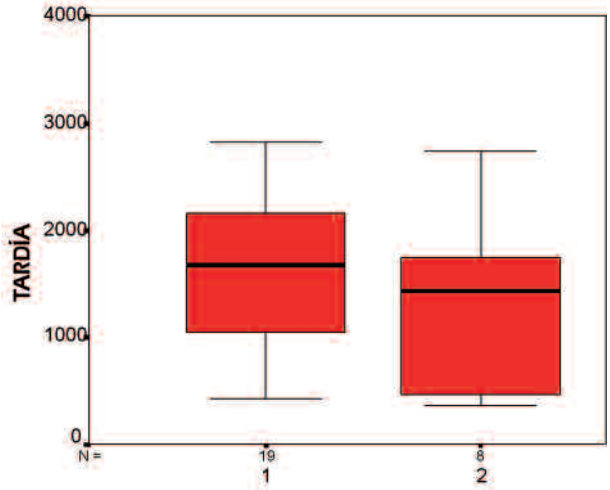

Fig. 10: Mean endothelial count after 12 months in the PK group (1 in the x-axis) and PPK (2 in the x-axis).

tion of corneal failures is greater with this technique. However, the causal pathology probably influences the production of lower endothelial cell counts (5-7). PPK has been utilized in elderly patients (graph 1) and in more complex cases such as presence anterior chamber lens and vitreous, iris alterations, etc. (graph 2). Accordingly, in this group the alterations in the anterior segment led to associating keratoplasty with other surgical maneuvers such as anterior vitrectomy, synechiotomy, lens removal, iris suture, and the like.

In addition, it should be borne in mind that if a conventional PK had been performed in these cases we would have risked an extrusion of the intra-ocular content due to a greater tissue manipulation and more endothelial support on the lens or other intra-ocular structures during the suture stage. By limiting the corneal opening, intra-ocular manipulation and placement of the first sutures becomes easier, in addition to reducing the risk of ocular globe collapse and expulsive hemorrhage.

Therefore, it can be concluded that this technique provides greater surgical safety without a significant reduction of the graft endothelial count. This allows us to recommend this surgical option in high risk penetrating keratoplasty cases in which anterior segment alterations are associated.

REFERENCES

1. *Filatov VP.Transplantation of the cornea. Arch Ophthalmol 1935; 13: 321-347.*
2. *Zaidman G. Pediatric keratoplasty. In: Rasik V. Corneal transplantation. New Delhi, India: Jaypee Brothers Medical Publishers (P) Ltd; 2002; 201-208.*
3. *Faktorovich EG, Rabinowitz YS. Method for safer penetrating keratoplasty in patients with low scleral rigidity. J Cataract Refract Surg 1999; 25: 882-884.*
4. *Panda A, Bageshwar LM, Ray M, Singh JP, Kumar A. Deep lamellar keratoplasty versus penetrating keratoplasty for corneal lesions. Cornea 1999; 18: 172-175.*
5. *Patel SV, Hodge Do, Bourne WM .Corneal endothelium and postoperative outcomes 15 years after penetrating keratoplasty. Am J Ophthalmol 2005; 139: 311-319.*
6. *Bourne WM. Cellular changes in transplanted human corneas. Cornea 2001; 20: 560-569.*
7. *Armitage WJ, Dick AD, Bourne WM. Predicting endothelial cell loss and long-term corneal graft survival. Invest Ophthalmol Vis Sci 2003; 44: 3326-3331.*