

Aseptically Processed Placental Membrane Improves Healing of Diabetic Foot Ulcerations: Prospective, Randomized Clinical Trial

Lawrence A. DiDomenico, DPM*
 Dennis P. Orgill, MD, PhD†
 Robert D. Galiano, MD‡
 Thomas E. Serena, MD§
 Marissa J. Carter, PhD, MA¶
 Jarrod P. Kaufman, MD**
 Nathan J. Young, DPM††
 Charles M. Zelen, DPM‡‡

Background: Allogeneic grafts derived from amnion/chorion are known to be efficacious in healing chronic diabetic foot ulcerations (DFUs). The goal of this study was to compare aseptically processed dehydrated human amnion and chorion allograft (dHACA) versus standard of care (SOC) in facilitating wound closure in nonhealing DFUs.

Methods: Patients with DFUs treated with SOC (off-loading, appropriate debridement, and moist wound care) after a 2-week screening period were randomized to either SOC or wound-size-specific dHACA (AmnioBand, Musculoskeletal Transplant Foundation, Edison, N.J.) applied weekly for up to 12 weeks plus SOC. Primary endpoint was the percentage of wounds healed at 6 weeks between groups.

Results: At 6 weeks, 70% (14/20) of the dHACA-treated DFUs healed compared with 15% (3/20) treated with SOC alone. Furthermore, at 12 weeks, 85% (17/20) of the DFUs in the dHACA group healed compared with 25% (5/20) in the SOC group, with a corresponding mean time to heal of 36 and 70 days, respectively. At 12 weeks, the mean number of grafts used per healed wound for the dHACA group was 3.8 (median 3.0), and mean cost of the tissue to heal a DFU was \$1400. The mean wastage at 12 weeks was 40%. One adverse event and 1 serious adverse event occurred in the dHACA group; neither was graft related. Three adverse events and 1 serious adverse event occurred in the SOC group.

Conclusion: Aseptically processed dHACA heals diabetic foot wounds significantly faster than SOC at 6 and 12 weeks with minimal graft wastage. (*Plast Reconstr Surg Glob Open* 2016;4:e1095; doi: 10.1097/GOX.0000000000001095; Published online 12 October 2016.)

Chronic diabetic foot ulcerations (DFUs) are a devastating complication of diabetes. Expedient healing of DFUs is important to avoid osteomyelitis, hospitalization, or lower extremity amputation, as well as complications associated with patient suffering and high healthcare cost. Although many DFUs granu-

From the *Lower Extremity Institute for Research and Therapy, Youngstown, Ohio; †Department of Plastic Surgery, Brigham and Women's Hospital, Boston, Mass.; ‡Division of Plastic Surgery, Feinberg School of Medicine, Northwestern University, Chicago, Ill.; §Serena Group, Cambridge, Mass.; ¶Strategic Solutions, Inc., Cody, Wyo.; **General Surgery, Premier Surgical, Brick, N.J.; ††Martinsville Research Institute, Martinsville, Va.; and ‡‡Professional Education and Research Institute, Roanoke, Va. Received for publication August 13, 2016; accepted August 31, 2016.

Copyright © 2016 The Authors. Published by Wolters Kluwer Health, Inc. on behalf of The American Society of Plastic Surgeons. All rights reserved. This is an open-access article distributed under the terms of the Creative Commons Attribution-Non Commercial-No Derivatives License 4.0 (CCBY-NC-ND), where it is permissible to download and share the work provided it is properly cited. The work cannot be changed in any way or used commercially without permission from the journal.

DOI: 10.1097/GOX.0000000000001095

Disclosure: Dr. DiDomenico is the medical director of LEIRT and has received research funds from MTF to conduct this clinical trial. Dr. Orgill is a consultant for MTF and receives research funding through grants to Brigham and Women's Hospital. Dr. Galiano is a consultant for MTF and receives research funding through grants to Northwestern University School of Medicine. Dr. Serena is the CEO and medical director of Serena Group and has received research funds for clinical trial from MTF. Dr. Carter has received funds as a consultant for MTF. Dr. Kaufman is a consultant for MTF and has received funds for speaking engagements. Dr. Zelen is employed by the Professional Education and Research Institute, for which he is a medical director and CEO; funds have been received from MTF to conduct clinical trials. Dr. Young has no financial interest to declare in relation to the content of this article. Site investigators and the principal investigator were financially compensated for their time involved in conducting this clinical trial using research funds. Each investigator filled out a conflict of interest form with the IRB. Although Western IRB does not consider receiving research funds to conduct a clinical trial as a conflict of interest, no individual with an actual conflict as defined by the Western IRB, was permitted to consent or participate in the management of any patient in this trial. This study was funded by Musculoskeletal Transplant Foundation (Edison, N.J.). The Article Processing Charge was paid for by the authors.

late and heal with good standard wound management, such as off-loading, debridement, and management of bioburden and inflammation,¹⁻³ certain wounds are unable to granulate and reepithelialize and become stalled in the inflammatory phase of wound healing.

Cellular and tissue-based matrix products can accelerate wound healing by stimulating the microenvironment to transition from the inflammatory to proliferative phase of healing.⁴ Human amniotic membrane grafts were first used as a biomaterial for reconstructive surgery by Davis⁵ in 1910. Early applications of amniotic membranes focused on treating corneal burns, ulcers,^{6,7} and cutaneous burns.⁸ By the end of the 1990s, amniotic membrane processing and long-term storage (cryopreservation, dehydration) steered usage in wound care, and spinal and reconstructive surgery.⁹ In reconstructive surgery, amniotic membranes have been used in diverse areas such as the cervix and ureter,^{10,11} nerve regeneration,¹² fingertips,¹³ and deep periodontal defects.¹⁴

Human placental membranes are composed primarily of amnion and chorion, 2 avascular but conjoined layers (Fig. 1).¹⁵ These membranes are rich in extracellular matrix proteins, growth factors, and cytokines, which can induce angiogenesis and dermal fibroblast proliferation and recruit mesenchymal stem cells involved in wound repair and regeneration.¹⁵⁻¹⁸

Prior randomized controlled trials (RCTs) focusing on chronic wounds have demonstrated the success of amniotic membranes processed via cryopreservation and dehydration with terminal sterilization.¹⁹⁻²⁴ Dehydrated human amnion and chorion allograft (dHACA, AmnioBand[®],

Musculoskeletal Transplant Foundation, Edison, N.J.) is aseptically processed amnion and chorion that is approved for use under the FDA HCT/P, 21 CFR 1271 regulations on homologous use of human tissue. dHACA is not subject to terminal sterilization, which may provide advantages in terms of preserving matrix architecture and cellular trafficking.²⁵

The primary objective of this study was to compare complete wound healing in patients with nonhealing DFUs after 6 weeks of weekly application of dHACA as an adjunct therapy to standard of care (SOC) with SOC alone.

METHODS

Patients with at least 1 unhealed neuropathic DFU that had failed conservative therapy for a minimum of 4 weeks were randomized 1:1 to either dHACA + SOC or SOC alone. The study was conducted at 5 outpatient wound care centers in the United States. The study protocol was approved by the Western Institutional Review Board on January 29, 2015 (protocol number, 20150073). Written consent was obtained from all participants before any study-related procedure.

The trial was conducted in compliance with applicable regulatory requirements in accordance with the provisions of the Declaration of Helsinki, and was preregistered at ClinicalTrials.gov (NCT02399826). Confidentiality was maintained with all patient records in accordance with Health Insurance Portability and Accountability Act requirements. The trial was conducted between March 23, 2015 and March 23, 2016.

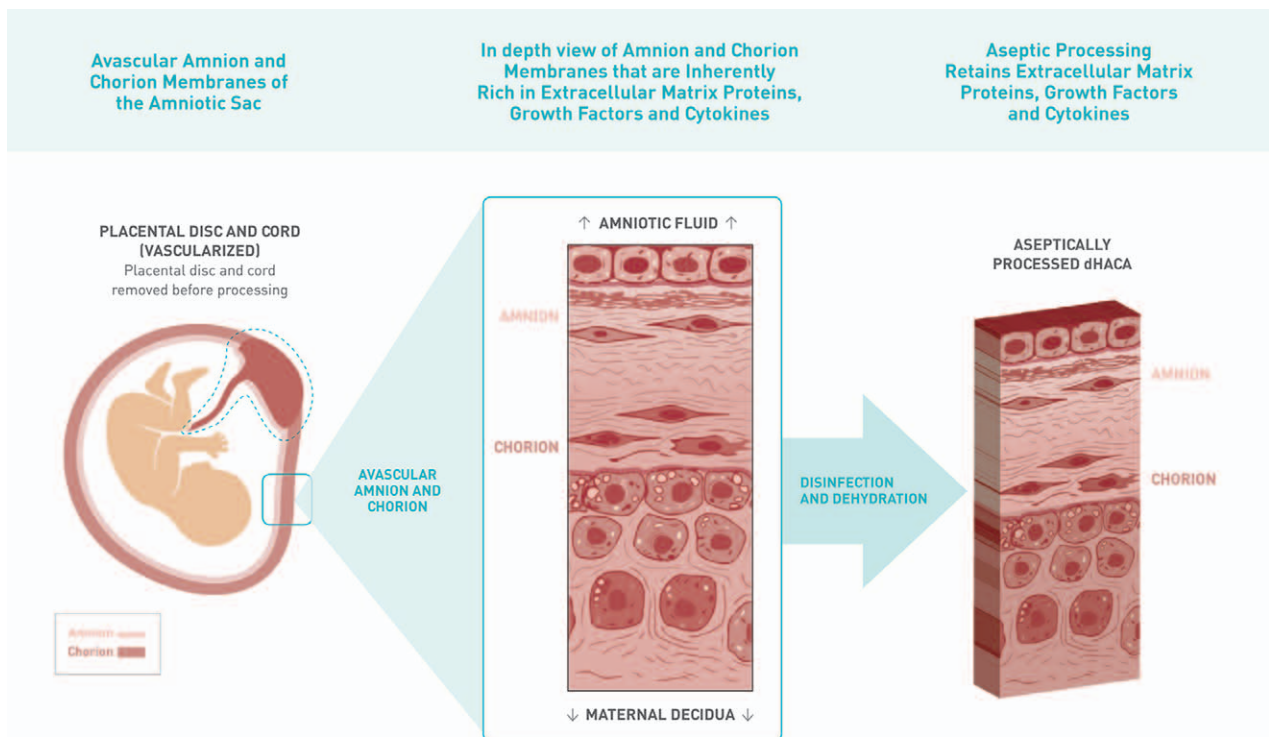


Fig. 1. Diagram of the aseptic processing of human amniotic membranes from placental tissue to produce a structural graft of dHACA for wound placement.

Patient Screening, Eligibility, and Randomization

After signed consent, patients were screened on the basis of inclusion and exclusion criteria (Table 1). Blood was also drawn for serum creatinine and glycosylated hemoglobin (HbA1c) analysis.

If multiple DFUs were present, the largest (index wound) was selected. Infection assessment was performed on the basis of the guidelines of Woo and Sibbald.²⁶ Wounds were evaluated using a probe-to-bone test with a sterile ophthalmological probe to determine whether the study wound might have osteomyelitis, confirmed by X-ray and bone biopsy. Surface area was estimated using acetate tracing. The entire wound was digitally photographed at a distance of 30 cm with a graded centimeter ruler present, with a legible label directly adjacent to the ulcer. Vascular assessment was performed on the extremity on which the wound was located using a combination of transcutaneous oxygen test, ankle brachial index and Doppler arterial waveform tests.

All study-eligible wounds were managed with SOC alone for a 2-week screening period before randomization. Surgical debridement was achieved with a 15-blade scalpel or curette to remove all necrotic tissue. Wound off-loading was performed using a total contact cast or removable cam walker (Royce Medical, Inc., Camarillo, Calif.). Collagen alginate and a 3-layer dressing were applied daily. During 2-week screening, wounds were assessed and measured weekly. Further debridement was performed as necessary. If the index wound had not reduced by more than 20% in size at the end of the screening period, the patient was then randomized.

Randomization was based on a block size of 10, with 5 sheets of paper having SOC assignment and 5 having dHACA assignment. Allocation concealment was achieved by placing each sheet of paper in an envelope and sealing it. Envelopes were shuffled by the study coordinator and subsequently labeled 1 through 10 while being observed by the principal investigator and study staff. The process was repeated 4 times, and the envelopes were distributed to the individual sites. Site investigators were not aware of the methods employed to achieve randomization and treatment assignment.

Dehydrated Human Amnion and Chorion Allograft

The tissue used in this study consists of aseptically processed, dehydrated amnion and chorion (AmnioBand, Musculoskeletal Transplant Foundation) and was provided to investigators gratis in a variety of size-specific grafts, from 1.0 cm disks to 4×6 cm² sizes to minimize wastage. The most size-appropriate graft was selected for each graft application.

Treatments

After randomization, each patient was treated weekly during the study period until the index wound closed or for 12 weeks. Vital signs were taken at each study visit and blood glucose levels measured. Patients in poor metabolic control were referred to their primary care physician or endocrinologist to ensure that diabetes management during the study was adequate. No patients were withdrawn from the study because of diabetes management issues.

Table 1. Inclusion and Exclusion Criteria

Inclusion Criteria	Exclusion Criteria
<ul style="list-style-type: none"> • Male or female age 18 or older • Type 1 or type 2 diabetes mellitus (ADA diagnostic criteria) • Signed informed consent • Patient's wound diabetic in origin and larger than 1 cm² • Wound present for a minimum of 4 wk duration, with documented failure of prior treatment to heal the wound • Wound has no signs of infection • Wound present anatomically on the foot as defined by beginning below the malleoli of the ankle • Additional wounds may be present but not within 3 cm of the study wound • Serum creatinine <3.0 mg/dL • HbA1c <12% at randomization • Patient has adequate circulation to the affected extremity, as demonstrated by 1 of the following within the past 60 days: Dorsum transcutaneous oxygen test ≥30 mm Hg; ABI with results of ≥0.7 and ≤1.2; or Doppler arterial waveforms, which are triphasic or biphasic at the ankle of affected leg • Patient is of legal consenting age • Patient is willing to provide informed consent and is willing to participate in all procedures and follow-up evaluations necessary to complete the study 	<ul style="list-style-type: none"> • Wound probing to bone (UT grade IIIA–D) • Index wound >25 cm² • HbA1c >12% within previous 90 d • Serum creatinine level 3.0 mg/dL or greater • Patients with a known history of poor compliance with medical treatments • Patients previously randomized into this study, or presently participating in another clinical trial • Patients currently receiving radiation therapy or chemotherapy • Patients with known or suspected local skin malignancy to the index wound • Patients with uncontrolled autoimmune connective tissues diseases • Non-revascularizable surgical sites • Active infection at index wound site • Any pathology that would limit the blood supply and compromise healing • Patients who have received a biomedical or topical growth factor for their wound within the previous 30 d • Patients who are pregnant or breast feeding • Patients who are taking medications that are considered immune system modulators that could affect graft incorporation • Patients taking a Cox-2 inhibitor. • Patients with wounds healing >20% during the screening period

ADA, American Diabetes Association.

Index wounds were cleansed with sterile normal saline solution, followed by debridement if required, with post-debridement surface area recorded before wound photography. If infection was suspected, both anaerobic and aerobic cultures were obtained from wound swabs and appropriate systemic antibiotic treatment was initiated and continued until the infection was clinically resolved. If the infection precluded dHACA application in the treatment group or caused problems with scheduled visits in either group, the patient was withdrawn from the trial and the treatment was considered to be a failure.

The index wound in the SOC group was dressed daily with collagen alginate (Fibracol, Systagenix, Gargrave, Yorkshire, United Kingdom); the wound was dressed by patients or their caregivers at home 6 days a week and by the site investigator 1 day a week. For index wounds in the treatment group, an outline of the wound was sketched on the graft using the acetate drawing, and the graft photographed to document size and portion of the graft not being used (waste). The graft was cut to size with a 15-blade scalpel, pie-crusting to no greater than 1.5:1.0 ratio if needed, rinsed with sterile saline, and placed over the wound site, ensuring the graft was consistently covering the entire wound surface. The graft was covered with a nonadherent dressing (Adaptic Touch, Systagenix, Yorkshire, United Kingdom) topped with a moisture-retentive dressing (hydrogel bolster) and a padded 3-layer dressing (Dynaflex, Systagenix). Application of dHACA occurred weekly during the study period until complete epithelialization occurred, the patient was withdrawn, or the study was completed. Six weeks after randomization, the percentage area reduction (PAR) was calculated for the index wound. If the DFU failed to reduce in area by 50% or more, the patient was withdrawn from the study and allowed to seek other treatment options.²⁷

Healing Validation

Wounds were defined healed if complete (100%) epithelialization occurred without drainage and need for dressing, as determined by the site investigator. Durable closure was assessed at a follow-up visit scheduled 1 week after. The principal investigator was responsible for approving protocol pathway decisions regarding wound closure or individual patient continuation in the study based on photographic review. Validation of healing was conducted by an independent panel of physicians, including a vascular surgeon, 2 plastic surgeons, a general surgeon, a podiatrist, and a scientific expert in angiogenesis. These adjudicators, blinded to patient study group assignments, reviewed decisions made by site investigators regarding patient enrollment, healing, and study continuation. At study exit, every patient was given complimentary diabetic shoes and insoles, provided by the sponsor per protocol.

Study Outcomes

The study primary endpoint was comparison of proportion of wounds healed at 6 weeks between the 2 treatment groups. Secondary endpoints included proportion of wounds healed at 12 weeks, time to heal within 6 and 12 weeks, count of graft applications, graft wastage, and cost

of product to closure for healed wounds in the dHACA group. Mean percentage graft wastage (% GW) for each wound was determined by percentage of the area of the graft that was discarded. When disks of dHACA were used, the calculation assumed a circle for the dHACA application. Graft costs for each wound were calculated by summing the costs of the dHACA applications from all visits based on the graft sizes used, using the current published fee schedule for each graft.

Sample Size Calculations and Statistical Analysis

Sample sizes of 20 in each group were selected to achieve at least 80% power (84% actual) to detect a difference between the group proportions of 0.45. The proportion in group 1 (treatment group) was assumed to be 0.35 under the null hypothesis and 0.8 under the alternative hypothesis. The proportion in group 2 (control group) was 0.35. The test statistic used was the 2-sided Z test with pooled variance. The significance level actually achieved by this design was 0.052.

The intent-to-treat (ITT) and safety populations comprised randomized patients who received at least 1 treatment. All analyses used the ITT approach. The last observation carried forward principle was used in regard to missing observations. Study variables were summarized as means and standard deviations (\pm SDs) for continuous variables, as well as medians for non-normal data. Categorical variables were presented as counts and proportions or percentages. Although statistical testing between treatment groups at baseline is not recommended as logical according to CONSORT guidelines,²⁸ this was carried out to examine the success of randomization. For categorical variables, chi square or Fisher's exact tests were performed to test for statistical differences. A Kaplan–Meier analysis was conducted to compare time to heal within 6 or 12 weeks between the 2 treatment groups. A logistic regression was carried out to analyze proportion of wounds healed at 6 weeks, adjusting for all available covariates known to influence wound healing. Covariates were entered into 1 block with stepwise elimination for nonsignificant covariates. Model fit was assessed using Hosmer and Lemeshow goodness of fit and Bayesian information criterion. Dispersion was calculated from deviance and degrees of freedom. Effect size was calculated using Cohen's *d*. To adjust for the family-wise error rate, *P* values were reported using the Hochberg step-up procedure. Adjusted 2-sided *P* values <0.05 were considered significant. PASW 19 (IBM, Chicago, Ill.) was used to perform the statistical testing.

PAR for the index wound at 6 or 12 weeks was calculated thus $[(A_1 - A_{xw})/A_1] \times 100$, where A_1 is the area of the index wound at randomization and A_{xw} the area at 6 or 12 weeks.

RESULTS

Of 47 patients screened, 40 met the screening criteria and were randomized to dHACA + SOC ($n = 20$), or SOC alone ($n = 20$) (Fig. 2). One subject was lost to follow-up in the SOC group because of a serious adverse event (SAE) that

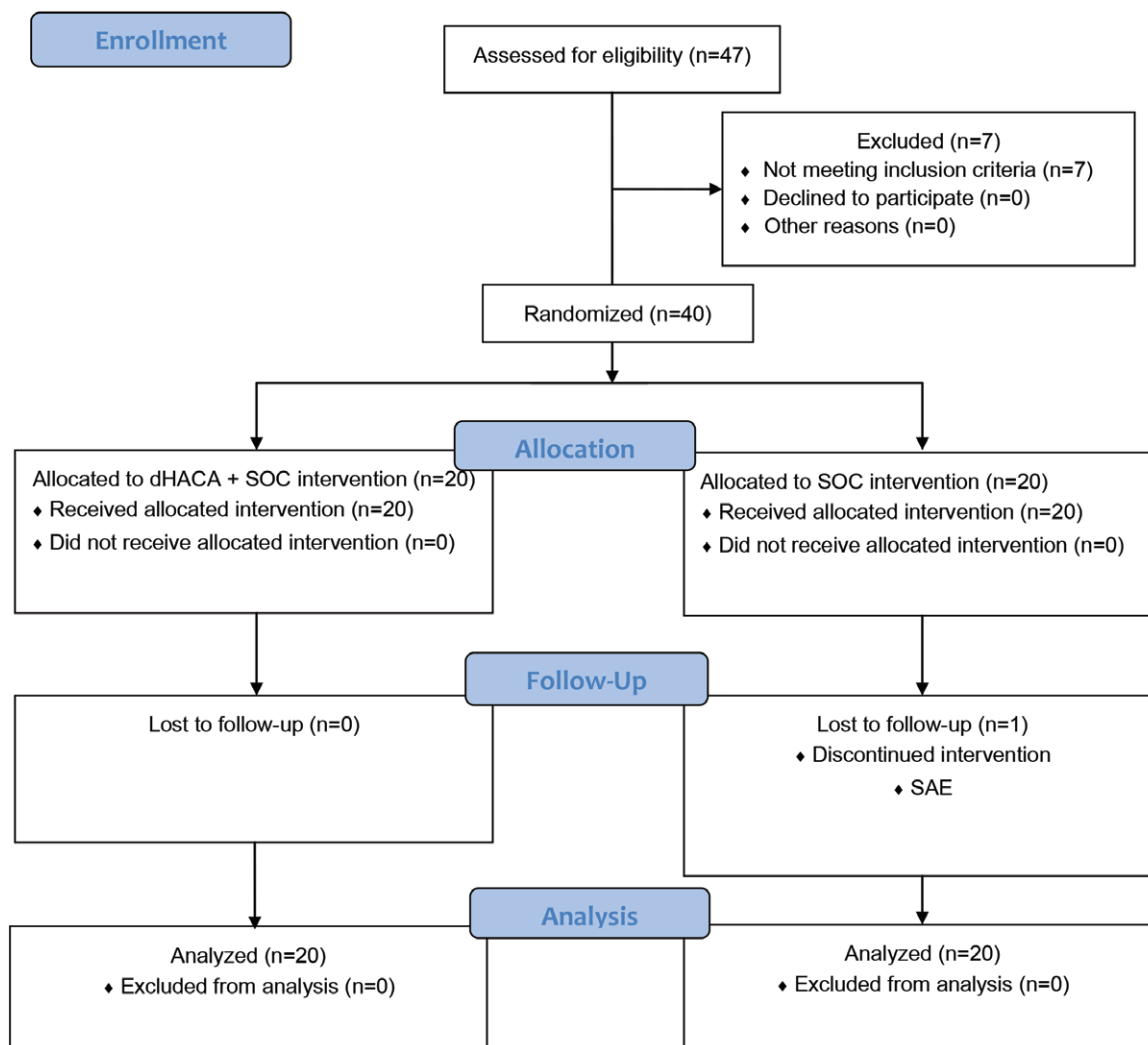


Fig. 2. Flowchart of trial participants.

involved bone infection and occurred at week 6. Except for mean wound area at randomization in which the SOC group was larger than the dHACA group (3.3 versus 2.0 cm²), the groups were well matched in regard to patient- and wound-related parameters (Table 2).

At our primary endpoint (6wk), 70% (14/20) of the dHACA + SOC-treated DFUs had healed compared with 15% (3/20) of DFUs treated with SOC alone ($P = 0.001$) (Cohen's d : 1.3) (Fig. 3). Although treatment was the only significant variable in the logistic regression model, log patient age was retained ($P = 0.057$) to improve overdispersion. Final model statistics were: Nagelkerke R^2 , 0.47; Hosmer and Lemeshow, 0.90; dispersion, 1.0; and overall correct classification of subjects, 78%. The odds ratio for healing in dHACA + SOC-treated patients compared with SOC patients was 17 (95% confidence interval [CI], 3.1–93), $P = 0.001$. At 12 weeks, 85% (17/20) of the DFUs in the dHACA + SOC group had healed compared with 25% (5/20) in the SOC group (Fig. 4). At 6 weeks, mean time to heal for the dHACA–SOC group was 30 days (95% CI, 24–35) compared with 40 days

(95% CI, 37–43) for the SOC group ($P = 0.00073$). At 12 weeks, mean time to heal between the groups had widened considerably: dHACA + SOC, 36 days (95% CI, 27–46); SOC, 70 days (95% CI, 59–81; $P = 0.00073$) (Fig. 5). At 6 weeks, PAR for the SOC group had reached 48% \pm 65%, whereas the value for the dHACA + SOC group was 87% \pm 30%. The corresponding figures at 12 weeks were little changed: 41 \pm 72 and 87 \pm 31, respectively (Fig. 6).

At the 6-week point, 8 patients from the SOC group and 1 patient from the dHACA + SOC group were withdrawn from the study because their wounds failed to reduce in area by at least 50%. Although all DFUs were found still closed 1 week after initial closure in the dHACA + SOC cohort, 2 DFUs in the SOC group reopened after initial wound closure.

At 6 weeks, the mean number of grafts used per wound for the dHACA + SOC group was 3.1 (\pm 1.7). The mean cost of product to heal DFUs was \$1091 (\pm \$619; $n = 14$). At 12 weeks, the mean number of grafts used per healed wound for the dHACA + SOC group was

Table 2. Wound- and Patient-related Variables between Groups at Randomization

Variable	dHACA	SOC	P
Age (y)	59 (13)	58 (9)	0.72
Race			
Caucasian	19 (95)	19 (95)	1.0
African American	1 (5)	1 (5)	
Gender			
Male	11 (55)	16 (80)	0.09
Female	9 (45)	4 (20)	
BMI	37 (9.6)	37 (11)	0.98
Smoker	4 (20)	2 (10)	0.78
Drinks alcohol	3 (15)	5 (25)	0.63
HbA1c*	7.5 (1.2)	7.8 (1.5)	0.50
Creatinine	1.1 (0.49)	1.1 (0.43)	0.79
Wound area (cm ²)	2.0 (0.90); median: 1.7	3.3 (4.35); median: 2.2	0.56
Wound plantar surface	15 (75)	15 (75)	1.0
Wound location			
Toe	4 (20)	4 (20)	0.72
Forefoot	7 (35)	5 (25)	
Midfoot	8 (40)	8 (40)	
Heel/ankle/hindfoot	1 (5)	3 (15)	

Continuous variables are reported as means and SDs and categorical variables as number (n) and percentage (%).

*Average of HbA1c values (beginning and end of study).

BMI, body mass index.

3.8 (±2.2). The mean cost of product to heal was \$1400 (±\$1100; n = 17). Mean wastage at 12 weeks was 40% (±22; median: 45; n = 17).

Four adverse events occurred: 1 in the dHACA + SOC group (5%) and 3 in the SOC group (15%). All adverse events that progressed into SAEs involved localized pedal infections initially treated with antibiotics. There were a

total of 2 SAEs, 1 in the dHACA + SOC group and 1 in the SOC, both involving foot infections that progressed to osteomyelitis; both were treated with OR debridement and IV antibiotics. No adverse events were found to be graft related.

The number needed to treat at 12 weeks was 1.7 (95% CI, 1.2–2.8).

DISCUSSION

In this RCT, examining our primary endpoint, weekly application of dHACA as an adjunctive therapy to SOC was superior for healing compared with SOC alone in the treatment of full-thickness DFUs as measured by the percentage of wounds healed at 6 weeks. The substantial wound area reduction seen in this study occurred in the majority of the patients receiving dHACA during the initial weeks of application, where the dHACA showed the greatest ability to reduce wound size. Analysis of the primary endpoint of complete wound healing at 6 weeks showed that >4 times more wounds were healed in the dHACA–SOC group compared with the SOC group, with a large effect size of 1.3,²⁹ as well as a large clinically meaningful effect. In the adjusted analysis, no other covariates besides treatment were statistically significant, including wound area at baseline. Further analysis at 12 weeks based on proportion of wounds healed or time to heal demonstrated that the healing effect attributable to the dHACA graft was maintained. The aseptically processed dHACA was statistically superior for all endpoints in healing DFUs compared with SOC alone.

The aseptic processing of the dHACA used in this trial distinguishes it from comparable grafts that have un-

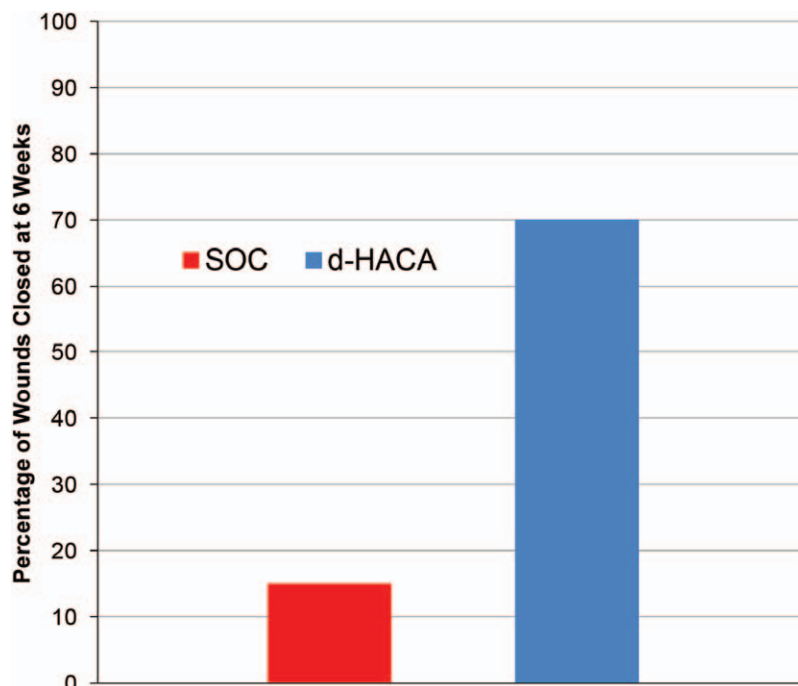


Fig. 3. Bar graph showing complete wound healing at 6 weeks for the dHACA and SOC groups, tested by chi square ($P = 0.001$).

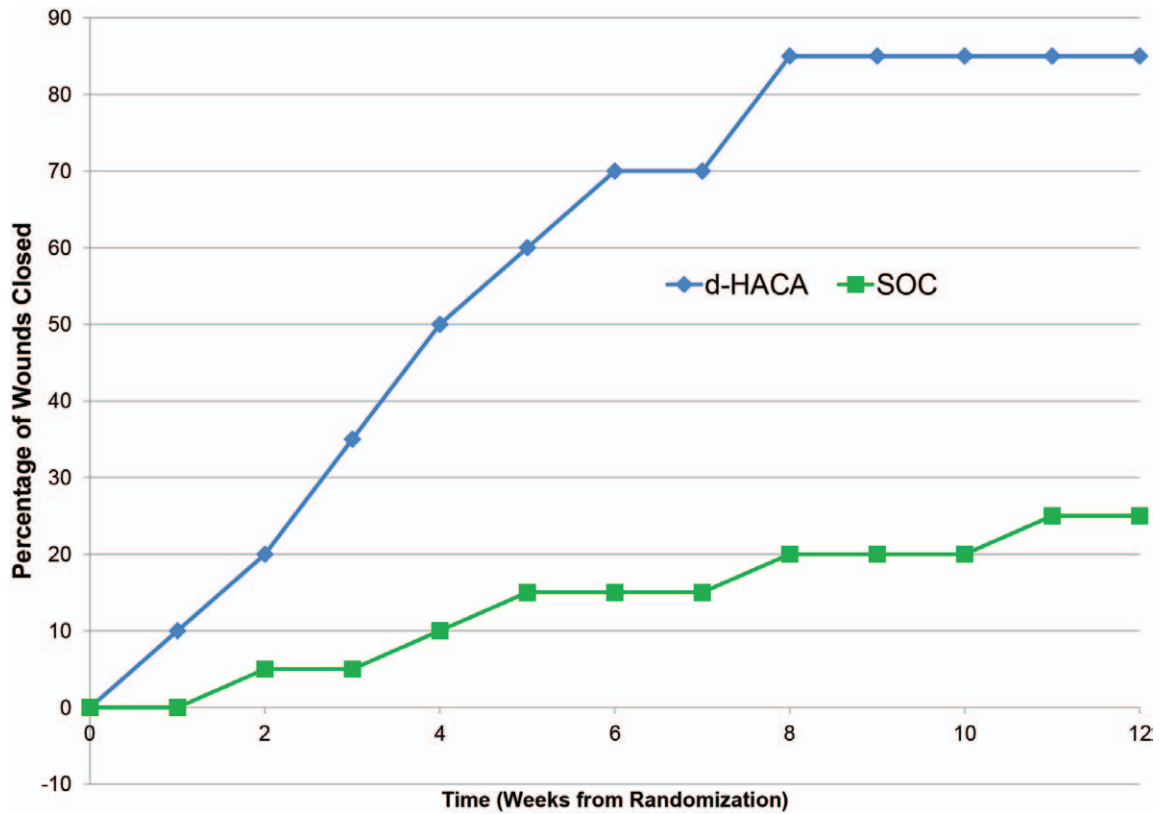


Fig. 4. Percentage of wounds healed weekly up to 12 weeks by treatment group (not statistically tested at 12 wk).

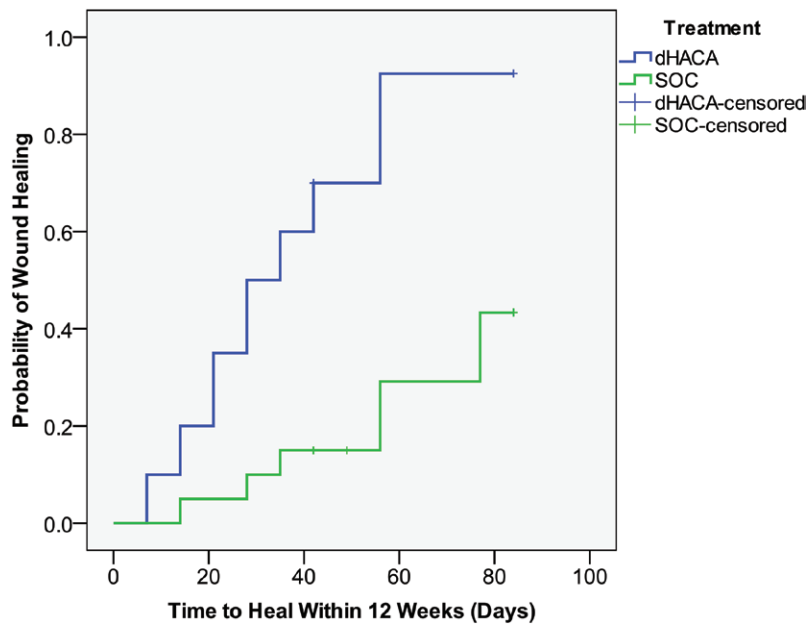


Fig. 5. Kaplan–Meier plot of time to heal within 12 weeks by treatment group, tested by the log rank test ($P = 0.00073$).

dergone terminal sterilization employing both gamma and electron beam irradiation. Radiation sterilization has been observed to cause disruption of collagen fibers and basement membrane, loss of structural integrity and fragmentation in the amniotic membrane, and disinte-

gration of epithelial basement membrane, at doses of 25 to 50 kGy, and nuclear chromatin condensation at 12.5 kGy.^{30–33} Endogenous cytokine and growth factor levels (tissue inhibitor of metallo-proteinases, platelet derived growth factor, epidermal growth factor, fibroblast

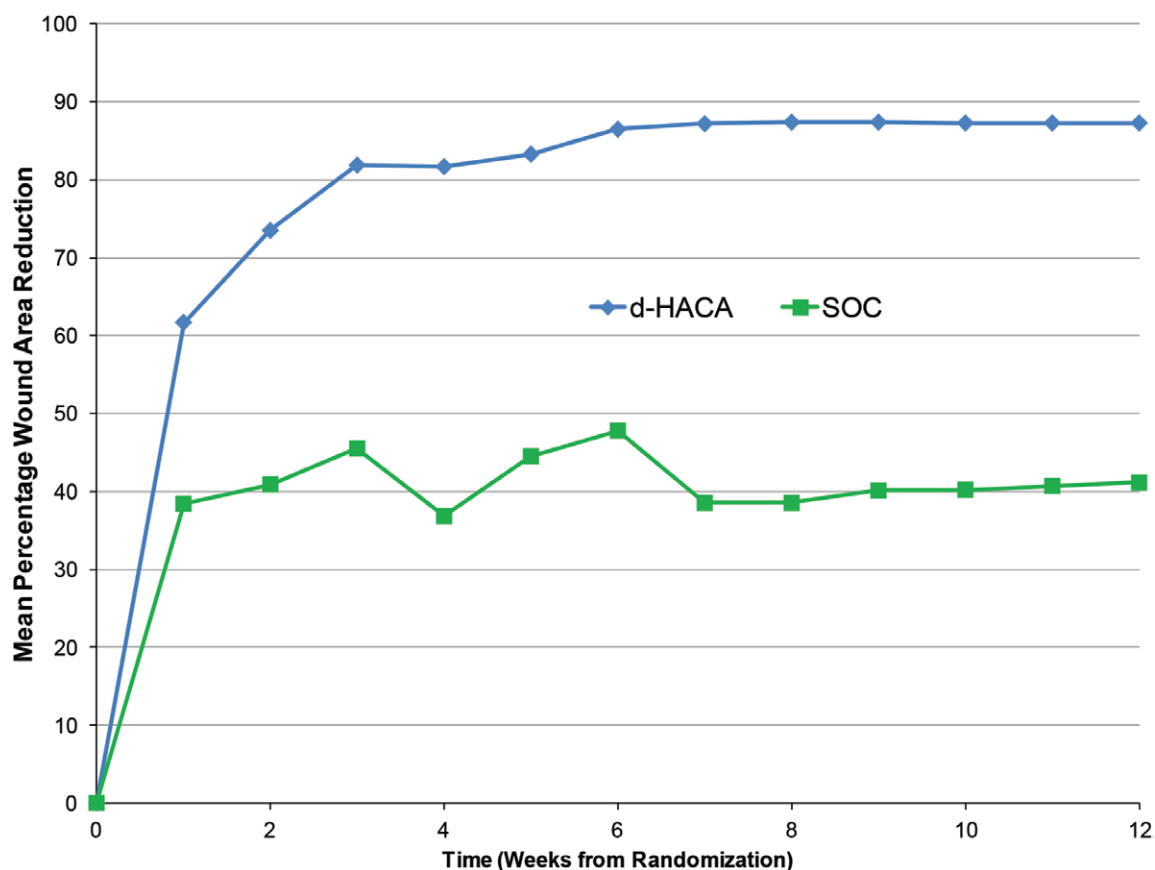


Fig. 6. Weekly percentage wound area reduction up to week 12 (ITT basis) by treatment group (not statistically tested at 12 wk).

growth factor) are also affected at gamma doses as low as 10 kGy.³⁴ The superior healing observed in diabetic wounds treated by dHACA may support the advantage of aseptic processing. However, more scientific studies are needed to determine how terminal sterilization affects cellular mechanisms versus aseptic processing once the graft has been placed in a wound, as well as translation of those effects into healing metrics.

The median number of 3 applications per healed wound was comparable to recently published amniotic membrane trials.^{18–24,35} The availability of smaller sizes of dHACA led to lower graft costs and wastage at both 6 and 12 weeks when compared with previously published RCTs that studied soft-tissue grafts as a therapy for diabetic wounds.^{23,24} The mean graft cost to wound closure at 12 weeks in all dHACA-healed wounds was \$1400, which is among the lowest graft cost to closure reported for any published allograft study. Further, the availability of a wide variety of sizes of graft as small as a 1.0-cm disk enabled less wastage (40%) compared with trials of other bioengineered soft-tissue grafts showing wastage over twice this figure.²³

Our study strengths include pragmatic SOC, satisfactory allocation concealment with ITT analysis based on sufficient statistical power, appropriate adjustment for multiple statistical testing, and reporting according to CONSORT guidelines. Limitations of our trial include the lack of blinding (patient and investigator) and lack

of a soft-tissue matrices comparator. Future studies may consider comparing different amniotic tissue forms and allowing wounds of greater severity or depth.³⁶ In addition, withdrawal of patients whose wounds did not reduce in area by at least 50% after 6 weeks of either treatment regimen—done to ensure patient safety—resulted in high right censoring for analyses at 12 weeks. Another issue in regard to inclusion/exclusion criteria was the use of ABI as one means of evaluating distal perfusion. Diabetic patients' calcification of lower extremity arteries can falsely elevate readings, with values often exceeding 1.3.³⁷ In most instances, such high readings would have automatically caused a screen failure, and this might have resulted in a more biased population, which is why Doppler studies were performed on the entire cohort for evaluation of biphasic flow in the study extremities. Finally, although our cost analysis was based upon publicly available data (mean sales price per cm² and published studies), a preferred, full health economic analysis of dHACA is beyond the scope of this trial.

In conclusion, aseptically processed dHACA plus SOC treatment for nonhealing DFUs over 6 and 12 weeks has been shown to heal DFUs significantly faster than SOC with minimal graft wastage. Given its modest cost and ability to heal recalcitrant DFUs, the dHACA graft may have clinical applications in patients with even more complex wounds that are deep to tendon and bone.

Charles M. Zelen, DPM, FACFAS, MAPWCA

Professional Education and Research Institute, Inc.

222 Walnut Ave

Roanoke, VA 24016

E-mail: cmzelen@periedu.com

REFERENCES

- Lipsky BA, Berendt AR, Cornia PB, et al.; Infectious Diseases Society of America. 2012 Infectious Diseases Society of America clinical practice guideline for the diagnosis and treatment of diabetic foot infections. *Clin Infect Dis*. 2012;54:e132–e173.
- Snyder RJ, Frykberg RG, Rogers LC, et al. The management of diabetic foot ulcers through optimal off-loading: building consensus guidelines and practical recommendations to improve outcomes. *J Am Podiatr Med Assoc*. 2014;104:555–567.
- Hingorani A, LaMuraglia GM, Henke P, et al. The management of diabetic foot: a clinical practice guideline by the Society for Vascular Surgery in collaboration with the American Podiatric Medical Association and the Society for Vascular Medicine. *J Vasc Surg*. 2016;63(2 Suppl):3S–21S.
- Rosique RG, Rosique MJ, Farina Junior JA. Curbing inflammation in skin wound healing: a review. *Int J Inflamm*. 2015;2015:316235.
- Davis J. Skin transplantation with a review of 550 cases at the Johns Hopkins Hospital. *Johns Hopkins Hospital Report*. 1910;15:307–310.
- Sorsby A, Symons HM. Amniotic membrane grafts in caustic burns of the eye (burns of the second degree). *Br J Ophthalmol*. 1946;30:337–345.
- Sippel KC, Ma JJ, Foster CS. Amniotic membrane surgery. *Curr Opin Ophthalmol*. 2001;12:269–281.
- Kesting MR, Wolff KD, Hohlweg-Majert B, et al. The role of allogenic amniotic membrane in burn treatment. *J Burn Care Res*. 2008;29:907–916.
- Loeffelbein DJ, Rohleder NH, Eddicks M, et al. Evaluation of human amniotic membrane as a wound dressing for split-thickness skin-graft donor sites. *Biomed Res Int*. 2014;2014:572183.
- Mhaskar R. Amniotic membrane for cervical reconstruction. *Int J Gynaecol Obstet*. 2005;90:123–127.
- Koziaik A, Salagierski M, Marcheluk A, et al. Early experience in reconstruction of long ureteral strictures with allogenic amniotic membrane. *Int J Urol*. 2007;14:607–610.
- Fesli A, Sari A, Yilmaz N, et al. Enhancement of nerve healing with the combined use of amniotic membrane and granulocyte-colony-stimulating factor. *J Plast Reconstr Aesthet Surg*. 2014;67:837–843.
- Fijan A, Hashemi A, Namazi H. A novel use of amniotic membrane for fingertip injuries. *J Wound Care*. 2014;23:255–258.
- Kiany F, Moloudi F. Amnion membrane as a novel barrier in the treatment of intrabony defects: a controlled clinical trial. *Int J Oral Maxillofac Implants*. 2015;30:639–647.
- Koob TJ, Lim JJ, Masee M, et al. Properties of dehydrated human amnion/chorion composite grafts: implications for wound repair and soft tissue regeneration. *J Biomed Mater Res B Appl Biomater*. 2014;102:1353–1362.
- Koob TJ, Rennert R, Zabek N, et al. Biological properties of dehydrated human amnion/chorion composite graft: implications for chronic wound healing. *Int Wound J*. 2013;10:493–500.
- Koob TJ, Lim JJ, Masee M, et al. Angiogenic properties of dehydrated human amnion/chorion allografts: therapeutic potential for soft tissue repair and regeneration. *Vasc Cell*. 2014;6:10.
- Niknejad H, Peirovi H, Jorjani M, et al. Properties of the amniotic membrane for potential use in tissue engineering. *Eur Cell Mater*. 2008;15:88–99.
- Zelen CM, Serena TE, Denozieri G, et al. A prospective randomised comparative parallel study of amniotic membrane wound graft in the management of diabetic foot ulcers. *Int Wound J*. 2013;10:502–507.
- Zelen CM, Serena TE, Snyder RJ. A prospective, randomised comparative study of weekly versus biweekly application of dehydrated human amnion/chorion membrane allograft in the management of diabetic foot ulcers. *Int Wound J*. 2014;11:122–128.
- Serena TE, Carter MJ, Le LT, et al.; EpiFix VLU Study Group. A multicenter, randomized, controlled clinical trial evaluating the use of dehydrated human amnion/chorion membrane allografts and multilayer compression therapy vs. multilayer compression therapy alone in the treatment of venous leg ulcers. *Wound Repair Regen*. 2014;22:688–693.
- Lavery LA, Fulmer J, Shebetka KA, et al.; Grafix Diabetic Foot Ulcer Study Group. The efficacy and safety of Grafix® for the treatment of chronic diabetic foot ulcers: results of a multi-centre, controlled, randomised, blinded, clinical trial. *Int Wound J*. 2014;11:554–560.
- Zelen CM, Gould L, Serena TE, et al. A prospective, randomised, controlled, multi-centre comparative effectiveness study of healing using dehydrated human amnion/chorion membrane allograft, bioengineered skin substitute or standard of care for treatment of chronic lower extremity diabetic ulcers. *Int Wound J*. 2015;12:724–732.
- Zelen CM, Serena TE, Gould L, et al. Treatment of chronic diabetic lower extremity ulcers with advanced therapies: a prospective, randomised, controlled, multi-centre comparative study examining clinical efficacy and cost. *Int Wound J*. 2016;13:272–282.
- Matuska AM, McFetridge PS. The effect of terminal sterilization on structural and biophysical properties of a decellularized collagen-based scaffold; implications for stem cell adhesion. *J Biomed Mater Res B Appl Biomater*. 2015;103:397–406.
- Woo KY, Sibbald RG. A cross-sectional validation study of using NERDS and STONEES to assess bacterial burden. *Ostomy Wound Manage*. 2009;55:40–48.
- Sheehan P, Jones P, Caselli A, et al. Percent change in wound area of diabetic foot ulcers over a 4-week period is a robust predictor of complete healing in a 12-week prospective trial. *Diabetes Care*. 2003;26:1879–1882.
- Moher D, Hopewell S, Schulz KF, et al.; Consolidated Standards of Reporting Trials Group. CONSORT 2010 Explanation and Elaboration: updated guidelines for reporting parallel group randomised trials. *J Clin Epidemiol*. 2010;63:e1–37.
- Cohen J. *Statistical Power Analysis for the Behavioral Sciences*. Hillsdale, NJ: Erlbaum; 1988.
- Rodríguez-Ares MT, López-Valladares MJ, Touriño R, et al. Effects of lyophilization on human amniotic membrane. *Acta Ophthalmol*. 2009;87:396–403.
- Cooke M, Tan EK, Mandrycky C, et al. Comparison of cryopreserved amniotic membrane and umbilical cord tissue with dehydrated amniotic membrane/chorion tissue. *J Wound Care*. 2014;23:465–474, 476.
- Mrázová H, Koller J, Fujeříková G, et al. Structural changes of skin and amnion grafts for transplantation purposes following different doses of irradiation. *Cell Tissue Bank*. 2014;15:429–433.
- Mrázová H, Koller J, Kubišová K, et al. Comparison of structural changes in skin and amnion tissue grafts for transplantation induced by gamma and electron beam irradiation for sterilization. *Cell Tissue Bank*. 2016;17:255–260.
- Paolin A, Trojan D, Leonardi A, et al. Cytokine expression and ultrastructural alterations in fresh-frozen, freeze-dried and γ -irradiated amniotic membranes. *Cell Tissue Bank*. 2016;17:399–406.
- Zelen CM, Orgill DP, Serena T, et al. A prospective, randomised, controlled, multicentre clinical trial examining healing rates, safety and cost to closure of an acellular reticular allogenic human dermis versus standard of care in the treatment of chronic diabetic foot ulcers. *Int Wound J*. April 12, 2016. Epub ahead of print. DOI: 10.1111/iwj.12600
- Frykberg RG. Diabetic foot ulcers: pathogenesis and management. *Am Fam Physician*. 2002;66:1655–1662.
- Khan NA, Rahim SA, Anand SS, et al. Does the clinical examination predict lower extremity peripheral arterial disease? *JAMA*. 2006;295:536–546.