What is the contrast-filled structure seen during right ventriculography?

P. 639

Answer: A

During right ventriculography (Fig. 1, Video 1), it was noted that the contrast agent injected through the catheter did not fill the right ventricular (RV) cavity very well. Instead, it initially stained the RV myocardium and gradually formed a pouch within the RV wall. It appears that the catheter was inadvertently engaged into a thebesian vein and the contrast agent, which was injected with high pressure (600 psi), first opacified the thebesian venous system (thin arrows) and eventually formed a venous lake within the RV wall (thick arrow). Ventricular tachycardia was also noted during the formation of intramyocardial pouch. Immediately after the first recorded image, contrast agent was found to have drained into the pericardial space, and there was no persistent staining of myocardium (Fig. 2, Video 2). Hemodynamics of the patient did not deteriorate. Echocardiographic imaging in a cath lab revealed small pericardial effusion without signs of tamponade (Fig. 3, Video 3). Procedure was completed with left heart catheterization and aortography as planned. The patient remained stable, and pericardial effusion did not increase during post-procedural hospital stay of 2 days.

Thebesian venous system was first described in the 18th century as "vaso cordis minimae." These veins form a "lesser" venous system that accounts for 5%–10% of venous drainage of the myocardium. In contrast to epicardial venous system, thebesian veins drain venous blood directly into the adjacent chamber. In other words, they provide direct connections between cardiac chambers and coronary venous system. Unintentional cannulation of thebesian veins with or without subsequent perforation was previously reported (1–3). Specifically, catheters that have a straight distal tip, such as Multipurpose, Amplatz, Judkins, Tiger, Jackie, and NIH, have a tendency to cannulate these small veins. Therefore, it is of vital importance to check the position of the catheter tip with a small amount of contrast injection prior to ventriculography with power injectors. Fortunately, such a complication was very unlikely to occur with pigtail catheter, which should be chosen in the first place.

Diverticulum is a rare outpouching of the ventricular cavity. It is generally regarded as an accessory chamber. Its wall consists of normal myocardium and show synchronous systolic contraction with the ventricle. It is more frequently observed in the left rather than the right ventricle. It frequently originates from the apex or anterosuperior free wall in RV. Those originating from apex are finger-shaped with a narrow neck, whereas others originating from anterosuperior wall have a broad base and a trabeculation pattern similar to RV cavity.

Pseudoaneurysm, generally observed in the left ventricle after myocardial infarction, is very seldom observed in RV. RV pseudoaneurysm may develop after penetrating chest trauma and iatrogenic perforations (due to catheterization, pacemaker implantation, and endomycardial biopsy). It appears (in ventriculography or computed tomography) as a contrast-filled round sac connected to the RV cavity with a narrow neck.

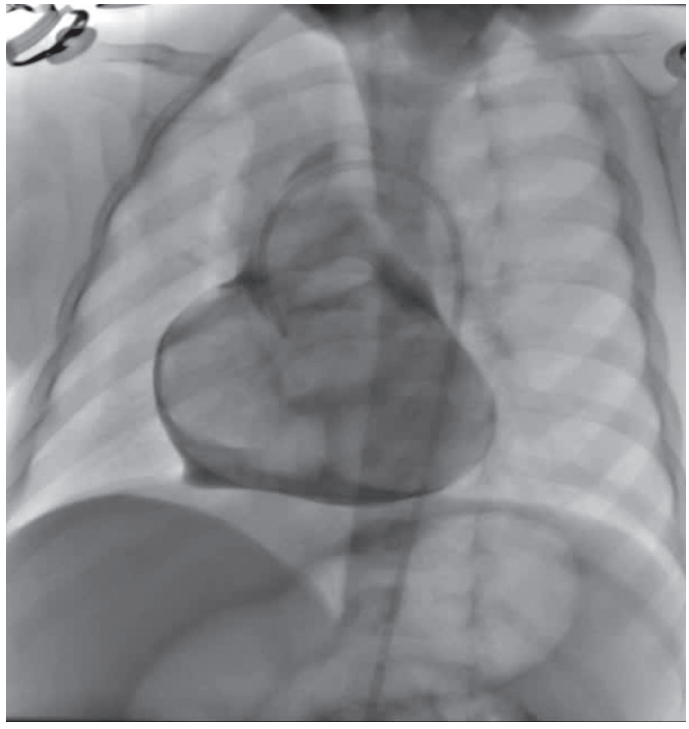

Figure 2. A still image immediately after right ventriculography showing contrast agent drained into pericardial space

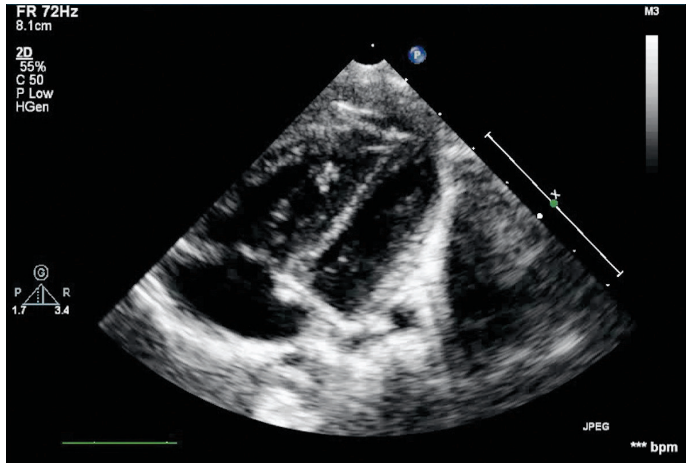

Figure 3. Echocardiographic image showing minimal pericardial effusion

Coronary arteriovenous malformation is defined as an abnormal communication between a coronary artery and a venous structure in circulation. The most common arterial site is the right coronary artery followed by the left anterior descending artery. Common venous sites (in descending order of frequency) are RV, right atrium, pulmonary artery, coronary sinus, and superior vena cava. Instead of a ventricular outpouching, it is usually seen as a convoluted vascular structure between arterial and venous system (using coronary angiography or computed tomography).

The presence of RV outflow tract obstruction and hypertrophy played a protective role in this case. While hypertrophic RV limited perforation by systolic contraction, increased RV pressure resisted imminent pericardial tamponade. The patient underwent elective cardiac surgery for tetralogy of Fallot without any complications. Operative findings were consistent with angiographic diagnosis.

Burak Turan, Onur Çağlar Acar*
Departments of Cardiology, *Pediatric Cardiology, Kocaeli Derince Training and Research Hospital; Kocaeli-*Turkey*

Video 1. Right ventriculography with NIH catheter (Supertorque Plus, Cordis Corp.).
Video 2. Aortography showing contrast agent drained into pericardial space.
Video 3. Echocardiographic cine loop showing minimal pericardial effusion and absence of apparent tamponade.

References

1. Judkins C, Yamen E. Inadvertent thebesian vein cannulation during radial access ventriculography. JACC Cardiovasc Interv 2013; 6: e9-10.
2. Frizzell JD, Alkouz M, Sheldon MW. Left ventricular perforation during ventriculogram using an optitorque tiger catheter. JACC Cardiovasc Interv 2014; 7: 1456-7.
3. Gach O, Lempereur M, Eeckhout E, Legrand V. Unintentional "ventriculo-phlebo-myo-pericardiography". JACC Cardiovasc Interv 2014; 7: 577-8.

From Prof. Dr. Arif Akşit's collections