

## CASES FOR DIAGNOSIS

# Painful Nodule on the Sole of the Foot

J. Concheiro, J.A. Labandeira, and J. Toribio

Servicio de Dermatología, Complejo Hospitalario Universitario, Facultad de Medicina, Santiago de Compostela, A Coruña, Spain

### Clinical History

The patient was a 50-year-old waiter with no personal or family history of interest, who was seen for a lesion that was painful on walking. The lesion was on the sole of the right foot, had been present for 8 months, and had not resolved spontaneously. The patient denied any local trauma. He occasionally used nonsteroidal anti-inflammatory drugs for analgesia.

### Physical Examination

On the medial aspect of the middle third of the sole of the right foot there was a faintly palpable, annular, subcutaneous lesion with a diameter of 5 cm and with erythematous patches, some of which were covered by small hemorrhagic scabs (Figure 1).

There were no other lesions on examination of the rest of the skin.

### Histopathology

Biopsy of one of the erythematous areas revealed a well-defined area in the middle and deep dermis (Figure 2) with an abundance of eccrine sweat glands of normal morphology and vascular structures with occasional dilatations (Figure 3).

### What Was the Diagnosis?

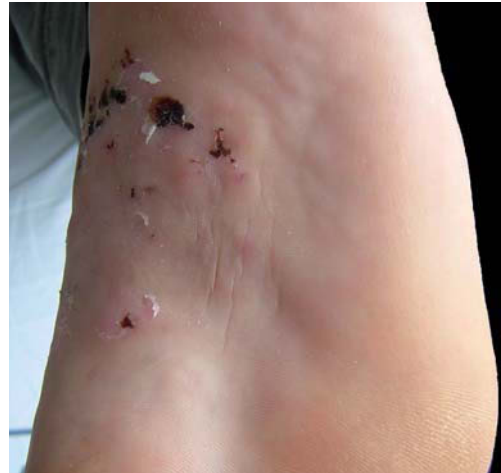

Figure 1.

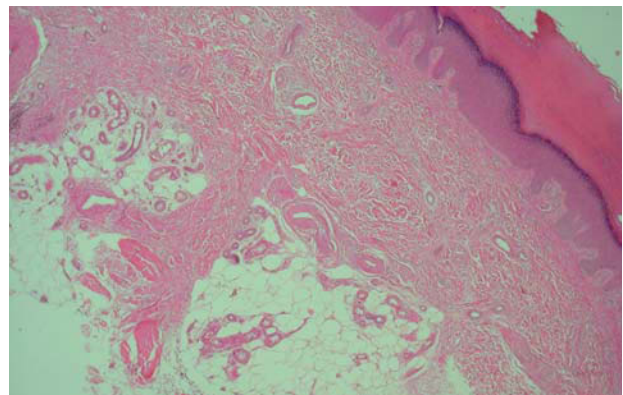


Figure 2. Hematoxylin-eosin,  $\times 10$ .

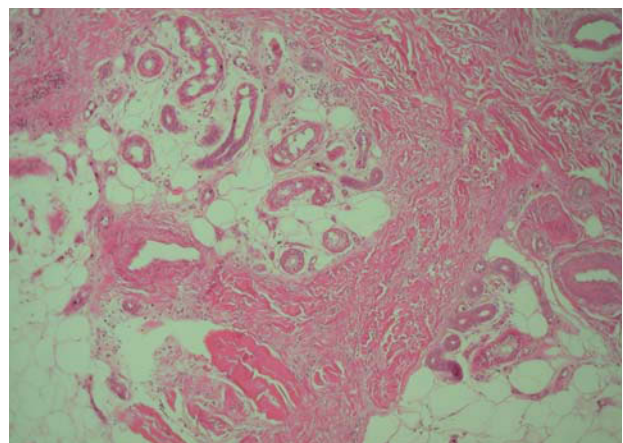


Figure 3. Hematoxylin-eosin,  $\times 60$ .

Correspondence:  
Javier Concheiro  
Departamento de Dermatología  
Facultad de Medicina  
C/ San Francisco, s/n  
15782 Santiago de Compostela, A Coruña, Spain  
mejaim@usc.es

Manuscript accepted for publication February 28, 2008.

## Diagnosis

Eccrine angiomatous hamartoma.

## Clinical Course and Treatment

As this was a stable, benign lesion, the patient declined treatment after explanation of the various therapeutic options, and decided to continue under observation.

## Discussion

Eccrine angiomatous hamartoma is a rare, benign lesion characterized by a proliferation of eccrine structures and vascular elements, usually capillaries, in the middle and deep dermis. The term was conceived by Hyman et al<sup>1</sup> in 1968, although cases had been reported previously using similar names,<sup>2</sup> and the first description was probably by Lotzbeck in 1859.<sup>3</sup> This is a very rare condition, with only 47 well-documented cases in the literature. It affects men and women equally and is congenital in up to 45% of cases; it rarely presents in adults.<sup>4</sup>

Clinically, the condition usually presents on the lower limbs as a single tumor lesion, which is very often subcutaneous; there may be multiple lesions. It can also affect other sites<sup>4</sup> and can even have a linear distribution. Lesions may be associated with other local disorders, such as hypertrichosis and, in a third of cases, hyperhidrosis, pain, or dysesthesia.

The diagnosis is mainly histopathologic<sup>4,5</sup> and is based on the Hyman criteria,<sup>1</sup> which describe this condition as hyperplasia of dilated or normal eccrine glands in association with foci of angiomatous capillaries, and with a variable presence of hair, lipomatous, mucinous, or lymphatic structures. A new variant has recently been described, with characteristics of an arteriovenous malformation.<sup>6</sup> The immunohistochemical characteristics

are similar to those observed in normal eccrine glands and vascular structures.<sup>4,5</sup>

Although their origin is uncertain, the congenital form is thought to involve a defective biochemical interaction between the differentiated epithelium and the underlying mesenchyme during early organogenesis, leading to a proliferation of abnormal adnexal and vascular structures. Late onset lesions are related to recurrent trauma.<sup>3,4</sup>

The clinical differential diagnosis includes numerous conditions, such as vascular malformations, glomus tumors, and other hamartomas. Histologically the lesions must be differentiated from eccrine nevus and sudoriparous angioma. Eccrine nevus is associated with eccrine gland hyperplasia but there is no associated capillary proliferation, and sudoriparous angioma has a predominant vascular component, formed mostly of larger vessels, together with dilatation but not proliferation of the eccrine glands.<sup>4,5</sup>

Surgical treatment by excision is indicated in symptomatic cases; in view of the benign nature of the condition, other lesions may be kept under observation. Analgesics only give temporary relief. Spontaneous regression has been reported.<sup>3-5</sup>

## References

1. Hyman AB, Harris H, Brownstein MH. Eccrine angiomatous hamartoma. *N Y State J Med.* 1968;68:2803-6.
2. Issa OA. Hamartoma angiomatoso sudoríparo funcionante. *Actas Dermosifiliogr.* 1964;55:361-5.
3. Foshee JB, Grau RH, Adelson DM, Crowson N. Eccrine angiomatous hamartoma in an infant. *Pediatr Dermatol.* 2006;23:365-8.
4. Pelle MT, Pride HB, Tyler WB. Eccrine angiomatous hamartoma. *J Am Acad Dermatol.* 2002;47:429-35.
5. Cebreiro C, Sánchez-Aguilar D, Gómez Centeno P, Fernández-Redondo V, Toribio J. Eccrine angiomatous hamartoma: report of seven cases. *Clin Exp Dermatol.* 1998;23:267-70.
6. Chien AJ, Asgari M, Argenyi ZB. Eccrine angiomatous hamartoma with elements of an arterio-venous malformation: a newly recognized variant. *J Cutan Pathol.* 2006;33:433-6.