

## Predictive Factors for the Evolution of Reactive Arthritis to Ankylosing Spondylitis

SIMONA BANICIOIU-COVEI<sup>1</sup>, F.A. VREJU<sup>1</sup>, PAULINA CIUREA<sup>1</sup>

<sup>1</sup>University of Medicine and Pharmacy of Craiova, Department of Rheumatology

**ABSTRACT:** Purpose: The goal of this study is to identify the predictive factors involved in the evolution of the reactive arthritis to ankylosing spondylitis by following the presence and degree of sacroiliitis and also the appearance of acute anterior uveitis. Material and Methods: The study was performed between 01.01.2011-31.12.2014 on 112 patients, aged between 17 and 47 years old, in evidence of the Rheumatology Clinic of the Clinical Hospital Emergency Craiova. The patients were divided in 2 lots according to the radiological criteria: the first lot included 52 patients diagnosed with reactive arthritis, with the determination of the pathogen agent involved and the demonstration of sacroiliitis first degree by Nuclear Magnetic Resonance (IRM). The second lot included a number of 60 patients diagnosed with reactive arthritis, without presenting significant changes in the sacroiliac joints and at the cervico-dorsal-lumbar spine. Results: In the first batch, the performance of the IRM and monitoring the patients every 6 months over 3 years revealed the progression of sacroiliitis from first degree in which it was at the moment of diagnosing at second degree in a 6 month period. Three years after initiation of therapy for reactive arthritis, the patients from the second batch responded favorably to treatment, the performance of imaging not revealing signs of sacroiliitis. Conclusion: Association of sacroiliitis at baseline proved to be a negative prognostic factor in reactive arthritis, which can suggest the evolution to ankylosing spondylitis, monitoring these patients being necessary for at least 3 years from the point of diagnosing.

**KEYWORDS:** reactive arthritis, sacroiliitis, ankylosing spondylitis

### Introduction

Spondyloarthritis defined a group of inflammatory joint diseases which have a genetical, clinical and progressive profile, different from the one of the rheumatoid arthritis.

Ankylosing spondylitis is an inflammatory chronic systemic disease, which affects predominantly the sacroiliac joints and the axial skeleton, associating important peripheral joint involvement and extraarticular features such as: acute anterior uveitis, pulmonary fibrosis of the superior lobes, aortic insufficiency, neurological and renal impairment. Sacroiliitis, which is the result of the affected area of synovial joints from lower 2/3, inflammatory condrites and subchondral osteitis, may represent the first radiological change, modifications being simetrical in time which will allow stadialization. Sacroiliitis is an important characteristic of the spondiloarthritis group, but it appears more frequently in ankylosing spondylitis in comparison with reactive arthritis or psoriatic arthritis.

Reactive arthritis is defined as an affection which appears after an interval of 1-4 weeks from an infection with an enteral or urogenital gateway at patients with HLA-B27 antigen present. Infectious factors are represented by a set of bacteria such as Salmonella, Shigella, Campylobacter jejuni, which cross the gastrointestinal mucosal barrier and its bacterial

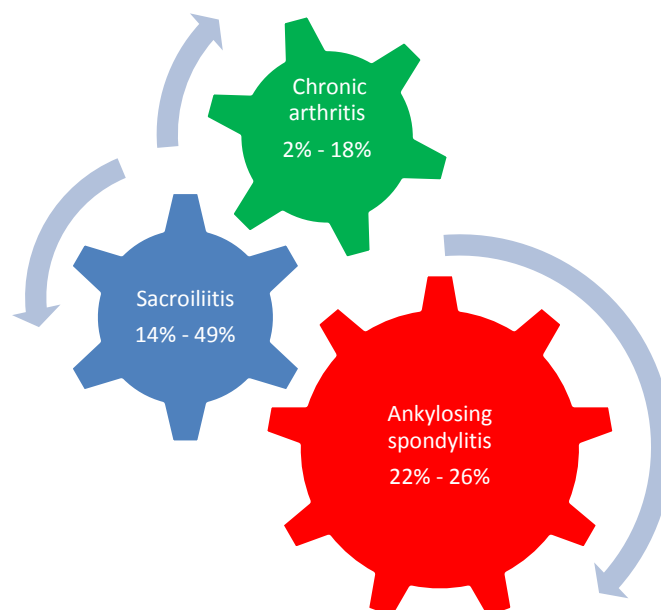
components become rezident in the joints. The etiology of trigger infection arthritogenic may influence the prognosis so Chlamydia predisposes to chronic evolution in 70% of patients with urethritis [1].

Acute anterior uveitis represents an inflammatory infection of the uveal tract, frequent in spondilarthritis group, which manifests itself through eye pain, rash, photophobia, excessive tearing and diminishing eyesight.

A characteristic lesion of spondiloarthritis is enthesitis. In spondiloarthritis, the most affected entheses are: achilian, patellar and the ones from the ischial tuberosity. In terms of ultrasound, in grayscale, enthesitis is defined as a loss of echostructure normal fibrillar of the tendons at the insertion, heterogeneous structure, irregular edges and their thickening.

Evolution of the reactive arthritis is influenced also by the type of the infectious trigger. Thereby, reactive arthritis can transform itself in chronic arthritis with an incidence from 2% to 18% of cases, with the presence of sacroiliitis between 14% and 49% of cases. We may consider an evolution to ankylosing spondylitis in 22% to 26% of cases [3].

The aim of this study is to analyze the possibility of evolution of reactive arthritis to ankylosing spondylitis by following the progression of sacroiliitis and the appearance of acute anterior uveitis.



**Fig. 1. Relationships in the evolution of the reactive arthritis to ankylosing spondylitis**

## Materials and Methods

The study was performed between 01.01.2011- 31.12.2014 on 112 patients, aged between 17 and 47 years old, in evidence of the Rheumatology Clinic of the Clinical Hospital Emergency Craiova. The patients were divided in 2 lots according to the radiological criteria: the first lot included 52 patients diagnosed with reactive arthritis, with the determination of the pathogen agent involved and the demonstration of sacroiliitis first degree by Nuclear Magnetic Resonance (IRM). The second lot included a number of 60 patients diagnosed with reactive arthritis, without presenting significant changes in the sacroiliac joints and at the cervico-dorsal-lumbar spine. The study was realised according to the ethical principles issued by „Declaration of Human Rights” from Helsinki, approved by the ethics committee and all the patients signed the informed consent.

There were noted historical data of the patients, disease duration, the results of the complete clinical examination, of the ophthalmological consult and of the imagistic explorations (Nuclear Magnetic Resonance, conventional radiography of the sacroiliac joints and the cervico-dorsal-lumbar spine, cord-lung radiography, musculoskeletal ultrasound). Biological explorations included normal samples, determining the pathogen agents involved and the HLA-B27 antigen detection.

At the IRM examination, erosions and subchondral sclerosis could be mostly observed

in the slope iliac. In order to appreciate the sacroiliac joints status, the New York scale was used which is: degree 0- normal, degree 1- suspicion, without specific radiological changes, degree 2- minimum sacroiliitis: bone contours faded through subchondral bone resorption, with fake enlargement and discrete sclerosis, degree 3- moderate sacroiliitis, osteocondensation through osteosclerosis slopes articular, which have jagged edges, in „postage stamp”, degree 4- anchilosis: disappearance of the joint space with a complete fusion through bone bridges of the 2 iliac slopes.

IRM, in sequences T1, T2, STIR (Short TI Inversion Recovery) and post contrast, was the imagistical investigation with the highest sensibility (95%), in early identification of structural alterations from the sacroiliac joints [6].

The pathogens most frequently involved were in proportion of 99% represented by *Chlamydia trachomatis* and 1% by *Ureaplasma Urealyticum*. *Chlamydia trachomatis* was detected through polymerase chain test. For the diagnosis of HLA-B27 antigen through the lymphocyte cytotoxicity assay, there were used microtiter plates with the anti- HLA-B27 serum applied in wells. For determining *Ureaplasma*, it was used PCR analysis, which demonstrates the DNA of the germs.

The ophthalmic assessment included assessment of visual acuity, fundus examination and measuring intraocular pressure. Additionally, it was performed a slit-lamp examination: it was

examined the cornea through direct illumination with a beam angle of 30- 40 degree between the microscope and the source of light. It was scanned the endothelium for precipitated keratolytic, iritis brand. The most important structure to examine was the anterior room, which was in contact with the cornea and the iris and occupied with aqueous humor. Normally, the aqueous humor is optically clear, but in this case there could be seen white and red spots, being noted on a scale from 1 to 4.

The ultrasound evaluation of entheses was performed with the help of the transducer in longitudinal position in the quadriceps, patellar (proximal and distal), achilean tendons and in the plantar aponeurosis. The reference cut-off sizes were below 6 mm for quadriceps at the insertion of patella, under 4 mm for the patellar tendon, at the superior insertion on the patella and also at the inferior insertion on the tibial tuberosity, under 5 mm- the achilian tendon, at the insertion on the calcaneus and < 4 mm for the plantar aponeurosis at the insertion on the calcaneus. The dimensions are approximate and they corelate with the body mass index [4].

The historical data of the patients, the clinical ones obtained at the phisical examination and the results of the paraclinical examination according to the study protocol were noted at the moment on inclusion, at planned intervals and at the end of the study, being introduced in a data base performed in Excel programme (from the

Microsoft package), compatible with all the programs of statistic interpretation which we used in analysing the information we collected. Filling in the data was realised with the help of the information obtained during unexpected controls related to the evolution of the disease.

The processing was made with the help of Cross, Basic Tables commands, corelate, regression, Factor Analysis and the Data Analysis modul of the Excel package, as well as with the help of Analysis modul of the EPI2000 programme (graphic, tabels and statistic tests). Comparing means was done with the help of the following tests: Student, Wilcoxon, Kruskal-Wallis.

The interpretation of the tests comparing averages, Anova, Student, Wilcoxon, Kruskal-Wallis:

$P < 0,05$ , the difference is significant( s)

$P < 0,01$ , the difference is highly significant( hs)

$P > 0,05$ , the difference is insignificant( ns)

The interpretation of P values at dependence tests of factors:

$P < 0, 05$ , the dependence between the two factors is significant( s)

$P < 0,01$ , the dependance is highly significant( hs)

$P < 0,001$ , the dependance is very high significant( vhs)

$P > 0,05$ , the dependance is insignificant( ns)

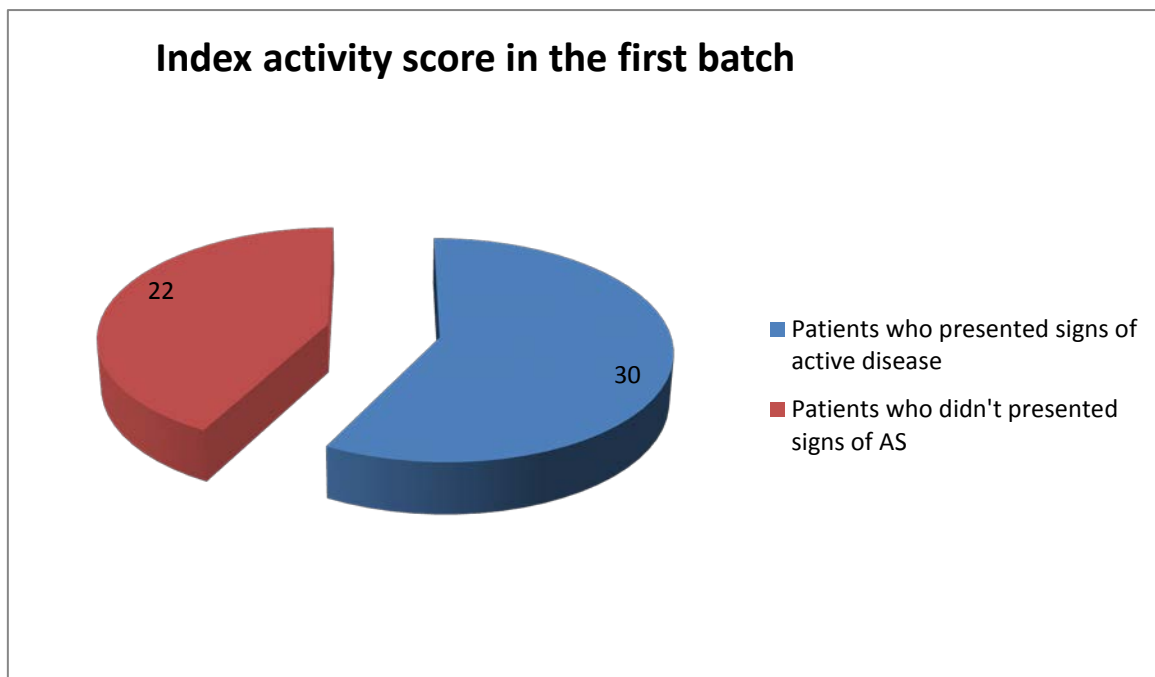


Fig.2. Index activity score in the first batch

**Results**

The progression of sacroiliitis to degree 3-4 unilaterally or 2 bilaterally after approximately 2 years after diagnosing reactive arthritis in the case of the first batch of patients allowed setting the diagnosis of ankylosing spondylitis.

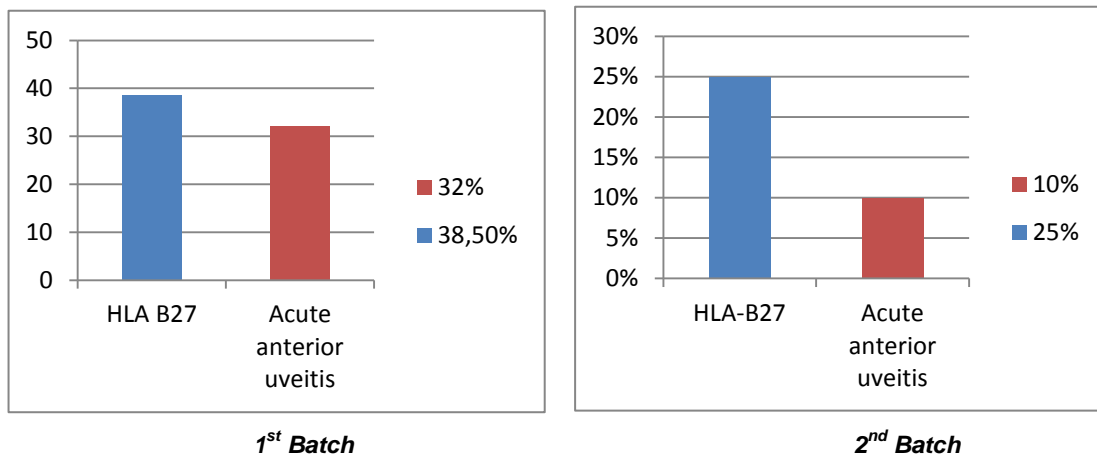
In case of the first batch, the HLA-B27 antigen was identified at 20 patients (38,5%) and 17 of the patients (32%) were diagnosed with acute anterior uveitis, in attacks lasting 4-8 weeks at approximately half of those with recurrences, alternating at both eyes.

As far as the disease activity, from the 52 patients who were included in this batch, 30 of them presented signs of active disease defined according to the Bath Ankylosing Spondylitis Disease Activity Index (BASDAI)  $\geq 5$  and the growth of C-reactive protein.

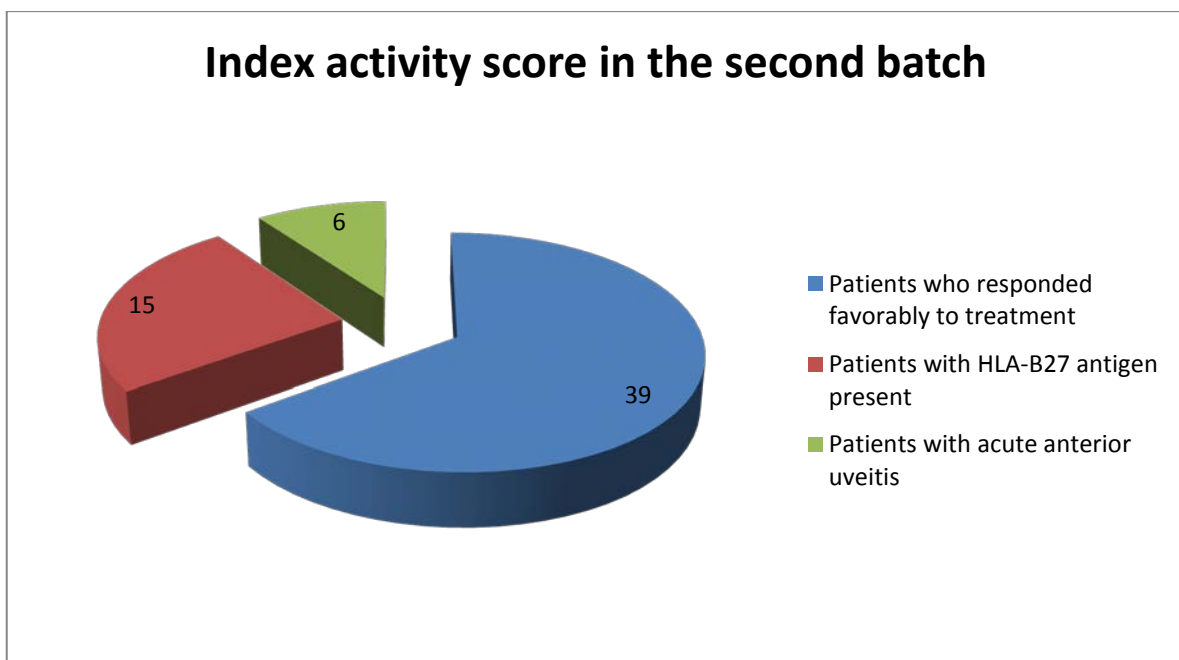
When it comes to the second batch, at 3 years from the initiation of treatment for reactive arthritis, 39 patients (65%) responded favorably to the treatment, the imaging explorations performed did not detect significant changes at sacroiliac joints, as well as at the cervico-dorsal-lumbar spine in comparison with the evaluation at baseline.

The rest of 21 patients (35%) had the same therapeutic response, but at 15 patients (71,4%) it was found the HLA-B27 antigen and 6 of the patients (29,6%) presented signs of acute anterior uveitis.

From the total of 60 patients, 21 of them (35%) had a curling evolution, with repetitive episodes of arthritis, accompanied by lumbosacral pain and persistent heels pain.



**Fig.3. Percentage expression of the pathological changes occurring in the groups of patients**



**Fig.4. Index activity score in the second batch**

## Discussions

Spondiloarthritis, idea introduced in 1974 by Moll and Wright, are defined as inflammatory arthropathies characterised by the affection of sacroiliac joints and the association with HLA-B27. The group of spondiloarthritis include the following affections: ankylosing spondylitis, reactive arthritis, psoriatic arthritis, enteropathic arthritis and undifferentiated spondiloarthritis.

The spondiloarthritis group is based on an ensemble of clinical and radiological elements, which appear mostly at subjects with familial aggregation and a ground for HLA-B27 [2]. The clinical criteries are dominated by the buttock pain or the pain localised at the spinal column, having specific elements of inflammatory causes, by the peripheral oligoarthritis localized at the legs, by the clinical symptoms resulted from the inflammatory affection of entheses, by the extraarticular events such as: mucocutaneous, cardiac, ocular and intestinal. The radiological characteristic is in particular unilaterally or bilaterally sacroiliitis, but also the presence of bony spikes localised at the calcaneus, the iliac crest, the ischiatic tuberosity, etc., result of enthesitis [5]. The positive diagnosis allowed introduction in the European Study Group of Spondiloarthropathies (ESSG), which appeared in 1991 and included also the undifferentiated spondiloarthritis.

In the case of the first batch, it was necessary to identify a possible predictive role of the presence of sacroiliitis for the progression of reactive arthritis to ankylosing spondylitis by monitoring patients with arthrites for at least 3 years from the point of diagnosis, every 6 months.

The presence with an increase frequency of uveitis at aproximaly 32% of the patients may be suggestive for the evolution to ankylosing spondylitis.

One of the conclusions derived from the study T. C. Mitulescu et al performed and published in 2014 shows that acute anterior uveitis HLA-B27+ represents the most frequent and characteristic extraarticular feature of ankylosing spondylitis [7].

In the case of the second batch, at 3 years from initiating therapy for reactive arthritis, the patients responded favorably to the treatment, fact confirmed by the absence of significant changes at the radiological and IRM

explorations in the sacroiliac joints as well as at the cervico-dorsal- lumbar spine.

In this study performed, the association of sacroiliitis proved to be a negative prognostic factor in reactive arthritis alongside the presence of acute anterior uveitis, facts that make necessary monitoring patients with reactive arthritis on the course of at least 3 years after diagnosing.

## Conclusions

1. Sacroiliitis at baseline demonstrated by the imagistic explorations proved to be a predictive factor for the evolution of reactive arthritis to ankylosing spondylitis.

2. Acute anterior uveitis is considered to be a negative prognostic factor at patients with reactive arthritis.

3. Chlamydia trachomatis and Ureaplasma Urealyticum proved to be the most frequent pathogen agents involved in the evolution of reactive arthritis to ankylosing spondylitis.

## Acknowledgements

"This paper was published under the frame of European Social Found, Human Resources Development Operational Programme 2007-2013, project no. POSDRU/159/1.5/S/136893".

## References

1. Fendler C, Laitko S, Sorensen H, et al: Frequency of triggering bacteria in patients with reactive arthritis and undifferentiated oligoarthritis and the relative importance of the tests used for diagnosis, *Ann Rheum Dis* 60:337-343,2001
2. Garg N, van den Bosch F, Deodhar A : The concept of spondyloarthritis: where are we now? *Best Pract Res Clin Rheumatol*. 2014 Oct;28(5):663-72
3. Inman RD, Chiu B: Cytokine profiles in the joint define pathogen clearance and severity in Chlamydia-induced arthritis. *Arthritis Rheum* 2006; 54:499-507.
4. Fodor Daniela: *Ecografie musculo-scheletala*, Editura Medicala, Bucuresti, 2009.
5. Rudwaleit M, van der Heijde D, Landewe R, et al: The Assessment of SpondyloArthritis , international Society classification criteria for peripheral spondyloarthritis and for spondyloarthritis in general, *Ann Rheum Dis* 70: 25- 31, 2011
6. Shaikh SA. Ankylosing spondylitis: recent breakthroughs in diagnosis and treatment. *The Journal of the Canadian Chiropractic Association*. 2007;51(4):249-260.
7. Mitulescu T.C., Dimănescu Monica, Predețeanu Denisa, Voinea Liliana-Mary: Rolul TNF- $\alpha$  in uveita asociata cu spondilita anchilozanta- de la patogenie la tratament, *Revista Romana de Reumatologie*, 2014, XXIII (3)