

# European consensus on diagnosis and treatment of germ cell cancer: a report of the European Germ Cell Cancer Consensus Group (EGCCCG)

H. J. Schmoll<sup>1\*</sup>, R. Souchon, S. Krege, P. Albers, J. Beyer, C. Kollmannsberger, S. D. Fossa, N. E. Skakkebaek, R. de Wit, K. Fizazi, J. P. Droz, G. Pizzocaro, G. Daugaard, P. H. M. de Mulder, A. Horwich, T. Oliver, R. Huddart, G. Rosti, L. Paz Ares, O. Pont, J. T. Hartmann, N. Aass, F. Algaba, M. Bamberg, I. Bodrogi, C. Bokemeyer, J. Classen, S. Clemm, S. Culine, M. de Wit, H. G. Derigs, K. P. Dieckmann, M. Flasshove, X. Garcia del Muro, A. Gerl, J. R. Germa-Lluch, M. Hartmann, A. Heidenreich, W. Hoeltl, J. Joffe, W. Jones, G. Kaiser, O. Klepp, S. Kliesch, L. Kisbenedek, K. U. Koehrmann, M. Kuczyk, M. P. Laguna, O. Leiva, V. Loy, M. D. Mason, G. M. Mead, R. P. Mueller, N. Nicolai, G. O. N. Oosterhof, T. Pottek, O. Rick, H. Schmidberger, F. Sedlmayer, W. Siegert, U. Studer, S. Tjulandin, H. von der Maase, P. Walz, S. Weinknecht, L. Weissbach, E. Winter & C. Wittekind

<sup>1</sup>Martin-Luther-University, Department of Hematology/Oncology, Halle, Germany

Received 26 September 2003; revised 2 March 2004; accepted 2 March 2004

Germ cell tumour is the most frequent malignant tumour type in young men with a 100% rise in the incidence every 20 years. Despite this, the high sensitivity of germ cell tumours to platinum-based chemotherapy, together with radiation and surgical measures, leads to the high cure rate of  $\geq 99\%$  in early stages and 90%, 75–80% and 50% in advanced disease with ‘good’, ‘intermediate’ and ‘poor’ prognostic criteria (IGCCCG classification), respectively. The high cure rate in patients with limited metastatic disease allows the reduction of overall treatment load, and therefore less acute and long-term toxicity, e.g. organ sparing surgery for specific cases, reduced dose and treatment volume of irradiation or substitution of node dissection by surveillance or adjuvant chemotherapy according to the presence or absence of vascular invasion. Thus, different treatment options according to prognostic factors including histology, stage and patient factors and possibilities of the treating centre as well may be used to define the treatment strategy which is definitively chosen for an individual patient. However, this strategy of reduction of treatment load as well as the treatment itself require very high expertise of the treating physician with careful management and follow-up and thorough cooperation by the patient as well to maintain the high rate for cure. Treatment decisions must be based on the available evidence which has been the basis for this consensus guideline delivering a clear proposal for diagnostic and treatment measures in each stage of gonadal and extragonadal germ cell tumour and individual clinical situations. Since this guideline is based on the highest evidence level available today, a deviation from these proposals should be a rare and justified exception.

**Key words:** consensus on diagnosis and treatment, germ cell tumour, testicular cancer

## Introduction

During the past two decades germ cell cancer has become the ‘model’ of a curable neoplasm. The major factor for the high cure rate is the high level of sensitivity of germ cell cancer to

a variety of chemotherapeutic agents, in particular to cisplatin. Further aspects have also been important for the development of the current treatment standards of germ cell cancer, in particular, well-designed and well-conducted prospective randomised trials highlighting clinically relevant questions in surgical, radiotherapeutic and chemotherapeutic management of germ cell cancer, as well as the integration of interdisciplinary management into the treatment and clinical research of these patients. Therefore, a large body of evidence from clinical trials exists that allows physicians and patients to choose

---

\*Correspondence to: European Germ Cell Cancer Consensus Group (EGCCCG), c/o Prof. Hans-Joachim Schmoll, Martin-Luther-University, Department of Hematology/Oncology, Ernst-Grube-Str. 40, 06120 Halle, Germany. Tel: +49-345-5572924; E-mail: hans-joachim.schmoll@medizin.uni-halle.de

**Table 1.** Hierarchy of scientific evidence (declining from level IA to IV) according to the definition of US Agency for Health Care Policy and Research by use of the Cochrane Collaboration [2]

Level	Sources and characteristics of evidence
IA	Evidence obtained from meta-analysis of randomised clinical controlled trials (RCT) and systematic reviews of RCT
IB	Evidence obtained from at least one RCT
IIA	Evidence obtained from at least one well-designed controlled study without randomisation
IIB	Evidence obtained from at least one other type of well-designed quasi-experimental study
III	Evidence obtained from well-designed non-experimental descriptive studies, such as comparative studies, correlation studies and case studies
IV	Evidence obtained from expert committee reports or opinions and/or clinical experience of respected authorities without transparent proof

between different treatments which offer the best curative option with the least amount of toxicity. However, due to the multitude of available treatment options, decision making regarding the optimal management of a patient has become more complicated. This applies in particular to patients with early stage disease who are often cured with minimal intervention and who are at risk of being overtreated. Likewise, patients with advanced, relapsed or refractory disease are difficult to treat and may not always receive optimal medical care.

Germ cell cancer is a rare disease that needs expert treatment. Clear evidence has emerged that, in particular, patients with advanced germ cell cancer benefit from the expertise of their managing physician with improved survival [EBM III: 1]. {Evidence-based medicine (EBM): definitions of the levels and characteristics of evidence originate from the US Agency for Health Care Policy and Research [2]. Evidence of the statements given in this paper are based on the criteria listed in Table 1.} This expertise is dependent on the experience of the physician which is probably best indicated by the number of patients treated in the department [EBM III: 1]. A large patient volume resulting in competence and experience even with rare clinical scenarios is crucial and most patients being referred to national reference centres with special experience in the field of germ cell cancer benefit from the expertise. However, of equal importance is that clear, comprehensive and up-to-date consensus guidelines are available which represent the current 'state of the art' in diagnosis and treatment of germ cell cancer. Therefore the European Germ Cell Cancer Consensus Group (EGCCCG) has developed the following guidelines which identify the current standards in diagnosis and treatment of germ cell cancer based on the available evidence published so far.

## Patients and methods

On 22–23 November 2002, the European Consensus Conference on the Diagnosis and Treatment of Germ Cell Cancer was organised by the German Testicular Cancer Study Group (GTCSG) in Essen, Germany. Medical, radiation and urological oncologists, as well as pathologists, from several European countries were invited. The selection was based on major scientific contributions in the field of diagnosis and treatment of germ cell cancer. The purpose of this meeting was to define current 'state of the art' treatment using the methodology of evidence-based medicine (EBM) (Table 1) [2, 3]. In the 2 years prior to this meeting, members of the GTCSG had reviewed the available literature according to EBM standards and published national German guidelines on the diagnosis and treatment of germ cell cancer [4, 5]. These guidelines were sent to all the invited participants prior to the conference and served, together with two

other EBM-based guidelines from other European countries [6, 7], as a basis for the discussion. The resulting text was edited by the writing committee, reviewed and discussed by all participants. All listed participants of the EGCCCG have agreed to this final consensus paper.

## Diagnosis and staging

### Clinical presentation of germ cell cancer

The majority of patients present with primary tumour in the testis. Delay in diagnosing germ cell cancer may be caused either by patients who may ignore symptoms too long or by physicians who fail to define the correct diagnosis, e.g. misclassify a testicular mass as epididymitis [EBM III: 8] or back pain as resulting from vertebral disc problems. Therefore, a high level of suspicion should be maintained in young men with any of these clinical features. In a minority of patients the primary tumour manifestation is located extragonadally, i.e. in the retroperitoneum or in the mediastinum. About one-third of these patients will harbour intratubular germ cell neoplasia (TIN) (synonym: carcinoma in situ, CIS). In another third, ultrasonography of the testes reveals scar tissue indicating a 'burned out' testicular tumour which also has to be removed. Therefore, only one-third of these patients have definitively a primary extragonadal germ cell tumour [EBM III: 9]. In all young men with retroperitoneal, supraclavicular or mediastinal mass, an underlying germ cell cancer should always be considered [EBM III: 8–11].

The diagnosis is supported by elevated  $\alpha$ -fetoprotein (AFP) or  $\beta$ -human gonadotropin ( $\beta$ -HCG). In case of normal tumour markers and suspicious testicles, the diagnosis of germ cell cancer must be confirmed by tumour biopsy before treatment is initiated. A histology of poorly or undifferentiated carcinoma or poorly differentiated adenocarcinoma is highly suggestive of the presence of germ-cell tumours. Such histologies should undergo immunohistological evaluation, including germ cell tumour specific markers and, if possible, the expression of isochromosome i(12p) which is specific for this tumour entity.

### Diagnostic work up for a primary testicular tumour

When assessing the patient's history the following risk factors for the development of testicular tumours should be addressed: contralateral testicular tumour [EBM IIA: 12–14], undescended testis/cryptorchidism [EBM IIA: 15–17; EBM IIB: 18, 19] and testicular tumour among first-grade relatives, in particular, in the father and/or brothers [EBM IIB: 20–22].

**Table 2.** Diagnosis and staging of germ cell cancer*Markers mandatory*

- Seminoma/non-seminoma ⇒ AFP, β-HCG,
- Advanced disease ⇒ LDH in addition to AFP and β-HCG

*Markers optional:*

- For seminoma only ⇒ hPLAP, NSE

*Imaging:*

- Testicular sonography (7,5 MHz transducer)
- Chest X-ray
- CT- scan of abdomen and pelvis
- Chest CT- scan (not mandatory for seminoma stage I)
- MRI of chest and abdomen: only if contraindication for CT scan (e.g. contrast media)
- CT- scan or preferably MRI of CNS: only in advanced disease with intermediate or poor prognosis, or if symptoms
- Bone scan: only if alkaline phosphatase elevated, or symptoms
- PET scan:
  - Identify viable tissue in residual lesion ≥3 cm in advanced seminoma if determined ≥4 weeks after chemotherapy
  - Might be helpful to identify stage IIa in clinical stage I non-seminoma (only in clinical trial)

*Fertility optional:*

- total testosterone, LH, FSH, semen analysis

AFP, α-fetoprotein; CT, computed tomography; FSH, follicle-stimulating hormone; β-HCG, β-human gonadotropin; LDH, lactate dehydrogenase; LH, luteinising hormone; NSE, neurone-specific enolase; PET, positron emission tomography; PLAP, placental alkaline phosphatase.

Mandatory diagnostic examinations (Table 2) include palpation as well as determination of the serum tumour markers AFP and β-HCG [EBM IIA: 23–29]. Lactate dehydrogenase (LDH) is an important prognostic factor and should therefore also be determined prior to treatment. Neurone-specific enolase (NSE) and placental alkaline phosphatase (PLAP) can provide additional information for treatment, monitoring and follow-up of patients with advanced seminoma, but are optional and do not represent mandatory investigations. PLAP is reliable only in non-smokers as smoking interferes with measurement of PLAP. Routine determination of additional serum markers, e.g. LDH isoenzymes, is not recommended.

If ultrasonography of the testes is performed a 7.5 MHz transducer should be used [EBM IV: 23]. Other imaging procedures, i.e. magnetic resonance or positron emission tomography (PET) of the testis, should not routinely be used since their results will not alter the clinical management of the patients.

In every case of suspected testicular malignancy surgical exploration is obligatory. However, in a patient with life-threatening metastatic disease and unequivocally elevated AFP or HCG, chemotherapy must be given without any delay. In this situation orchiectomy can be postponed until the completion of chemotherapy.

**Treatment of the primary tumour***Orchiectomy*

As a rule orchiectomy is performed prior to any further treatment [EBM IIB: 30, 31]. Orchiectomy should be timely sched-

**Table 3.** Treatment of the primary testis tumour*Radical orchiectomy*

- Prior to any further treatment
- If life-threatening metastatic disease and clear diagnosis of germ cell tumour by marker elevation: start of immediate chemotherapy followed by delayed orchiectomy

*Organ preserving surgery of testis tumour to be considered in case of*

- Synchronous bilateral testis tumours
- Metachronous contralateral (second) testis tumour
- Tumour in a solitary testis and sufficient endocrine function
- At experienced centres only!

uled; in particular, there is no need for emergency surgery. In patients with life-threatening metastatic disease, up-front chemotherapy has to be given. Orchiectomy has to be postponed until completion of chemotherapy Table 3. The results of the tumour marker determination should be available prior to surgery and have to be re-evaluated thereafter to determine the half life kinetic (half life time: AFP <7 days; β-HCG <3 days).

Radical orchiectomy is performed through an inguinal incision [EBM IIA: 32, EBM IIB: 33, 34]. The tumour-bearing testicle is resected along with the spermatic cord at the level of the internal inguinal ring. In patients with negative serum tumour markers and small and possibly benign tumours, histological analysis of a frozen section should be performed prior to definitive orchiectomy to allow organ sparing surgery, particularly if a benign tumour is found [EBM IIB: 35, 36].

*Organ preserving surgery*

Organ preserving surgery might be an alternative to orchiectomy in small primary tumours, but this approach is highly experimental and must be limited to clinical trials. However, in patients with synchronous bilateral tumours, metachronous contralateral tumours or solitary testicles with normal pre-operative testosterone levels, organ-preserving surgery is an alternative procedure to orchiectomy and should be discussed with the patient. If organ preserving surgery is considered, the patient should always be treated at a centre with experience in the management of this rare clinical situation [EBM IIB: 37–39]. If organ preserving surgery is performed and TIN histologically documented, adjuvant radiotherapy of the remaining testicular tissue is strongly recommended according to the management strategy for TIN in unilateral tumours [EBM IIB: 14, 37–40].

**Diagnosis and treatment of intratubular germ cell neoplasia (TIN/CIS)***Testicular biopsy in patients with gonadal germ cell cancer*

Intratubular germ cell neoplasia is defined as a premalignant testicular germ cell lesion. In patients with TIN, the cumulative probability for the development of a testicular tumour is 70% after 7 years [EBM IIB: 41]. Five per cent of patients with testicular tumours harbour TIN within the contralateral 'normal' testicle, detectable by open biopsy in 99% of cases

**Table 4.** Prevalence and diagnosis of TIN in the testis which is not affected by germ cell tumour

---

Biopsy for detection of TIN in contralateral testis

- 5% of all patients with testicular tumour
- $\geq 34\%$  TIN in patients with testicular atrophic volume  $<12$  ml and age  $<30$  years
- $\geq 33\%$  TIN in patients with extragonadal germ cell tumour prior to chemotherapy
- Approximately 10% TIN in patients with extragonadal germ cell tumour after chemotherapy

If untreated, invasive testis tumour develops in 70% of the TIN positive testis within 7 years

99% of TIN detected by random biopsy

Biopsy not mandatory but strongly recommended in

- high risk patients (atrophy and young age)
- Extragonadal germ cell tumour (prior chemotherapy, if not prior than  $\geq 6$  months after chemotherapy)
- Contralateral testis, one or both testes in extragonadal germ cell tumour.

---

TIN, intratubular germ cell neoplasia.

(Table 4). For patients with testicular volumes  $<12$  ml and an age  $<30$  years the risk of TIN in the contralateral testis is  $>34\%$  [EBM IIA: 14, 40, 42; EBM IIB: 43]. Therefore, the option of a contralateral testicular biopsy should be discussed with the patient, in particular, those at high risk of TIN [EBM IIA: 14, 40]. Contralateral biopsy should be performed preferably at the time of orchiectomy. Biopsies to identify TIN must be preserved in Stieve's or Bouin's solution (not in formalin!) [EBM IIB: 44, 45].

#### *Testicular biopsy in patients with extragonadal germ cell cancer*

About one-third of patients with extragonadal germ cell cancer harbour TIN within one or both testicles which otherwise appear normal. The cumulative risk of developing a metachronous testicular cancer 10 years after diagnosis and treatment of extragonadal germ cell tumours is only 10%, and higher among patients with non-seminomatous histology or retroperitoneal location than among patients with pure seminomatous histology (1.4%) or primary mediastinal location (6.2%) [EBM III: 10]. However, since all patients with extragonadal germ cell cancer will receive platin-based chemotherapy which will eliminate a substantial percentage of TIN, a routinely performed bilateral testicular biopsy is not recommended (Table 4). Nevertheless, if a biopsy is planned in patients with a higher risk for TIN following an extragonadal germ cell tumour, this should be preferably performed prior to chemotherapy [EBM IIA: 23–29, EBM III: 46, 47; EBM IV: 23]. If performed thereafter, testicular biopsy may be considered not earlier than 6 months after the completion of chemotherapy [EBM IIA: 23–29, EBM III: 46, 47; EBM IV: 23].

#### *Treatment of TIN (Table 5)*

*TIN in the contralateral testis or in the affected single testis after organ-preserving surgery.* There are three possible options, i.e. orchiectomy, radiotherapy, as well as a surveil-

**Table 5.** Treatment of testicular intraepithelial neoplasia (TIN)

---

TIN in contralateral testis or in case of organ preserving surgery

- If fertility should be maintained  $\Rightarrow$  delay definitive treatment by surveillance until resolution of fertility issue, followed by active treatment or further surveillance
- If fertility not relevant  $\Rightarrow$  irradiation 20 Gy (2 Gy, 5 $\times$ /week)

TIN in patients without gonadal tumour (incidental diagnosis, e.g. by biopsy for infertility or extragonadal germ cell tumour)

- Orchiectomy to be preferred over irradiation (potential damage of contralateral not affected testis by scattered radiation)

TIN in patients receiving chemotherapy (either as adjuvant treatment or for advanced or extragonadal disease)

- Since chemotherapy eradicates TIN in two-thirds of patients with TIN prior to chemotherapy, definitive treatment for TIN only if TIN is diagnosed at (re)biopsy after chemotherapy (re-biopsy not mandatory).

---

lance strategy, which should be discussed with the patient. Both orchiectomy or radiotherapy offer definitive treatment of TIN, but will destroy potential residual fertility. Since the interval between diagnosis of TIN and the development of a testicular tumour is usually long, a surveillance strategy is justified for patients who want to father children and have residual spermatogenesis at least sufficient for assisted fertilisation. In the case of a surveillance strategy regularly performed evaluation of the TIN-bearing testicle by ultrasound is mandatory.

If radiation treatment is chosen a total dose of 20 Gy (single doses of 2 Gy, five fractions per week) seems to be the most appropriate treatment which is able to safely eliminate all TIN loci [EBM III: 48–51]. In order to preserve testosterone production, radiation doses of  $<20$  Gy have been investigated. Whereas the potential benefit of this strategy is uncertain, a radiation dose  $<20$  Gy may result in lower frequencies of complete TIN eradication [EBM IIB: 52–54].

After radiation treatment regular determination of the serum testosterone levels should be performed since radiation may impair Leydig cell function [EBM IIB: 53]. The same applies to patients after organ preserving surgery. All patients with subnormal testosterone levels and clinical signs of androgen deficiency should be offered hormone replacement treatment.

*Treatment of TIN in patients without overt gonadal tumours.* TIN may be found incidentally in a testis investigated for other reasons (infertility or extragonadal germ cell tumours). In patients with a normal contralateral testicle, orchiectomy is a reasonable choice for definitive treatment, since radiation treatment of TIN might impair fertility of the contralateral unaffected testicle due to scattered radiation. This particularly applies to patients with an atrophic TIN-bearing testicle.

*Treatment of TIN in patients scheduled to receive chemotherapy.* If chemotherapy is planned in patients with TIN, radiation treatment should be postponed to avoid extensive damage to Leydig cells by the combination of chemotherapy and irradiation. Furthermore, in about two-thirds of patients TIN will be eradicated by chemotherapy alone [EBM IIB: 52; EBM III: 50, 55]. Therefore, a further biopsy may be considered in these patients not earlier than 6 months after

chemotherapy has been completed. Technically, a two site biopsy is recommended in this particular situation, because TIN cells will probably be low in number secondary to chemotherapy and thus a single random biopsy would have a high probability of missing the diagnosis [EBM IV: 56]. In cases of TIN persisting after chemotherapy these patients should be managed as described above.

### Histological examination of germ cell cancer

It is recommended to completely laminate the testicular specimen in transverse sections. Additional sections have to be taken from the spermatic cord. For a full histological examination of the tumour, it is necessary to obtain one block per centimetre of tumour, not less than a total of three blocks, as well as blocks from the peritumoral region and of remote testicular tissue. Further samples have to be taken from the funicular resection margin and from the spermatic cord with 1 cm distance to the testicle. Immunohistology can include cytokeratin for the detection of non-seminomatous elements, PLAP for the identification of TIN, CD31/factor VIII for the identification of vessel endothelium as well as AFP and  $\beta$ -HCG. TIN may be identified using H&E preparations, PLAP staining or by semithin-section technique.

The tumour must be classified according to the World Health Organisation (WHO) classification [57, Table 6]. The category 'anaplastic seminoma' is no longer used. The histopathological report must address the following issues (Table 7): localisation and size of the tumour, multiplicity, tumour extension (rete testis, tunica albuginea, tunica vaginalis, epididymis, spermatic cord, scrotum), pT category according to the UICC classification [58], histological type (WHO-ICD-O), the presence or absence of TIN, as well as the presence or absence of invasion of blood or lymphatic vessels [57].

In tumours with pluriform structures, each individual component and its estimated relative proportion should be documented. Similarly, evidence of syncytiotrophoblasts should be indicated in seminoma as well as any additional sarcomatous elements in spermatocytic seminomas, as recommended by WHO. Because of its clinical importance it is highly recommended that all histological specimens are assessed by a pathologist experienced in testis cancer pathology.

### Staging procedures and prognostic classification

To define the clinical stage of a patient with a gonadal germ cell tumour the TNM classification of the UICC should be used [58]. In addition, most patients with metastatic disease are classified according to the classification of the International Germ Cell Cancer Collaborative Group (IGCCCG) [59] which is also incorporated into the TNM classification. The individual treatment strategy is based on both the TNM classification and the IGCCCG-prognostic factor-based classification which includes histology, location of primary tumour, location of metastases and level of AFP,  $\beta$ -HCG and LDH as prognostic markers to categorise patients into 'good', 'intermediate' and 'poor' prognosis groups (Table 8). For

**Table 6.** WHO classification of germ cell tumours of the testis [7]

Tumours of one histological type
<ul style="list-style-type: none"> <li>• Seminoma</li> <li>• Spermatocytic seminoma</li> <li>• Embryonal carcinoma</li> <li>• Polyembryoma</li> <li>• Teratoma               <ul style="list-style-type: none"> <li>○ Mature</li> <li>○ Immature</li> <li>○ With malignant transformation</li> </ul> </li> <li>• Yolk sac tumour (endodermal sinus tumour)</li> <li>• Choriocarcinoma</li> </ul>
Tumours of more than one histological type
<ul style="list-style-type: none"> <li>• Embryonal carcinoma with teratoma (teratocarcinoma)</li> <li>• Choriocarcinoma and any other types (specify)</li> <li>• Other combinations (specify)</li> </ul>

WHO, World Health Organisation.

**Table 7.** Histopathological report of testicular tumour

Localisation
Size
Multiplicity
Extension of tumour (e.g. rete testis involvement, etc.)
pT category (UICC)
Histopathological type (WHO)
In seminoma: presence of syncytiotrophoblasts
In pluriform tumours description of each individual component
Presence of vascular invasion
Presence of TIN

TIN, intratubular germ cell neoplasia; WHO, World Health Organisation.

patients presenting with primary extragonadal germ cell tumours, a different prognostic outcome model has been developed [11] but is presently not routinely used.

#### *Prognostic factors in low volume disease*

*Seminoma clinical stage (CS) I.* Although no prognostic classification system has been prospectively validated so far, there is evidence that the size of the primary tumour (<4 cm versus  $\geq 4$  cm) and the infiltration of the rete testis are independent prognostic indicators for occult metastases [EBM IIB: 60]. These histopathological parameters should therefore be documented. Patient age (<34 versus  $\geq 34$  years) and the presence of vascular invasion (VI) are of equivocal prognostic relevance [EBM IIB: 60–62; EBM III: 62, 63].

*Non-seminoma CS I.* Infiltration of the primary tumour by venous blood vessels or lymphatic infiltration (vascular invasion, VI) are the most important prognostic indicators for occult metastases and should be assessed in all patients [EBM IB: 64; EBM IIA: 65–69; EBM IIB: 70–73; EBM III: 73–80]. Without adjuvant treatment 48% of patients with VI will develop metastases while only 14–22% of those without will relapse [EBM IIB: 72]. The proliferation rate, as well as the percentage of embryonal carcinoma in relation to the total

**Table 8.** IGCCCG classification of prognostic groups [59]

Prognosis	Proportion of patients	5-year survival	Non-seminoma	Seminoma
Good	56%	90%	<ul style="list-style-type: none"> <li>• Testis or primary extragonadal retroperitoneal tumour and low markers               <ul style="list-style-type: none"> <li>○ AFP &lt;1.000 ng/ml</li> <li>○ and <math>\beta</math>-HCG &lt;1000 ng/ml (&lt;5000 IU/l)</li> <li>○ and LDH &lt;1.5×normal level</li> </ul> </li> <li>• and no non-pulmonary visceral metastases</li> </ul>	<ul style="list-style-type: none"> <li>• Any primary localisation</li> <li>• any marker level</li> <li>• and no non-pulmonary visceral metastases</li> </ul>
Intermediate	28%	80%	<ul style="list-style-type: none"> <li>• Testis or primary extragonadal retroperitoneal tumour and intermediate markers               <ul style="list-style-type: none"> <li>○ AFP 1000–10 000 ng/ml</li> <li>○ and/or <math>\beta</math>-HCG 1000–10 000 ng/ml (5000–50 000 IU/l)</li> <li>○ and/or LDH 1.5–10×upper normal level</li> </ul> </li> <li>• and no presence of non-pulmonary visceral metastases</li> </ul>	<ul style="list-style-type: none"> <li>• Any primary localisation</li> <li>• and presence of non-pulmonary visceral metastases (liver, CNS, bone, intestine)</li> <li>• any marker level</li> </ul>
Poor	16%	50%	<ul style="list-style-type: none"> <li>• Primary mediastinal germ cell tumour with or without further risk factors</li> <li>• testis or primary retroperitoneal tumour</li> <li>• and presence of non-pulmonary visceral metastases (liver, CNS, bone, intestine)</li> <li>• and/or 'high markers'               <ul style="list-style-type: none"> <li>○ AFP &gt;10 000 ng/ml</li> <li>○ and/or <math>\beta</math>-HCG &gt;10 000 ng/ml (50 000 IU/l)</li> <li>○ and/or LDH &gt;10×normal level</li> </ul> </li> </ul>	

IGCCCG, International Germ Cell Cancer Collaborative Group; AFP,  $\alpha$ -fetoprotein;  $\beta$ -HCG,  $\beta$ -human gonadotropin; LDH, lactate dehydrogenase; CNS, central nervous system.

tumour volume, are further prognostic indicators [EBM IIB: 68, 70, 72, 77; EBM III: 75, 76, 78–82]. However, these markers do not contribute independent prognostic information in addition to the factor of VI.

*Non-seminoma pathological stage (PS) IIA/B.* If no adjuvant chemotherapy after surgical resection is administered [EBM III: 83, 84] the volume of the retroperitoneal mass [<2 cm (PS IIA) versus 2–5 cm (PS IIB)] and the presence of vascular invasion within the primary tumour are independent prognostic indicators for relapse.

### Imaging procedures

Information regarding validation of staging investigations using imaging techniques are not based on prospective phase III studies, so that meaningful EBM graduation cannot be given [85].

Computerized tomography (CT) of the chest, abdomen and pelvis are required as initial staging investigations. CT of the chest may be omitted for patients with testicular seminoma presenting without retroperitoneal tumour mass. Oral and intravenous contrast media are mandatory [86–91]. For the evaluation of the lung and mediastinum, chest CT scan is more sensitive than plain X-ray films [90–92]. However, it

should be noted that pulmonary/pleural nodules of <1 cm can represent a false positive finding in CT scans [78, 88, 90–93]. Furthermore, CT scans of the abdomen and pelvis might give false-negative results in up to 30% of cases due to difficulties in the interpretation of lymph nodes based on morphology and size alone. Therefore, the differentiation between clinical stages I and IIA is unreliable [87–89, 94, 95]. A detailed description of the location, number and size of lymph nodes should be provided in the radiology report.

Ultrasonography of the retroperitoneum is less sensitive than CT [87]. Magnetic resonance tomography (MRT) scans of the abdomen and pelvis do not provide additional information and should be restricted to patients to whom intravenous contrast media cannot be given [96, 97]. At the present time, it is controversial whether the sensitivity of PET is superior to the sensitivity of CT [98]. Whereas those trials are desirable, PET scans are not recommended outside clinical trials as part of routine initial staging procedures [99–104]. Bone scans should be obtained in patients with elevated levels of alkaline phosphatase or if bone metastases are clinically suspected.

Imaging of the brain by CT, or preferably by MRT, is required in patients with clinical signs potentially indicating brain metastases [EBM IV: 105, 106]. This might be expected especially in patients with metastatic disease and 'intermediate'

or 'poor' prognosis according to the IGCCCG classification [59].

### **Treatment-associated fertility issues and sperm banking**

In patients of reproductive age, baseline fertility assessment should be performed including the determination of total testosterone level, luteinising hormone (LH), follicle-stimulating hormone (FSH) and semen analysis. The patient must be informed about the possibility of cryoconservation. This procedure should be preferably carried out before orchiectomy [EBM II: 53; EBM III: 51, 107, 108; EBM IV: 109–111]. Patients with bilateral testicular tumours or a testicular tumour with contralateral TIN and with severe oligo-, azo- or aspermia may be informed about the option of testicular sperm extraction [EBM IV: 111–116]. However, this procedure may not be available in all European countries.

#### *Testosterone replacement*

In patients with bilateral orchiectomy lifelong testosterone replacement must be offered. After unilateral orchiectomy the necessity for testosterone supplementation depends on testosterone serum levels and clinical symptoms [EBM I-IV: 117].

#### *Contraception*

Although no increased risk of malformation in children born after the end of treatment has been reported, contraception throughout treatment as well as for 1 year of follow-up is recommended [EBM III: 118]. Patients who wish to father children should be followed with hormone and semen analysis for 1–3 years after completion of treatment.

### **Treatment of patients with seminoma CS I**

Despite normal CT scans, a 20% risk of clinical occult metastatic disease in locoregional lymph nodes with subsequent disease progression remains if no adjuvant treatment is applied after orchiectomy [EBM IIB: 60, 119, 120]. Nevertheless, the cure rate in CS I seminoma patients is almost 100% and can be achieved with three strategies: adjuvant radiation treatment, surveillance strategy with administration of irradiation or chemotherapy in case of relapse, or adjuvant chemotherapy with single-agent carboplatin [EBM IIB: 121–123]. Whereas adjuvant irradiation or surveillance are the current standard options, the third option of one cycle of adjuvant carboplatin has also recently been proven in a prospective randomised trial (EBM IB: 123a).

#### *Adjuvant radiotherapy*

Adjuvant radiotherapy is currently the most frequently used standard treatment resulting in a relapse rate of 3–4%. Almost all of these recurrences are located outside the irradiated area, mostly in the pelvis (1.7%) or close to the border of the radiation fields [EBM IB: 124, 125; EBM IIA: 126, 127]. The target volume of irradiation includes the infradiaphragmal paraaortal/paracaval lymphatics [EBM IB: 124, 125; EBM IIA: 126, 127]. The upper and lower field margins are defined

by the upper edge of thoracic vertebra 11 and the lower edge of lumbar vertebra 5. Ipsilateral to the primary tumour the lateral field margin should be extended to the renal hilum; the contralateral margin has to include the processus transversus of the lumbar vertebrae. The total dose is 20 Gy, applied in single doses of 2.0 Gy each, five fractions per week, based on the results of the recently completed prospective randomised trial of the Medical Research Council (MRC) which compared 30 Gy with 20 Gy [EBM IB: 125]. The use of a linear accelerator is mandatory. An extension of the irradiation field to the ipsilateral iliacal, inguinal or scrotal region in the event of prior maldescensus testis, inguinal or scrotal violations or pT3/4 primary tumours is probably not indicated since there is no evidence for a different treatment outcome [EBM IIA: 32; EBM III: 128].

Limited target volume and doses of modern adjuvant radiotherapy substantially add to a further reduction of treatment-related side-effects, such as impairment of fertility due to scatter radiation doses to the remaining testicle [EBM IB: 124; EBM IIB: 129]. Therefore, radiation effects on the patient's spermatogenesis due to scatter doses, which is always <2 Gy, seem to be unlikely and do not require shielding of the contralateral testis [EBM IB: 124; EBM IIB: 129].

Adjuvant radiation therapy may be associated with mild acute side-effects (usually WHO grade I–II), predominantly in the form of gastrointestinal symptoms [EBM IIB: 126]. Relapse after radiation will occur in 3–4% of patients and is nearly always located outside the radiation field [EBM IB: 120; EBM IIA: 126; EBM IIB: 130, 131]. However, adjuvant radiation represents an unnecessary treatment for ~80% of patients who would otherwise remain free of relapse even without any adjuvant treatment. Furthermore, compared to no adjuvant treatment there is a small risk of secondary malignancies after radiation therapy [EBM III: 132–134]. However, there are no data currently available quantifying the risks of secondary malignancies if modern radiation techniques are applied with reduced doses and limited target volumes. The risk of radiation-induced impairment of fertility is discussed controversially [EBM III: 51, 107]; however, its effect may be minimal.

#### *Surveillance*

A surveillance strategy may be used as an alternative to adjuvant irradiation [EBM IIA: 126, 127; EBM IIB: 130, 131]. Surveillance takes into account the fact that 80% of patients do not need any adjuvant treatment after orchiectomy and are therefore overtreated by adjuvant irradiation. However, the results of a retrospective meta-analysis of patients managed by surveillance indicates a higher risk of relapse if the tumour size is  $\geq 4$  cm or the tumour has invaded the rete testis [EBM IIB: 60; EBM III: 135]. Relapses will occur predominantly (in 97% of cases) in the retroperitoneal or high iliacal lymph nodes [EBM IIB: 61, 120, 136, 137] and may occur as late as 10 years after orchiectomy, or even later [EBM IIB: 61, 120; EBM III: 138]. This requires prolonged follow-up of the patients. Treatment of those patients who relapse is usually

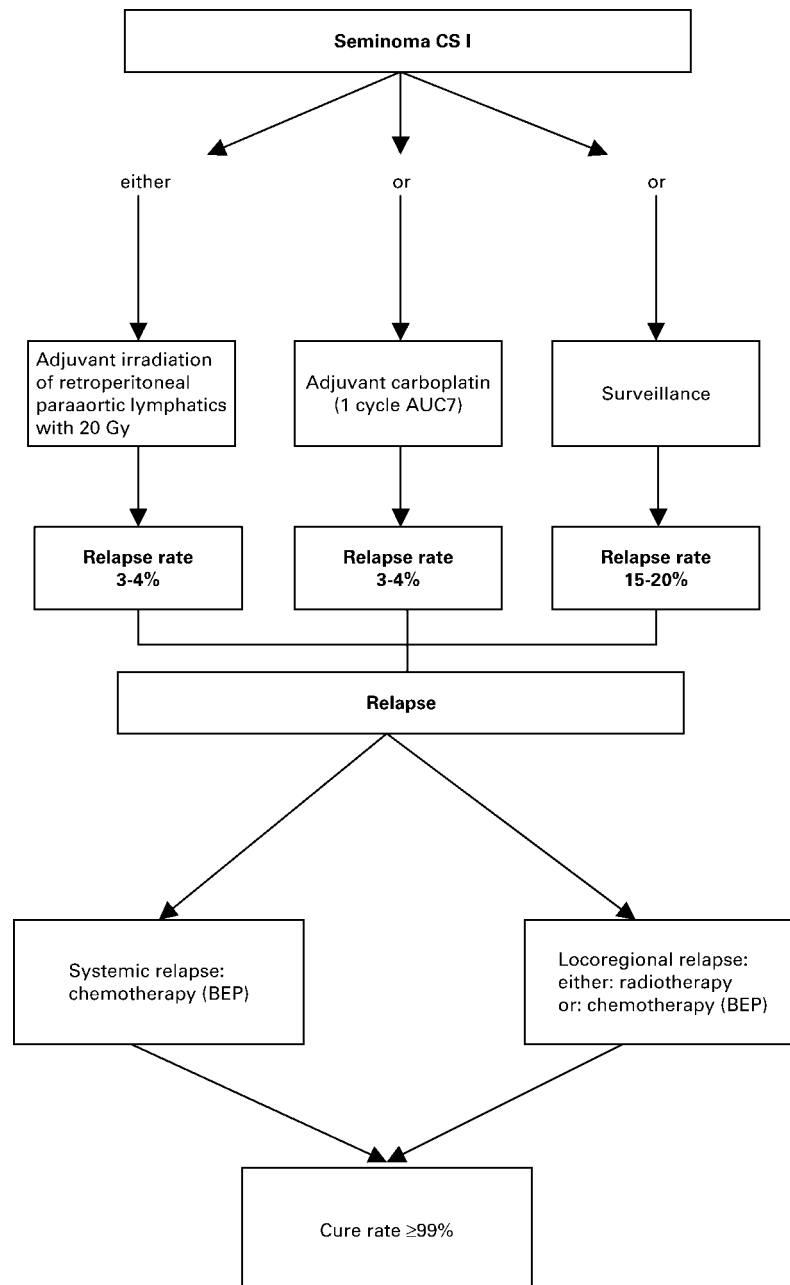
more intensive [EBM IIB: 119; EBM III: 138]. Due to the higher risk of relapse patients managed by surveillance may experience greater psychological stress [EBM III: 139].

*Adjuvant carboplatin chemotherapy*

The third alternative is adjuvant chemotherapy with one cycle of carboplatin AUC7. The analysis of the large MRC/EORTC trial comparing adjuvant treatment with either radiation or one cycle of single agent carboplatin AUC7 revealed after a median of 4 years follow-up no significant difference in relapse rate, time to relapse and survival (EBM IB: 123a). The pattern of relapse differs (more retroperitoneal lymph node relapse with carboplatin versus more pelvic lymph node relapse with adjuvant irradiation) but the less time to complete carboplatin

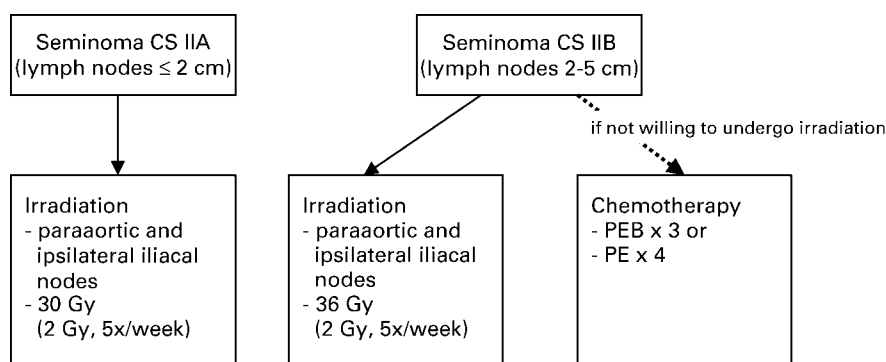
and the reduction of contralateral testis tumour (2 versus 10 patients) could offer a significant advantage over a full course of irradiation.

Taken together, all three options result in a different relapse rate (3–4% for irradiation or adjuvant carboplatin versus 15–20% for surveillance) but a high cure rate of nearly 100% if applied properly. All three treatment options, adjuvant radiotherapy, adjuvant carboplatin and surveillance, are acceptable standard strategies for the management of patients with CS I seminoma (Figure 1). The individual strategy could be selected on the basis of the risk factors defined by Warde et al. (60); however, this risk adapted approach —e.g. adjuvant treatment for patients at high risk for relapse—is still under prospective evaluation and therefore not unanimously



**Figure 1.** Treatment algorithm after orchiectomy according to individual risk factors in patients with seminoma clinical stage (CS) I.





**Figure 2.** Treatment algorithm in seminoma clinical stage IIA/B.

recommended as a routine strategy out of clinical trials. The individual decision must be based on a discussion with the patient, taking into account the above mentioned benefits and disadvantages, as well as the individual situation of the patient and/or treatment centre.

### Treatment of patients with seminoma CS IIA/B

The standard treatment in CS IIA/B seminoma is radiotherapy. With modern radiation techniques this treatment results in a relapse-free survival at 6 years of 95% for stage IIA and 89% for stage IIB [EBM IIB: 140]. Overall survival is close to 100% [EBM IIB: 140–142; EBM III: 142, 143]. The target volume includes the paraaortic and ipsilateral iliacal lymphatics. The upper field margin is the upper border of thoracic vertebra 11, the lower field margin is the upper border of the acetabulum. In CS IIA, the lateral field margins for the para-aortic fields are identical to those for CS I. In CS IIB the lateral field margins are individually modified according to the extension of the lymph nodes with a safety margin of 1.0–1.5 cm. In CS IIA and CS IIB radiation doses of 30 and 36 Gy, respectively, are administered homogeneously with single doses of 2 Gy at five fractions per week. To reduce the risk of impairment of fertility due to scatter radiation dose, shielding of the remaining testicle during irradiation is mandatory. Three months post radiation therapy, abdominal and pelvic CT scans should be performed to document the treatment effect [EBM IIB: 144; EBM III: 145–149] and as a basis for follow up.

Any extension of the radiation target volume to the contralateral iliacal, inguinal or scrotal region for prior maldescensus testis, inguinal or scrotal violation or pT3/4 primary tumours is not indicated since there is no unequivocal evidence for a different treatment outcome if such an extension is made [EBM IIA: 32; EBM III: 143]. The role of combined radiation and chemotherapy is currently under investigation [EBM IIB: 142, 150] and should therefore not be used outside clinical trials.

Chemotherapy with three cycles of standard-dose cisplatin, etoposide and bleomycin (BEP), or four cycles of EP represent an alternative treatment for patients not willing to undergo radiotherapy, in particular, in the case of larger retroperitoneal disease (Figure 2). Single-agent carboplatin, even using a dosage according to area under the concentration–time curve

(AUC) of 7, has no advantage over radiation treatment and is probably associated with a higher risk of locoregional or systemic relapse [EBM IIB: 151].

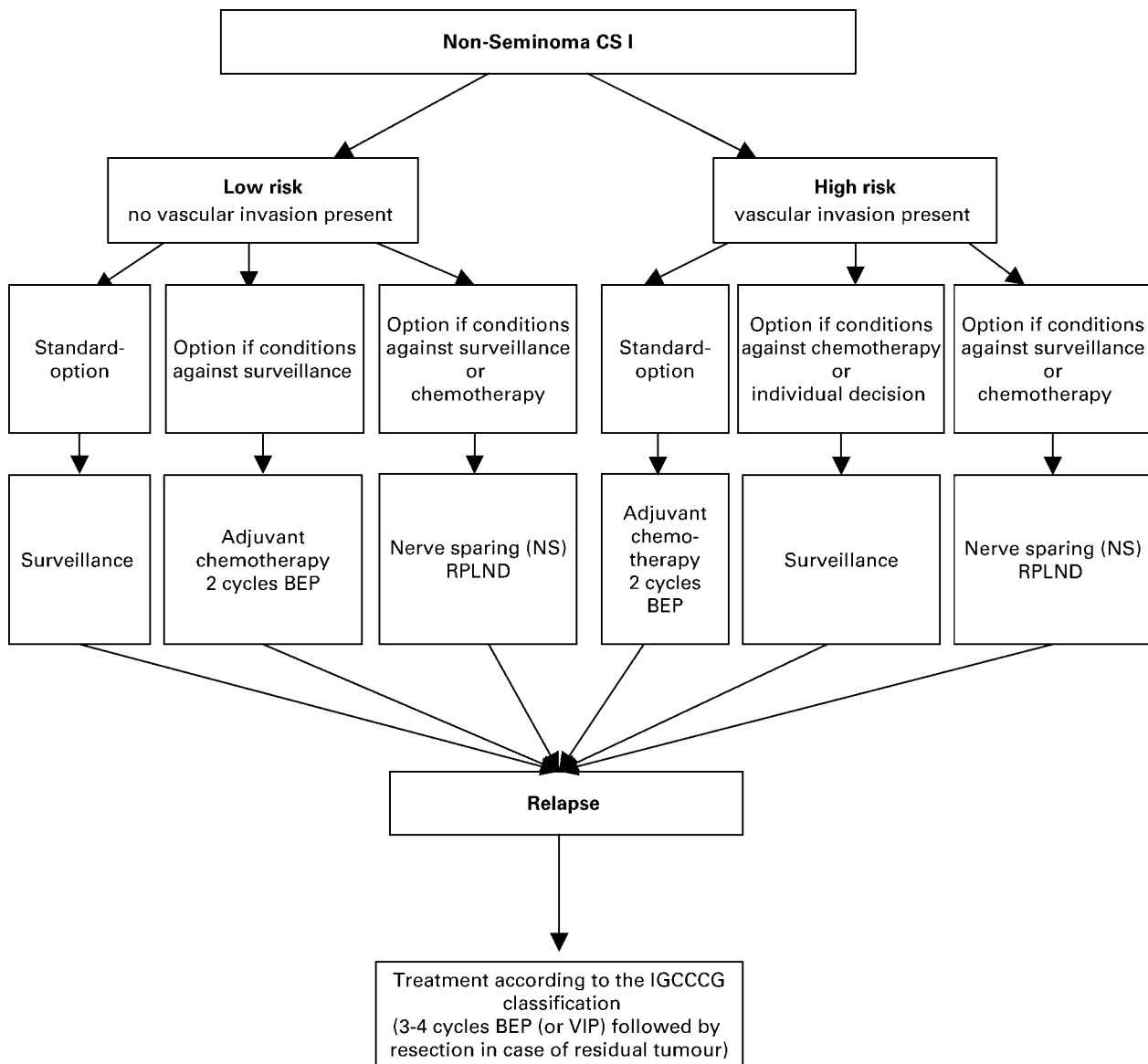
### Treatment of patients with non-seminoma CS I

The cure rate of patients with non-seminoma (NS) CS I is 99% independent of the strategy used if performed properly [EBM IIB: 72, 152]. In the case of surveillance, the relapse rate is 27–30% when considering a long-term follow up of  $\leq 20$  years [EBM IIB: 77, 152]. Relapses occur in the retroperitoneum in 54–78% of patients, in the lung in 13–31% of patients, but are very rarely in more than one visceral organ [EBM IIB: 152; EBM III: 153].

Vascular invasion (VI) of the primary tumour is the most important prognostic indicator for relapse. Patients with VI have a risk of 48% of developing metastatic disease [EBM IB: 64; EBM IIB: 72] whereas only 14–22% of patients without VI will relapse [EBM IB: 64; EBM IIA: 66; EBM IIB: 68, 77]. A risk adapted strategy based on the presence or absence of VI is the recommended standard procedure (Figure 3).

Patients with a low risk of relapse (no VI) should be managed by surveillance, although standardised recommendations for follow up have not yet been defined. With this approach 78–86% of patients do not need any further treatment after orchiectomy [EBM IIA: 66; EBM IIB: 68, 77]. If a patient under surveillance relapses, the administration of chemotherapy will result in a cure rate close to 100%. Only in circumstances not suitable for surveillance is adjuvant chemotherapy with two cycles of BEP recommended. Nerve sparing retroperitoneal lymph node dissection (NS-RPLND) is an option, if conditions against both standard options, surveillance or adjuvant chemotherapy, exist.

Patients with a high risk of relapse (VI present) may be considered for adjuvant chemotherapy with two cycles of BEP. With this approach 97% of patients will remain relapse-free and the overall cure rate is  $\geq 99\%$  [EBM IIB: 72]. The disadvantage of adjuvant treatment in high-risk patients is that half of the patients who receive adjuvant BEP would not have required chemotherapy at all and may be unnecessarily exposed to the side-effects of chemotherapy [EBM IB: 154; EBM IIA: 155; EBM III: 156, 157], a possible transient decrease in fertility [EBM IIB: 158; EBM III: 159] and possibly a small risk of



**Figure 3.** Treatment algorithm after orchiectomy according to individual risk factors in patients with non-seminoma clinical stage (CS) I.

secondary malignancies, as reported from patients receiving higher doses of chemotherapy [EBM III: 107, 132–134]. However, surveillance in high-risk patients with a relapse rate of 48% exposes patients to psychological distress [EBM III: 139]. Relapses might be detected later and subsequent treatment is more intensive. Nevertheless, if surveillance is carried out properly >98% of these patients will still have a good prognosis at the time of relapse and are cured by chemotherapy.

In those rare patients unwilling to undergo a surveillance strategy or adjuvant chemotherapy, a nerve sparing lymphadenectomy (NS-RPLND) may be performed [EBM IIA: 160; EBM III: 161, 162]. However, patients who choose NS-RPLND will be unnecessarily exposed to surgery in 50% of cases with the risk of surgery associated side-effects [EBM IIB: 152], in particular, a 6–8% risk of retrograde ejaculation [EBM IIB: 152, EBM III: 163, 164]. In addition, NS-RPLND does not completely eliminate the risk of recurrence

and relapses will occur in ~10% of cases with almost all of these relapses outside of the retroperitoneum being located in the lungs. Late relapses are rare [EBM III: 138].

### Treatment of patients with non-seminoma CS II A/B

The cure rate for CS IIA and IIB non-seminoma is close to 98%. Patients with abnormal marker levels of AFP,  $\beta$ -HCG and/or LDH in CS IIA/B are treated according to the algorithms for patients with advanced disease, according to IGCCCG recommendations [59].

Patients with retroperitoneal lymph nodes 1–2 cm, suspected to be CS IIA, without marker elevation represent a particular problem. Two options should be considered: staging-RPLND or surveillance. With RPLND the pathological stage could be verified immediately; if surveillance is chosen, follow up at short intervals, e.g. 6 weeks, is indicated to document whether the lesion either grows, remains stable or

becomes smaller. A growing lesion indicates malignant retroperitoneal disease and in this case treatment should start; whereas a shrinking lesion is likely to be not of malignant origin (Figure 4).

RPLND should be performed using a nerve-sparing technique [EBM III: 165]. However, depending on the experience of the surgeon, RPLND may result in loss of antegrade ejaculation in 5–32% of patients despite a nerve-sparing approach [EBM IIA: 166; EBM III: 155, 157, 159]. Other morbidity related to surgery may occur in up to 10% of patients [EBM III: 164]. Surgical exploration at the time of RPLND will reveal a pathological stage (PS) I in 12–13% of patients [EBM IIA: 166]. In cases of PS IIA/B, further options are adjuvant chemotherapy or surveillance [EBM IB: 167; EBM IIA: 168; EBM III: 169, 170]. In cases of adjuvant chemotherapy the recurrence rate is 0–7%. Relapses occur almost exclusively outside the retroperitoneum [EBM IB: 167; EBM IIA: 166; EBM III: 161, 170]. Yet chemotherapy is necessary in only 30% and 50% of patients in PS IIA and PS IIB, respectively [EBM IB: 167; EBM IIA: 168; EBM III: 161, 169, 170]. Therefore, adjuvant chemotherapy in all patients represents an overtreatment in 50–70% of patients with the resulting treatment-related toxicity and possible late sequelae [EBM IB: 154; EBM IIA: 171; EBM IIB: 158; EBM III: 132–134, 154, 172].

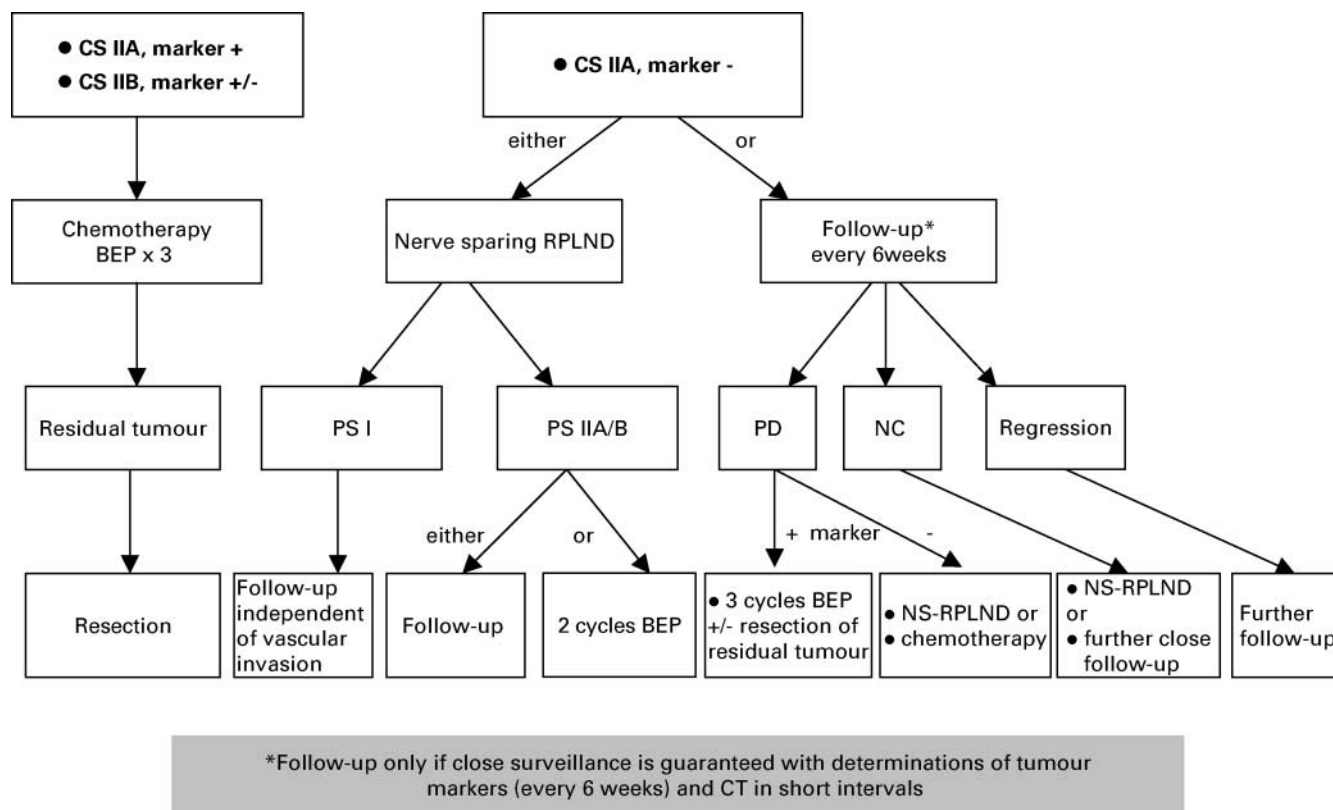
Alternatively, patients with stage IIA/B and marker negative disease may be offered an ultrasonography guided biopsy, and

in those patients with a positive biopsy for undifferentiated tumour three cycles of BEP will be the treatment of choice.

As an alternative to RPLND, compliant patients with non-seminoma CS IIA can be managed by surveillance (Figure 4). If progressive disease occurs without a corresponding increase of the tumour markers AFP or  $\beta$ -HCG explorative surgery should be performed. Patients with increase of the tumour markers AFP or  $\beta$ -HCG require chemotherapy with BEP according to the treatment algorithm for patients with metastatic disease and IGCCCG recommendations [EBM IIA: 166; EBM III: 173–175]. The possible contribution of PET-scan in this situation has not been properly investigated.

### Treatment of patients with advanced disease

For patients with 'good' prognosis disease, according to IGCCCG criteria [59], standard treatment is three cycles of BEP. In cases of contraindications against bleomycin four cycles of cisplatin and etoposide (PE) can be given [EBM IA: 59; EBM IB: 176, 177; EBM IIA: 178; EBM III: 179]. The efficacy of BEP, given for 5 days with etoposide 100 mg/m<sup>2</sup> and cisplatin 20 mg/m<sup>2</sup> each day is equivalent to BEP with etoposide 165 mg/m<sup>2</sup> applied during 3 days and cisplatin 50 mg/m<sup>2</sup> during 2 days [EBM IB: 180]. However, BEP given over 3 days has increased long-term toxicity including ototoxicity, peripheral neurotoxicity or Raynaud syndrome when four cycles are applied [EBM IB: 181, 182; EBM IIA: 178].



**Figure 4.** Treatment options in patients with non-seminoma clinical stage IIA. Follow-up only if close surveillance is guaranteed with determinations of tumour markers (every 6 weeks) and computed tomography in short intervals. BEP, cisplatin, etoposide and bleomycin; CS, clinical stage; NS-RPLND, nerve sparing retroperitoneal lymph node dissection; PS, pathological stage.

**Table 9.** Chemotherapy protocols for treatment of advanced germ cell cancer

	Cisplatin, mg/m <sup>2</sup> (30 min.-inf.)	Etoposide, mg/m <sup>2</sup> (30–60 min.-inf.)	Ifosfamide*, mg/m <sup>2</sup> (1 h-inf.)	Bleomycin, mg/m <sup>2</sup> (IV bolus)	q day	No. of cycles/prognosis	
						Good	Intermediate/poor
BEP, PEB “5 days”	20 d 1–5	100 d 1–5	–	d 1, 8, 15	22	3	4
BEP, PEB “3 days”	50 d 1, 2	165 d 1, 2, 3	–	d 1, 8, 15	22	3	–
PE	20 d 1–5	100 d 1–5	–	–	22	4	–
PEI, VIP**	20 d 1–5	75 d 1–5	1200 d 1–5	–	22–29	–	4

\*Mesna: 400 mg IV before the day 1 ifosfamide dose and then 1,200 mg/ day by continuous IV infusion on day 1 to 5 (120 hours).

\*\*PEI/ VIP only if contraindication against Bleomycin.

BEP, cisplatin, etoposide and bleomycin; PEI, cisplatin, etoposide and ifosfamide; VIP, etoposide, ifosfamide and cisplatin.

Therefore, the original 5-day BEP regimen for four cycles remains the standard treatment in ‘intermediate’ and ‘poor’ prognosis patients. Chemotherapy should be given without dose reductions in 22-day intervals. Postponing treatment, i.e. maximum of 3 days for each decision, should only be considered in cases of existing fever, neutrophils <500/μl or platelets <100 000/μl at day 1 of a subsequent cycle.

There is no indication for routine prophylactic application of haematopoietic growth factors, such as granulocyte colony-stimulating factor (G-CSF). However, if serious infectious complications have occurred during one preceding chemotherapy cycle, prophylactic administration of G-CSF is recommended in subsequent cycles [EBM IIA: 183, 184]. Since dose reductions due to neutropenia should be avoided, prophylactic G-CSF should also be used if prolonged neutropenia occurs for maintenance of the required dose intensity.

With the introduction of an ‘intermediate’ prognosis group by the IGCCCG classification a group of patients has been defined who may reach a 5-year survival of 80%. Data of a meta-analysis support four cycles of BEP as standard treatment in these patients [EBM IA: 59; EBM IB: 181]. In order to design more effective treatment, all patients with an ‘intermediate’ prognosis should be treated in prospective trials [EBM IV: 185].

For patients with ‘poor’ prognosis standard treatment consists of four cycles of BEP. Four cycles of etoposide, ifosfamide and cisplatin (VIP) are equally effective compared with BEP, but cause more acute myelotoxicity without offering benefits and are not recommended as standard [EBM IB: 186]. In the IGCCCG analysis, 5-year progression-free and overall survival were 41% and 48%, respectively. In individual patients, VIP may be preferred to BEP in order to avoid possible bleomycin-induced lung injury in already pulmonary compromised patients. Patients in a poor general condition (<50% according to the Karnofsky scale) with extended liver-, pulmonary- or central nervous system (CNS)-involvement may benefit from a short course of reduced-dose chemotherapy before a full-dose chemotherapy cycle is started, e.g. 2–3 days of cisplatin/etoposide.

It has not yet been proven that high-dose chemotherapy plus autologous haematopoietic stem cell support given as

first-line therapy increases survival. Therefore, high-dose chemotherapy must not be used outside of a prospective clinical trial [EBM IIB: 187, 188; EBM III: 189].

To maintain the highest chance of cure, ‘poor’ prognosis patients should be transferred to a specialised centre without any delay to benefit from optimal interdisciplinary management and supportive care [EBM III: 1].

### Treatment of patients with brain metastases

Approximately 10% of all patients with advanced germ cell cancer present with brain metastases (i.e. 1–2% of all patients with testicular cancer). At relapse, metastases in the CNS usually occur as part of a systemic relapse and very rarely as an isolated relapse after previously successful treatment. Patients who present with brain metastases at initial diagnosis have a long-term survival probability of 30–40%, whereas patients who develop metastases during first-line treatment or in the context of recurrent disease outside of the brain have a 5-year survival rate of only 2–5%. The best prognostic group consists of patients with a solitary brain lesion discovered by initial staging investigations [EBM III: 105, 106]. The presence of metastatic choriocarcinoma indicates a poor prognosis independent from any form of treatment (unpublished data of GTCSSG CNS Working Party) [EBM III: 105, 106, 190].

The optimal sequence of treatment modalities (chemotherapy, radiotherapy, operation) has not yet been finally defined. Curatively intended chemotherapy is necessary in all patients with brain metastases [EBM III: 190]. In a multivariate analysis cranial irradiation in addition to systemic chemotherapy improved the overall prognosis of patients who present with a brain metastasis [EBM III: 191] in contrast to earlier reports demonstrating no benefit [EBM III: 106].

It has also not yet been defined whether consolidating irradiation of the CNS is required after complete remission has been achieved by chemotherapy alone. Radiotherapy therefore should only be applied in controlled clinical study protocols according to the procedure in other solid tumours, e.g. applied as whole brain irradiation (single dose not exceeding 2 Gy) concomitantly with combination cisplatin-based chemotherapy [EBM IIB: 192].

Whether secondary resection of a solitary residual mass is required after chemotherapy (MRT scans are mandatory for detection of micrometastases) remains unclear and depends on the extent of systemic disease, the resectability and the location of the residual lesion, as well as on the initial histology of the primary tumour. However, surgery may be considered in individual patients with solitary brain metastases.

**Monitoring of treatment result and further treatment**

The prognostic value of a transient increase of tumour markers after initiation of first-line treatment as well as a delayed decrease of tumour markers according to their usual half-life is equivocal [EBM III: 193]. In patients with slow tumour marker decline and stable or regressive radiologically documented

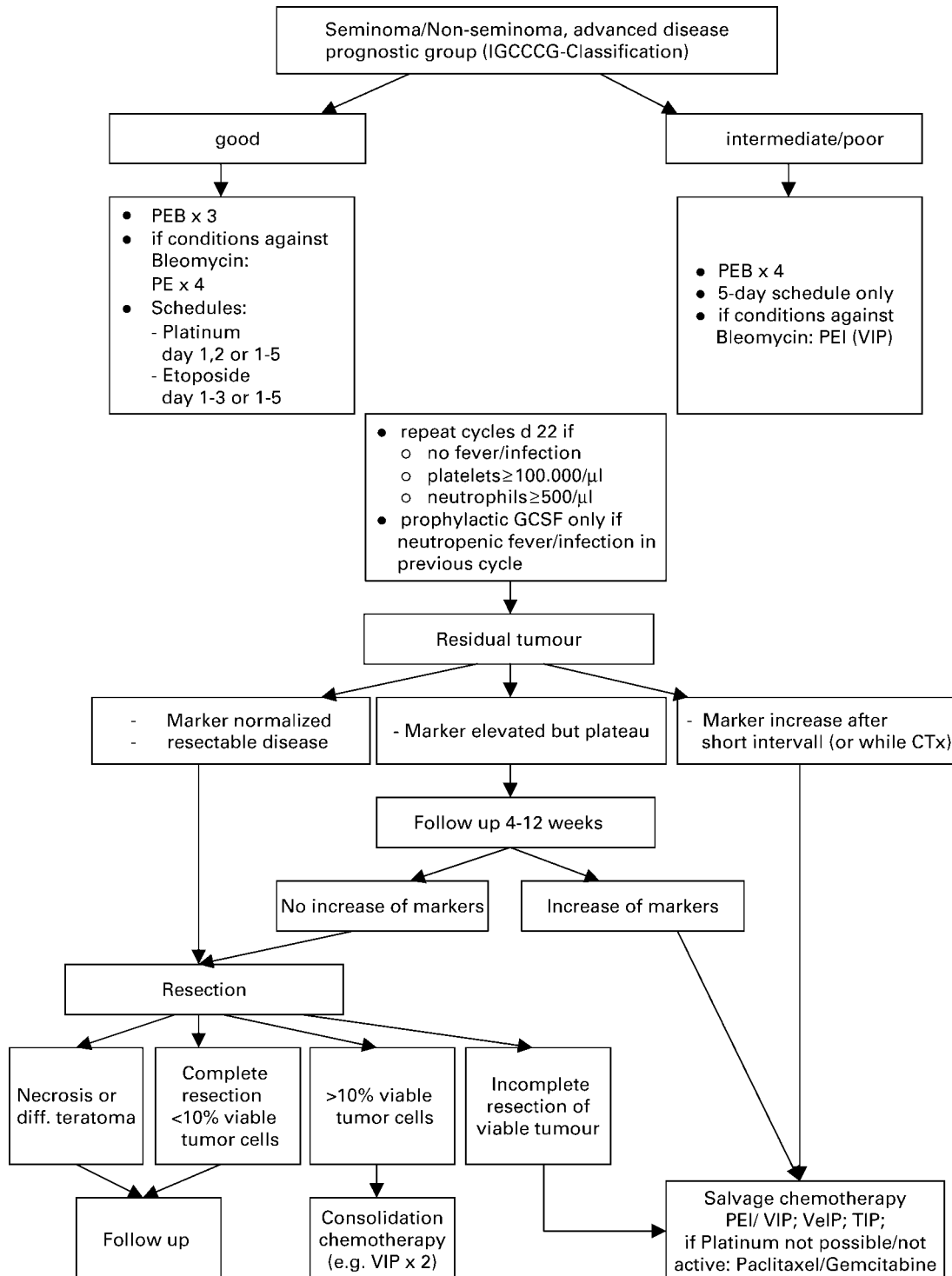


Figure 5. Treatment algorithm for advanced germ cell tumor.

tumour manifestation, chemotherapy should be completed with three to four cycles, depending on the initial stage [EBM IIA: 59, 194, 195]. Patients with a documented tumour marker increase during chemotherapy must be switched to salvage treatment even if the tumour marker progression does not coincide with radiological progression. It is very important that the marker is measured directly before each treatment cycle, otherwise the marker can be falsely increased due to release of markers from necrotic tumour cells (Figure 5).

Patients with a marker plateau at a low level after four cycles of BEP or VIP should be followed in short intervals for further decline. In addition, all residual radiological lesions should be resected if possible [EBM III: 196]. Salvage chemotherapy should only be initiated if an unequivocal tumour marker increase is observed (Figure 5).

Monitoring tumour markers prior to each treatment cycle is mandatory. Radiological restaging has to be performed after completion of first-line chemotherapy. In patients with slow marker decline or clinical evidence of tumour progression radiological restaging should be considered earlier. In patients with unequivocally progressive tumours early modification of the first-line treatment strategy is required. Progression with tumour markers despite first-line chemotherapy requires the immediate initiation of salvage treatment [EBM IIB: 188, 197]. However, patients who experience tumour marker progression during or within 4 weeks of cisplatin-based first-line treatment have a very poor prognosis [EBM IIB: 198].

If progression occurs with growing metastases, despite declining tumour markers, the presence of a 'growing teratoma syndrome' is highly probable, and complete resection of all tumour manifestations is required after the end of first-line chemotherapy [EBM III: 199]. Only in the event of rapid radiological tumour progression should immediate surgery be performed before the completion of chemotherapy [EBM IV:].

Resection of residual masses should be performed in patients with tumour markers persisting at low levels after completion of first-line treatment. Salvage chemotherapy is required for any documented increase in tumour markers after first-line treatment [EBM III: 182].

## Resection of residual tumour

### *Seminoma*

Post-chemotherapy as well as post-radiotherapy residual masses in seminoma patients should not necessarily be resected, irrespective of their size, but should be closely followed by imaging investigations and tumour marker determinations [EBM IIB: 200; EBM III: 201–204]. A positive result of PET scans, if performed more than 4 weeks after chemo-/radiotherapy, is a strong and reliable predictor of viable tumour tissue in patients with residual lesions >3 cm [EBM IIB: 205, 206]. In patients with progressive disease of the residual mass after first-line chemotherapy thorough histological evaluation and salvage chemotherapy after confirmation of seminoma should be performed [EBM III: 207; EBM IV: 208].

### *Non-seminoma*

Patients who achieve complete remission, i.e. negative tumour markers and residual lesions  $\leq 1$  cm after chemotherapy, post-chemotherapy RPLND is not required [EBM IIB: 209, 210; EBM III: 211]. Neither any imaging procedures (including PET) nor any prognostic model have been able to reliably predict residual mass histology [EBM IIB: 212; EBM III: 196, 213–220]. Therefore, in patients with a residual mass >1 cm and normalisation of tumour markers the residual masses have to be resected [EBM IIA: 221, 222; EBM IIB: 223; EBM III: 211, 224, 225]. Histological findings in subsequent surgery for residual masses after first-line chemotherapy will reveal necrosis, mature teratoma and vital cancer in about 50%, 35% and 15% of patients, respectively. The incidence of vital cancer may be even higher after salvage chemotherapy. If technically feasible, all residual masses should be resected. In patients with residual masses at multiples sites, an individual decision should be made regarding the number and extension of resections [EBM III: 196]. Decisions on the extent of surgery should be based on the risk of relapse of an individual patient and on quality-of-life issues [EBM IIA: 222; EBM III: 215]. Resection of residual tumours outside the abdomen or lung should also be considered on an individual basis, since a discordance in histology is found in 35–50% of patients [EBM III: 217, 226]. If the histology of the primarily resected mass is only necrosis, both surveillance of the remaining residual lesions, as well as their complete resection, are acceptable therapeutic options. Due to the high treatment-related acute morbidity, surgery of residual masses should be performed only at specialised centres.

Post-chemotherapy laparoscopic RPLND remains experimental and should not be used outside clinical trials [EBM III: 227–229].

### *Consolidation chemotherapy after secondary surgery*

After resection of necrosis or mature teratoma no further treatment is required. In cases of vital carcinoma or immature teratoma the role of further consolidation chemotherapy is equivocal (cave: cumulative dose of bleomycin). A retrospective analysis demonstrated an improved progression-free survival with adjuvant chemotherapy, but failed to show an improvement in overall survival. Therefore a 'wait-and-watch' strategy may also be justified [EBM III: 230]. Patients in the 'good' prognosis group, according to the IGCCCG classification, with complete resection of residual masses and with <10% vital tumour cells in the resected specimens have a favourable outcome even without adjuvant chemotherapy. If the completely resected tumour presents >10% of viable cancer, or if completeness of the resection is in doubt, consolidation chemotherapy might be justified.

The prognosis is markedly worse in patients after second- or third-line chemotherapy whose resected residual masses contain vital undifferentiated carcinoma. In these patients postoperative adjuvant chemotherapy does not improve survival and is therefore not indicated [EBM III: 218, 224].

## Salvage chemotherapy for relapsed and/or refractory disease

In patients who relapse or progress after first-line treatment, the localisation and histology of the primary tumour, the response to first-line treatment, the duration of previous remissions, as well as the level of the tumour markers AFP and  $\beta$ -HCG at the time of relapse or progression are known prognostic indicators [EBM IIB: 198; EBM III: 193].

### *Seminoma*

The majority of patients who relapse after first-line radiotherapy have a cure rate >90% and should receive cisplatin-based chemotherapy comparable to the treatment strategy in advanced seminoma (Figure 1). Conventional-dose cisplatin-based salvage chemotherapy after first-line therapy with BEP will result in long-term remissions in  $\leq 50\%$  of patients [EBM IIB: 231]. Regimens of choice are four cycles of cisplatin, etoposide and ifosfamide (PEI), etoposide, ifosfamide and cisplatin (VIP), vinblastine, ifosfamide and cisplatin (VeIP) or paclitaxel, ifosfamide and cisplatin (TIP) [EBM IIB: 232]. No conventional-dose salvage regimen has shown unequivocal superiority so far over another conventional-dose cisplatin-containing salvage regimen [EBM IIB: 233, 234]. It is currently impossible to decide whether cisplatin-based combination chemotherapy is sufficient or whether high-dose chemotherapy is needed [EBM IIB: 235]. For this reason these patients should be treated at experienced centres and within prospective randomised trials.

### *Non-seminoma*

The majority of patients with recurrent disease after surgery have a good prognosis with a cure rate >90% and should receive cisplatin-based chemotherapy comparable to the treatment strategy in advanced non-seminoma. Salvage treatment after first-line chemotherapy for metastatic disease consists of four cycles of PEI, VIP, VeIP or TIP. Paclitaxel combinations have been favoured by some groups because of single-agent activity of paclitaxel in phase II trials in refractory patients. In addition, a high response rate of >50% to TIP was observed in a small group of selected patients with good prognostic features (EBM: IIB: 232). Results from randomized trials specifically addressing the role of paclitaxel are not yet available. [EBM IIB: 232]. Conventional-dose cisplatin-based salvage chemotherapy can achieve long-term remission in 15–40% of patients, depending on individual risk factors [EBM IIB: 198, 233; EBM III: 193]. No conventional-dose salvage regimen has shown unequivocal superiority so far over another conventional-dose cisplatin-containing salvage regimen [EBM IIB: 233, 234]. The use of conventional-dose combination chemotherapy with more than three agents increases toxicity without improving overall treatment outcome [EBM IIB: 234, 236].

Depending on the presence or absence of adverse prognostic factors, the results of salvage therapy after first-line cisplatin-based treatment are unsatisfactory [EBM IIB 198; EBM III: 193]. Phase II trials indicate a 10% improvement in survival

with early intensification of salvage treatment using high-dose chemotherapy [EBM IIB: 235]. However, no advantage was observed according to the results of a large randomised trial [EBM IB: 237]. Therefore, all of these patients should be entered into ongoing multicentre studies and should be referred to centres experienced in the treatment of relapsed and/or refractory patients. Options for third-line chemotherapy are combinations such as paclitaxel–gemcitabine, gemcitabine–oxaliplatin or paclitaxel–gemcitabine–cisplatin, preferably within clinical trials.

## Salvage surgery

Residual masses after salvage chemotherapy should be resected within 4–6 weeks after the normalisation of tumour markers or after a low-level marker plateau has been reached. Only in the case of progressive tumour markers after salvage treatment and lack of other chemotherapeutic options should surgical resection of residual tumours (sometimes referred to as ‘desperation surgery’) be considered, and if complete resection of all tumour manifestations seems feasible. With this approach long-term survival may be achieved in about 25% of patients [EBM III: 198, 238–243], particularly in those patients who have unresponsive late relapse, moderately elevated AFP and localised (mainly retroperitoneal) metastatic deposits. Salvage surgery should not be attempted in rapidly progressive disease with increased  $\beta$ -HCG levels.

## Late relapse ( $\geq 2$ years after end of first-line treatment)

If technically feasible, patients with late relapse and negative tumour markers should undergo immediate radical surgery to completely resect all mature teratoma or secondary non-germ cell cancer. Due to the poor results of chemotherapy in patients with late relapses, patients with small and completely resectable lesions should also undergo surgery in the case of elevated tumour markers [EBM III: 138, 244].

If the lesions are not completely resectable, biopsies should be obtained for histological assessment and salvage chemotherapy should be initiated. If the patient responds to salvage chemotherapy, secondary surgery should be conducted whenever possible.

In case of unresectable but localised refractory disease radiotherapy can be considered.

## Follow up

The follow up of patients with germ cell cancer consists of regular clinical examinations, monitoring of serum tumour markers and imaging investigations. Clinicians and patients should be aware of the possibility of an occurrence of a contralateral second testicular primary. The risk depends on exposure to chemotherapy with 1–3% after chemotherapy, and up to 5% if no chemotherapy was given. In the case of biopsy proven but untreated TIN in the contralateral testis, the cumulative probability for the development of a testicular tumour is 70% after 7 years [EBM IIB: 41]. All tumours

should be detected at an early stage by regular control including self examination of the testis. If regular ultrasounds of the contralateral testicle are performed one should be aware that microlithiasis is very common after chemotherapy and should not be construed as an abnormality. Testosterone, LH and FSH levels may also be evaluated regularly.

Large differences exist in the risk of recurrence or progression among patients with germ cell cancer due to differences in the stage at initial presentation and individual management decisions. The intensity of follow-up investigations should be modified according to these factors. There is only limited information about the optimal follow-up strategy. Ongoing trials are addressing this issue, but their results are pending. Therefore, no specific recommendation with respect to the intensity of follow-up investigations can be given at the present time.

## Acknowledgements

This consensus was made possible by the thorough and very intensive work and input of all the members of the EGCCCG who have personally or virtually participated at the consensus process and the final consensus conference, and elaborated this consensus report. Particular appreciation is given to the members of the writing committee led by R. Souchon and S. Krege, who have done the most eminent and extensive work in writing and organisation of this final manuscript, S. Krege and P. Albers for the preparation of the consensus conference, all the German authors for reviewing and evaluating the literature with respect to evidence levels for preparation of the conference, and to all members of the consensus group who have critically reviewed, agreed and signed this final consensus report.

## References

1. Collette L, Sylvester RJ, Stenning SP et al. Impact of the treating institution on survival of patients with 'poor-prognosis' metastatic nonseminoma. European Organization for Research and Treatment of Cancer Genito-Urinary Tract Cancer Collaborative Group and the Medical Research Council Testicular Cancer Working Party. *J Natl Cancer Inst* 1999; 91: 839–846 (EBM III).
2. US Department of Human Health Services. Acute pain management: operative or medical procedures and trauma. Clinical Practice Guideline No. 1. AHCPR Publication No. 92-0023. Rockville, MD: Agency for Health Care Policy and Research 1993; 107.
3. Woolf SH. Practice guidelines, a new reality in medicine II. Methods of developing guidelines. *Arch Intern Med* 1992; 152: 946–952.
4. Krege S, Schmoll H-J, Souchon R. Interdisciplinary consensus on diagnosis and treatment of testicular germ cell tumors: result of an update conference on evidence-based medicine (EBM). *Eur Urol* 2001; 40: 372–391.
5. Deutsche Krebsgesellschaft: Leitlinie zur Diagnostik und Therapie von Hodentumoren auf Grundlage evidenzbasierter Medizin (EBM). Guidelines on diagnostics and treatment of testicular germ cell tumors based on evidence based medicine (EBM). In Souchon R, Schmoll HJ, Krege S for the German Testicular Cancer Study Group (eds): Qualitätssicherung in der Onkologie, 1st edition. München-Bern-Wien-New York: Zuckschwerdt, 2002.

6. Laguna MP, Pizzocaro G, Klepp O et al. EAU guidelines on testicular cancer. EAU Working Group on Oncological Urology. *Eur Urol* 2001; 40: 102–110.
7. The Royal College of Radiologist' Clinical Oncology Network in partnership with Scottish Intercollegiate Network. (2000) Guidelines on the management of adult testicular germ cell tumours. *Clin Oncol* 2000; 12: S173–S210.
8. Bokemeyer C, Droz JP, Horwich A et al. Extragenital seminoma: an international multicenter analysis of prognostic factors and long term treatment outcome. *Cancer* 2001; 91: 1394–1401 (EBM III).
9. Scholz M, Zehender M, Thalmann GN et al. Extragenital retroperitoneal germ cell tumor: evidence of origin in the testis. *Ann Oncol* 2002; 13: 121–124 (EBM III).
10. Hartmann JT, Fossa SD, Nichols CR et al. Incidence of metachronous testicular cancer in patients with extragenital germ cell tumors. *J Natl Cancer Inst* 2001; 93: 1733–1738 (EBM III).
11. Hartmann JT, Nichols CR, Droz JP et al. Prognostic variables for response and outcome in patients with extragenital germ-cell tumors. *Ann Oncol* 2002; 13: 1017–1028 (EBM III).
12. Dieckmann KP, Loy V, Büttner P. Prevalence of bilateral testicular germ cell tumors and early detection based on contralateral testicular intra-epithelial neoplasia. *Br J Urol* 1993; 71: 340–345 (EBM IIA).
13. Osterlind A, Berthelsen JG, Abildgaard N et al. Risk of bilateral testicular germ cell tumors in Denmark: 1960–1984. *J Natl Cancer Inst* 1991; 83: 1391–1395 (EBM IIA).
14. von der Maase H, Rorth M, Walbom-Jorgensen S et al. Carcinoma in situ of contralateral testis in patients with testicular germ cell cancer: study of 27 cases in 500 patients. *Br Med J (Clin Res Ed)* 1986; 293: 1398–1401 (EBM IIA).
15. Moller H, Prener A, Skakkebaek NE. Testicular cancer, cryptorchidism, inguinal hernia, testicular atrophy and genital malformations: case-control studies in Denmark. *Cancer Causes Control* 1996; 7: 264–274 (EBM IIA).
16. Prener A, Hsieh CC, Engholm G et al. Birth order and risk of testicular cancer. *Cancer Causes Control* 1992; 3: 265–272 (EBM IIA).
17. Tollerud DJ, Blattner WA, Fraser MC et al. Familial testicular cancer and urogenital developmental anomalies. *Cancer* 1985; 55: 1849–1854 (EBM IIA).
18. Pinczowski D, McLaughlin JK, Lackgren G et al. Occurrence of testicular cancer in patients operated on for cryptorchidism and inguinal hernia. *J Urol* 1991; 146: 1291–1294 (EBM IIB).
19. Swerdlow AJ, De Stavola BL, Swanwick MA et al. Risk factor for testicular cancer: a case-control study in twins. *Br J Cancer* 1999; 80: 1098–1102 (EBM IIB).
20. Dieckmann KP, Pichlmeier U. The prevalence of familial testicular cancer. *Cancer* 1997; 80: 1954–1960 (EBM IIB).
21. Forman D, Oliver RTD, Marsh SGE et al. Familial testicular cancer: a report of the UK family register, estimation of risk and an HLA class I sib-pair analysis. *Br J Cancer* 1992; 65: 255–262 (EBM IIB).
22. Westergaard T, Olsen JH, Frisch M et al. Cancer risk in fathers and brothers of testicular cancer patients in Denmark. A population based study. *Int J Cancer* 1996; 66: 627–631 (EBM IIB).
23. Nichols CR. Testicular cancer. *Curr Probl Cancer* 1998; 22: 187–274 (EBM IV).
24. Bassetto MA, Pasini F, Franceschi T et al. Extragenital germ cell tumour: a clinical study. *Anticancer Res* 1995; 15: 2751–2754 (EBM IIA).
25. Casella R, Rochlitz C, Sauter G et al. 'Burned out' testicular tumour: a rare form of germ cell neoplasias. *Schweiz Med Wochenschr* 1999; 129: 235–240 (EBM IIA).



26. de Takats PG, Jones SR, Penn R et al.  $\alpha$ -Foetoprotein heterogeneity: what is its value in managing patients with germ cell tumours? *Clin Oncol (R Coll Radiol)* 1996; 8: 323–326. (EBM IIA).
27. Dueland S, Stenwig AE, Heilo A et al. Treatment and outcome of patients with extragonadal germ cell tumours: the Norwegian Radium Hospital's experience 1979-94. *Br J Cancer* 1998; 77: 329–335 (EBM IIA).
28. Hartmann M, Pottke T, Bussar-Maatz R et al. Elevated human chorionic gonadotropin concentrations in the testicular vein and in peripheral venous blood in seminoma patients. An analysis of various parameters. *Eur Urol* 1997; 31: 408–413 (EBM IIA).
29. van de Gaer P, Verstraete H, De Wever I et al. Primary retroperitoneal extragonadal germ cell tumour. *J Belge Radiol* 1998; 81: 221–222 (EBM IIA).
30. Leibovitch I, Little JS, Foster RS et al. Delayed orchiectomy after chemotherapy for metastatic nonseminomatous germ cell tumors. *J Urol* 1996; 155: 952–954 (EBM IIB).
31. Simmonds PD, Mead GM, Lee AHS et al. Orchiectomy after chemotherapy in patients with metastatic testicular cancer. *Cancer* 1995; 75: 1018–1024 (EBM IIB).
32. Capelouto CC, Clark PE, Ransil BJ et al. A review of scrotal violation in testicular cancer: is adjuvant local therapy necessary? *J Urol* 1995; 153: 981–985 (EBM IIA).
33. Harding M, Paul J, Kaye SB. Does delayed diagnosis or scrotal incision affect outcome for men with nonseminomatous germ cell tumors? *Br J Urol* 1995; 76: 491–494 (EBM IIB).
34. Leibovitch I, Baniel J, Foster RS et al. The clinical implications of procedural deviations during orchiectomy for nonseminomatous testis cancer. *J Urol* 1995; 154: 935–939 (EBM IIB).
35. Robertson GS. Radical orchiectomy and benign testicular conditions. *Br J Surg* 1995; 82: 342–345 (EBM IIB).
36. Elert A, Olbert P, Hegele A et al. Accuracy of frozen section examination of testicular tumors of uncertain origin. *Eur Urol* 2002; 41: 290–293 (EBM IIB).
37. Heidenreich A, Weissbach L, Höltl W et al. German Testicular Cancer Study Group. Organ sparing surgery for malignant germ cell tumor of the testis. *J Urol* 2001; 166: 2161–2165 (EBM IIB).
38. Heidenreich A, Höltl W, Albrecht W et al. Testis-preserving surgery in bilateral testicular germ cell tumours. *Br J Urol* 1997; 79: 253–257 (EBM IIB).
39. Weissbach L. Organ preserving surgery of malignant germ cell tumors. *J Urol* 1995; 153: 90–93 (EBM IIB).
40. Dieckmann KP, Loy V. Prevalence of contralateral testicular intraepithelial neoplasia in patients with testicular germ cell neoplasms. *J Clin Oncol* 1996; 14: 3126–3132 (EBM IIA + IIB).
41. Skakkebaek NE, Berthelsen JG, Müller J. Carcinoma in situ of the undescended testis. *Urol Clin North Am* 1982; 9: 377–385 (EBM IIB).
42. Harland SJ, Cook PA, Fossa SD et al. Intratubular germ cell neoplasia of the contralateral testis in testicular cancer: defining a high risk group. *J Urol* 1998; 160: 1353–1357 (EBM IIA).
43. Kliesch S, Thomaidis T, Schütte G et al. Update on the diagnostic safety for detection of testicular intraepithelial neoplasia (TIN). *APMIS* 2003; 111: 70–75 (EBM IIB).
44. Giwercman A, Cantell L, Marks A. Placental-alkaline phosphatase as a marker of carcinoma-in-situ of the testis. Comparison with monoclonal antibodies M2A and 43-9F. *APMIS* 1991; 99: 586–594 (EBM IIB).
45. Giwercman A, Andrews PW, Jorgensen P et al. Immunohistochemical expression of embryonal marker TRA-1-60 in carcinoma in situ and germ cell tumors of the testis. *Cancer* 1993; 72: 1308–1314 (EBM IIB).
46. Daugaard G, Rørth M, von der Maase H, Skakkebaek NE. Management of extragonadal germ cell tumors and the significance of bilateral testicular biopsies. *Ann Oncol* 1992; 3: 283–289 (EBM IIB).
47. Fossa SD, Aass N, Heilo A et al. Testicular carcinoma in situ in patients with extragonadal germ-cell tumours: the clinical role of pre-treatment biopsy. *Ann Oncol* 2003; 14: 1412–1418 (EBM III).
48. Heidenreich A, Vorreuther R, Neubauer S et al. Paternity in patients with bilateral testicular germ cell tumors. *Eur Urol* 1997; 31: 246–248 (EBM IV).
49. Dieckmann KP, Besserer A, Loy V. Low-dose radiation therapy for testicular intraepithelial neoplasia. *J Cancer Res Clin Oncol* 1993; 119: 355–359 (EBM III).
50. Dieckmann KP, Loy V. The value of the biopsy of the contralateral testis in patients with testicular germ cell cancer: the recent German experience. *APMIS* 1998; 106: 13–20 (EBM IIB + III).
51. Petersen PM, Giwercman A, Skakkebaek NE, Rørth M. Gonadal function in men with testicular cancer. *Semin Oncol* 1998; 25: 224–233 (EBM III).
52. Christensen TB, Daugaard G, Geertsen PF et al. Effect of chemotherapy on carcinoma in situ of the testis. *Ann Oncol* 1998; 9: 657–660 (EBM IIB).
53. Petersen PM, Giwercman A, Daugaard G et al. Effect of graded testicular doses of radiotherapy in patients treated for carcinoma-in-situ in the testis. *J Clin Oncol* 2002; 20: 1537–1543 (EBM IIB).
54. Classen J, Dieckmann KP, Bamberg M et al. Radiotherapy with 16 Gy may fail to eradicate testicular intraepithelial neoplasia (TIN): preliminary communication of a dose-reduction trial of the German Testicular Cancer Study Group. *Br J Cancer* 2003; 88: 828–831 (EBM IIB).
55. von Ostau C, Krege S, Hartmann M, Rübber H. Metachronous contralateral germ cell tumor 7 years after management of testicular intraepithelial neoplasia by chemotherapy and multiple control biopsies. *Scand J Urol Nephrol* 2001; 35: 430–431 (EBM III).
56. Classen J, Dieckmann KP. Radiotherapy of carcinoma in situ of the testis. *J Clin Oncol* 2002; 20: 3559–3560 (EBM IV).
57. Mostofi FK, Sesterhenn IA. Histological typing of testis tumours. WHO International Histological Classification of Tumours, 2nd edition. Berlin-Heidelberg-New York-Tokyo: Springer 1998.
58. Sobin LH, Wittekind Ch (eds): UICC: TNM classification of malignant tumours, 6th edition. New York: Wiley-Liss 2002.
59. International Germ Cell Cancer Collaborative Group (IGCCCG). The International Germ Cell Consensus Classification: a prognostic factor based staging system for metastatic germ cell cancer. *J Clin Oncol* 1997; 15: 594–603 (EBM IA/IIA/IIB/III).
60. Warde P, Specht L, Horwich A et al. Prognostic factors for relapse in stage I seminoma managed by surveillance. *J Clin Oncol* 2002; 20: 4448–4452 (EBM IIB).
61. Warde P, Gospodarowicz MK, Banerjee D et al. Prognostic factors for relapse in stage I testicular seminoma treated with surveillance. *J Urol* 1997; 157: 1705–1710 (EBM IIBA).
62. Weissbach L, Bussar-Maatz R, Löhns U et al. Prognostic factors in seminomas with special respect to HCG: results of a prospective multicenter study. *Eur Urol* 1999; 36: 601–608 (EBM IIA + III).
63. Horwich A, Alsanjari N, A'Hearn R et al. Surveillance following orchiectomy for stage I testicular seminoma. *Br J Cancer* 1992; 65: 775–778 (EBM III).
64. Albers P, Siener R, Kliesch S et al. Risk factors for relapse in clinical stage I nonseminomatous testicular germ cell tumors: results of the German Testicular Cancer Study Group trial. *J Clin Oncol* 2003; 21: 1505–1512 (EBM IB).
65. Böhlen D, Borner M, Sonntag RW et al. Long term results following adjuvant chemotherapy in patients with clinical stage I testicular

- nonseminomatous malignant germ cell tumors with high risk factors. *J Urol* 1999; 161: 1148–1152 (EBM IIA).
66. Klepp O, Dahl O, Flodgren P et al. Risk-adapted treatment of clinical stage I non-seminoma testis cancer. *Eur J Cancer* 1997; 33: 1038–1044 (EBM IIA).
  67. Kratzik Ch, Hörtl W, Albrecht W et al. Risk adapted management for NSGCT stage I: long-term results of a multicenter study. *J Urol* 1996; 157: 547A (EBM IIA).
  68. Ondrus D, Matoska J, Belan V et al. Prognostic factors in clinical stage I nonseminomatous germ cell testicular tumors: rationale for different risk-adapted treatment. *Eur Urol* 1998; 33: 562–566 (EBM IIA+IIB).
  69. Pont J, Hörtl W, Kosak D et al. Risk-adapted treatment choice in stage I nonseminomatous testicular germ cell cancer by regarding vascular invasion in the primary tumor: a prospective trial. *J Clin Oncol* 1990; 8: 16–19 (EBM IIA).
  70. Albers P, Ulbright TM, Albers J et al. Tumor proliferative activity is predictive of pathological stage in clinical stage A non-seminomatous testicular germ cell tumors. *J Urol* 1996; 155: 579–586 (EBM IIB).
  71. Madej G, Pawinski A. Risk-related adjuvant chemotherapy for stage I non-seminoma of the testis. *Clin Oncol* 1991; 3: 270–272 (EBM IIB).
  72. Read G, Stenning SP, Cullen MH et al. Medical Research Council prospective study of surveillance for stage I testicular teratoma. Medical Research Council Testicular Tumors Working Party. *J Clin Oncol* 1992; 10: 1762–1768 (EBM IIB).
  73. Sogani PC, Perrotti M, Herr HW et al. Clinical stage I testis cancer: long term outcome of patients on surveillance. *J Urol* 1998; 159: 855–858 (EBM IIB+III).
  74. White PM, Howard GC, Best JJ et al. The role of computed tomographic examination of the pelvis in the management of testicular germ cell tumours. *Clin Radiol* 1997; 52: 124–129 (EBM IIB).
  75. Moul JW, McCarthy WF, Fernandez EB et al. Percentage of embryonal carcinoma and vascular invasion predict pathologic stage in clinical stage I non-seminomatous testicular cancer. *Cancer Res* 1994; 54: 1–3 (EBM III).
  76. Alexandre J, Fizazi K, Mahe C et al. Stage I non-seminomatous germ-cell tumours of the testis: identification of a subgroup of patients with a very low risk of relapse. *Eur J Cancer* 2001; 37: 576–582.
  77. Heidenreich A, Schenkman NS, Sesterhenn IA et al. Immunohistochemical expression of Ki-67 to predict lymph node involvement in clinical stage I nonseminomatous germ cell tumors. *J Urol* 1997; 158: 620–625 (EBM IIB).
  78. Heidenreich A, Sesterhenn IA, Mostofi FK et al. Prognostic factors that identify patients with clinical stage I nonseminomatous germ cell tumors at low risk and high risk for metastasis. *Cancer* 1998; 83: 1002–1011 (EBM III).
  79. Albers P, Bierhoff E, Neu D et al. MIB-1 immunohistochemistry predicts patients at low risk of metastasis in clinical stage I non-seminomatous testicular germ cell tumors. *Cancer* 1997; 79: 1710–1716 (EBM III).
  80. de Riese WT, Albers P, Walker EB et al. Predictive parameters of biologic behavior of early stage nonseminomatous testicular germ cell tumors. *Cancer* 1994; 74: 1335–1341 (EBM III).
  81. Nicolai N, Pizzocaro GA. A surveillance study of clinical stage I nonseminomatous germ cell tumors of the testis: a 10-year follow up. *J Urol* 1995; 154: 1045–1049 (EBM III).
  82. Sweeney CJ, Hermans BP, Heilman DK et al. Results and outcome of retroperitoneal lymph node dissection for clinical stage I embryonal carcinoma-predominant testis cancer. *J Clin Oncol* 2000; 18: 358–362 (EBM III).
  83. Javadpour N, Canning DA, O'Connell KJ et al. Predictors of recurrent clinical stage I nonseminomatous testicular cancer. A prospective clinicopathologic study. *Urology* 1986; 27: 508–511 (EBM III).
  84. Sesterhenn IA, Weiss RB, Mostofi FK et al. Prognosis and other clinical correlates of pathologic review in stage I and II testicular carcinoma: a report from the Testicular Cancer Intergroup Study. *J Clin Oncol* 1992; 10: 69–78 (EBM III).
  85. Lijmer JG, Mol BW, Heisterkamp S et al. Empirical evidence of design-related bias in studies of diagnostic tests. *JAMA* 1999; 282: 1061–1066.
  86. Gospodarowicz MK, Sturgeon JFG, Jewett MAS. Early stage and advanced seminoma: role of radiation therapy, surgery, and chemotherapy. *Semin Oncol* 1998; 25: 160–173.
  87. Krug B, Heidenreich A, Dietlein M et al. Lymphknotenstaging maligner testikulärer Keimzelltumoren. *Fortschr Röntgenstr* 1999; 171: 87–94.
  88. Lashley D, Lowe B. A rational approach to managing stage I non-seminomatous germ cell cancer. *Urol Clin North Am* 1998; 25: 405–423.
  89. Leibovitch I, Foster RS, Kopecky KK et al. Identification of clinical stage A nonseminomatous testis cancer patients at extremely low risk for metastatic disease: a combined approach using quantitative immunohistochemical, histopathologic, and radiologic assessment. *J Clin Oncol* 1998; 16: 261–268.
  90. White PM, Howard GC, Best JJ et al. The role of computed tomographic examination of the pelvis in the management of testicular germ cell tumours. *Clin Radiol* 1997; 52: 124–129 (EBM IIB).
  91. White PM, Adamson DJA, Howard GCW et al. Imaging of the thorax in the management of germ cell testicular tumours. *Clin Radiol* 1999; 54: 207–211 (EBM IIB+III).
  92. Meyer CA, Conces DJ. Imaging of intrathoracic metastases of non-seminomatous germ cell tumors. *Chest Surg Clin N Am* 2002; 12: 717–738.
  93. See WA, Hoxie L. Chest staging in testis cancer patients: imaging modality selection based upon risk assessment as determined by abdominal computerized tomography scan results. *J Urol* 1993; 150: 874–878.
  94. Leibovitch I, Foster RS, Kopecky KK et al. Improved accuracy of computerized tomography based clinical staging in low stage non-seminomatous germ cell tumor using size criteria of retroperitoneal lymph nodes. *J Urol* 1995; 154: 1759–1763.
  95. McLeod DG, Weiss RB, Stablein DM et al. Staging relationships and outcome in early stage testicular cancer: a report from the Testicular Cancer Intergroup Study. *J Urol* 1991; 145: 1178–1183.
  96. Bellin M, Roy C, Kinkel K et al. Lymph node metastases: safety and effectiveness of MR imaging with ultrasmall superparamagnetic iron oxide particles: initial clinical experience. *Radiology* 1998; 207: 799–808.
  97. Hogeboom WR, Hoekstra HJ, Mooyart EL et al. Magnetic resonance imaging of retroperitoneal lymph node metastases of non-seminomatous germ cell tumors of the testis. *Eur J Surg Oncol* 1993; 19: 429–437.
  98. Lassen U, Daugaard G, Eigtved A et al. Wholebody positron emission tomography (PET) with FDG in patients with stage I non-seminomatous germ cell tumours (NSGCT). *Eur J Nucl Med Imaging* 2003; 30: 396–402.
  99. Albers P, Bender H, Yilmaz H et al. Positron emission tomography in the clinical staging of patients with stage I and II germ cell tumors. *Urology* 1999; 53: 808–811.
  100. Cremerius U, Wildberger JE, Borchers H et al. Does positron emission tomography using 18-fluoro-2-deoxyglucose improve clinical

- staging of testicular cancer? Results of a study of 50 patients. *Urology* 1999; 54: 900–904.
101. Hoh CK, Seltzer MA, Franklin J et al. Positron emissions tomography in urological oncology. *J Urol* 1998; 159: 347–356.
  102. Weber WA, Avril N, Schwaiger M. Relevance of positron emission tomography (PET) in oncology. *Strahlenther Onkol* 1999; 175: 356–376.
  103. Tsatalpas P, Beuthien-Baumann B, Kropp J et al. Diagnostic value of 18F-FDG positron emission tomography for detection and treatment control of malignant germ cell tumors. *Urol Int* 2002; 68: 157–163.
  104. Spermon JR, De Geus-Oei LF, Kiemeneij LA et al. The role of 18-fluoro-2-deoxyglucose positron emission tomography in initial staging and re-staging after chemotherapy for testicular germ cell tumours. *BJU Int* 2002; 89: 549–556.
  105. Bokemeyer C, Nowak P, Haupt A et al. Treatment of brain metastases in patients with testicular cancer. *J Clin Oncol* 1997; 15: 1449–1454 (EBM III).
  106. Fossa SD, Bokemeyer C, Gerl A et al. Treatment outcome of patients with brain metastases from malignant germ cell tumors. *Cancer* 1999; 85: 988–997 (EBM III).
  107. DeSantis M, Albrecht W, Höltl W, Pont J. Impact of cytotoxic treatment on long-term fertility in patients with germ-cell cancer. *Int J Cancer* 1999; 83: 864–865 (EBM III).
  108. Jacobsen KD, Fossa SD, Bjoro TP et al. Gonadal function and fertility in patients with bilateral testicular germ cell malignancy. *Eur Urol* 2002; 42: 229–238. Discussion 237–238 (EBM III).
  109. Fossa SD, Dahl AA, Haaland CF. Health-related quality of life in patients treated for testicular cancer. *Curr Opin Urol* 1999; 9: 425–429 (EBM IV).
  110. Kliesch S, Behre HM, Jürgens H et al. Cryopreservation of semen from adolescent patients with malignancies. *Med Pediatr Oncol* 1996; 26: 20–27 (EBM IV).
  111. Kliesch S, Kamischke A, Nieschlag E. Cryopreservation of sperm. In Nieschlag E, Behre HM (eds): *Andrology—Male Reproductive Health and Dysfunction*. Berlin-Heidelberg-New York: Springer 1997; 349–358 (EBM IV).
  112. Dieckmann KP, Loy V. Paternity in a patient with testicular seminoma and contralateral testicular intraepithelial neoplasia. *Int J Androl* 1993; 16: 143–146 (EBM IV).
  113. Giwercman A, von der Maase H, Rorth M et al. Semen quality in testicular tumour and CIS in the contralateral testis. *Lancet* 1993; 341: 384–385 (EBM IV).
  114. Giwercman A, von der Maase H, Rorth M et al. Current concepts of radiation treatment of carcinoma in situ of the testis. *World J Urol* 1994; 12: 125–130 (EBM III+IV).
  115. Heidenreich A, Vorreuther R, Neubauer S et al. Paternity in patients with bilateral testicular germ cell tumors. *Eur Urol* 1997; 31: 246–248 (EBM IV).
  116. Kliesch S, Bergmann M, Hertle L et al. Semen parameters and testicular pathology in men with testicular cancer and contralateral carcinoma in situ or bilateral testicular malignancies. *Hum Reprod* 1997; 12: 2830–2835 (EBM IV).
  117. Nieschlag E, Behre HM. Pharmacology and clinical use of testosterone. In Nieschlag E, Behre HM (eds): *Testosterone: Action, Deficiency, Substitution*. Berlin-Heidelberg-New York: Springer 1999; 92–114.
  118. Dodds L, Marrett LD, Tomkins DJ et al. Case-control study of congenital anomalies in children of cancer patients. *Br Med J* 1993; 307: 164–168 (EBM III).
  119. Warde PR, Gospodarowicz MK, Goodman PJ et al. Results of a policy of surveillance in stage I testicular seminoma. *Int J Radiat Oncol Biol Phys* 1993; 27: 11–15 (EBM IIB).
  120. Warde P, Gospodarowicz MK, Panzarella T et al. Stage I testicular seminoma: results of adjuvant irradiation and surveillance. *J Clin Oncol* 1995; 13: 2255–2262 (EBM IIB).
  121. Dieckmann KP, Brüggelboes B, Pichlmeier U et al. Adjuvant treatment of clinical stage I seminoma: is one single course of carboplatin sufficient? *Urology* 2000; 55: 102–106 (EBM IIB).
  122. Mason M, Jones W. Treatment of stage I seminoma: more choice, more dilemmas. *Clin Oncol* 1997; 9: 210–212 (EBM IIB).
  123. Krege S, Kalund G, Otto T et al. Phase II study: adjuvant single-agent carboplatin therapy for clinical stage I seminoma. *Eur Urol* 1997; 31: 405–407 (EBM IIB).
  - 123a. Oliver RT, Mason M, Von der Masse H et al. on behalf of the MRC Testis Tumour Group and the EORTC GU Group. A randomised comparison of single agent carboplatin with radiotherapy in the adjuvant treatment of stage I seminoma of the testis, following orchidectomy: MRC TE19/EORTC 30982. *Proc Am Soc Clin Oncol* 2004; 23: 385 (Abstr 4517) (EBM IB).
  124. Fossa SD, Horwich A, Russel JM. Optimal planning target volume for stage I testicular seminoma: a Medical Research Council randomized trial. *J Clin Oncol* 1999; 17: 1146–1154 (EBM IB).
  125. Jones WG, Fossa SD, Mead GM et al. A randomised trial of two radiotherapy schedules in the adjuvant treatment of stage I seminoma (MRC TE 18). *Eur J Cancer* 2001; 37 (Suppl 6): S157 (Abstr 572) (EBM IB).
  126. Bamberg M, Schmidberger H, Meisner C et al. Radiotherapy for stage I, IIA/B testicular seminoma. *Int J Cancer* 1999; 83: 823–827 (EBM IIA).
  127. Kiricuta IO, Sauer J, Bohndorf W. Omission of the pelvic irradiation in stage I testicular seminoma: a study of postorchidectomy paraaortic radiotherapy. *Int J Radiat Oncol Biol Phys* 1996; 35: 293–298 (EBM IIA).
  128. Logue JP, Mobarek N, Read G. Short fractionation para-aortic radiotherapy for stage I seminoma of the testis. *Radiother Oncol* 1998; 48 (Suppl 1): 10 (EBM III).
  129. Joos H, Sedlmayer F, Gomahr A et al. Endocrine profiles after radiotherapy in stage I seminoma: impact of two different radiation treatment modalities. *Radiother Oncol* 1996; 43: 159–162 (EBM IIB).
  130. Dosman MA, Zagars GK. Postorchidectomy radiotherapy for stages I and II testicular seminoma. *J Radiat Oncol Biol Phys* 1993; 26: 381–390 (EBM IIB).
  131. Zagars GK. Management of stage I seminoma: radiotherapy. In Horwich A (ed.): *Testicular Cancer: Investigation and Management*. London, UK: Chapman & Hall 1996; 99–106 (EBM IIB).
  132. Travis LB, Curtis RE, Storm H et al. Risk of second malignant neoplasms among long-term survivors of testicular cancer. *J Natl Cancer Inst* 1997; 89: 1429–1439 (EBM III).
  133. Travis L, Andersson M, Holowaty E et al. Risk of leukemia following radiotherapy and chemotherapy for testicular cancer. *Proc Am Soc Clin Oncol* 1999; 18: 308a (Abstr 1185) (EBM III).
  134. Bokemeyer C, Schmoll HJ. Secondary neoplasms following treatment of malignant germ cell tumors. *J Clin Oncol* 1993; 11: 1703–1709 (EBM III).
  135. Warde P, Jewett MAS. Surveillance for stage I testicular seminoma. Is it a good option? *Urol Clin North Am* 1998; 25: 425–433 (EBM III).
  136. Sternberg CN. The management of stage I testis cancer. *Urol Clin North Am* 1998; 25: 435–449 (EBM IIB).
  137. von der Maase H, Specht L, Jacobsen GK et al. Surveillance following orchidectomy for stage I seminoma of the testis. *Eur J Cancer* 1993; 29A: 1931–1934 (EBM IB).
  138. Baniel J, Foster RS, Gonin R et al. Late relapse of testicular cancer. *J Clin Oncol* 1995; 13: 1170–1176 (EBM III).

139. Fossa SD, Moynihan C, Serbuti S. Patients' and doctors' perception of long-term morbidity in patients with testicular cancer clinical stage I. *Support Care Cancer* 1996; 4: 118–128 (EBM III).
140. Classen J, Schmidberger H, Meisner C et al. Radiotherapy for stages IIA/B testicular seminoma: final report of a prospective multicenter clinical trial. *J Clin Oncol* 2003; 21: 1101–1106 (EBM IIB).
141. Schmidberger H, Bamberg M, Meisner C et al. Radiotherapy in stage IIA and IIB testicular seminoma with reduced portals: a prospective multicenter study. *Int J Radiat Oncol Biol Phys* 1997; 39: 321–326 (EBM IIB).
142. Patterson H, Norman AR, Mitra SS et al. Combination carboplatin and radiotherapy in the management of stage II testicular seminoma: comparison with radiotherapy treatment alone. *Radiother Oncol* 2001; 59: 5–11 (EBM IIB).
143. Zagars GK, Pollack A. Radiotherapy for stage II testicular seminoma. *Int J Radiat Oncol Biol Phys* 2001; 51: 643–649 (EBM III).
144. Bauman GS, Venkatesan VM, Ago CT et al. Postoperative radiotherapy for stage I/II seminoma: results of 212 patients. *Int J Radiat Oncol Biol Phys* 1998; 42: 313–317 (EBM III).
145. Bayens YC, Helle PA, van Putten WLJ et al. Orchiectomy followed by radiotherapy in 176 stage I and II testicular seminoma patients: benefits of a 10-year follow-up study. *Radiother Oncol* 1992; 25: 97–102 (EBM III).
146. Lai PP, Bernstein MJ, Kim H et al. Radiation therapy for stage I and IIA testicular seminoma. *Int J Radiat Oncol Biol Phys* 1994; 28: 373–379 (EBM III).
147. Vallis KA, Howard GCW, Duncan W et al. Radiotherapy for stage I and II testicular seminoma: results and morbidity in 238 patients. *Br J Radiol* 1995; 68: 400–405 (EBM III).
148. Warde P, Gospodarowicz M, Panzarella T et al. Management of stage II seminoma. *J Clin Oncol* 1998; 16: 290–294 (EBM III).
149. Whipple GL, Sagerman RH, van Rooy EM. Long-term evaluation of postorchiectomy radiotherapy for stage II seminoma. *Am J Clin Oncol* 1997; 20: 196–201 (EBM III).
150. von der Maase H. Do we have a new standard of treatment for patients with seminoma stage IIA and stage IIB? *Radiother Oncol* 2001; 59: 1–3 (EBM IV).
151. Krega S, Boergemann C, Hartmann M et al. Single-agent carboplatin for stage II-A/B testicular seminoma—a multicenter study of the German Testicular Cancer Study Group *J Urol* 2004; 171 (Suppl): 245 (Abstr 992).
152. Spermon JR, Roeleveld TA, van der Poel HG et al. Comparison of surveillance and retroperitoneal lymph node dissection in stage I nonseminomatous germ cell tumors. *Urology* 2002; 59: 923–929 (EBM IIB, EBM IIA).
153. Donohue JP, Thornhill JA, Foster RS et al. Retroperitoneal lymphadenectomy for clinical stage A testis cancer (1965–1989): modifications of technique and impact on ejaculation. *J Urol* 1993; 149: 237–243 (EBM III).
154. Fossa SD, Aass N, Winderen M et al. Long-term renal function after treatment for malignant germ-cell tumours. *Ann Oncol* 2002; 13: 187–189 (EBM IB).
155. Pont J, Albrecht W, Postner G et al. Adjuvant chemotherapy for high-risk clinical stage I nonseminomatous testicular germ cell cancer: long-term results of a prospective trial. *J Clin Oncol* 1996; 14: 441–448 (EBM IIA).
156. Cullen MH, Stenning SP, Parkinson MC et al. Short-course adjuvant chemotherapy in high-risk stage I nonseminomatous germ cell tumors of the testis: a Medical Research Council report. *J Clin Oncol* 1996; 14: 1106–1113 (EBM III).
157. Strumberg D, Brugge S, Korn MW et al. Evaluation of long-term toxicity in patients after cisplatin-based chemotherapy for non-seminomatous testicular cancer. *Ann Oncol* 2002; 13: 229–236 (EBM III).
158. Hartmann JT, Albrecht C, Schmoll HJ et al. Long term effects on sexual function and fertility after treatment of testicular cancer. *Br J Cancer* 1999; 80: 801–807 (EBM IIB).
159. Bohlen D, Burkhard FC, Mills R et al. Fertility and sexual function following orchiectomy and two cycles of chemotherapy for stage I high risk nonseminomatous germ cell cancer. *J Urol* 2001; 165: 441–444 (EBM III).
160. Weissbach L, Boedefeld EA, Horstmann-Dubral B. Surgical treatment of stage-I non-seminomatous germ cell testis tumor. *Testicular Tumor Study Group Bonn. Eur Urol* 1990; 17: 97–106 (EBM IIA).
161. Donohue JP, Thornhill JA, Foster RS et al. The role of retroperitoneal lymphadenectomy in clinical stage B testis cancer: the Indiana University experience (1965 to 1989). *J Urol* 1995; 153: 85–89 (EBM III).
162. Donohue JP, Foster RS, Rowland RG et al. Nervesparing retroperitoneal lymphadenectomy with preservation of ejaculation. *J Urol* 1990; 144: 287–292 (EBM III).
163. Heidenreich A, Albers P, Hartmann M et al. Complications of primary nerve-sparing retroperitoneal lymph node dissection on clinical stage I nonseminomatous germ cell tumors of the testis. *German Testicular Cancer Study Group. J Urol* 2003; 169: 1710–1714 (EBM III).
164. Baniel J, Foster RS, Rowland RG et al. Complications of primary retroperitoneal lymph node dissection. *J Urol* 1994; 152: 424–427 (EBM III).
165. de Bruin MJFM, Oosterhof GON, Debruyne FM. Nerve-sparing retroperitoneal lymphadenectomy for low stage testicular cancer. *Br J Urol* 1993; 71: 336–339 (EBM III).
166. Weissbach L, Bussar-Maatz R, Flechtner H et al. RPLND or primary chemotherapy in clinical stage IIA/B nonseminomatous germ cell tumors? Results of a prospective multicenter trial including quality of life assessment. *Eur Urol* 2000; 37: 582–594 (EBM IIA).
167. Williams SD, Stablein DM, Einhorn LH et al. Immediate adjuvant chemotherapy versus observation with treatment at relapse in pathological stage II testicular cancer. *N Engl J Med* 1987; 317: 1433–1438 (EBM IB).
168. Pizzocaro G, Monfardini S. No adjuvant chemotherapy in selected patients with pathological stage II nonseminomatous germ cell tumors of the testis. *J Urol* 1994; 131: 677–680 (EBM IIA).
169. Weißbach L, Hartlapp JH. Adjuvant chemotherapy of metastatic stage II non-seminomatous testis tumor. *J Urol* 1991; 146: 1285–1298 (EBM III).
170. Kennedy BJ, Torkelson JL, Fraley EE. Adjuvant chemotherapy for stage II nonseminomatous germ cell cancer of the testis. *Cancer* 1994; 73: 1485–1489 (EBM III).
171. Pont J, Albrecht W. Fertility after chemotherapy for testicular germ cell cancer. *Fertil Steril* 1997; 68: 1–5 (EBM IIA).
172. Aass N, Kaasa S, Lund E et al. Long term somatic side-effects and morbidity in testicular cancer patients. *Br J Cancer* 1990; 61: 151–155 (EBM III).
173. Peckham MJ, Hendry WF. Clinical stage II non-seminomatous germ cell testicular tumors. Results of management by primary chemotherapy. *Br J Urol* 1985; 57: 763–768 (EBM III).
174. Logothetis CJ, Samuels ML, Selig DE et al. Primary chemotherapy followed by a selective retroperitoneal lymphadenectomy in the management of clinical stage II testicular carcinoma: a preliminary report. *J Urol* 1985; 134: 1127–1130 (EBM III).
175. Horwich A, Stenning S. Initial chemotherapy for stage II testicular nonseminoma. *World J Urol* 1994; 12: 148–150 (EBM III).
176. de Wit R, Stoter G, Kaye SB et al. Importance of bleomycin in combination chemotherapy for good-prognosis testicular nonseminoma:

- a randomized study of the European Organization for Research and Treatment of Cancer Genitourinary Tract Cancer Cooperative Group. *J Clin Oncol* 1997; 15: 1837–1843 (EBM IB).
177. Horwich A, Sleijfer DT, Fossa SD et al. Randomized trial of bleomycin, etoposide, and cisplatin compared with bleomycin, etoposide, and carboplatin in good-prognosis metastatic nonseminomatous germ cell cancer: a multiinstitutional Medical Research Council/European Organization for Research and Treatment of Cancer trial. *J Clin Oncol* 1997; 15: 1844–1852 (EBM IB).
  178. Fossa SD, De Wit R, Roberts JT et al. Quality of life in good prognosis patients with metastatic germ cell cancer: a prospective study of the European Organization for Research and Treatment of Cancer Genitourinary Group/Medical Research Council Testicular Cancer Study Group (30941/TE20). *J Clin Oncol* 2003; 21: 1107–1118 (EBM IIA).
  179. Xiao H, Mazumdar M, Bajorin DF et al. Long-term follow-up of patients with good-risk germ cell tumors treated with etoposide and cisplatin. *J Clin Oncol* 1997; 15: 2553–2558 (EBM III).
  180. de Wit R, Roberts JT, Wilkinson PM et al. Equivalence of three or four cycles of bleomycin, etoposide, and cisplatin chemotherapy and of a 3- or 5-day schedule in good-prognosis germ cell cancer: a randomized study of the European Organization for Research and Treatment of Cancer Genitourinary Tract Cancer Cooperative Group and the Medical Research Council. *J Clin Oncol* 2001; 19: 1629–1640 (EBM IB).
  181. de Wit R, Stoter G, Sleijfer DT et al. Four cycles of BEP versus four cycles of VIP in patients with intermediate-prognosis metastatic testicular non-seminoma: a randomized study of the EORTC Genitourinary Tract Cancer Cooperative Group. *European Organization for Research and Treatment of Cancer. Br J Cancer* 1998; 78: 828–832 (EBM IB).
  182. Zon RT, Nichols C, Einhorn LH. Management strategies and outcomes of germ cell tumor patients with very high human chorionic gonadotropin levels. *J Clin Oncol* 1998; 16: 1294–1297 (EBM III).
  183. Bokemeyer C, Kuczyk MA, Köhne H et al. Hematopoietic growth factors and treatment of testicular cancer: biological interactions, routine use and dose intensive chemotherapy. *Ann Hematol* 1996; 72: 1–9 (EBM IIA).
  184. Fossa SD, Kaye SB, Mead GM et al. Filgrastim during combination chemotherapy of patients with poor-prognosis metastatic germ cell malignancy. *European Organization for Research and Treatment of Cancer, Genitourinary Group, and the Medical Research Council Testicular Cancer Working Party, Cambridge, UK. J Clin Oncol* 1998; 16: 716–724 (EBM IIA).
  185. de Wit R, Louwerens M, de Mulder PH et al. Management of intermediate-prognosis germ-cell cancer: results of a phase I/II study of Taxol-BEP. *Int J Cancer* 1999; 83: 831–833 (EBM III).
  186. Nichols CR, Catalano PJ, Crawford ED et al. Randomized comparison of cisplatin and etoposide and either bleomycin or ifosfamide in treatment of advanced disseminated germ cell tumors: an Eastern Cooperative Oncology Group, Southwest Oncology Group, and Cancer and Leukemia Group B Study. *J Clin Oncol* 1998; 16: 1287–1293 (EBM IB).
  187. Bokemeyer C, Kollmannsberger C, Meisner C et al. First-line high-dose chemotherapy compared with standard-dose PEB/VIP chemotherapy in patients with advanced germ cell tumors: a multivariate and matched-pair analysis. *J Clin Oncol* 1999; 17: 3450–3456 (EBM IIB).
  188. Motzer RJ, Mazumdar M, Bajorin DF et al. High-dose carboplatin, etoposide, and cyclophosphamide with autologous bone marrow transplantation in first-line therapy for patients with poor-risk germ cell tumors. *J Clin Oncol* 1997; 15: 2546–2552 (EBM IIB).
  189. Sonneveld D, Hoekstra HJ, van der Graaf WTA et al. Improved long term survival of patients with metastatic nonseminomatous testicular germ cell carcinoma in relation to prognostic classification systems during the cisplatin era. *Cancer* 2001; 91: 1304–1315 (EBM III).
  190. Kollmannsberger C, Nichols C, Bamberg M et al. First-line high-dose chemotherapy ± radiation in patients with metastatic germ-cell cancer and brain metastases. *Ann Oncol* 2000; 11: 553–559 (EBM III).
  191. Hartmann JT, Bamberg M, Albers P et al. Multidisciplinary treatment and prognosis of patients with central nervous metastases (CNS) from testicular germ cell tumor (GCT) origin. *Proc Am Soc Clin Oncol* 2003; 22: 400 (Abstr 1607) (EBM III).
  192. Spears WT, Morphis JG, Lester SG et al. Brain metastases and testicular tumors: long-term survival. *Int J Radiat Oncol Biol Phys* 1991; 22: 17–22 (EBM IIB).
  193. Schmoll HJ, Beyer J. Prognostic factors in metastatic germ cell tumors. *Semin Oncol* 1998; 25: 174–185 (EBM III).
  194. Gerl A, Clemm C, Lamerz R et al. Prognostic implications of tumour marker analysis in non-seminomatous germ cell tumours with poor prognosis metastatic disease. *Eur J Cancer* 29A 1993; 29A: 961–965 (EBM IIA).
  195. Murphy BA, Motzer RJ, Mazumdar M et al. Serum tumor marker decline is an early predictor of treatment outcome in germ cell tumor patients treated with cisplatin and ifosfamide salvage chemotherapy. *Cancer* 1994; 73: 2520–2556 (EBM IIA).
  196. Oldenburg J, Alfsen GC, Lien HH et al. Postchemotherapy retroperitoneal surgery remains necessary in patients with nonseminomatous testicular cancer and minimal residual tumor masses. *J Clin Oncol* 2003; 21: 3310–3317 (EBM III).
  197. de Wit R, Collette L, Sylvester R et al. Serum a-fetoprotein surge after the initiation of chemotherapy for non-seminomatous testicular cancer has an adverse prognostic significance. *Br J Cancer* 1998; 78: 1310–1315 (EBM IIB).
  198. Fossa SD, Stenning SP, Gerl A et al. Prognostic factors in patients progressing after cisplatin-based chemotherapy for malignant non-seminomatous germ cell tumours. *Br J Cancer* 1999; 80: 1392–1399 (EBM IIB).
  199. Andre F, Fizazi K, Culine S et al. The growing teratoma syndrome: results of therapy and long-term follow-up of 33 patients. *Eur J Cancer* 2000; 36: 1389–1394 (EBM III).
  200. Albers P, Weinknecht S, Krega S et al. Prediction of necrosis after chemotherapy of advanced germ cell tumors: results of a prospective multicenter trial of the GTCSG. *J Urol* 2002; 167 (Suppl): 172 (Abstr 690) (EBM IIB).
  201. Kamat MR, Kulkarni JN, Tongoankar HB et al. Value of retroperitoneal lymph node dissection in advanced testicular seminoma. *J Surg Oncol* 1992; 51: 65–67 (EBM IIB).
  202. Hofmockel G, Gruss A, Theiss M. Chemotherapy in advanced seminoma and the role of postcytostatic retroperitoneal lymph node dissection. *Urol Int* 1996; 57: 38–42 (EBM III).
  203. Herr HW, Sheinfeld J, Puc HS et al. Surgery for a post-chemotherapy residual mass in seminoma. *J Urol* 1997; 157: 860–862 (EBM III).
  204. Mosharafa AA, Foster RS, Leibovich BC et al. Is the postchemotherapy resection of seminomatous elements associated with higher acute morbidity? *J Urol* 2002; 167: 172 (Abstr 692) (EBM III).
  205. De Santis M, Bokemeyer C, Becherer A et al. Predictive impact of 2-18-fluoro-2-deoxy-D-glucose positron emission tomography (FDG PET) for residual postchemotherapy masses in patients with bulky seminoma. *J Clin Oncol* 2001; 19: 3740–3744 (EBM IIB).
  206. De Santis M, Becherer A, Bokemeyer C et al. FDG-PET as prognostic indicator for seminoma residuals: an update from the multicenter

- SEMPET study. *Proc Am Soc Clin Oncol* 2003; 22: 382 (Abstr 1535) (EBM III).
207. Duchesne GM, Stenning SP, Aass N et al. Radiotherapy after chemotherapy for metastatic seminoma: a diminishing role. *Eur J Cancer* 1997; 33: 829–835 (EBM III).
  208. Puc H, Heelan R, Mazumdar M et al. Management of residual mass in advanced seminoma: results and recommendations from Memorial Sloan-Kettering Cancer Center. *J Clin Oncol* 1996; 14: 454–460 (EBM IV).
  209. Toner GC, Panicek DM, Heelan RT et al. Adjunctive surgery after chemotherapy for nonseminomatous germ cell tumors: recommendations for patient selection. *J Clin Oncol* 1990; 8: 1683–1694 (EBM IIB).
  210. Fossa SD, Ous S, Lien HH et al. Post-chemotherapy lymph node histology in radiologically normal patients with metastatic nonseminomatous testicular cancer. *J Urol* 1989; 141: 557–559 (EBM IIB).
  211. Kuczyk M, Machtens S, Stief C et al. Management of the post-chemotherapy residual mass in patients with advanced stage non-seminomatous germ cell tumors (GCT). *Int J Cancer* 1999; 83: 852–855 (EBM III).
  212. Steyerberg EW, Keizer HJ, Fossa SD et al. Prediction of residual retroperitoneal mass histology after chemotherapy for metastatic nonseminomatous germ cell tumor: multivariate analysis of individual patient data from six study groups. *J Clin Oncol* 1995; 13: 1177–1187 (EBM IIB).
  213. Debono DJ, Heilman DK, Einhorn LH et al. Decision analysis for avoiding postchemotherapy surgery in patients with disseminated nonseminomatous germ cell tumors. *J Clin Oncol* 1997; 15: 1455–1464 (EBM III).
  214. Foster RS, Donohue JP. Can retroperitoneal lymphadenectomy be omitted in some patients after chemotherapy? *Urol Clin North Am* 1998; 25: 479–484 (EBM III).
  215. Steyerberg EW, Kaiser HJ, Habbema JD. Prediction models of the histology of residual masses after chemotherapy for metastatic testicular cancer. ReHiT Study Group. *Int J Cancer* 1999; 83: 856–859 (EBM III).
  216. Vergouwe Y, Steyerberg EW, De Wit R et al. External validity of a prediction rule for residual mass histology in testicular cancer: an evaluation for good prognosis patients. *Br J Cancer* 2003; 88: 843–847 (EBM III).
  217. Hartmann JT, Candelaria M, Kuczyk MA et al. Comparison of histological results from the resection of residual masses at different sites after chemotherapy for metastatic non-seminomatous germ cell tumours. *Eur J Cancer* 1997; 33: 843–847 (EBM III).
  218. Stenning SP, Parkinson MC, Fisher C et al. Postchemotherapy residual masses in germ cell tumor patients: content, clinical features, and prognosis. Medical Research Council Testicular Tumour Working Party. *Cancer* 1998; 83: 1409–1419 (EBM III).
  219. Hendry WF, Norman AR, Dearnaley DP et al. Metastatic nonseminomatous germ cell tumors of the testis: results of elective and salvage surgery for patients with residual retroperitoneal masses. *Cancer* 2002; 94: 1668–1676 (EBM III).
  220. Sheinfeld J. The role of adjunctive postchemotherapy surgery for nonseminomatous germ-cell tumors: current concepts and controversies. *Semin Urol Oncol* 2002; 20: 262–271 (EBM III).
  221. Aprikian AG, Herr HW, Bajorin DF et al. Resection of post-chemotherapy residual masses and limited retroperitoneal lymphadenectomy in patients with metastatic testicular nonseminomatous germ cell tumors. *Cancer* 1994; 74: 1329–1334 (EBM IIA).
  222. Herr HW. Does necrosis on frozen-section analysis of a mass after chemotherapy justify a limited retroperitoneal resection in patients with advanced testis cancer? *Br J Urol* 1997; 80: 653–657 (EBM IIA).
  223. Wood DP, Herr HW, Heller G et al. Distribution of retroperitoneal metastases after chemotherapy in patients with nonseminomatous germ cell tumors. *J Urol* 1992; 148: 1812–1816 (EBM IIB).
  224. Hartmann JT, Schmoll HJ, Kuczyk MA et al. Postchemotherapy resections of residual masses from metastatic non-seminomatous germ cell tumors. *Ann Oncol* 1997; 8: 531–538 (EBM III).
  225. Rabbani F, Goldenberg SL, Gleave ME et al. Retroperitoneal lymphadenectomy for post-chemotherapy residual masses: is a modified dissection and resection of the residual mass sufficient? *Br J Urol* 1998; 81: 295–300 (EBM III).
  226. Hendry WF, Barrett A, McElwain JJ et al. The role of surgery in the combined management of metastases from malignant teratomas of the testis. *Br J Urol* 1980; 52: 38–44 (EBM III).
  227. Rassweiler JJ, Frede T, Lenz E et al. Long-term experience with laparoscopic retroperitoneal lymph node dissection in the management of low-stage testis cancer. *Eur Urol* 2000; 37: 251–260 (EBM III).
  228. Janetschek G, Peschel R, Hobisch A et al. Laparoscopic retroperitoneal lymph node dissection. *J Endourol* 2001; 15: 449–455 (EBM III).
  229. Steiner H, Peschel R, Hoeltl L et al. Laparoscopic retroperitoneal lymph node dissection is feasible after chemotherapy for retroperitoneal stage II nonseminomatous germ cell tumors. *J Urol* 2002; 167: 170 (Abstr 684) (EBM III).
  230. Fizazi K, Tjulandin S, Salvioni R et al. Viable malignant cells after primary chemotherapy for disseminated nonseminomatous germ cell tumors: prognostic factors and role of postsurgery chemotherapy—results from an international study. *J Clin Oncol* 2001; 19: 2647–2657 (EBM III).
  231. Miller KD, Loehrer PJ, Gonin R et al. Salvage chemotherapy with vinblastine, ifosfamide, and cisplatin in recurrent seminoma. *J Clin Oncol* 1997; 15: 1427–1431 (EBM IIB).
  232. Motzer RJ, Sheinfeld J, Mazumdar M et al. Paclitaxel, ifosfamide, and cisplatin second-line therapy for patients with relapsed testicular germ cell cancer. *J Clin Oncol* 2000; 18: 2413–2418 (EBM IIB).
  233. Loehrer PJ Sr, Gonin R, Nichols CR et al. Vinblastine plus ifosfamide plus cisplatin as initial salvage therapy in recurrent germ cell tumor. *J Clin Oncol* 1998; 16: 2500–2504 (EBM IIB).
  234. Beyer J, Rick O, Siegert W, Bokemeyer C. Salvage chemotherapy in relapsed germ cell tumors. *World J Urol* 2001; 19: 90–93 (EBM IIB).
  235. Beyer J, Stenning S, Gerl A et al. High-dose versus conventional-dose chemotherapy as first-salvage treatment in patients with non-seminomatous germ-cell tumors: a matched pair analysis. *Ann Oncol* 2002; 13: 599–605 (EBM IIB).
  236. Kaye SB, Mead GM, Fossa S et al. Intensive induction-sequential chemotherapy with BOP/VIP-B compared with treatment with BEP/EP for poor prognosis metastatic germ cell tumor: a randomized Medical Research Council/European Organization for Research and Treatment of Cancer study. *J Clin Oncol* 1998; 16: 692–701 (EBM IIB).
  237. Rosti G, Pico JL, Wandt H et al. High-dose chemotherapy (HDC) in the salvage treatment of patients failing first-line platinum chemotherapy for advanced germ cell tumors (GCT); first results of a prospective randomised trial of the European Group for Blood and Marrow Transplantation (EBMT): IT-94 study. *Proc Ann Soc Clin Oncol* 2002; 21: 180a (Abstr 716) (EBM IB).
  238. Murphy BR, Breeden ES, Donohue JP et al. Surgical salvage of chemorefractory germ cell tumors. *J Clin Oncol* 1993; 11: 324–329 (EBM III).
  239. Eastham JA, Wilson TG, Russell C et al. Surgical resection in patients with nonseminomatous germ cell tumor who fail to normalize serum tumor markers after chemotherapy. *Urology* 1994; 43: 74–80 (EBM III).

240. Kisbenedek L, Bodrogi I, Szeldeli P et al. Results of salvage retroperitoneal lymphadenectomy (RLA) in the treatment of patients with nonseminomatous germ cell tumors remaining marker positive after inductive chemotherapy. *Int Urol Nephrol* 1995; 27: 325–329 (EBM III).
241. Coogan CL, Foster RS, Rowland RG et al. Postchemotherapy retroperitoneal lymph node dissection is effective therapy in selected patients with elevated tumor markers after primary chemotherapy alone. *Urology* 1997; 50: 957–962 (EBM III).
242. Ravi R, Ong J, Oliver RT et al. Surgery as salvage therapy in chemotherapy-resistant nonseminomatous germ cell tumors. *Br J Urol* 1998; 81: 884–888 (EBM III).
243. Albers P, Ganz A, Hannig E et al. Salvage surgery of chemorefractory germ cell tumors with elevated tumor markers. *J Urol* 2000; 164: 381–384 (EBM III).
244. Gerl A, Clemm C, Schmeller N et al. Late relapse of germ cell tumors after cisplatin-based chemotherapy. *Ann Oncol* 1997; 8: 41–47 (EBM III).