

Light microscopy and molecular identification of *Sarcocystis* spp. in meat producing animals in Selangor, Malaysia

Latif, B.*, Kannan Kutty, M., Muslim, A., Hussaini, J., Omar, E., Heo, C.C., Rossle, N.F., Abdullah, S., Kamarudin, M.A. and Zulkarnain, M.A.

Faculty of Medicine, Universiti Teknologi MARA, 47000 Sungai Buloh, Selangor, Malaysia

*Corresponding author email: bahalatif@yahoo.com

Received 22 November 2014; received in revised form 26 December 2014; accepted 2 January 2015

Abstract. One thousand and forty-five tissue samples of skeletal muscles, tongue, heart, diaphragm and esophagus were collected from 209 animals (43 sheep, 89 goats and 77 cattle) from an abattoir in Selangor between February and October, 2013. Each sample was divided into three pieces with each piece measuring 2-3 mm³. Each piece was then squeezed between two glass slides and examined microscopically at x 10 magnification for the presence of sarcocystosis. Three positive samples from each animal species were then fixed in 10% formalin for histological processing. Seven positive samples collected from each animal species were preserved at -80°C or 90% ethanol for gene expression studies. Microsarcocysts were detected in 114 (54.5%) animals by light microscopy (LM). The infection rates in sheep, goat and cattle were 86, 61.8 and 28.6% respectively. The highest rate of infection was in the skeletal muscles of sheep (64.9%) and goats (63.6%) and in the heart of cattle (63.6%). The cysts were spindle to oval in shape and two stages were recognized, the peripheral merozoites and centrally located banana-shaped bradyzoites. 18S rRNA gene expression studies confirmed the isolates from the sheep as *S. ovis*, goats as *S. capracanis* and cattle as *S. bovicanis*. This, to the best of our knowledge, is the first molecular identification of an isolate of *S. ovis* and *S. capracanis* in Malaysia. Further studies with electron microscopy (EM) are required in the future to compare the features of different types of *Sarcocystis* spp.

INTRODUCTION

Sarcocystosis is a zoonotic disease caused by coccidian intracellular protozoan of the genus *Sarcocystis* (Levine, 1986). *Sarcocystis* spp. require two hosts to complete its life cycle; with the sexual cycle in the intestine of a carnivore as a definitive host and asexual cycle in the tissues of a herbivore as an intermediate hosts (Dubey, 1976; Fayer, 2004). Four species of *Sarcocystis* have been reported in sheep, namely; *Sarcocystis ovis* and *Sarcocystis arieticanis* that are transmissible by canids, and *Sarcocystis ovifelis* and *Sarcocystis medusiformis* that are transmissible by felids. In goats, *Sarcocystis capracanis* and *Sarcocystis hircicanis* are transmissible via canids and in cattle,

Sarcocystis bovicanis is transmitted via canids, whereas *Sarcocystis hirsute* and *Sarcocystis hominis* via felids and human respectively (Levine, 1986; Dubey *et al.*, 1989).

Diagnosis of muscular sarcocystosis is by way of examination of tissue samples from infected hosts, primarily from the skeletal muscle, tongue, heart, diaphragm, and esophagus. Two types of *Sarcocystis* cyst have been identified; macroscopic cyst that is visible to the naked eye and microscopic cyst that can be detected microscopically. Light microscopy and ultrastructural studies have shown different species of *Sarcocystis* among livestock. Serological tests such as enzyme-linked immunosorbent assay (ELISA) and indirect fluorescent antibody test (IFAT) has also been used to detect

sarcocystosis in animals and humans (Thomas & Dissanaïke, 1978; Latif *et al.*, 1999). In recent years, polymerase chain reaction (PCR) has been used for the identification of *Sarcocystis* spp. in animals and humans. PCR has better sensitivity and specificity in parasite detection and is able to screen a large number of samples compared to electron microscopy (Pritt *et al.*, 2008). Numerous studies on sarcocystosis using PCR in cattle (Pritt *et al.*, 2008; More *et al.*, 2011), camel (Motamedi, 2011), captive bear (Davies *et al.*, 2011), water buffaloes (Oryan *et al.*, 2011), pigeons (Olias *et al.*, 2013), pigs (Yan *et al.*, 2013), and other animals (Fayer, 2004) have been reported.

In Malaysia, most studies performed e.g. on animals in the wild (Zaman, 1970), monkeys (Prathap, 1973), rodents (Dissanaïke *et al.*, 1975; Zaman & Colley, 1975; Kan & Dissanaïke, 1976; Lai, 1977; Ambu *et al.*, 2011), bandicoot (Kan, 1979), zoo animals (Dissanaïke *et al.*, 1977; Latif *et al.*, 2010), water buffaloes (Dissanaïke *et al.*, 1977; Dissanaïke & Kan, 1978; Kan & Dissanaïke, 1978), sheep (Norlida *et al.*, 2012) and cattle (Latif *et al.*, 2013) for the identification of sarcocystosis have depended on the morphology, size of the cyst, and the thickness of the cyst wall. There are relatively few studies that have used PCR for identification of *Sarcocystis* sp. in Malaysia (Latif *et al.*, 2013). The aims of this study therefore were to identify the common species of *Sarcocystis* using PCR, and their prevalence in sheep, goat and cattle slaughtered in one of the large abattoirs in Selangor.

MATERIALS AND METHODS

Collection of samples

One thousand and forty-five tissue samples (n=1045) were collected from 209 animals (43 sheep, 89 goats, 77 cattle) from an abattoir in Selangor, Malaysia between February and October 2013. Tissue samples weighing about 200 g each were taken from the tongue, heart, diaphragm, esophagus and skeletal muscle and transferred immediately in self-sealing plastic bags to the parasitology

lab at the Faculty of Medicine, Universiti Teknologi MARA (UiTM) and stored in at 4°C for further study.

Microscopic examination

Three pieces, each measuring 2-3 mm³, were cut from each tissue sample and squeezed firmly between two glass slides and examined microscopically at 10 x magnifications. Some of the tissue samples that were positive for *Sarcocystis* spp. were then stored at -80°C or in 90% ethanol for PCR studies, while some were fixed in 10% buffered neutral formalin and embedded in paraffin blocks for histological examination. The tissues were then cut into sections of 3-5 mm thickness and stained with hematoxylin and eosin (H&E).

DNA extraction and PCR

Seven samples from sheep, goat and cattle that were positive for *Sarcocystis* on light microscopy were cut into small pieces weighing 2 mg each and DNA was extracted using Gene JET Genomic DNA Purification Kit (Thermo Scientific, USA) according to the manufacturer's instruction. PCR was carried for amplification of D2 region in conserved regions of the 18S rRNA of *Sarcocystis* spp. with the estimated amplicon size of 350bp. PCR amplification was carried out using Phusion Flash PCR Master Mix (Thermo Scientific, USA) where forward primer SAD2F (5'-GGAAGCGATTGGAACC-3') and reverse primer SAD2R (5'-CCTTGGTCCGTGTTTCA-3' (Wunschmann, 2011) were used. All amplification reactions were performed using Mastercycler Gradient (Eppendorf, Germany). Reaction mixture consisted of 200 pM of each primer, 25µl of 2X Phusion Flash PCR Master Mix, 2µl DNA template, and topped with nuclease-free water to a volume of 50µl. The thermal profile consisted of initial denaturation at 94°C for 2 minutes, followed by 40 cycles of 30 seconds denaturation at 95°C, 30 seconds annealing at 55°C, and 1 minute extension at 72°C, with a 10 minute final extension at 72°C. Gel electrophoresis was done to validate the presence of amplified PCR product before being processed for sequencing. The gel was viewed and analyzed using GelDocXr +

System (Bio-Rad Laboratories, USA) and MyImage Analysis Software (Thermo Scientific, USA). PCR product purification was done using GeneJET Gel Extraction and DNA Clean-Up Kit (Thermo Scientific, USA). The sequencing process was carried out in First BASE Laboratories, Malaysia. Similarity between sequences from this study and the sequences deposited in the GenBank was searched using NCBI basic local alignment search tool (BLAST) (www.ncbi.nlm.nih.gov/blast) to obtain *Sarcocystis* spp. genotype from the samples.

RESULTS

Light microscopy

Of 209 animals examined, 114 (54.5%) were positive for *Sarcocystis* spp on light microscopy. The infection rates were 86%, 61.8% and 28.6% in sheep, goat and cattle respectively (Table 1). According to the organs, sarcocysts were identified in the skeletal muscle (64.9%), diaphragm (48.6%), heart (43.2%), tongue (40.5%), esophagus (35.1%) in sheep; skeletal muscle (63.6%), diaphragm (49.1%), tongue (47.3%), esophagus (29.1%), heart (5.5%) in goats; and heart (63.6%), tongue (40.9%), skeletal muscle (27.3%), esophagus (27.3%) in cattle.

The cysts were spindle to oval in shape, and two stages were recognized, namely; the peripheral merozoites and centrally located banana-shaped bradyzoites (Figure 1). The mean sizes of the cyst were 172.96µm x 53.64µm, 131.68µm x 49.49µm, and 151.66µm x 75.83µm for sheep, goat and cattle respectively. The wall thickness was 2.85, 1.56 and 2.47µm for sheep, goat and cattle respectively. The size of the bradyzoite was

10.43µm x 2.24µm for sheep, 9.34µm x 2.88µm for goat and 15.23µm x 2.2µm for cattle (Table 2).

PCR analysis

Parasite-specific 18S rRNA gene PCR confirmed *S. oivicanis* in the sheep (97% sequence similarity with Gene Bank accession no. AF076899); *S. capracanis* in goat (98% sequence similarity with GeneBank accession no.AF012885); and *S. bovicanis* in cattle (97% sequence similarity with GeneBank accession no.AF076903) (Table 3).

Gel electrophoresis analysis of the PCR isolates showed the DNA fragment size ranging between 300 and 350 bp (Figure 2). No band was detected for negative control. The sequencing results after nucleotide sequencing were aligned with other *Sarcocystis* sequences deposited in the GenBank database, using NCBI BLAST software, which revealed that all the isolates from sheep matched with *S. oivicanis*, from the goat with *S. capracanis* and from the cattle with *S. bovicanis*.

DISCUSSION

This is the first prevalence study combining light microscopy and molecular identification of *Sarcocystis* spp in tissue samples from sheep, goat and cattle in Malaysia.

The overall prevalence of micro-sarcocyst was 54.5%. Norlida *et al.* (2012) had reported a prevalence of 52.8% in sheep in the state of Kelantan. Latif *et al.* (2013) found the infection rate in cattle in Selangor at 36.2%. In this study the infection rates in sheep, goat and cattle were 86%, 61.8% and 28.6% respectively. The difference in the rate of infection in sheep and cattle might be attributed to the sample size in addition to the different regions and the availability of the definitive hosts (canids). The prevalence of *Sarcocystis* infection (28.6–86%) in this study was lower than that reported in many other countries. Some of the reported prevalence rates include 84.0% in sheep in the United States (Dubey *et al.*, 1989) 82.4%

Table 1. Prevalence of sarcocystosis in sheep, goats and cattle by light microscopy

Animal species	No. of samples	No. of positive (%)
Sheep	43	37 (86)
Goats	89	55 (61.8)
Cattle	77	22 (28.6)
Total	209	114 (54.5)

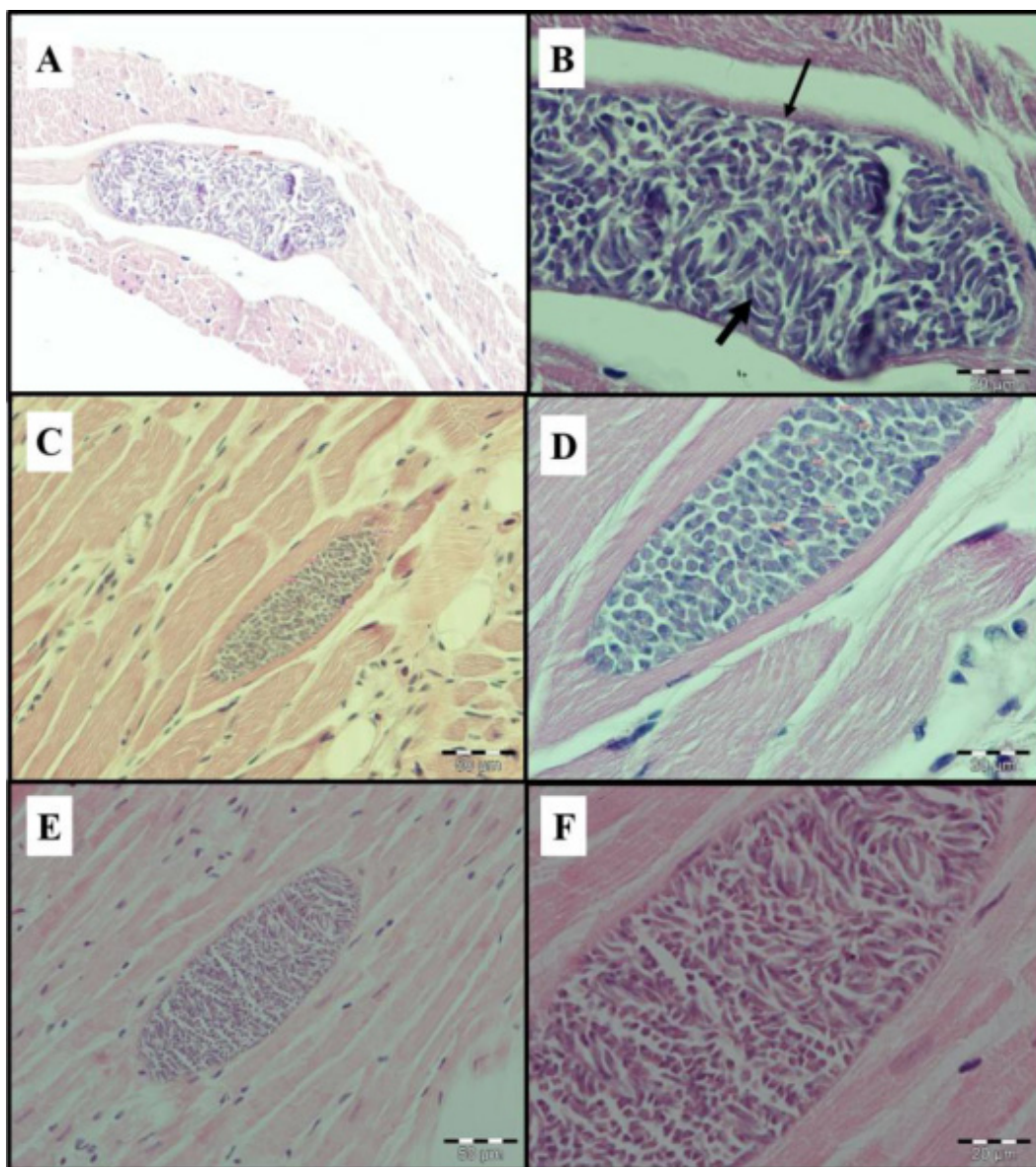


Figure 1. Microsporocysts in histological tissues of animals stained with Hematoxylin & eosin (H&E) and viewed under compound microscope. A and B: Heart of sheep x40, x100; C and D: Tongue of goat x40, x100; E and F: Muscle of cattle x40, x100. Thin arrow in B: cyst wall; thick arrow: bradyzoites.

Table 2. Size and morphology of sarcocysts of sheep, goats and cattle

Species	Organ	Shape	Size / μm	Wall / μm^*	Bradyzoite/ μm
Sheep	Heart & diaphragm	Spindle to oval	172.96 x 53.64	Thin /2.85	10.43 x 2.24
Goats	Tongue & diaphragm	Spindle to oval	131.68 x 49.49	Thin /1.56	9.34 x 2.88
Cattle	Skeletal muscle	Spindle to oval	151.66 x 75.83	Thin /2.47	15.23 x 2.2

*Thin wall < 3 μm [Ref.8]. The number represents the mean thickness of the wall measured from 5 – 7 sarcocysts.

Table 3. Tissue samples of sheep, goats and cattle positive for *Sarcocystis* sp. by microscopy and species identification by PCR and genotyping

Animal No.	Species	Organ*	<i>Sarcocystis</i> spp.	Gene Bank accession no.
125	sheep	H	<i>S. ovicanis</i>	AF076899
127	sheep	E	<i>S. ovicanis</i>	AF076899
135	sheep	E	<i>S. ovicanis</i>	AF076899
136	sheep	H, E, SM	<i>S. ovicanis</i>	AF076899
137	sheep	E	<i>S. ovicanis</i>	AF076899
139	sheep	H, SM	<i>S. ovicanis</i>	AF076899
141	sheep	T, D	<i>S. ovicanis</i>	AF076899
108	goats	T, D	<i>S. capracanis</i>	AF012885
110	goats	T	<i>S. capracanis</i>	AF012885
115	goats	D	<i>S. capracanis</i>	AF012885
117	goats	SM	<i>S. capracanis</i>	AF012885
119	goats	T	<i>S. capracanis</i>	AF012885
120	goats	E, SM	<i>S. capracanis</i>	AF012885
122	goats	SM	<i>S. capracanis</i>	AF012885
005	cattle	T	<i>S. bovicanis</i>	AF076903
007	cattle	SM	<i>S. bovicanis</i>	AF076903
016	cattle	H	<i>S. bovicanis</i>	AF076903
054	cattle	H, E, T	<i>S. bovicanis</i>	AF076903
061	cattle	H	<i>S. bovicanis</i>	AF076903
066	cattle	H, E	<i>S. bovicanis</i>	AF076903
086	cattle	SM	<i>S. bovicanis</i>	AF076903

* SM : skeletal muscle; T : tongue; H : heart; D : diaphragm; E : esophagus

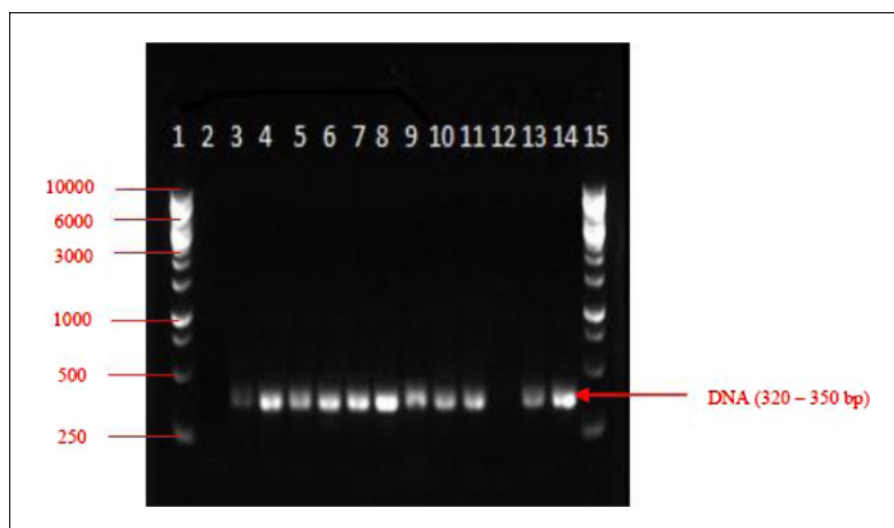


Figure 2. Electrophoresis of PCR product of *Sarcocystis* isolated from sheep, goats and cattle. The DNA fragment size ranged between 300 and 350 bp. Lane 1 and 15: 1kb DNA Ladder, lane 2 negative control and lane 3 to 14 PCR product from selected tissues.

in the cattle in Australia (Savini *et al.*, 1992), 97.0% in sheep, 97.4% in goat and 97.8% in cattle in Iraq (Latif *et al.*, 1999), 96.9% in sheep and 90.0% in cattle in Mongolia (Fukuyo *et al.*, 2002), 99.5% in cattle in Argentina (More *et al.*, 2011) 100% in sheep and 94.7% in cattle in Iran (Hamidinejat *et al.*, 2010; Dehaghi *et al.*, 2013). The low prevalence of sarcocystosis in meat producing animals in Malaysia in comparison with other countries could be attributed to the low population of stray dogs. Dogs are known as a definitive host of *Sarcocystis* spp. of livestock (Dubey *et al.*, 1989).

This study also showed variable rates of distribution of sarcocysts in the tissues. In sheep and goat, the infection was higher in the skeletal muscles (64.3%) followed by diaphragm (48.9%) whereas in the cattle it was in the heart (63.6%) followed by the tongue (40.9%). In Egypt, Morsy *et al.* (2011) reported that the skeletal muscle of goats was the most predominant infected site (77%) followed by diaphragm (74%). In Mongolia, Fukuyo *et al.* (2002) reported the infection rate was 100% in the tongue in the sheep and 100% in the heart in cattle. Dafedar *et al.* (2008) showed the infection rate in goats to be higher (69.45%) in the esophagus than in other tissues in Bangalore, India. It was reported that in cattle sarcocysts are most commonly found in the cardiac muscle followed by diaphragm and esophagus while in the sheep, it is in the esophagus (CFSPH, 2005). Latif *et al.* (2013) reported the infection rate was 27% in both skeletal muscle and diaphragm in cattle in Malaysia. The differences in the infection rate of the organs of sheep, goat and cattle might be due to various external factors, such as probable cyst contamination, isolates responsible for infection, or differences in the ecological habitats and nutritional status of the hosts that may lead to variations in the immunity of the host against infection (Morsy *et al.*, 2011).

In all animals, the cysts were spindle to oval in shape, and the mean sizes in each animal species were 172.96 μ m x 53.64 μ m in sheep, 131.68 μ m x 49.49 μ m in goats, and 151.66 μ m x 75.83 μ m in cattle. The wall was thin, with the thickness of 2.85 μ m in sheep,

1.56 μ m in goat and 2.47 μ m in cattle. The size of the bradyzoite was 10.43 μ m x 2.24 μ m in sheep, 9.34 μ m x 2.88 μ m in goats and 15.23 μ m x 2.2 μ m in cattle. Barham *et al.* (2004) found that the microcysts of *S. capracanis* in goats were spindle shaped and measuring 529 μ m x 62 μ m with a wall thickness of 3.2 μ m. In Egypt, Morsy *et al.* (2011) found that the microcysts of *S. capracanis* were elongated to spindle in shape with a mean size of 141.5 μ m in length and 63.5 μ m in width and a cyst wall thickness of 2 μ m. In cattle, the cyst wall of *S. bovicanis* was thin (< 1 μ m) and the size was 450 μ m x 80 μ m. Dubey (1976) reported the size of bradyzoite of *S. bovicanis* at 11–14 μ m x 2.5–3.5 μ m and Morsy *et al.* (2011) showed that the bradyzoites of *S. capracanis* measured 13–15 μ m. These differences in the size of the cysts and internal structures could be due to the age of the cyst and the strain of the *Sarcocystis* spp. (Figure 1). These variations in size and internal structures could make morphological identification a little difficult, and hence the need to use molecular based techniques like PCR to aid in the identification of sarcocystosis.

Different methods have been used for diagnosis of sarcocystosis, including muscle squash, digestion method, cross-sectional and IFAT (Dubey *et al.*, 1989; Latif *et al.*, 1999). Recently, molecular based techniques (PCR) have been used to detect *Sarcocystis* spp. in intermediate hosts (Guclu *et al.*, 2004; Pritt *et al.*, 2008). Differentiation of *Sarcocystis* spp. by PCR technique is important because some species are more pathogenic to the livestock and most importantly to detect the zoonotic species such as the cattle species *S. hominis*. In the present study, PCR identified only *S. ovicanis*, *S. capracanis*, and *S. bovicanis* in sheep, goat and cattle respectively, which are strictly animal species and no human infections have been reported from these species.

Based on our study, we recommend using the combination of muscle squash, histological and PCR methods for the detection of sarcocystosis in livestock, which will reflect the actual prevalence of the disease instead of just using single type of

detection method. Further ultrastructural studies (TEM) would shed more light on the cyst wall and internal structures of each species.

Our focus is on the combined approach in the diagnosis of sarcocystosis in Malaysia, which has hitherto not been conducted. Molecular identification established the presence of *S. ovicanis* and *S. capracanis* in this region. This will prove useful for all those involved in public health care. Identification of the species itself is a good pointer to the prevalence of these particular species here. As Malaysians have a special predilection for rearing cats it is important that the problem of the spread of sarcocystosis infection in Malaysia is well dealt with. In addition, sarcocystosis is still prevalent in animals slaughtered for human consumption in Malaysia. Hence, it is imperative to ensure that meat is well-cooked to prevent possible infection of the definitive hosts. Furthermore, this study has demonstrated the first attempt at molecular identification of *S. ovicanis* (sheep) and *S. capracanis* (goats) in Malaysia.

Acknowledgements. The authors are very grateful to the management of the Selangor State abattoir for its kind assistance in collecting the samples. This study was funded by the UiTM Excellence Fund No. 600- RMI/ DANA 5/3/RIF(50/2012).

REFERENCES

- Ambu, S., Yeoh, E.Y.S., Mak, J.W. & Chakravarthi, S. (2011). Prevalence of *Sarcocystis* spp. in rodents in Peninsular Malaysia. *International Journal of Science, Medicine & Education* **5**(2): 29-38.
- Barham, M., Stützer, H., Karanis, P., Latif, B. & Neiss, W. (2005). Seasonal variation in *Sarcocystis* species infections in goats in northern Iraq. *Parasitology* **130**(2): 151-156.
- CFSPH (The Center for food Security & Public Health (2005). Sarcocystosis. *CFSPH, Iowa*: pp 1-6.
- Dafedar, A.M., D'Souza, P.E., Ananda, K. & Puttalakshamma, G. (2008). Prevalence of sarcocystosis in goats slaughtered at an abattoir in Bangalore, Karnataka state. *Veterinary World* **1**(11): 335-337.
- Davies, J.L., Haldorson, G.J., Bradway, D.S. & Britton, A.P. (2011). Fatal hepatic sarcocystosis in a captive black bear (*Ursus americanus*) associated with *Sarcocystis canis*-like infection. *Journal of Veterinary Diagnostic Investigation* **23**(2): 379-383.
- Dehaghi, M.M., Fallahi, M., Sami, M. & Radfar, M.H. (2013). Survey of *Sarcocystis* infection in slaughtered sheep in Kerman Abattoir, Kerman, Iran. *Comparative Clinical Pathology* **22**(3): 343-346.
- Dissanaike, A. & Kan, S. (1978). Studies on *Sarcocystis* in Malaysia. *Zeitschrift für Parasitenkunde* **55**(2):127-138.
- Dissanaike, A., Kan, S., Retnasabapathy, A. & Baskaran, G. (1977). Developmental stages of *Sarcocystis fusiformis* (Railliet, 1897) and *Sarcocystis* sp., of the water buffalo, in the small intestines of cats and dogs respectively. *The Southeast Asia Journal of Tropical Medicine and Public Health* **8**(3): 417-417.
- Dissanaike, A. & Poopalachelvam, M. (1975). *Sarcocystis booliati* n. sp. and a parasite of undetermined taxonomic position, *Octoplasma garnhami* n. gen. n. sp., from the moonrat, *Echinorex gymnurus*. *The Southeast Asian Journal of Tropical Medicine and Public Health* **6**(2): 175-185.
- Dubey, J. (1976). A review of *Sarcocystis* of domestic animals and of other coccidia of cats and dogs. *Journal of the American Veterinary Medical Association* **169**(10): 1061-1078.
- Dubey, J.P., Speer, C. & Fayer, R. (1989). Sarcocystosis of animals and man: *CRC Press, Inc.*
- Fayer, R. (2004). *Sarcocystis* spp. in human infections. *Clinical Microbiology Reviews* **17**(4): 894-902.

- Fukuyo, M., Battsetseg, G. & Byambaa, B. (2002). Prevalence of *Sarcocystis* infection in meat-producing animals in Mongolia. *Southeast Asian Journal of Tropical Medicine and Public Health* **33**(3): 490-495.
- Guclu, F., Aldem-R, O. & Guler, L. (2004). Differential identification of cattle *Sarcocystis* spp. by random amplified Polymorphic DNA–Polymerase chain reaction (RAPD-PCR). *Revue de medecine veterinaire* **155**: 440-444.
- Hamidinejat, H., Razi Jalali, M. & Nabavi, L. (2010). Survey on *Sarcocystis* infection in slaughtered cattle in south-west of Iran, emphasized on evaluation of muscle squash in comparison with digestion method. *Journal of Animal and Veterinary Advances* **9**(12): 1724-1726.
- Kan, S. (1979). Ultrastructure of the cyst wall of *Sarcocystis* spp. from some rodents in malaysia. *International Journal for Parasitology* **9**(5):475-480.
- Kan, S. & Dissanaik, A. (1976). Ultrastructure of *Sarcocystis booliati* from the moon rat, *Echinosorex gymnurus* in Malaysia. *International Journal for Parasitology* **6**(4): 321-326.
- Kan, S. & Dissanaik, A. (1978). Studies on *Sarcocystis* in Malaysia. *Zeitschrift für Parasitenkunde* **57**(2): 107-116.
- Lai, P. (1977). *Sarcocystis* in Malaysian field rats. *Southeast Asian Journal of Tropical Medicine and Public Health* **8**: 417-419.
- Latif, B., Al-Delemi, J., Mohammed, B., Al-Bayati, S. & Al-Amiry, A. (1999). Prevalence of *Sarcocystis* spp. in meat-producing animals in Iraq. *Veterinary Parasitology* **84**(1): 85-90.
- Latif, B., Vellayan, S., Heo, C., Kannan Kutty, M., Omar, E., Abdullah, S. & Tappe, D. (2013). High prevalence of muscular sarcocystosis in cattle and water buffaloes from Selangor, Malaysia. *Tropical Biomedicine* **30**(4): 699-705.
- Latif, B., Vellayan, S., Omar, E., Abdullah, S. & Mat Desa, N. (2010). Sarcocystosis among wild captive and zoo animals in Malaysia. *The Korean Journal of Parasitology* **48**(3): 213-217.
- Levine, N.D. (1986). The taxonomy of *Sarcocystis* (protozoa, apicomplexa) species. *The Journal of Parasitology* **72**: 372-382.
- More, G., Abrahamovich, P., Jurado, S., Bacigalupe, D., Marin, J., Rambeaud, M. & Venturini, M. (2011). Prevalence of *Sarcocystis* spp. in Argentinean cattle. *Veterinary Parasitology* **177**(1): 162-165.
- Morsy, K., Saleh, A., Al-Ghamdi, A., Abdel-Ghaffara, F., Al-Rasheid, K., Bashtar, A.R. & Mehlhorn, H. (2011). Prevalence pattern and biology of *Sarcocystis capracanis* infection in the Egyptian goats: A light and ultrastructural study. *Veterinary Parasitology* **181**(2): 75-82.
- Motamedi, G.R., Dalimi, A., Nouri, A. & Aghaeipour, K. (2011). Ultrastructural and molecular characterization of *Sarcocystis* isolated from camel (*Camelus dromedarius*) in Iran. *Parasitology Research* **108**(4): 949-954.
- Norlida, O., Zarina, M., Latif, B., Abo, R. & Al-Sultan, I. (2012). A histopathological appraisal of ovine sarcocystosis in Kelantan. *Journal of Advanced Biomedical Pathobiology Research* **2**(4): 137-142.
- Olias, P., Meyer, A., Klopffleisch, R., Lierz, M., Kaspers, B. & Gruber, A.D. (2013). Modulation of the host Th1 immune response in pigeon protozoal encephalitis caused by *Sarcocystis calchasi*. *Veterinary Research* **44**(1): 1-11.
- Oryan, A., Sharifiyazdi, H., Khordadmehr, M. & Larki, S. (2011). Characterization of *Sarcocystis fusiformis* based on sequencing and PCR-RFLP in water buffalo (*Bubalus bubalis*) in Iran. *Parasitology Research* **109**(6): 1563-1570.
- Prathap, K. (1973). *Sarcocystis* in the Malaysian long-tailed monkey *Macaca fascicularis*. *Transactions of the Royal Society of Tropical Medicine and Hygiene* **67**(4): 615.

- Pritt, B., Trainer, T., Simmons-Arnold, L., Evans, M., Dunams, D. & Rosenthal, B.M. (2008). Detection of *Sarcocystis* parasites in retail beef: a regional survey combining histological and genetic detection methods. *Journal of Food Protection* **71**(10): 2144-2147.
- Savini, G., Dunsmore, J., Robertson, I. & Seneviratna, P. (1992). The epidemiology of *Sarcocystis* spp. in cattle of Western Australia. *Epidemiology and Infection* **108**(1): 107-113.
- Thomas, V. & Dissanaik, A. (1978). Antibodies to *Sarcocystis* in Malaysians. *Transactions of the Royal Society of Tropical Medicine and Hygiene* **72**(3): 303-306.
- Wunschmann, A., Armien, A., Reed, L., Gruber, A. & Olias, P. (2011). *Sarcocystis calchasi*-Associated Neurologic Disease in a Domestic Pigeon in North America. *Transboundary and Emerging Diseases* **58**(6): 526-530.
- Yan, W., Qian, W., Li, X., Wang, T., Ding, K. & Huang, T. (2013). Morphological and molecular characterization of *Sarcocystis miescheriana* from pigs in the central region of China. *Parasitology Research* **112**(3): 975-980.
- Zaman, V. (1970). *Sarcocystis* spp. in the slow loris *Nycticebus coucang*. *Transactions of the Royal Society of Tropical Medicine and Hygiene* **64**(1): 195-196.
- Zaman, V. & Colley, F.C. (1975). Light and electron microscopic observations of the life cycle of *Sarcocystis orientalis* sp. n. in the rat (*Rattus norvegicus*) and the Malaysian reticulated python (*Python reticulatus*). *Zeitschrift für Parasitenkunde* **47**(3): 169-185.