

Use of Tomosynthesis in Intraoperative Digital Specimen Radiography – Is a Reduction of Breast Re-excision Rates Possible?

Einsatz der Tomosynthese in der intraoperativen digitalen Präparate-Radiografie – Ist eine Reduktion der Mammarexzisionsrate möglich?

Authors

R. Schulz-Wendtland¹, G. Dilbat², M. R. Bani³, M. P. Lux³, M. Meier-Meitingner¹, E. Wenkel¹, S. Schwab⁴, M. W. Beckmann³, M. Uder⁴, B. Adamietz¹

Affiliations

¹ Universitätsklinikum Erlangen (University Hospital in Erlangen), Department of Radiology, Gynaecological Radiology, Erlangen

² Radiological Practice Roth and Weissenburg, Roth

³ Universitätsklinikum Erlangen (University Hospital in Erlangen), Department of Gynaecology and Obstetrics, Erlangen

⁴ Universitätsklinikum Erlangen (University Hospital in Erlangen), Department of Radiology, Erlangen

Schlüsselwörter

- Mamma
- Mammakarzinom
- mammografische Dichte

Key words

- breast
- mammary gland tumor
- mammographic density

received 6.9.2011
revised 16.9.2011
accepted 19.9.2011

Bibliography

DOI <http://dx.doi.org/10.1055/s-0031-1280427>
Geburtsh Frauenheilk 2011; 71: 1080–1084 © Georg Thieme Verlag KG Stuttgart · New York · ISSN 0016-5751

Correspondence

Prof. Dr. med.
Ruediger Schulz-Wendtland
Radiologisches Institut
des Universitätsklinikums
Erlangen (Institute of Radiology
of the University Hospital
in Erlangen)
Gynäkologische Radiologie
(Gynaecology radiology)
Universitätsstraße 21–23
91056 Erlangen
ruediger.schulz-wendtland@
idr.imed.uni-erlangen.de

Abstract



Aim: A prospective clinical study was done to see whether it is possible to reduce the rate of re-excisions using digital breast tomosynthesis (DBT) compared commercial FFDM.

Material and Method: Between 1/2011 and 5/2011 we diagnosed an invasive breast cancer (BI-RADS 5) in 100 patients. After histological verification we performed breast-conserving therapy with intraoperative imaging using one of 2 different systems: 1. Tomosynthesis (Siemens, Erlangen, Germany), amorphous selenium, Tungsten source, focus 0.1 mm, resolution 85 µm, pixel pitch, 8 l/mm, range: 50°, 25 projections, time for scanning > 20 s, geometry: same scanning scope, reconstruction: filtered back projection; or 2. Inspiration™ (Siemens, Erlangen, Germany), amorphous selenium, tungsten source, focus 0.1 mm, resolution 85 µm, pixel pitch, 8 l/mm as the standard. The 100 radiograms obtained with both systems were prospectively shown on a monitor to 3 radiologists.

Results: Out of a total of 100 patients with histologically proven breast cancer (BI-RADS 6) no re-excision was necessary in 78 patients. A retrospective analysis (n=22) demonstrated an increase in sensitivity of tomosynthesis compared to the Inspiration™ at a magnification of 1.0:1.0 of 8% (p<0.05), i.e., in 8 patients re-excision would not have been necessary with tomosynthesis.

Conclusion: Tomosynthesis has a significant higher sensitivity (p<0.05) compared with a commercial FFDM system. Studies with higher numbers of patients will be necessary to evaluate this method.

Zusammenfassung



Ziel: Prospektive Untersuchung, ob mithilfe der digitalen Brusttomosynthese (DBT) im Vergleich mit einem herkömmlichen FFDM-System eine Senkung der Rate an Reexzisionen möglich ist.

Material und Methode: In der Zeit von 1/2011 bis 5/2011 wurde bei 100 Patientinnen ein invasives Mammakarzinom (BI-RADS 5) diagnostiziert. Nach histologischer Sicherung erfolgte die brusterhaltende Therapie mit intraoperativem Präparateradiogramm mit 2 unterschiedlichen Systemen: 1. Tomosynthese (Siemens, Erlangen, Deutschland), amorphes Selen, W-Anode, Fokus 0,1 mm, Ortsauflösung 85 µm, Pixelpitch, 8 l/mm, Winkelbereich 50°, 25 Projektionen, Scandauer > 20 s, Geometrie: gleichförmige Abtastung, Rekonstruktion: gefilterte Rückprojektion und 2. Inspiration™ (Siemens, Erlangen, Deutschland), amorphes Selen, W-Anode, Fokus 0,1 mm, Ortsauflösung 85 µm, Pixelpitch, 8 l/mm als Standard. Die jeweils 100 Präparateradiogramme wurden prospektiv 3 Radiologen auf einem Befundungsmonitor präsentiert.

Ergebnisse: Bei den 100 Patientinnen mit histologisch gesichertem Mammakarzinom (BI-RADS 6) war bei 78 Patientinnen nach erfolgter brusterhaltender Therapie keine weitere operative Therapie (Reexzision) indiziert. Die retrospektive Analyse (n=22) ergab eine Steigerung der Sensitivität zwischen Tomosynthese und Inspiration™ bei einer Vergrößerung von 1,0:1,0 von 8% (p<0,05), d.h. bei 8 Patientinnen wäre mit der Tomosynthese eine Reexzision nicht notwendig gewesen.

Schlussfolgerung: Die Tomosynthese zur Präparateradiografie erreicht signifikant (p<0,05) eine bessere Sensitivität im Vergleich zu einem FFDM-System mit herkömmlichem Detektor. Studien mit größeren Zahlen sind notwendig zur weiteren Evaluierung der Methode.

Introduction

The mortality of breast cancer declined in the last decade [1,2]. This is not only due to the implementation of recent research results in clinical practice and guidelines for treatment [3–6], but is also caused by implementation of standards in clinical diagnostics.

Both the European Guidelines and the S3 Guidelines require that at least 70% of all malignant breast lesions (BI-RADS 5) must be histologically verified before performing an operation – in fact, 90% is desirable [7–10]. This should then ensure that only a single operational intervention is required following the preoperative clarification of a diagnostically malignant process. This also requires the corresponding marking of all non-palpable breast lesions before the actual operational intervention (for example with wire) [7–10].

Sample radiography is often considered to be the method of choice for the proof of the complete removal of the lesion [11, 12]. A possible indicated approach is to transport the sample from operating room to Radiology in a suitable container and x-ray it directly there [13] or, optimally, directly perform sample radiography (two planes) intraoperatively in the operating room. The result of sample radiography is then directly available to both the surgeon and the pathologist, either via the medium film (analogue/digital) or, more efficiently, via the PACS.

The breast cancer re-excision rate after primary breast-conserving therapy with previous histologically verified carcinoma (histologically B5 and thus BI-RADS 6) is between 10% and 57% in the literature, depending on the safety margin defined [14].

Digital, image-guided methods for breast cancer diagnostic are used since a while. The full-field digital mammography is established and the digital breast tomosynthesis creates a 3-dimensional information about the mammary gland [15].

The objective of our prospective study was to determine whether a reduction in the rate of re-excisions for histologically verified invasive breast cancer followed by breast-conserving therapy with wire marking is possible compared to a well-known full field digital mammography (FFDM) system (Inspiration™, Siemens) (● Fig. 2), with the use of Tomosynthesis (Siemens) (● Fig. 1 a and b).

Material and Methods

Between 1/2011 and 5/2011 we diagnosed invasive breast cancer (BI-RADS 5) in 100 patients on the basis of complementary diagnoses (hospital, mammography, sonography, MRT). The ages of the patients varied from 27 to 84 years (median: 59 years). The sizes of the lesions determined by the imaging methods were between 6 mm and 19 mm (median: 15 mm). In accordance with the European Guidelines and the S3 Guidelines [7–10] all patients were examined preoperatively by a sonographically guided punch or stereotactically/radiographical guided vacuum biopsy, with the histological result B5, i.e. diagnostically BI-RADS 6. As no multi-focality or multi-centricity was found in any of the cases and the extent was less than 2.0 cm, the S3 Guidelines did not indicate the need for primary neoadjuvant chemotherapy [9,10]. Following the histological diagnosis B5, diagnostically BI-RADS 6, according to the primary process of histologically verifying the findings, all patients underwent a preoperative sonographically or stereotactically/radiographically guided wire marking. This was followed by breast-conserving therapy, including the senti-




Fig. 1 a and b Tomosynthesis (Siemens, Erlangen, Germany), amorphous selenium, tungsten source, focus 0.1 mm, spatial resolution 85 μm , pixel pitch, 8 l/mm, angular range 50 degrees, 25 projections, scan time > 20 s, Geometry: uniform scanning, reconstruction: filtered back projection. **a** Tomosynthesis at + 6 degrees, **b** Tomosynthesis at + 14 degrees.



Fig. 2 Inspiration™ (Siemens, Erlangen, Germany), amorphous selenium, tungsten source, focus 0.1 mm, spatial resolution 85 μm , pixel pitch, 8 l/mm, 0 degree position.

nel lymph node (marking with both patent blue and technetium 99m). The operated segment was marked with thread (orientation) (*three* planes) and radiologically investigated, compression-free [16] with the wire still placed, with two different systems, both with automatic exposure control (AEC) (Tomosynthesis, 1 plane, System 1) and sample radiography in two planes (Inspiration™, System 2) (magnification 1.0: 1.0) (● Table 1):

1. Tomosynthesis (Siemens, Erlangen, Germany), amorphous selenium, tungsten source, focus 0.1 mm, spatial resolution 85 μm , pixel pitch, 8 l/mm, angular range 50 degrees, 25 projections, scan time > 20 s, Geometry: uniform scanning, reconstruction: filtered back projection
2. Inspiration™ (Siemens, Erlangen, Germany), amorphous selenium, tungsten source, focus 0.1 mm, spatial resolution 85 μm , pixel pitch, 8 l/mm

Table 1 Important basic technical features of the systems (System No. 1 “Tomosynthesis” and System No. 2 “Inspiration™”) for the preparation of sample radiograms – as well as the possibilities for the generation of projection images/Cine mode with the “Tomosynthesis” with an angular range of 50 degrees and 25 projections and a scan time of > 20 s, uniform scanning geometry and reconstruction of the filtered back projections.

| | System No. 1 “Tomosynthesis” | System No. 2 “Inspiration™” |
|---|---------------------------------|--------------------------------|
| Manufacturer | Siemens | Siemens |
| X-ray source | | |
| Anode | Mo, W | Mo, W |
| Filter | Mo, Rh | Mo, Rh |
| Scattered radiation grid | linear | linear |
| Detector | | |
| Conversion material | Semiconductor a-Se | Semiconductor a-Se |
| Readout process | Thin film transistors | Thin film transistors |
| Pixel size | 85 µm | 85 µm |
| Spatial resolution (Nyquist frequency) | 8 Lp/mm | 8 Lp/mm |

The entire series of radiograms for 100 operated segments with breast-conserving therapy (Tomosynthesis [1 plane] [25 projections and Cine mode]; digital full field [Inspiration™] [2 planes] [standard]) were presented prospectively on a diagnostic monitor intraoperatively to *three* radiologists with different experience in digital mammography. The results of the findings (focus in or not in all *three* planes with sufficient safety margin [1.0 cm] with sample radiography [25 projections/two planes]) [9,10] were correlated with the follow-on overall histological findings. The radiologists who determined these findings were aware that a malignancy had to be present.

Result

Of the 100 patients with a histologically verified breast cancer (BI-RADS 6), 78 patients required no further operative therapy (re-excision) following breast-conserving therapy – as confirmed by the sample radiograms prepared directly during the primary operation (intraoperatively) (25 projections and in Cine mode/2 planes) (focus seen in all *three* planes with sufficient safety margin (1.0 cm) with sample radiography). The sample radiogram in two planes, magnification 1.0:1.0 (● Fig. 4) was defined as the *standard*.

On the basis of the standard sample (Inspiration™, 2 planes, magnification 1.0:1.0) and the pathological findings (5 samples, operation non in sano; 17 samples, lesion histologically investigated with a safety margin of < 1.0 cm) a re-excision was performed on 22 patients. The tomosynthesis performed in parallel (25 projections and Cine mode, magnification 1.0:1.0) (● Fig. 3) showed that a re-excision on the basis of the specified criteria was necessary in only 14 patients.

The final histological result of the 22 operated patients (re-excision) indicated that with five patients the operation took place non in sano, however the safety margin was < 1.0 cm for only six patients; that is, no residual tumours could be identified. This means that a re-excision on the basis of the final histological findings would only have been justified for 11 patients.

A direct comparison of sample radiography with the Tomosynthesis and Inspiration™ shows an improvement in sensitivity of 8% ($p < 0.05$) (● Table 2).

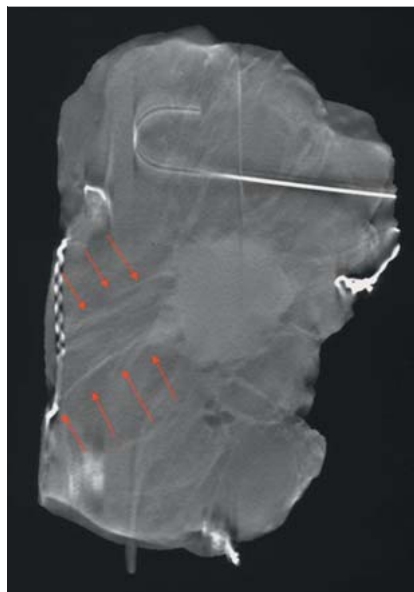


Fig. 3 Sample radiogram Tomosynthesis, image 13 of 25; magnification 1.0 × 1.0, invasive breast carcinoma T1cN0M0, diameter of tumour nucleus 1.6 cm, extent of spiculae 3.2 cm (arrows) reaching to the edge of the sample radiogram, non in sano, unequivocally assessable (verified, both by imaging and histology).

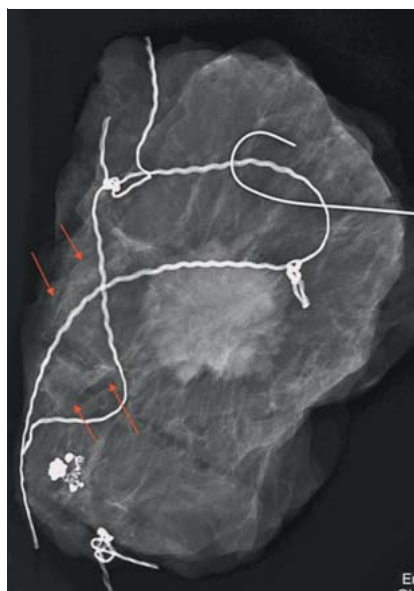


Fig. 4 Sample radiogram Inspiration™; magnification 1.0 × 1.0, invasive breast carcinoma pT1cN0M0, diameter of tumour nucleus 1.6 cm, spiculae (arrows) not assessable.

Discussion

The efficacy of an operation can be enhanced by additional sample radiograms [7–14,16]. According to the information of the European Guidelines and the S3 Guidelines, this should be performed in two planes [7–10]. This allows the possibility of obtaining the immediate confirmation of a successful operation still during the operation. The direct presentation of the sample in two planes then allows immediate follow-up resection if the sample is not pathological. Significant progress was ensured with the introduction of digital imaging plates used with conventional analogue mammography equipment. This method is based on CCD chips and the possibilities for the use of PACS which these enable – but, compared with the all-digital systems now available, this has a far lower detector quantum efficiency (DQE) [12, 13,17–21]. In the last 10–15 years x-ray equipment was developed expressly for the preparation of sample radiograms which can be viewed at different locations (for example in the operating

Table 2 Sensitivity and specificity of the two systems (System No. 1 “Tomosynthesis” and System No. 2 “Inspiration™”) determined by three radiologists, each of whom prospectively evaluated 100 sample radiograms/projection images (Cine mode) with a total of 100 malignant lesions.

| Magnification | Sensitivity (%) | | Specificity (%) | |
|-----------------|----------------------------|--------------------------|----------------------------|--------------------------|
| | System No. 1 | System No. 2 | System No. 1 | System No. 2 |
| | “Tomosynthesis” (85 µm) | “Inspiration” (85 µm) | “Tomosynthesis” (85 µm) | “Inspiration” (85 µm) |
| 1.0:1.0 (No. 1) | | | | |
| 1.0:1.0 (No. 2) | | | | |
| Radiologist 1 | 86.0 | 78.0 | 100.0 | 100.0 |
| Radiologist 2 | 87.0 | 79.0 | 100.0 | 100.0 |
| Radiologist 3 | 87.0 | 78.0 | 100.0 | 100.0 |
| Mean value | 86.6 | 78.3 | 100.0 | 100.0 |

room, in the Radiology Department or in Pathology). An innovative process, from conventional systems, via imaging plates to all-digital systems [12, 13, 17–21] and further to CMOS technology [22] could also be observed over this time. The new development of digital breast tomosynthesis (DBT) [23–25] as a supplement to digital mammography now also allows the possibility to prepare sample radiograms intraoperatively. By contrast with classical planigraphic technique, the individual projections of a scanning cycle are not superimposed to an image directly on the detector, but initially stored on the computer as individual images. The individual images are then combined to slice images using mathematical reconstruction algorithms (synthesis = joining). This allows the calculation of an arbitrary number of slices from the data of a scanning cycle without additional radiation exposure. DBT slices are usually 1 mm thick; however they can also be thicker. Particularly the detection of grouped micro-calcifications may make the viewing of thicker slices necessary in order to be able to recognise whether groups belong together. All slices can be displayed as individual high-resolution images and can also be displayed in Cine mode. In literature, improvements in sensitivity and specificity [26] are given as a supplement to digital mammography, with the possibilities for reducing the recall rate [27, 28] and also in mammography screening [29]. With the system which we used, the samples were investigated radiographically in 25 projections with an angular range of 50 degrees. The three radiologists evaluated the samples by tomosynthesis (1 plane) on the basis of the projection images and also in Cine mode (System 1), with the sample radiogram in two planes (System 2) defined as *standard* and, on the basis of these results, performed a re-excision on 22 patients.

The final histological result of the 22 operated patients (re-excision) indicated that with five patients the operation took place non in sano, however the safety margin was < 1.0 cm for only six patients; that is, no residual tumours could be identified. This means that a re-excision on the basis of the final histological findings would only have been justified for 11 patients.

A direct comparison of sample radiography with the Tomosynthesis and Inspiration™ shows an improvement in sensitivity of 8% ($p < 0.05$). The reason may lie in the fact that tomosynthesis allows a more exact characterisation of the breast parenchyma in the screening mammography (c–c and obliq.) [30] and also shows this in the sample radiogram: better demarcation (spiculae and DCIS sections of the tumour manifestation compared with the remaining benign glandular parenchyma).

The breast cancer re-excision rate after primary breast-conserving therapy with previous histologically verified breast (histologically B5 and thus BI-RADS 6) in our historical patient collective is currently in fact also 22% in our retrospective evaluation and between 10% and 57% in the literature, depending on the safety

margin defined [14]. In order to reduce the re-excision rate, not to satisfy the European Guidelines or the S3 Guidelines but particularly to spare the patients a second operational intervention with all its side effects, the future possibility of volumetric analysis in mammography on the basis of tomosynthesis and 3D imaging could make a significant contribution [25]. Furthermore, our results are consistent with and superior to those obtained with sample radiograms in digital technique with the use of zooming and magnifications up to a factor of 2.0 [22, 31–34].

Conflict of Interest

None.

References

- Kaufmann M, Rody A. Breast cancer: reduced mortality by early detection and adjuvant therapy. *Geburtsh Frauenheilk* 2009; 69: 218–232
- Katalinic A. Breast cancer: declining mortality despite its increasing incidence. *Geburtsh Frauenheilk* 2009; 69: 237–239
- Beckmann MW, Blohmer JU, Costa SD et al. Zurich consensus: German expert opinion on the St. Gallen votes on 15 March 2009 (11th international conference at St. Gallen: primary therapy of early breast cancer) 2009 St. Gallen conference: primary therapy of early breast cancer – opinion among German experts (Zurich 2009). *Geburtsh Frauenheilk* 2009; 69: 377–383
- Ruckhaberle E, Solbach C, Kaufmann M. Conference report on the 31st annual San Antonio breast cancer symposium, December 10–14, 2008 “Continuing change in diagnostics and therapy of breast cancers – from molecular basics to tailored therapy”. *Geburtsh Frauenheilk* 2009; 69: 202–211
- Ruckhaberle E, Rody A, Kaufmann M. Report of the 32nd annual San Antonio breast cancer symposium, December 10–13, 2009 “An international scientific symposium for interaction and exchange among basic scientists and clinicians in breast cancer”. *Geburtsh Frauenheilk* 2010; 70: 177–183
- Fasching PA, Fehm T, Janni W et al. Breast cancer therapy – a state of the art review. *Geburtsh Frauenheilk* 2010; 70: 875–886
- Perry NM. Quality assurance in the diagnosis of breast disease. *Eur J Cancer* 2001; 37: 159–172
- Wallis M, Tardivon A, Helbich T et al. Guidelines from the European Society of Breast Imaging for diagnostic interventional breast procedures. *Eur Radiol* 2007; 17: 581–588
- Albert US, Hrsg. S3-Leitlinie Brustkrebs-Früherkennung in Deutschland. 1. Aktualisierung 2008. www.senologie.org 2008. München: W. Zuckschwerdt-Verlag; 2008
- Kreienberg R, Kopp I, Albert U et al. S3-Leitlinie Diagnostik, Therapie und Nachsorge des Mammakarzinoms. 1. Aktualisierung. Im Internet: www.senologie.org 2008. München: W. Zuckschwerdt-Verlag; 2008
- D’Orsi CJ. Management of the breast specimen. *Radiology* 1995; 194: 297–302
- Diekmann F, Grebe S, Bick U et al. Digitale intraoperative Präparate-radiographie bei diagnostischen Exzisionen nicht palpabler Läsionen der Brust. *Fortschr Röntgenstr* 2000; 172: 969–971

- 13 Grunert J-H, Flemming P, Borchert B et al. Vergrößerungspräparate-radiographie als Qualitätskontrolle der Mikrokalkerkfassung im Rahmen der histopathologischen Aufarbeitung von Mammabiopsiegewebe. *Fortschr Röntgenstr* 2000; 172: 68–72
- 14 Bani MR, Lux MP, Heusinger K et al. Factors correlating with reexcision after breast-conserving therapy. *EJSO* 2009; 35: 32–37
- 15 Schulz-Wendtland R, Wenkel E, Wacker T et al. Quo vadis? Trends in digital mammography. *Geburtsh Frauenheilk* 2009; 69: 108–117
- 16 Grunert J-H, Wiechmann U, Gmelin E. Kompressionsfreie Mamma-präparateradiographie in 2 Ebenen mit Hilfe eines Radiographiecontainers. *Fortschr Röntgenstr* 2003; 175: 413–417
- 17 Kürzl R, Baltzer J, Lohe KJ. Intraoperative specimen radiography in mammographically suspected, non palpable breast lesions. Experiences with the Faxitron unit. *Fortschr Med* 1979; 97: 1688–1690
- 18 Kürzl R, Lohe KJ, Baltzer J et al. Radiography used during operations for biopsies of non-palpable lesions of the breast which have been suspected because of mammography. *J Gynecol Obstet Biol Reprod* 1981; 10: 431–434
- 19 Moritz JD, Westerhof JP, Funke M et al. Ein neues Präparateradiographiegerät mit maximal 20facher Vergrößerung für die Mammadiagnostik. *Fortschr Röntgenstr* 1998; 168: 133–138
- 20 Grunert JH, Borchert B, Farber A et al. Mikrokalknachweis in Mamma-Exzisionspräparaten mit Hilfe der DIMA-Vergrößerungspräparate-radiographie vierfach im Vergleich zur konventionellen Vergrößerungs-radiographie eineinhalbfach. *Fortschr Röntgenstr* 1999; 171: 302–306
- 21 Muttalib M, Tisdall M, Scawn R et al. Intra-operative specimen analysis using faxitron microradiography for excision of mammographically suspicious, non-palpable breast lesions. *The Breast* 2004; 13: 307–315
- 22 Schulz-Wendtland R, Bani MR, Lux MP et al. CMOS – Technologie für intraoperative digitale Präparateradiografien. *Geburtsh Frauenheilk* 2011; 71: 525–529
- 23 Niklason LT, Christian BT, Niklason LE et al. Digital tomosynthesis in breast imaging. *Radiology* 1997; 205: 399–406
- 24 Schulz-Wendtland R, Wenkel E, Lell M et al. Experimental phantom lesion detectability study using a digital breast tomosynthesis prototype system. *Röfo* 2006; 178: 1219–1223
- 25 Schulz-Wendtland R, Fuchsjäger M, Wacker T et al. Digital mammography: an update. *Eur J Radiol* 2009; 72: 258–265
- 26 Good WF, Abrams GS, Catullo VJ et al. Digital breast tomosynthesis: a pilot observer study. *AJR* 2008; 190: 865–869
- 27 Gur D, Abrams GS, Chough DM et al. Digital breast tomosynthesis: observer performance study. *AJR* 2009; 193: 586–591
- 28 Poplack SP, Tosteson TD, Kogel CA et al. Digital breast tomosynthesis: initial experience in 98 women with abnormal digital screening mammography. *AJR* 2007; 189: 616–623
- 29 Teertstra HJ, Loo CE, van den Bosch MA et al. Breast tomosynthesis in clinical practice: initial results. *Eur Radiol* 2010; 20: 16–24
- 30 Kontos D, Bakic PR, Carton AK et al. Parenchymal texture analysis in digital breast tomosynthesis for breast cancer risk estimation: a preliminary study. *Acad Radiol* 2009; 16: 283–298
- 31 Schulz-Wendtland R, Hermann K-P, Wenkel E et al. Vergleich der klinischen Wertigkeit von Zielaufnahmen mit reduzierter Pixelgröße des Detektors und digitalem Monitorzooming bei der Beurteilung von Mikrokalkzifikationen in der digitalen Mammographie. *Fortschr Röntgenstr* 2007; 179: 492–496
- 32 Haygood TM, Arribas E, Brennan PC et al. Conspicuity of microcalcifications on digital screening mammograms using varying degrees of monitor zooming. *Acad Radiol* 2009; 16: 1509–1517
- 33 Kim MJ, Youk JH, Kang DR et al. Zooming method (x 2.0) of digital mammography vs. digital magnification view (x 1.8) in full-field digital mammography for the diagnosis of microcalcifications. *Br J Radiol* 2010; 83: 486–492
- 34 Koutaloni M, Delis H, Pascoal A et al. Can electronic zoom replace magnification in mammography? *BJR* 2010; 83: 569–577

Deutschsprachige Zusatzinformationen mit deutschem Text online abrufbar unter: www.thieme-connect.de/ejournals/toc/gebfra.