

Research Article

Study of branching pattern of median nerve at carpal tunnel and its importance in surgical anatomy

Raviprasanna K. H^{*1}, G. C. Poornima² and Dakshayani K. R³

¹Assistant Professor, Department of Anatomy, Sree Narayana Institute of Medical Sciences, North Kuthiathode, Chalakka, Ernakulam, Kerala-683594.

²Associate Professor, Department of Anatomy, Mysore Medical College and Research Institute, Mysore, Karnataka-570001.

³Professor and HOD, Department of Anatomy, Mysore Medical College and Research Institute, Mysore, Karnataka-570001.

***Correspondence Info:**

Dr. Raviprasanna K. H
Assistant Professor,
Department of Anatomy,
Sree Narayana Institute of Medical Sciences,
North Kuthiathode, Chalakka, Ernakulam, Kerala-683594.
E-mail: pravi_kh81@yahoo.in

Abstract

Introduction: Median nerve is called labourer's nerve as it supplies large flexor muscles of forearm and five intrinsic muscles of hand which help in movement of the thumb. Comprehensive knowledge pertaining to its variations is extremely important in clinical and surgical procedures so as to avoid injury to it. The precise knowledge of level of origin of muscular branches of median nerve is essential in free muscular transfers to restore the mobility of fingers after trauma and to prevent the complications during the carpal tunnel decompression.

Objective: In present study the objectives are to know the branching pattern of median nerve at carpal tunnel and its variations.

Materials and Methods: The study included 51 human cadaver upper limb specimens at the Department of Anatomy, Mysore Medical College & Research Institute, Mysore during 2011-13. The specimens fixed in 10% formalin were finely dissected and median nerve was traced for branching pattern at carpal tunnel.

Results: Out of 51 human cadaver specimens, thenar branch of median nerve originated at three different sites, median nerve divided into medial and lateral trunks at different levels with respect to flexor retinaculum, communicating branch between ulnar and median nerve was observed, third lumbrical and adductor pollicis received branches from median nerve.

Conclusion: In the present study an attempt is made to know the possible variations of median nerve branching pattern and termination in carpal tunnel so as to provide additional information which may help to decrease the risk of diagnostic and operative complications.

Keywords: Median Nerve; Carpal Tunnel; Flexor Retinaculum; Carpal Tunnel Syndrome

1. Introduction

Carpal tunnel syndrome is a common focal peripheral neuropathy. Increased pressure in the carpal tunnel results in median nerve compression and impaired nerve perfusion, leading to discomfort and paraesthesia in the affected hand.¹Anatomic variations of the median nerve are frequent and significant for wrist surgeries with short incisions and endoscopic procedures in treatment of carpal tunnel syndrome. These procedures demand thorough knowledge of anatomy and its variations of the structures in wrist. A surgeon should be efficient to appreciate anatomical variations which may lead to iatrogenic injury if recognised. A large proportion of industrial accidents resulting in total or partial impairment of function in the hand indirectly points at unrecognised variations leading to postoperative complications.

The balance between extrinsic and intrinsic muscles of hand helps in normal functioning and thumb is important in its movement which acts in opposite direction to all other fingers in grasping any object. The long flexor tendons and short intrinsic muscles of hand are responsible for providing grip and adjusting the position to carry out fine skilled movements of digits. The median nerve passes deep to flexor retinaculum in the carpal tunnel gives off thenar branch of median nerve to supply thenar group of muscles and the median nerve divides into medial and lateral trunks to supply palm and digits along with lateral two lumbricals.²Manual skill is important in many professional activities and a large proportion of industrial accidents result in total or partial impairment of function in the hand. An understanding of the structure of the hand is therefore crucial for those involved in reparative and rehabilitative procedures.³The present study aims to study the level of origin of thenar branch of median nerve, division of the median nerve with respect to flexor retinaculum, communicating branches between ulnar and median nerve in hand and other muscular branches from median nerve in hand.

2. Materials & Methods

The 51 human cadaver upper limb specimens obtained from Department of Anatomy, Mysore Medical College & Research Institute, Mysore during 2011-13 included 26 right and 25 left sided limbs. The specimens fixed in 10% formalin solution were dissected following the guidelines of Cunningham's manual.⁴Our study excluded those specimens which exhibited previous trauma to the upper limb, fractures, any kind of surgical procedures and pathologies. Flexor retinaculum was divided at the midline, avoiding damage to underlying structures. Thenar muscles and lumbricals were identified. The branches of median nerve in the hand were traced, studied and looked for any variations and the details were noted.

3. Results

Table 1: Level of origin of thenar branch of median nerve

Origin of thenar branch of median nerve	Right		Left	
	N	%	N	%
Pre-ligamentous (Proximal to flexor retinaculum)	-	-	01	01.96
Sub-ligamentous (Within the flexor retinaculum)	07	13.72	03	5.88
Extra-ligamentous (Distal to flexor retinaculum)[Figure 1]	19	37.25	21	41.17
Total	26	50.97	25	49.01

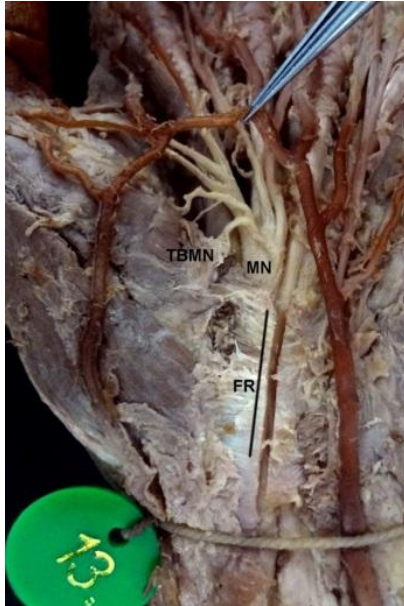

Figure 1: Extraligamentous origin of thenar branch of median nerve

- MN- Median Nerve
- FR-Flexor Retinaculum
- TBMN- Thenar Branch of Median Nerve

Table 2: Division of median nerve into medial and lateral trunks

Division of median nerve into medial and lateral trunks	Right		Left	
	N	%	N	%
Proximal to flexor retinaculum [Figure 2]	03	5.88	03	5.88
Within the retinaculum [Figure 3]	08	15.68	04	7.84
Distal to retinaculum	15	29.41	18	35.29
Total	26	50.97	25	49.01

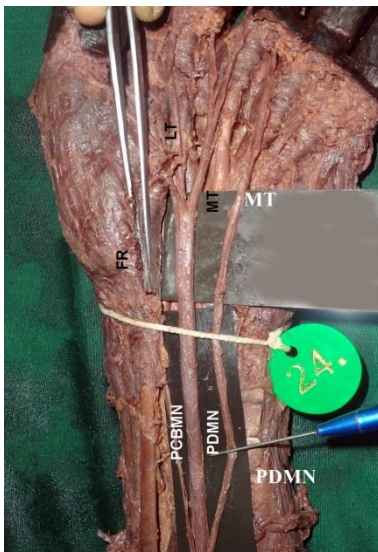


Figure 2: Median nerve is dividing into 2 trunks proximal to flexor retinaculum

- MN - Median Nerve
- FR - Flexor Retinaculum
- PDMN - Proximal Division of Median Nerve
- MT - Medial Trunk
- LT - Lateral Trunk
- PCBMN- Palmar Cutaneous Branch of Median Nerve

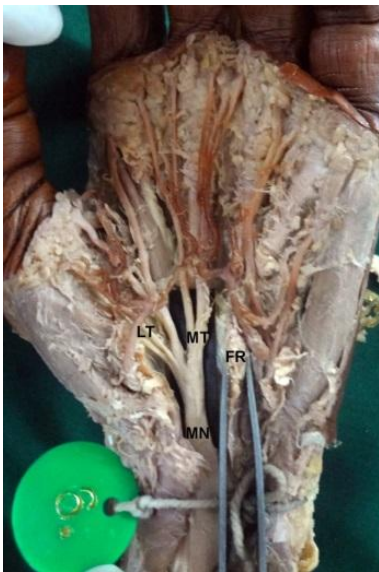

Figure 3: Median nerve division within the flexor retinaculum

- MN- Median Nerve
- FR - Flexor Retinaculum
- LT - Lateral Trunk
- MT - Medial Trunk

Communicating branch between ulnar and median nerve was observed in 4 limbs (7.8%) on right and 4 limbs (7.8%) on left sides (Figure- 4).

Third lumbrical supplied by median nerve was observed in one specimen (1.96%) [Figure-5]

Branch from median nerve supplying adductor pollicis muscle was observed in 4 specimens (7.8%) on right and 2 specimens (3.9%) on left side [Figure-6].

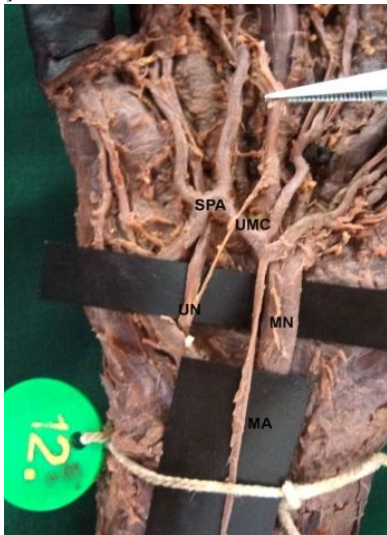


Figure 4: Ulnar and median nerve communication in hand

- UMC –Ulnar and Median Communication
- UN – Ulnar Nerve
- MN – Median Nerve
- SPA – Superficial PalmarArch
- MA – Median Artery

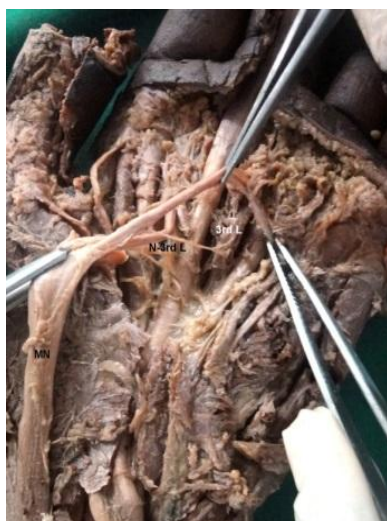

Figure 5: Third lumbrical supplied by median nerve

- MN- Median nerve
- 3rd L – Third Lumbrical muscle
- N. 3rd L – Nerve to Third Lumbrical

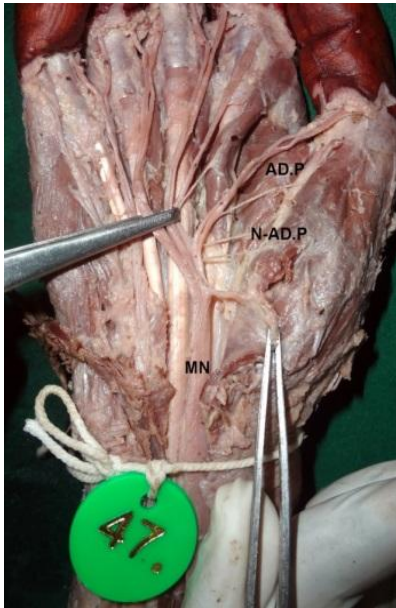


Figure 6: Median nerve supplying adductor pollicis muscle

MN- Median nerve

AD.P - Adductor Pollicis muscle

N- AD.P - Nerve to Adductor Pollicis muscle

4. Discussion

Lanz U in 1977 studied on 246 hands in which the carpal tunnel was explored at operation, 29 variations in the course of median nerve were found. Based on these findings and including published reports of others, the variations were classified into 4 groups. **Group I** – variation in the course of thenar branch of median nerve in 46%, **Group II** – presence of accessory branch in the distal part of carpal tunnel in 7.5% and proximal to retinaculum in 1.6%, **Group III** – high division or duplication of median nerve in 2.9%, and **Group IV** – accessory branch proximal to the carpal tunnel in 2.9%. The findings emphasize the importance of approaching the median nerve from the ulnar side when opening the carpal tunnel.⁵

Poisel classified the level of origin of thenar branch of median nerve into four types. **Type 1: Extra-ligamentous** – the nerve originated distal to flexor retinaculum. **Type 2: Sub-ligamentous** – the nerve originated within the flexor retinaculum. **Type 3: Trans-ligamentous** – the nerve originated within the retinaculum and will pierce the retinaculum and supplies thenar muscles. **Type 4: Pre-ligamentous** – new variety where the nerve is originated before the retinaculum.⁶ In 1998, Akio studied 147 hands and reported 114 hands had single thenar branch, 23 hands had 2 and 10 hands presented with 3 branches which supplied thenar muscles.⁷

In 2001, Imamura K noted the variations of thenar branch of median nerve during operations to treat carpal tunnel syndrome in 129 subjects wherein he observed Extra-ligamentous type in 122 hands (94.6%), Sub-ligamentous type in 2 hands (1.6%) and Trans-ligamentous in 5 hands (3.9%).⁸ In 2010, Mohammad M At-Qattan studied the level of origin of thenar branch of median nerve in 100 consecutive patients undergoing open carpal tunnel release and documented Extra-ligamentous in 56%, Sub-ligamentous in 34%, Trans-ligamentous in 9% and Pre-ligamentous in 1% of cases.⁹

In 2011, Mizia *et al* observed the following variations in 60 hands used for study. 43 hands (71.7%) – Lanz type I variant branching of thenar branch of median nerve, Level of origin of thenar branch was Extra-ligamentous in 50%, Sub-ligamentous in 20% and Trans-ligamentous in 1.67%.¹⁰ In 2011, Vashistha K reported normal branching pattern in 15 out of 50 hands (30%), left hands had more variations (20 of 35) as compared to right hands. In one peculiar hand five variations were observed- high division of median nerve, ulnar and sub-ligamentous origin of thenar branch of median nerve, two and half digital innervation pattern, multiple communicating branches at 3 levels between median and ulnar nerve. Bifid median nerve in 4 hands- proximal to transverse carpal ligament. Single thenar branch of median nerve was observed in 33 hands (66%). Thenar branch of median nerve was Sub-ligamentous in 13 hands (39.39%), Extra-ligamentous in 17 hands (51.51%) and Trans-ligamentous in 3 hands (9.09%). In 6 hands third lumbrical was also supplied by median nerve. Communication between median and ulnar was observed in 10 hands (20%) [90% were ulnar to median and rest 10% was from median to ulnar nerve].¹¹

In the present study the thenar branch of median nerve originated distal to flexor retinaculum in 40 specimens (78.42%), in 10 specimens (19.6%) it was sub-ligamentous and in one specimen (1.96%) it was pre-ligamentous. Thenar branch of the median nerve supplying the thenar muscles lies superficially and may be severed by relatively minor lacerations involving the thenar eminence. Severance of thenar branch of median nerve paralyses the thenar muscles and thumb loses much of its usefulness. The existence of trans-ligamentous and sub-ligamentous variations of the thenar branch increases the susceptibility to injury during transverse carpal ligament incision for carpal tunnel decompression.

In 1988, Amadio reported high bifurcation of median nerve in 3.3% of hands, multiple motor branches were present in 13 cases (4.72%) in a series of 275 carpal tunnel releases.¹² In the present study the high division of median nerve is proximal to flexor retinaculum in 11.76% when compared with studies done by Lanz⁵, Mizia *et al*.¹³ and Vashistha¹¹. Surgeons should be aware of anomalous branches which should be recognised and separately decompressed if needed.

In 2007, Loukas *et al* observed the communicating branches between median and ulnar nerves in 170 hands (85%) out of 200 formalin fixed hands. Out of which 143 hands (84.1%) belonged to type I (ulnar to median nerve), 12 hands (7.1%) belonged to type II (median to ulnar nerve), 6 hands (3.5%) to type III (multiple, present horizontally) and 9 hands (5.3%) to type IV (mixed type, multiple combinations existed).¹³ Communicating branch between ulnar and median nerve originating proximally from the 4th common digital nerve (from ulnar nerve) and entering the 3rd common digital nerve more distally (to median nerve) in hand is called as Berretini anastomosis.¹⁴ In 1999, Heidi Bas and James M Kleinert observed the communicating branches between the median and ulnar nerves in 20 palms (67%) out of 30 specimens used for study.¹⁵ These interconnections are at risk when releasing the distal aspect of the TCL during open or endoscopic carpal tunnel release. Aggressive retraction in this region and placement of the endoscope further distal to the TCL should both be avoided in order to prevent traction injury to these nerves resulting in paraesthesia in the long or ring finger distribution.¹⁴

The median nerve usually supplies first and second lumbricals. The third lumbrical is commonly supplied by ulnar nerve but rarely supplied by median nerve as in present study one specimen (1.96%) median nerve supplies 3rd lumbrical compared to 12% in study by Vashistha K¹¹, 2.66% by Mehta and Gardner¹⁶ and 57.14% by Brooks HSJ.¹⁷

In 2005, Elsabah *et al*¹⁸ reported the adductor pollicis was supplied by deep branch of ulnar nerve in 28 hands (93.33%) out of 30 specimens studied and in 2 hands (6.67%) adductor pollicis was supplied in addition by branch from median nerve. In the present study median nerve was supplying adductor pollicis in 11.7% and the innervation by median nerve was restricted to radial fibers of the muscle according to Homma and sakai.¹⁹ Schultz and Kaplan reported that this muscle was supplied by the median nerve.²⁰

5. Conclusion

A key to carry out therapeutic and diagnostic procedures successfully on carpal tunnel depends on the knowledge of the possible variations of nerves and arteries which may be encountered. Such neurovascular variations are not only more prone to iatrogenic injuries but they interfere in the correct interpretation of clinical conditions as well. Some of the complications that have been reported include injuries to nerves, arteries, wrong diagnosis and unnecessary carpal tunnel release.

In the present study an attempt is made to know the possible variations of median nerve branching pattern and termination in carpal tunnel so as to provide additional information which may help to decrease the risk of diagnostic and operative complications.

The present study concludes that the different types of variations in cadavers which have been studied would be of immense help for successful clinical approaches. Such variations of peripheral nerves noticed in routine surgical procedures or in traumatic injuries should be included into the surgical training programmes to help avoiding iatrogenic injuries.

Reference

- Demircay E, Civelek E, Cansever T, Kabatas S, Yilmaz C. Anatomic variations of the median nerve in the carpal tunnel: A brief review of the literature. *Turkish Neurosurgery* 2011; 21(3):388-9.
- Standing S, Ellis H, Healy JC, Johnson D, Williams A, Collins P, *et al*. Fore arm and Hand. In: Gray's Anatomy – The anatomical basis of clinical practice. 40th ed. Edinburgh: Churchill Livingstone; 2005. pp. 895-7.
- Olave E, Prates JC, Sol MD, Sarmiento A, Gabriell C. Distribution pattern of the muscular branch of the median nerve in the thenar region. *J Anat* 1995;186:441-6
- Romanes GJ. The forearm and hand. In: Cunningham's manual of practical anatomy. 15th ed. Vol. 1. Oxford: Oxford University Press; 1986. pp. 73-81.
- Lanz U. Anatomical variations of the median nerve in the carpal tunnel. *J Hand Surg Am* 1977;2(1):44-53.
- Poisel S. Ursprung und verlaufdes ramus muscularis des nervusdigitalis palmaris communis I (N medianus). *Chir Praxis* 1974; 18:471-4.
- Akio M. Variations and Anomalies of the Branching of the Median Nerve Observed on Carpal Tunnel Release. *J. Jap Society Surg Hand* 1998; 15:452-6.
- Imamura K. Anatomical variations of the recurrent branch of the median nerve. *J Orthop Traumatol* 2001; 50(1):170-3.
- Al-Qattan MM. Variations in the Course of the Thenar Motor Branch of the Median Nerve and Their Relationship to the Hypertrophic Muscle Overlying the Transverse Carpal Ligament. *J Hand Surg* 2010; 35A:1820-4.
- Mizia E, Klimek-Piotrowska W, Walocha J, Rutowski R, Wojtala R. The median nerve in the carpal tunnel. *Folia Morphol* 2011;70(1):41-6.
- Vashishtha. K. Variations of median nerve in carpal tunnel and its distribution in hand. *J Anat Soc India* 2011; 60(2):193-8.
- Amadio PC. Anatomic variations of the median nerve within the carpal canal. *Clin Anat* 1988; 1:23-31.
- Loukas M, Louis RG, Stewart L, Hallner B, Deluca T, Morgan W, *et al*. The surgical anatomy of ulnar and median nerve communications in the palmar surface of the hand. *J Neurosurg* 2007; 106:887-93.
- Dogan NU, Uysal II, Seker M. The communication between the ulnar and median nerves in Upper limb. *Neuroanatomy* 2009; 8:15-9.
- Bas H, Kleinert JM, Louisville KY. Anatomic variations in sensory innervation of the hand and digits. *J Hand Surg* 1999; 24:1171-84.
- Mehta HJ, Gardner WU. A Study of lumbrical muscles in the human hand. *Am J Anat* 1961; 109:227-8.
- Brooks HSJ. Variations in the nerve supply of the lumbrical muscles in the human hand with some observations on its nerve supply. *Med J Iran Hosp* 2001 Jan;20-4.
- Elsabeh S, Mokhtar Z, Hassan A, Biram D. Anatomical study of the arterial and nerve supply of the thenar muscles. 2005.
- Homma T, Sakai T. Thenar and Hypothenar muscles and their innervation by the ulnar and median nerves in the human hand. *Acta Anatomica* 1992; 145:44-9.
- Suhultz R, Kaplan EB. Nerve supply to the muscles and skin of the hand. In: Morton-Kaplan's Functional and Surgical Anatomy of the Hand. 1984. pp.222-43.