

The epidemiological and clinical aspects of *Demodex injai* demodicosis in dogs: a report of eight cases

Aspectos epidemiológicos e clínicos da demodicose por *Demodex injai* em cães: relato de oito casos

Rayane Sol Amaral Silva Sgarbossa^{1*}; Gisele Vieira Sechi¹; Bruna Duarte Pacheco¹; Stephany Buba Lucina²; Maicon Roberto Paulo³; Fabiana dos Santos Monti¹; Marconi Rodrigues de Farias⁴

Abstract

The mite *Demodex injai* causes demodicosis, an uncommon, chronic, and recurrent parasitic dermatopathy in dogs. Demodicosis is characterized by an excessive proliferation of the *Demodex injai* mite in the pilosebaceous unit. Typically, demodicosis occurs in adults, and is associated with an underlying disease or a specific host immunodeficiency. Here, we describe the epidemiological, clinical, dermatological, and therapeutic aspects of *Demodex injai* demodicosis in dogs (n=8) at the Hospital Unit for Companion Animals of the Pontifical Catholic University of Paraná in Brazil. The affected dogs were predominantly purebred, had a mean age of eight years, and showed no gender predisposition. The lesions were predominantly alopecic and erythematous-desquamatory, associated with follicular dyskeratosis and greasiness of the coat, and mainly affected the facial region, in addition to the back and limbs. The animals had a history of allergic, dyskeratotic, endocrine, neoplastic, and immunosuppressive comorbidities. The diagnosis of demodicosis was based on multiple skin scrapings, trichogram, and acetate tape impression of the lesion areas, macroscopic observation, and morphological characterization of the mite. Macrocytic lactones were effectively used for treatment in most cases; however, improvement of the condition may be related to adjunctive treatment of the underlying disease. **Key words:** Canine. Clinical signs. Demodectic mange. Dermatopathy. Mites.

Resumo

Demodicose provocada pelo ácaro *Demodex injai* é uma dermatopatia parasitária, crônica, recorrente, incomum em cães, caracterizada pela proliferação excessiva do ácaro na unidade pilossebácea. É frequentemente caracterizada como de surto adulto, generalizada e associada a uma doença de base ou a uma imunodeficiência específica inerente ao hospedeiro. O presente relato tem como objetivo descrever os aspectos epidemiológicos, clínico-dermatológicos e o tratamento da demodicose por *Demodex injai* em cães (n=8) atendidos na Unidade Hospitalar para Animais de Companhia da Pontifícia Universidade Católica do Paraná, em São José dos Pinhais, Paraná, Brasil. Os animais acometidos apresentaram idade média de oito anos, predominantemente de raças puras e não houve predisposição sexual. As lesões tinham características predominantemente alopecicas e eritemato-descamativas, associadas

¹ Discentes, Programa de Pós-Graduação em Ciência Animal, Pontifícia Universidade Católica do Paraná, PUCPR, Curitiba, PR, Brasil. E-mail: rayane.sgarbossa@gmail.com; gisele.sechi@hotmail.com; bruna.medvet@hotmail.com; fabiana-monti@hotmail.com

² Discente, Programa de Pós-Graduação em Ciências Veterinárias, Universidade Federal do Paraná, UFPR, Curitiba, PR, Brasil. E-mail: teh.lucina@hotmail.com

³ Médico Veterinário Autônomo, Curitiba, PR, Brasil. E-mail: maiconpaulo@hotmail.com

⁴ Prof., Programa de Pós-Graduação em Ciência Animal, PUCPR, Curitiba, PR, Brasil. E-mail: marconi.puc@terra.com.br

* Author for correspondence

à disqueratose folicular e untuosidade da pelagem, acometendo principalmente a região da face, mas também o dorso e os membros. Os animais apresentavam histórico de comorbidades alérgicas, disqueratóticas, endócrinas, neoplásicas ou imunossupressivas de base. O diagnóstico da demodicose foi estabelecido por múltiplos raspados de pele, tricograma e técnica de beliscamento por fita adesiva em áreas lesionais, seguindo à observação macroscópica e caracterização morfológica do ácaro. Instituiu-se tratamento com lactonas macrocíclicas, que se mostraram eficazes na maioria dos casos, entretanto, a involução do quadro pode estar relacionado ao tratamento adjunto das doenças de base.

Palavras-chave: Canino. Sinais clínicos. Sarna demodécica. Dermatopatia. Ácaros.

Introduction

Demodicosis is a parasitic, chronic, and recurrent dermatopathy involving excessive proliferation of mites of the genus *Demodex* sp. in the pilosebaceous unit. This proliferation results in perifolliculitis, folliculitis, and furunculosis (FERRER et al., 2014; MILLER et al., 2013). The main etiologic agent of demodicosis in dogs is *Demodex canis*, whose biological cycle occurs completely intrafollicularly. *D. canis* is found among the normal fauna of canine skin (RAVERA et al., 2013).

The etiopathogenetic mechanisms of demodicosis are unknown; however, evidence suggest that demodicosis is associated with a dysfunction of CD4+ T lymphocytes (OLIVEIRA et al., 2015). This dysfunction is due to immunological exhaustion that is secondary to immunosuppressive, chronic infectious-parasitic, and endocrine diseases or neoplasms. In addition, this dysfunction is also a secondary effect of the use of immunosuppressive medications (FERRER et al., 2014). With the establishment of infection, the proliferation of *D. canis* mites perpetuates changes in cutaneous immunology. These changes include alterations in the apoptotic machinery of immune system cells, which regulates cytokine expression and produces reactive oxygen species (SINGH; DIMRI, 2014).

In 2003, Desch and Hillier described a long-body mite that is twice as long as *D. canis* at all life cycle stages, i.e., *Demodex injai*. The adult male *D. injai* measures approximately twice the length of *D. canis*, while the adult female is about 50% larger than the male (DESCH; HILLIER, 2003). Presumably, these mites mainly live in the glands

and sebaceous ducts, and comprise the normal skin fauna of some canines (MILOSEVIC et al., 2013; SASTRE et al., 2013).

The *D. injai* mite causes a dermatopathy that is not commonly observed in dogs and affects adult dogs regardless of sex. The dermatopathy predominantly affects terrier dogs and its variations, although other breeds can be affected as well (ORDEIX et al., 2009). The disease is often associated with other morbidities, such as allergic dermatitis, hypothyroidism, hyperadrenocorticism, leishmaniasis, diabetes mellitus, neoplasms, and immunosuppressive treatments (MILLER et al., 2013; MUELLER et al., 2012). Clinical signs of the disease include dyskeratosis, an excessively oily coat, odor, alopecia, erythema, folliculocentric papules and pustules, hyperpigmentation, comedones, and secondary bacterial infection (DESCH; HILLIER, 2003).

The recommended treatment for *D. injai* demodicosis is the same as that for *D. canis* demodicosis, i.e., macrocyclic lactones, which have multimodal characteristics and a similar efficacy for both conditions (MUELLER et al., 2012). The use of macrocyclic lactones or amitraz is advocated as acaricidal therapy until microscopic healing is achieved, i.e., three to five negative skin scrapings with monthly intervals. Nevertheless, the success of the therapy is strictly related to the control of secondary bacterial infections and systemic underlying diseases (MUELLER et al., 2012).

Although infrequent in dogs, the incidence of *D. injai* demodicosis may be underdiagnosed in clinical veterinary practice. Thus, to support

veterinary diagnosis and treatment, here we describe epidemiological, clinical, and therapeutic aspects of *D. injai* demodicosis in dogs (n=8).

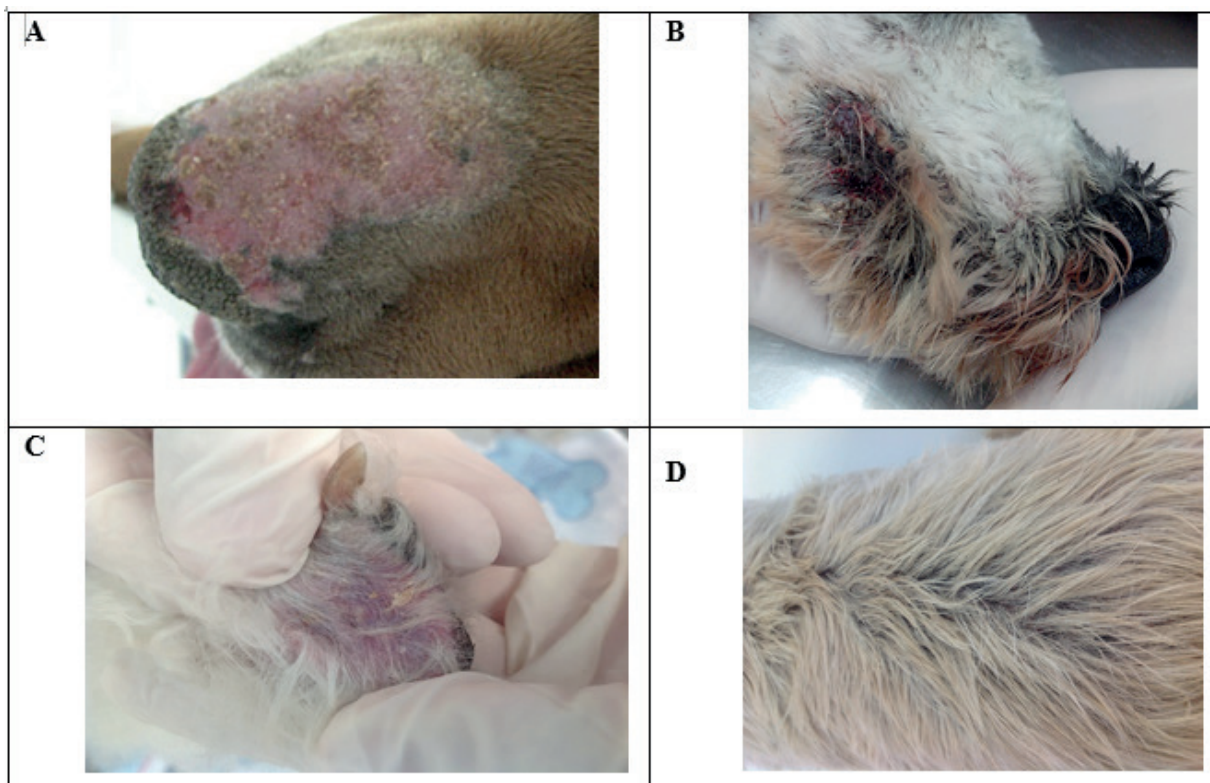
Cases Report

Eight dogs with *D. injai* demodicosis were treated between 2006 and 2014 at the Hospital Unit of Companion Animals of the Pontifical Catholic University of Paraná, São José dos Pinhais, Paraná, Brazil. For these affected dogs, we reviewed the associated breeds affected, age group, and sex (epidemiological characteristics). We also reviewed the lesion topography, integumentary system, and secondary and systemic lesions (clinical and dermatological characteristics) of the affected dogs.

Of the eight dogs with *D. injai* demodicosis, two were Cocker Spaniels, and the remaining five were a Brazilian Mastiff, Poodle, miniature Schnauzer, Akita, and Lhasa-apso. One dog did not present defined breed. Four dogs were female and four dogs were male. The average age was eight years, with a range of three to 13 years.

In four animals, lesions were found in the periocular, nasolabial and perioral planes, as well as the nasal bridge. In three animals, lesions were found in the dorsal thoracic region. In two animals, lesions were found in the auricular pavilions and auditory ducts. In the remaining two animals, lesions were found in either the cervical or foot region (dorsal or interdigital, respectively) (Figure 1A to D).

Figure 1A. Alopecia and erythematous-scaly plaques in the nasal bridge of a 1-year-old female Brazilian Mastiff with *Demodex injai* demodicosis; **B.** Erosion, ulcers, hematic crusts, and blood purulent exudation in the perioral region of an 8-year-old female miniature Schnauzer due to *Demodex injai*; **C.** Erythema, greasiness, and kerato-sebaceous interdigital sediments in the limbs of an 11-year-old male Poodle, with *Demodex injai* demodicosis; **D.** Intensely greasy hairs, hyperpigmentation, and comedones in an 8-year-old female miniature Schnauzer, with *Demodex injai* demodicosis.



Regarding the lesions, in six dogs, papules or folliculocentric papule-crusts and blood-purulent exudates were associated with hypotrichosis, alopecia, erythema, and dyskeratosis. In three dogs, seborrheic keratosis was adhered to the skin and coat, and greasiness and odor were present. External, bilateral, and ceruminous otitis were observed in two dogs, and folliculocentric and hypochromic papules were found in one dog (Figure 1A to D).

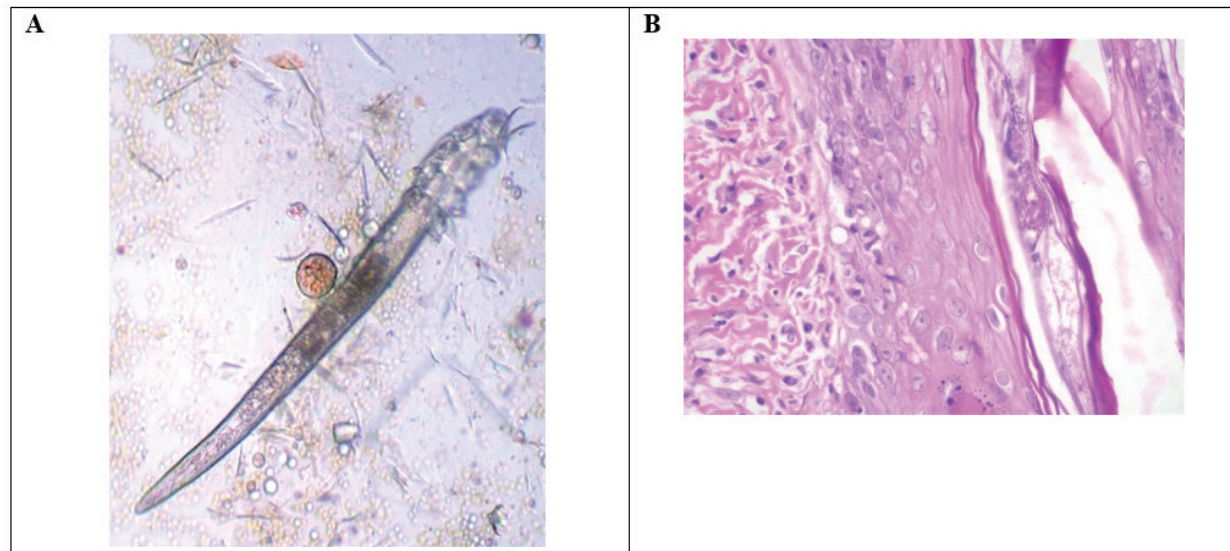
In addition to *D. injai* demodicosis, two dogs presented with atopic dermatitis, one dog had chronic cutaneous lupus erythematosus, one dog had hypothyroidism, and one dog had hyperadrenocorticism, diabetes mellitus, and associated gastric leiomyoma. The remaining three dogs had no recognized comorbidities.

The diagnosis of demodicosis was based on multiple skin scrapings of lesion areas, trichogram and acetate tape impression techniques, and

microscopic observation using 4X and 10X objective lenses. *D. injai* adult mites showed a thin and long-body with an average length of 370 μm , a narrow cephalothoracic region, and an opisthosoma measuring approximately 225 μm . The eggs presented a fusiform format, sharp end, and smooth surface.

Deep skin scrapings were positive in all animals, and showed the presence of multiple adult (Figure 2A) and immature forms of *D. injai* mite. A trichogram and parasitological examination with acetate tape impression were carried out in two dogs, and both dogs tested positive. The parasitological evaluation of the cerumen was positive for *D. injai* in two dogs with external otitis. Both *D. canis* and *D. injai* mites were observed in two dogs. A cytological analysis of blood purulent exudates using a 100X objective lens revealed the presence of *Staphylococcus spp.* in six dogs.

Figure 2A. An adult *Demodex injai* has a long and sharp body of approximately 370 μm in total length, a narrow cephalic-thoracic region, and an opisthosoma measuring approximately 225 μm in length; **B.** Intrafollicular presence of a *Demodex injai* adult mite associated with hyperkeratosis, follicular dilation, perifolliculitis, and lymphocytic mural folliculitis (Hematoxylin and Eosin stained, 100X).



Histopathological analysis based on hematoxylin and eosin (H&E) staining was performed in three dogs. The tests revealed the presence of perifolliculitis and lymphocytic mural folliculitis, hyperkeratosis, and follicular dilatation, with the intrafollicular presence of *D. injai* mites generally in the istmal or deep follicular regions (Figure 2B).

Acaricide treatment using macrocyclic lactones was performed following the guidelines recommended by Mueller et al. (2012). Moxidectin (400 µg kg⁻¹, orally, once a day) was administered to five dogs, resulting in a clinical improvement. Ivermectin (0.5 mg kg⁻¹, orally, once a day) was initially administered to one dog, but without a therapeutic response; it was later replaced with Doramectin (600 µg kg⁻¹, orally, every three days), and clinical improvement was observed. Doramectin therapy (at the same aforementioned dose) was also administered to two other dogs, and this treatment was associated with clinical improvement. For all animals, therapy was suspended after three negative skin scrapings with one-month intervals, and the average time of treatment was five months.

Systemic antibacterial therapy was performed in two animals. Cephalexin was administered (30 mg kg⁻¹, orally, and twice a day for 21 days), with clinical improvement of staphylococcal folliculitis. Topical therapy with 3% benzoyl peroxide shampoo (every seven days for four weeks) was performed for six animals.

Discussion

The *D. injai* demodicosis that we observed in our reported cases manifested as a generalized outbreak in adults, and was generally associated with an underlying disease. Endocrine, autoimmune, allergic, or dyskeratotic diseases may alter the physicochemical structure of the skin or cause immunological disorders, such as T cell immune exhaustion. This change causes an excessive proliferation of *D. injai* mites and the development

of disease in predisposed individuals (FERRER et al., 2014; SINGH; DIMRI, 2014). Sebaceous and cerulean gland hyperplasia associated with primary seborrhea may also lead to *D. injai* demodicosis, as reported in Milosevic et al. (2013).

Regarding the clinical signs of our cases, alopecia and erythematous-desquamative pattern were most commonly observed, denoting the follicular origin of the agent. The presence of kerato-sebaceous sedimentation adherence to the coat suggests follicular hyperkeratosis (MUELLER et al., 2012). Similarly, the presence of papule-crusts and bloody purulent exudate associated with staphylococcal folliculitis was frequent, which is consistent with demodicosis (FERRER et al., 2014).

Histopathological examinations revealed the presence of intrafollicular mites in three dogs, suggesting the pilosebaceous origin of the infection. This condition may have triggered the hyperplasia of sebaceous glands and ducts and the greasy hairs and skin that we observed in some animals. Our findings are consistent with clinical signs of *D. injai* demodicosis (ORDEIX et al., 2009; SASTRE et al., 2013).

Regarding the lesion topography, lesions were found in the periorbital regions, nasal bridge, nasolabial, and perioral planes, which may be related to an increased density of sebaceous glands in these regions (MILLER et al., 2013). Other areas, such as the cervical and thoracic regions, were also commonly affected, consistent with generalized canine demodicosis (FERRER et al., 2014).

We found that a diagnosis of *D. injai* demodicosis could be established using traditional methods, such as deep skin scraping, trichogram, and the acetate tape techniques. The high sensitivity and specificity demonstrated of these methods may be due to a high level of mite infestation, which facilitates extrusion from the follicular ostia (GROSS et al., 2005).

The presence of both *D. canis* and *D. injai* mites were found in two dogs. Rojas et al. (2012) suggests

that these mites are pleomorphic. However, based on genetic sequencing, Sastre et al. (2013) demonstrated that these mites are genetically different, suggesting that *D. injai* mites are molecularly similar to the *Demodex folliculorum* mites associated with rosacea syndrome in humans. Our observation of these two mite species in the same host suggests that the same morbid process may favor excessive proliferation of both mites and the development of folliculitis and furunculosis.

Acaricide treatment with macrocyclic lactones was effective in treating most of our cases of *D. injai* demodicosis, similar to what has been reported for the treatment of *D. canis* demodicosis. These drugs strengthen gamma-aminobutyric acid-mediated neuronal inhibition, promoting neuronal hyperpolarization and inhibiting nerve transmission in mites (MUELLER et al., 2012). Reduction of parasite load enables the host to restore T cell function and immunological control of mite proliferation (FERRER et al., 2014).

Clinical improvement may precede the parasitological healing (MILLER et al., 2013). On average, five months of treatment was necessary to relieve the demodicosis in our cases. One animal was treated with ivermectin and showed no response, which may have been due to associated comorbidities. Concomitant antibacterial treatment and treatment of underlying diseases may have promoted an improvement of demodicosis, which reinforces the etiopathogenic importance of the immune system for this dermatopathy (OLIVEIRA et al., 2015; SINGH; DIMRI, 2014).

Conclusion

D. injai demodicosis is a dermatopathy that often affects adult animals in a generalized manner, mostly as a cutaneous sign of chronic disease or immunosuppression. The predominant changes are alopecia, follicular dyskeratosis, and an oily coat. Diagnosis and treatment of *D. injai*

demodicosis did not differ from that reported for *D. canis* demodicosis. Nonetheless, involution of the dermatological pattern may be related to a concomitant treatment of underlying diseases.

References

- DESCH, C. E.; HILLIER, A. *Demodex injai*: a new species of hair follicle mite (Acari: Demodecidae) from domestic dog (canidae). *Journal of Medical Entomology*, Lanham, v. 40, n. 2, p. 146-149, 2003.
- FERRER, L.; RAVERA, I.; SILBERMAYR, K. Immunology and pathogenesis of canine demodicosis. *Veterinary Dermatology*, Oxford, v. 25, n. 5, p. 427-e65, 2014.
- GROSS, T. L.; IHRKE, P. J.; WALDER, E. J.; AFFOLTER, V. K. *Skin diseases of the dog and the cat: clinical and histopathologic diagnosis*. 2. ed. Oxford: Blacweel Science, 2005.
- MILLER, W. H.; GRIFFIN, C. E.; CAMPBELL, K. L. *Muller & Kirk's small animal dermatology*. 2. ed. St. Louis: Saunders, 2013.
- MILOSEVIC, L. A.; FRANK, L. A.; BRAHMBHATT, R. A.; KANIA, S. A. PCR amplification and DNA sequencing of *Demodex injai* from otic secretions of a dog. *Veterinary Dermatology*, Oxford, v. 24, n. 2, p. 286-288, 2013.
- MUELLER, R. S.; BENSIGNOR, E.; FERRER, L.; HOLM, B.; LEMARIE, S.; PARADIS, M.; SHIPSTONE, M. A. Treatment of demodicosis in dogs: 2011 clinical practice guidelines. *Veterinary Dermatology*, Oxford, v. 23, n. 2, p. 86-e21, 2012.
- OLIVEIRA, C. D.; LARSSON, C. E.; CAMARGO, M. M. Longitudinal assessment of T-lymphocyte subpopulations during generalized demodicosis in dogs and their relationship with remission. *Veterinary Dermatology*, Oxford, v. 26, n. 1, p. 18-e6, 2015.
- ORDEIX, L.; BARDAGÍ, M.; SCARAMPELLA, F.; FERRER, L.; FONDATI, A. *Demodex injai* infestation and dorsal greasy skin and hair in eight wirehaired fox terrier dogs. *Veterinary Dermatology*, Oxford, v. 20, n. 4, p. 267-272, 2009.
- RAVERA, I.; ALTET, L.; FRANCINO, O.; SÁNCHEZ, A.; ROLDÁN, W.; VILLANUEVA, S.; BARDAGÍ, M.; FERRER, L. Small *Demodex* populations colonize most parts of the skin of healthy dogs. *Veterinary Dermatology*, Oxford, v. 24, n. 1, p. 168-E37, 2013.

ROJAS, M.; RIAZZO, C.; CALLÉJON, R.; GUEVARA, D.; CUTILLAS, C. Molecular study on three morphotypes of *Demodex* mites (Acarina: Demodicidae) from dogs. *Parasitology Research*, Berlin, v. 11, n. 5, p. 2165-2172, 2012.

SASTRE, N.; RAVERA, I.; FERREIRA, D.; ALTET, L.; SÁNCHEZ, A.; BARDAGÍ, M.; FRANCINO, O.;

FERRER, L. Development of a PCR technique specific for *Demodex injai* in biological specimens. *Parasitology Research*, Berlin, v. 112, n. 9, p. 3369-3372, 2013.

SINGH, S. K.; DIMRI, U. The immuno-pathological conversions of canine demodicosis. *Veterinary Parasitology*, Amsterdam, v. 203, n. 1-2, p.1-5, 2014.

