

# Forgotten Cause of Ear Infection: Forgotten Cotton Buds

## Abstract

A 76 year old man with multiple comorbidities presented with a 4 week history of right ear infection associated with intense pain and offensive discharge. The right external ear canal was full of granulation tissue. The patient required hospital admission for analgesia, intravenous and topical antibiotic treatment for suspected malignant otitis externa. The patient responded well to medical therapy and one week later the granulation tissue regressed enough to reveal 2 deeply impacted cotton buds which were removed in the clinic. At subsequent reviews, the patient showed complete resolution of ear infection. Detached cotton tips impacted in the deeper parts of the external ear canal are the most common aural foreign body removed in adults. Public awareness of cotton bud use related complications needs to be raised. Unfortunately, despite doctors' and manufacturers' advice against the use of cotton buds in the ears, these remain in common use.

**Keywords:** Ear canal; Malignant otitis externa; Analgesia; Ear infection; Cotton buds; Granulation tissue; Foreign body; Ear wax; Hearing loss; Mastoiditis; Osteomyelitis; Cranial nerve; Otoloscopic examination; Micro suction; Tympanic membrane; Otomyiasis; Concha; Pinna

## Case Report

Volume 3 Issue 5 - 2015

**Shakeel M\*, Nair S, Ahmad Z and Gordon A**

*Department of Otolaryngology - Head and Neck surgery,  
Counties Manukau Superclinics, New Zealand*

**\*Corresponding author:** M Shakeel, ORL Fellow,  
Department of Otolaryngology - Head and Neck surgery,  
Counties Manukau Super clinics, 901 Great South Road,  
Manukau, Auckland, New Zealand, Tel: +64224383784; Fax:  
+649-277-1697; Email: drshakeel@doctors.org.uk

**Received:** October 13, 2015 | **Published:** November 02, 2015

## Introduction

The use of cotton buds for actively cleaning of the ears is common despite the old adage 'do not put anything smaller than your elbow in the ear'. The cotton buds are commonly used to remove the ear wax. The frequently reported complications secondary to cotton bud use include wax impaction, otitis externa and tympanic membrane perforation. Not infrequently, cotton buds can lodge in the ear canal, requiring removal by an experienced health care professional. We present the management of a patient who developed a severe ear infection secondary to forgotten cotton buds in the ear canal.

## Case Presentation

A 76 year old man with multiple comorbidities presented with a 4 week history of an infected right ear associated with hearing loss, intense pain and offensive discharge. The patient had been treated in the community by his family physician, but his otitis externa failed to settle down. The patient was reviewed in our emergency clinic where he was noted to have granulation tissue filling his right external auditory canal (EAC).

## Differential diagnosis

If the otitis externa is untreated then granulation tissue may develop in the ear canal. Sometimes involvement of the middle ear and mastoid antrum in the infective process can result in acute Mastoiditis and abscess with its potential to spread extra and intracranially. The examination of our patient revealed only granulation tissue in the ear canal and the mastoid region was normal on inspection and palpation. Because our patient was diabetic the diagnosis of malignant otitis externa was made. Reassuringly, there was no cranial nerve involvement and the patient responded well to intravenous antibiotics treatment. Based on his good clinical improvement no imaging was arranged

but most cases would need a CT scan of the temporal bone and skull base to rule out skull base osteomyelitis if cranial nerve involvement is suspected.

## Treatment

The patient was admitted to the ward for aggressive medical management, including pain relief, intravenous and topical antibiotic treatment for suspected malignant otitis externa. The patient responded well to treatment and was subsequently discharged home on oral antibiotics.

## Outcome and follow up

Clinic review a week later confirmed, ongoing improvement. At this stage, when the granulation tissue had regressed further, we were able to identify two deeply impacted cotton buds. The cotton buds were removed in the clinic and revealed an intact featureless tympanic membrane. The patient was reviewed in the clinic on a weekly basis for next 6 weeks and was provided with micro suction cleaning of the affected followed by instillation of topical antibiotic cream. At subsequent reviews, the patient showed complete resolution of the ear infection, with the tympanic membrane returning to a more normal appearance. A permanent hearing loss was not noted. The patient was advised against any future use of cotton buds in his ears.

## Discussion

The cotton bud was invented in the 1920s by Leo Gerstenzang after he attached wads of cotton to toothpicks [1]. Since then cotton buds have remained in common use to clean the ears in both adults and children. Users regard this as a safe means of removing ear wax and to 'itch' irritating ear canals. Many often disagree that cotton buds can cause infections, wax impaction or perforations [2]. Some physicians even suggest that cotton

bud use related ear complications are over stated [3]. The most common otolaryngology procedure performed in primary care is ear wax removal [4]. There is no doubt that cotton bud use can lead to impaction of the wax in the deeper part of the ear canal (Figure 1) with its associated symptomatology [5]. Detached cotton tips impacted in the deeper parts of the EACs (Figure 2&3) are the second most common foreign bodies in the ear canals of children and are the most common aural foreign bodies in adults [6,7]. The relationship between cotton bud related tympanic membrane (TM) perforations and hearing loss is well established [8]. TM perforations may not heal spontaneously and surgery may be required to repair it [9]. In addition, cotton buds are the most common cause of accidental penetrating ear injury in children [10]. At times the forgotten cotton buds can lead to unusual complications like Otomyiasis if the anatomy of the ear canal is not normal [11]. If brought to the attention of an otolaryngologist, the detached cotton bud retained in the ear canal can be removed under direct vision thereby preventing further complications (Figure 2&3). But if the cotton bud is forgotten in the ear canal for some time, then on otoscopic examination it is difficult to distinguish ear wax from a cotton bud. However, the fibres of the cotton bud are more obvious when a microscope is used to examine the ear, which helps to differentiate wax from a cotton bud (Figure 4).

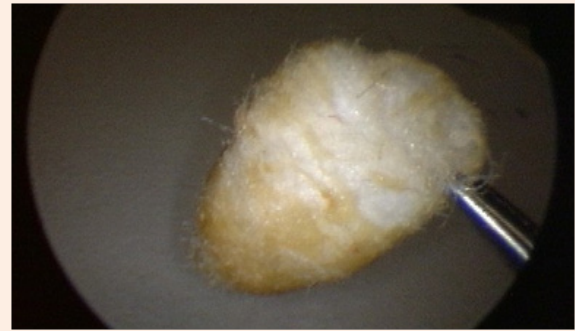

Figure 3: Removal of cotton bud from the ear canal.

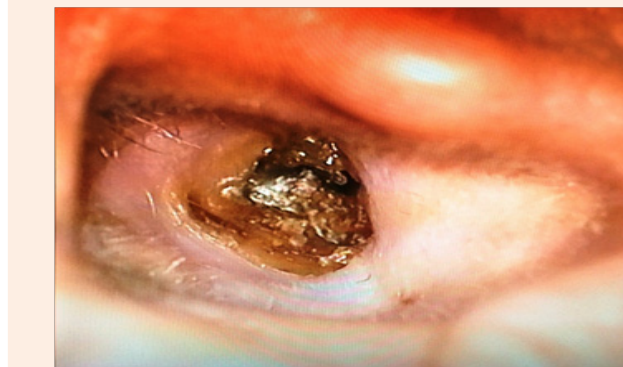


Figure 1: Wax impaction in the ear canal secondary to cotton bud use.

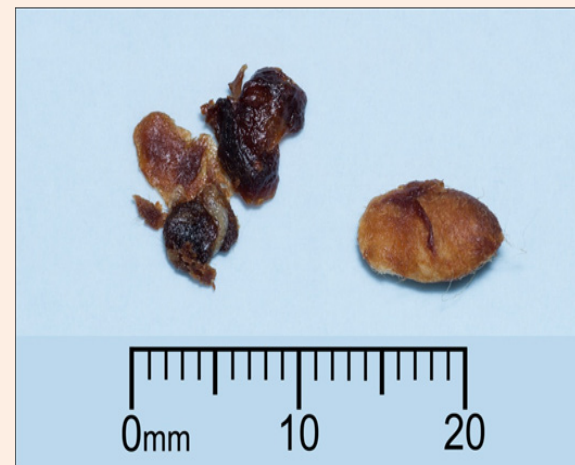

Figure 4: Differentiation of impacted cotton bud from wax.

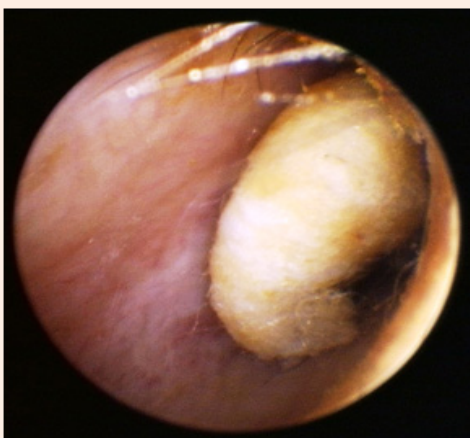


Figure 2: Detached cotton bud in the right ear canal.

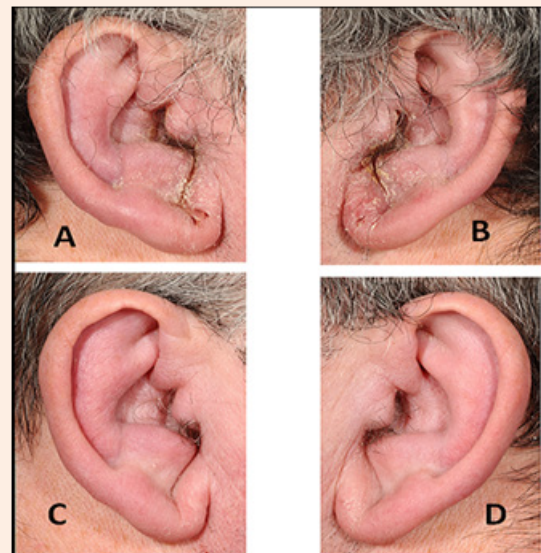


Figure 5: Involvement of outer ear skin in otitis externa (A & B) with resolution of infection with topical antibiotic and steroid treatment (C & D).

Cotton bud fibres incite an intense tissue reaction in the ear canal leading to inflammation and infection. If left in the ear canal for some time, the resultant otitis externa can lead to involvement of the skin of the concha and pinna. Accordingly, the skin of the pinna may need to be treated as well. In our case a mild topical steroid cream was used with good effect (Figure 5). The granulation tissue in the ear canal can engulf the foreign body and that happened in our patient. However, the granulation tissue in the ear canal of our patient continued to settle down over the following weeks revealing two deeply impacted cotton buds which were removed. It is important to review the patient regularly (often weekly) until the inflammation has settled. This may involve frequent micro suction (using a microscope to vacuum the ear canal debris) and application of topical creams or ointments to the EAC. Topical treatments may contain a combination of corticosteroid, antibiotic and antifungal agents. The patient was strongly advised against the use of cotton buds in his ears.

### Recommendations

Our case also highlights the fact that at times the patients may not remember inserting foreign bodies in their ear. Indeed, they may not consider a cotton bud to be a foreign body. In this case, the patient denied using a cotton bud, but it was only when the cotton buds became visible that the patient divulged the information that he had been using the cotton buds for itchy ears. Therefore, it is prudent to enquire about the use of cotton buds in patients presenting with ear problems. There would appear to be a need to raise public awareness about the self cleansing mechanism of the ear canal and to highlight that a normal ear canal does not need to be actively cleaned [12]. The ear wax protects, cleans, and lubricates the skin of the ear canal [13].

### Conclusion

Cotton bud use in the ear canal can lead to serious complications requiring hospital admission. The use of cotton buds should be documented in such scenarios. Public awareness of cotton bud use related complications needs to be raised. Unfortunately, despite doctors' and manufacturers' advice against the use of cotton buds in the ears, these remain in common use.

### Learning Points

- i. Cotton bud use in the ear canal can lead to serious complications requiring hospital admission. Otomicroscopic examination is essential in patients presenting with persistent ear infections.

- ii. The use of cotton buds should be documented in patients presenting with ear infections as patients may not divulge this information voluntarily.
- iii. Public awareness of cotton bud use related complications needs to be raised.

### References

1. [http://en.wikipedia.org/wiki/Cotton\\_swab](http://en.wikipedia.org/wiki/Cotton_swab)
2. Hobson JC, Lavy JA (2005) Use and abuse of cotton buds. *J R Soc Med* 98(8): 360-361.
3. Hickman J (2011) Extent of cotton-bud use in ears. *Br J Gen Pract* 61(593): 722.
4. Guest JF, Greener MJ, Robinson AC, Smith AF (2004) Impacted cerumen: Composition, production, epidemiology and management 97(8): 477-488.
5. Macknin ML, Talo H, Medendrop SV (1994) Effect of cotton-tipped swab use on ear-wax occlusion. *Clin Pediatr (Phila)* 33(1): 14-18.
6. Ryan C, Ghosh A, Wilson-Boyd B, Smit D, O'Leary S (2006) Presentation and management of aural foreign bodies in two Australian emergency departments. *Emerg Med Australas* 18(4): 372-378.
7. Nussinovitch M, Rimon A, Volovitz B, Raveh E, Prais D (2004) Cotton-tip applicators as a leading cause of otitis externa. *Int J Pediatr Otorhinolaryngol* 68(4): 433-435.
8. Kravitz H, Neyhus AI, Dale DO, Laker HI, Gomberg RM, et al. (1974) The cotton-tipped swab: a major cause of ear injury and hearing loss. *Clin Pediatr (Phila)* 13(11): 965-970.
9. Smith M, Darrat I, Seidman M (2012) Otologic complications of cotton swab use: one institution's experience. *Laryngoscope* 122(2): 409-411.
10. Steele BD, Brennan PO (2002) A prospective survey of patients with presumed accidental ear injury presenting to a paediatric accident and emergency department. *Emerg Med J* 19(3): 226-228.
11. Riaz CF, Judd O, Conboy PJ (2011) Otomyiasis of the mastoid cavity: an unusual complication of cotton-swab use *Ear Nose Throat J* 90(6): E34.
12. Alvord LS, Farmer BL (1997) Anatomy and orientation of the human external ear. *J Am Acad Audiol* 8(6): 383-390.
13. Jung TT, Jinn TH (2003) Diseases of the external ear. In: Snow JB, Ballenger JJ (Eds.), *Ballenger's otorhinolaryngology head and neck surgery*. (16<sup>th</sup> edn), Decker, Ontario, Canada, pp. 230-248.