



ORIGINAL RESEARCH ARTICLE

The efficacy and safety of a 70% glycolic acid peel with vitamin C for the treatment of acne scars

Heng Jun Khee, Liao MeiQi May*, Yang Shiyao Sam, Aw Chen Wee Derrick, Ho Sue-Ann

University Dermatology Clinic, National University Hospital (NUH), Singapore

Abstract: Acne scarring is a common complication associated with significant psychological distress. Both glycolic acid (GA) and vitamin C are known to improve the appearance of acne scarring. We performed a review of 13 patients treated with three 70% GA peels with vitamin C at four weeks apart. There was a statistically significant improvement in acne scarring and post-inflammatory hyperpigmentation from the baseline. Maximal effects were noted four weeks after the third chemical peel. It has an excellent safety profile with no permanent adverse effects noted. A combination of 70% glycolic acid with vitamin C chemical peel is an efficacious, well-tolerated treatment of acne scarring in Asian skin.

Keywords: Chemical peel; glycolic acid; acne scars

Citation: Heng JK, Liao MM, Yang SS, Aw CWD, Ho SA. The efficacy and safety of a 70% glycolic acid peel with vitamin C for the treatment of acne scars. *J Surg Dermatol* 2017; 2(4): 209–213; <http://dx.doi.org/10.18282/jsd.v2.i4.94>

*Correspondence to: Liao MeiQi May, University Dermatology Clinic, National University Hospital (NUH), 5 Lower Kent Ridge Rd, Level 3, Lift Lobby 1, Main Building Level 3, 119074, Singapore, maylmq@gmail.com

Received: 19th October 2016; Accepted: 2nd January 2017; Published Online: 3rd August 2017

Introduction

Acne is a common skin disorder which often results in permanent scarring. This can constitute a persisting disfiguring problem and is associated with considerable psychological distress. The development of acne scars is multifactorial, and is associated with the delay in the initiation of acne treatment, the duration of inflammatory response and the enzymatic degradation of collagen fibers. There are two main types of scars: atrophic (net loss of collagen) and hypertrophic (net gain of collagen) scars. Various treatment options are available for acne scarring, which include chemical peels, dermabrasion/microdermabrasion, laser resurfacing, punch techniques, needling and combined therapies.

Chemical peels, also known as chemexfoliation or derma peeling, have been used for many years in the treatment of acne scarring. Often, best results are achieved for superficial macular scars, and the level of improvement is extremely variable in different patient conditions^[1]. Glycolic acid (GA), a member of the alpha hydroxy acids (AHA) family, is one of the most commonly used chemical peeling agents. We report our experience in treating acne scars

with a commercial preparation of 70% GA and vitamin C chemical peel (Therapeutic Dermatologic Formula VCI[®], Ocean Health, USA).

Materials and methods

Methodology

We included patients with acne scarring treated with 70% GA peels with vitamin C at the dermatology clinic of National University Hospital (Singapore) between September 2014 and February 2015.

All patients above the age of 21 were eligible. The exclusion criteria included the following: patients who had taken oral retinoids, chemical peels or laser ablative procedures in the past six months; were in pregnancy; were breastfeeding; or had active facial dermatitis. All patients who met the inclusion criteria were instructed to stop topical retinoid one week prior to embarking on the priming regime. They received a series of three 70% GA peels with vitamin C, each four weeks apart. The treatment regimen and clinical evaluations are described below.

Treatment regimen

Priming

All patients were instructed to apply the following in order, twice daily, for 1 month: Cleanser (Therapeutic Dermatologic Formula, AHA facial wash), followed by Toner (Therapeutic Dermatologic Formula, Mild astringent), Control (Therapeutic Dermatologic Formula, AHA Oily & Acne Solution 8), Facial moisturiser (Therapeutic Dermatologic Formula, Ultra-Light Hydrator). Patients were also instructed to apply Sunblock (Therapeutic Dermatologic Formula, PA +++ UVA/UVB, SPF 50+) once daily in the morning. The list of ingredients for each product is listed in Appendix 1.

Peeling

Four weeks later, the patient received the first chemical peel. A single pass of 70% GA and vitamin C peel (Therapeutic Dermatologic Formula, VCI® High Potency Peel) was applied for 3–5 min depending on patient’s tolerance. A test spot of the peel was performed to evaluate tolerability prior to performing the full face peel. Spot neutralization (Therapeutic Dermatologic Formula Peel Neutralizer) was performed on areas of erythema, with subsequent full neutralization upon termination of the peel. Vitamin C Serum (Therapeutic Dermatologic Formula, “C”-scape serum) and Sunblock (Therapeutic Dermatologic Formula, PA +++ UVA/UVB, SPF 50+) was applied thereafter.

Post-peel care

For the first three days of each peel, patients were instructed to follow the same regime as that listed in “Priming” above, excluding the AHA Oily & Acne Solution 8. Patients were also instructed to use 10% vitamin C serum (Therapeutic Dermatologic Formula, “C”-scape serum) and Quick Recovery Cream (Therapeutic Dermatologic Formula, Quick Recovery Cream) twice daily. From day 4 until the next peel, Quick Recovery Cream was substituted with AHA Oily & Acne Solution 8. Each patient received three 70% GA chemical peels with vitamin C, each four weeks apart (*i.e.* week 4, 8 and 12).

Clinical evaluation

Patients were graded using the ECCA (*Echelle d’Evaluation Clinique des Cicatrices d’acné*, or Scale for Clinical Evaluation of Acne Scars) scale for acne scarring and post-acne hyperpigmentation index (PAHPI) for the evaluation of post-inflammatory hyperpigmentation^[2,3].

The ECCA scale is a semi-quantitative grading system for acne scarring. It is based on summation of individual types of scars and their numerical extent. Scar types deemed to be more visibly disfiguring were allocated higher weighting factor. The scars, with their corresponding weighting factor in parentheses, are as follows:

1. V-shaped atrophic scars, diameter <2 mm, punctiform (15)
2. U-shaped atrophic scars, diameter of 2–4 mm, sheer edges (20)
3. M-shaped atrophic scars, diameter >4 mm, superficial and irregular surface (25)
4. Superficial elastolysis (30) (This is part of the ECCA official scoring criteria. We based it based on cutaneous findings compatible with solar elastosis, *i.e.* thickened, yellow, dry and furrowing of skin.)
5. Hypertrophic inflammatory scars, scars of <2 years of age (40)
6. Keloid scars, hypertrophic scars, of >2 years of age (50)

Each of the above scars was evaluated with a four-point scale, with rating of absent (0), few scars (1), limited number of scars (2) and many scars (3).

PAHPI is a validated scoring system evaluating the post-inflammatory hyperpigmentation in patients with acne vulgaris. It consists of three characteristics (**Table 1**): size (*S*), intensity (*I*) and number of lesions (*N*).

Digital imaging was performed using Visia® Complexion Analysis. Standardized imaging was captured at each visit at week 0 (baseline), 4, 8, 12 and 16. Ratings on the clinical photographs were done separately by two dermatologists: the managing dermatologist and an independent dermatologist.

Safety assessment score

In addition, we monitored five clinical parameters of side effects after administration of each chemical peel: redness, swelling, oozing or crusting, hyperpigmentation and scarring.

A 10-point (1–10) visual analogue scale (VAS) for subjective assessment was also performed at baseline (week 0) and weeks 12 and 16.

Table 1. Scoring the post-acne hyperpigmentation index

Weighted score (<i>S</i>)	Median lesion size (mm)
2	<3
4	3–6
6	7–10
8	>10
Weighted score (<i>I</i>)	Median lesion intensity
3	Slightly darker than surrounding skin
6	Moderately darker than surrounding skin
9	Significantly darker than surrounding skin
Weighted score (<i>N</i>)	No. of lesions
1	1–15
2	16–30
3	31–45
4	46–60
5	>60

Note: Total post-acne hyperpigmentation index = *S* + *I* + *N*; score range: 6–22

Results

Study population

15 patients (7 males, 8 females) with a mean age of 28.2 years (age range 22–42) were identified during the six-month period from September 2014 to February 2015. Their skin types were either Fitzpatrick skin type III or IV. Two patients (13.3%) did not complete the series of peels. One patient withdrew due to mild contact dermatitis to the chemical peel and the other withdrew for personal reasons. A total of 13 patients' results were analyzed (7 males, 6 females).

Physician scores

ECCA scoring

According to the ECCA scale, a score of 0 indicates no scarring and a score of 540 indicates severe acne scarring. The mean pre-treatment ECCA score was 170.38 (SD = 39.18). The average of both physicians' ECCA scores are shown below (Table 2).

There was a trend towards improvement, with maximal effect noted at week 16, where a total mean score of 115 (SD = 41.37) was achieved (Figure 1, Figure 2a and 2b).

The differences in acne scarring scores at week 12 and week 16 compared with pre-treatment scores were assessed using the Wilcoxon signed-rank test. There was a statistically significant reduction in ECCA scores between week 12 and week 0 (mean change = 39.23, $P = 0.001$), and this improvement was maintained during the review in week 16 (mean change = 55.39, $P = 0.001$).

Table 2. Average of Physicians' ECCA scores

Patient	Week 0	Week 8	Week 12	Week 16	Percentage improvement
1	180	135	142.5	117.5	34.70%
2	200	180	165	165	17.50%
3	122.5	122.5	90	90	26.50%
4	202.5	160	160	167.5	17.30%
5	200	145	172.5	125	37.50%
6	175	97.5	97.5	92.5	47.10%
7	107.5	110	92.5	75	30.20%
8	195	195	185	165	15.40%
9	140	140	82.5	72.5	48.20%
10	230	207.5	187.5	155	32.60%
11	112.5	82.5	82.5	47.5	57.80%
12	155	122.5	107.5	80	48.40%
13	195	162.5	140	142.5	26.90%

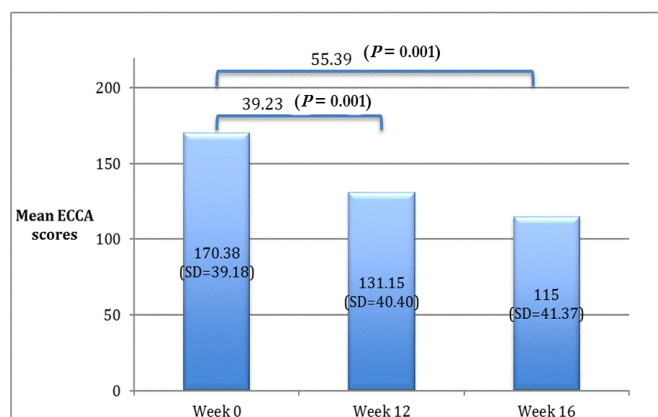


Figure 1. ECCA scores pre- and post-treatment

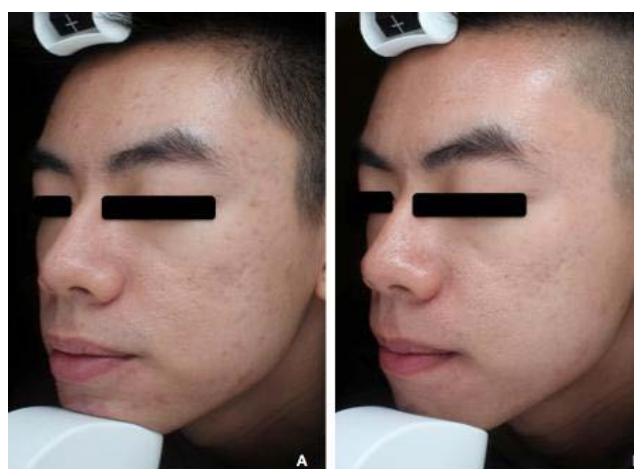

Figure 2a. A 23-year-old patient at: (A) week 0, pre-treatment; and (B) week 16, after three sessions of 70% GA peel with vitamin C

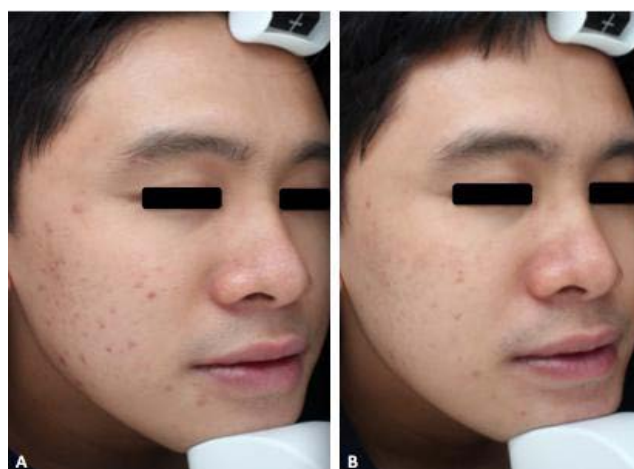

Figure 2b. A 27-year-old patient at: (A) week 0, pre-treatment; and (B) week 16, after three sessions of 70% GA peel with vitamin C

PAHPI scoring

A PAHPI score of 6 indicates mild post-acne hyperpigmentation, and a score of 22 indicates severe post-acne hyperpigmentation. The mean pre-treatment PAHPI score was 11.73 (SD = 39.18). The average of both physicians' PAHPI scores are shown below (Table 3).

There was a trend towards improvement, with maximal effect noted at week 16 where a mean score of 7.96 (SD = 2.21) was achieved (Figure 3).

The differences in acne scarring scores at week 12 and week 16 compared with pre-treatment scores were assessed using the Wilcoxon signed-rank test. There was a statistically significant reduction in ECCA scores between week 12 and week 0 (mean change = 2.81, $P = 0.002$), and this improvement was maintained during the review in week 16 (mean change = 3.77, $P = 0.002$).

Table 3. Average of both physicians' PAHPI scores

Patient	Week 0	Week 8	Week 12	Week 16	Percentage improvement
1	16	13.5	12	12	25.00%
2	15	12.5	11.5	11.5	23.30%
3	9.5	9	6	6	36.80%
4	12	7.5	10.5	9	25.00%
5	15	11.5	9	11	26.70%
6	11	8	8	6.5	40.90%
7	6	7.5	6.5	6	0.00%
8	10	8.5	8.5	7	30.00%
9	9	8.5	6	6	33.30%
10	15	13.5	11	8	46.70%
11	8	7.5	6	6	25.00%
12	12	8	9	7	41.70%
13	14	12	12	7.5	46.40%

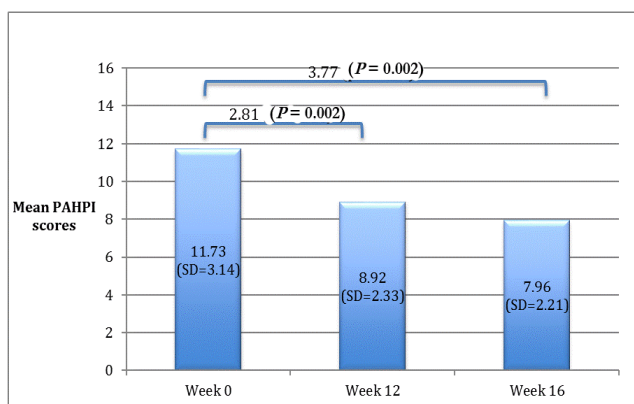


Figure 3. PAHPI scores pre- and post-treatment

Visual analogue scale

The visual analogue scale (VAS) ranged from 1 (no features of acne scars) to 10 (severe acne scarring). 9 out of 13 patients (69.2%) scored an improvement post-peel as compared to pre-peel scores. The mean pre-treatment score was 7.23, with maximal effect noted at week 12 with a mean score of 5.38, which was sustained at week 16 as well. Most of the patients experienced further improvement at week 16, except for two whose scores remained unchanged from week 12. 9 out of 13 patients (69.2%) scored an improvement post-peel as compared to pre-peel scores.

Safety assessment

The number of patients who experienced side effects post-chemical peel are tabulated below (Table 4). All patients experienced erythema and approximately half experienced some degree of swelling post-chemical peel. These resolved completely at week 16. Two patients reported hyperpigmentation at week 8; this had resolved in both patients at week 16. There was no permanent adverse reaction including scarring, oozing or crusting at any time.

There was mild hyperpigmentation noted at week 12 in two patients (15%), which fully resolved by week 16. The redness and swelling were transient and resolved within 1–3 days.

The 70% GA peel with vitamin C is tolerable and well accepted by our patient population (Table 5).

Discussion

Acne scarring is a common acne complication with a high prevalence amongst adolescents and young adults. It is often accompanied by post-inflammatory hyperpigmentation, which are unfortunate consequences associated with psychological distress, depression, poorer

Table 4. Safety assessment of side effects post-chemical peel

	Week 4	Week 8	Week 12	Week 16
Redness	13	13	13	0
Swelling	7	9	6	0
Oozing/crusting	0	0	0	0
Hyperpigmentation	0	2	0	1
Scarring	0	0	0	0

Table 5. Safety assessment score post-chemical peel, from 1 (absent) to 4(severe)

Side effect	Mean score (SD)		
	Week 4	Week 12	Week 16
1. Redness	2.38 (0.51)	2.69 (0.63)	2.46 (0.66)
2. Swelling	1.69 (0.63)	1.69 (0.48)	1.46 (0.51)
3. Oozing/crusting	1.00	1.00	1.00
4. Hyperpigmentation	1.00	1.15 (0.37)	1.00
5. Scarring	1.00	1.00	1.00

academic performance and higher unemployment rates^[4]. Furthermore, the appearance of acne scars worsens with normal aging and post-inflammatory hyperpigmentation is longer lasting in patients with darker skin tones, as in our study population.

GA is the smallest organic acid amongst the alpha-hydroxy acids (AHA). It penetrates the epidermis easily, making it the most common AHA used for chemical peeling. It exerts its beneficial effect on skin by moderating keratinization, promoting epidermolysis, dispersing basal layer melanin, and increasing dermal hyaluronic acid and collagen genes expression^[5]. The intensity of GA peel is mainly determined by the concentration of the acid and proper neutralization is required to terminate the peel^[6]. Vitamin C has also been used to improve acne scarring with its potent natural antioxidant properties and important role in the collagen biosynthetic pathway.

Erbağcı and Akçalı compared GA peels *versus* daily 15% GA cream^[7]. The study showed that six consecutive 70% GA peels performed biweekly resulted in significant improvement in atrophic scars scores compared to daily usage of 15% GA cream (54.7% *vs.* 37.2%, respectively). The study also showed that both high and low potency GAs were superior to placebo. Another study, by Sharad, evaluated the use of 35% GA as an adjuvant to microneedling for acne scars in Indian patients^[8]. There was significant mean improvement in acne scars in patients receiving 35% GA plus microneedling compared to the group who only received microneedling (62% *vs.* 31%, respectively). These studies showed that GA therapy contributed to a significant improvement in acne scarring.

We expanded on the works of Erbağcı and Sharad in investigating the effects of 70% GA peels on acne scarring. Our study is one of the few studies which used objective measures such as the ECCA and PAHPI scores, and showed statistically significant improvement in both acne scarring and post-inflammatory hyperpigmentation. Improvements were noticed by week 12, four weeks after the second peel (ECCA mean change: -39.23) and further improvements were observed at week 16, four weeks after the third peel (ECCA mean change: -55.39). Maximal effects for both ECCA and PAHPI scores were seen in week 16. Improvement in ECCA scores was mainly from improvement of atrophic scar scores rather than hypertrophic or keloidal scar scores. This finding is consistent with the mechanism of action of GA in stimulating collagen synthesis^[9].

Our study showed good results with high potency glycolic acid with vitamin C. Furthermore, there was an excellent safety profile of the 70% GA peel with vitamin C. Most patients experienced redness or mild swelling which were transient. Post-inflammatory hyperpigmentation occurred in 15% of our patients, which is comparable to Erbağcı's study, and usually resolved within a few weeks.

Conclusion

In conclusion, a combination 70% GA peel with vitamin C is a well-tolerated effective treatment for acne scarring

in Asian skin. Small sample size and lack of a long-term follow up are limitations of our study. Larger studies with a longer period of follow-up will be useful in determining the sustainability effect of this chemical peel.

Acknowledgements

The authors thank Ms. Samantha Lee (Senior Manager, Ocean Health Pte. Ltd.), and all NUH dermatology clinic staff.

Conflict of interest

The author declares no potential conflict of interest with respect to the research, authorship and/or publication of this article.

Supplementary information

Appendix 1: The ingredients of topical treatments. This supplementary information is available free of charge on JSD's website at doi: 10.18282/jsd.v2.i4.94.

References

1. Fabbrocini G, Annunziata MC, D'arco V, De Vita V, Lodi G, et al. Acne scars: Pathogenesis, classification and treatment. *Dermatology Res Practice* 2010; 2010. doi: 10.1155/2010/893080.
2. Dreno B, Khammari A, Orain N, Noray C, Merial-Kieny C, et al. ECCA grading scale: An original validated acne scar grading scale for clinical practice in dermatology. *Dermatology* 2006; 214(1): 46–51. doi: 10.1159/000096912.
3. Savory SA, Agim NG, Mao R, Peter S, Wang C, et al. Reliability assessment and validation of the postacne hyperpigmentation index (PAHPI), a new instrument to measure postinflammatory hyperpigmentation from acne vulgaris. *J Am Acad Dermatol* 2014; 70(1): 108–114. doi: 10.1016/j.jaad.2013.09.017.
4. Fried RG, Wechsler A. Psychological problems in the acne patient. *Dermatol Ther* 2006; 19(4): 237–240. doi: 10.1111/j.1529-8019.2006.00079.x.
5. Bernstein EF, Lee J, Brown DB, Yu R, Van Scott E. Glycolic acid treatment increases type I collagen mRNA and hyaluronic acid content of human skin. *Dermatol Surg* 2001; 27(5): 429–433. doi: 10.1046/j.1524-4725.2001.00234.x.
6. Sharad J. Glycolic acid peel therapy: A current review. *Clin Cosmet Invest Dermatol* 2013; 2013(6): 281–288. doi: 10.2147/CCID.S34029.
7. Erbağcı Z, Akçalı C. Biweekly serial glycolic acid peels *vs.* long-term daily use of topical low-strength glycolic acid in the treatment of atrophic acne scars. *Int J Dermatol* 2000; 39(10): 789–794. doi: 10.1046/j.1365-4362.2000.00076.x.
8. Sharad J. Combination of microneedling and glycolic acid peels for the treatment of acne scars in dark skin. *J Cosmet Dermatol* 2011; 10(4): 317–323. doi: 10.1111/j.1473-2165.2011.00583.x.
9. Kim SJ, Park JH, Kim DH, WON YH, Maibach HI. Increased *in vivo* collagen synthesis and *in vitro* cell proliferative effect of glycolic acid. *Dermatol Surg* 1998; 24(10): 1054–1058. doi: 10.1111/j.1524-4725.1998.tb04074.x.