JSLS

Laparoscopic Resection of Solitary Adrenal Metastasis from Lung Carcinoma: A Case Report

Dimitrios A. Linos, MD[1], Vassilios Spiridon C. Avlonitis, MD[2], Kosmas Iliadis, MD[3]

ABSTRACT

Background and Objectives: Patients with adrenal metastases from bronchogenic carcinoma are considered incurable and any surgical treatment is usually excluded. A review of the few cases of adrenalectomy for metastases from lung cancer that have been reported in the literature shows that good results can be achieved in selected patients. We propose a laparoscopic approach to perform the adrenalectomy in these patients.

Methods: A right laparoscopic adrenalectomy for metastasis from lung adenocarcinoma was performed. The right adrenal was resected using the anterior transperitoneal laparoscopic approach.

Results: The tumor was resected in total. The operating time was two hours. One year after surgery the patient remains well.

Conclusions: The current indications for laparoscopic adrenalectomy can include the removal of small metastatic adrenal lesions in selected cases.

Key Words: Adrenal gland neoplasms, Adrenalectomy, Lung neoplasms, Surgery, Laparoscopic.

University of Athens, Medical School.
[1]FACS, Associate Professor of Surgery, Department of Surgery, University of Athens, Medical School.
[2]Department of Surgery, University of Athens, Medical School.
[3]Department of Thoracic Surgery, Hygeia, Diagnostic and Therapeutic Center of Athens, University of Athens, Medical School.

Address reprint request to: Dimitrios Linos MD, 227 Kifissias Avenue, 14561, Kifissia, Greece. Telephone: ++ 301-6125001, Fax: ++ 301-6126170, E-mail: DLinos@hol.gr

INTRODUCTION

Adrenal metastases from lung cancer are a frequent event. They can be detected either during routine staging work-up of the disease or during follow-up after resection of the primary tumor. In both cases any surgical intervention is usually excluded, even if the lung cancer is well-controlled (i.e., stage T1-2 N0). However, a small number of cases of adrenalectomy for metastases from non-small cell lung carcinoma have been reported in the literature with good results.[1-8] We describe the first reported case of laparoscopic resection of a solitary adrenal metastasis from lung cancer.

CASE REPORT

A 69-year-old man, heavy smoker, had undergone a right lower lobectomy and mediastinal lymph node resection for adenocarcinoma of the lung of moderate differentiation, with negative for metastases lymph nodes (stage: T2 N0 M0). Eight months after the operation, during follow-up, computed tomography (CT) revealed a solitary mass in his right adrenal gland **(Figure 1)**. The patient had no complaints and his performance status was good. The findings from the physical examination were normal and his hemoglobin level was 13.8 g/dL. CT-guided fine needle aspiration biopsy of the adrenal lesion showed metastatic adenocarcinoma. No other metastases were detected with CT scan or radionuclide bone scan. A right laparoscopic adrenalectomy was attempted. We used the transperitoneal laparoscopic approach as described before.[9] With no particular difficulty, after ligation of the right adrenal vein, the tumor was resected in total. The operating time was 2 hours. The resected specimen weighed 80g and had a size of 7 x 5.5 x 5 cm. Microscopic examination confirmed metastatic adenocarcinoma originating from the lung.

Postoperatively the patient did well and was discharged on the third day. One year after surgery he remains well.

DISCUSSION

The adrenal gland is a frequent site of metastases from lung carcinoma. About one-third of patients dying of lung

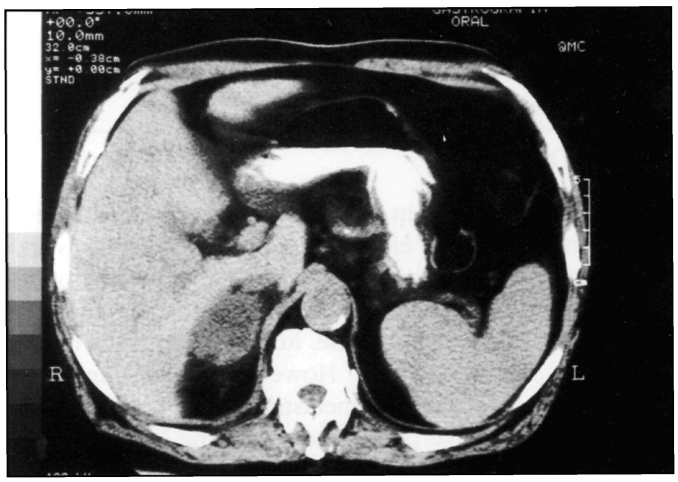

Figure 1. CT scan of the abdomen demonstrating right adrenal metastasis.

cancer have adrenal metastases at autopsy.[10] Preoperative staging with CT scan will reveal adrenal lesions in 7.5% of patients with non-small cell lung carcinoma.[11] A unilateral adrenal mass can be detected with CT scan in 4.1% of cases with otherwise operable lung cancer.[12] However, a needle biopsy is necessary in order to confirm the diagnosis of metastatic disease, since about two-thirds of the adrenal masses can be benign adenomas.[13]

Although patients with metastases from lung cancer are not candidates for surgery, a few cases of adrenalectomy for metastasis from non-small cell lung carcinoma have been reported in the literature.[1-8] Among 18 cases that have been recorded through 1995,[1-3, 6-8] eight deaths were reported. The median survival was 2 years. Seven patients (39%) were alive after 3 to 14 years (median: 5 years) of follow-up. In 1996, in a retrospective review of 14 patients with non-small cell lung carcinoma and a solitary adrenal metastasis who were managed with chemotherapy alone (n=6) or with chemotherapy followed by adrenalectomy (n=8), Luketich et al. reported a median survival of 8.5 months in the first group compared with 31 months in the second group (p=0.03).[5] In another study of 52 patients who underwent adrenalectomy for metastases from various primary tumor sites (including 11 cases with metastases from lung cancer), the 2-year survival rate was 40%. A significantly improved survival rate in patients with adrenal metastases due to adenocarcinoma compared with that in other histological types was recorded as well.[4] In spite of the small number of patients, all authors agree that resection of adrenal metastases in selected patients could be beneficial. Prerequisites for adrenalectomy that have been suggested are complete control of the primary tumor, no evidence of other metastases, and good performance status.[5,8]

We elected to proceed with laparoscopy in order to evaluate the peritoneal cavity for other metastases, assess local infiltration that would make an adrenalectomy impossible and above all, if the previous two evaluations were negative, to offer the patient the advantages of laparoscopic adrenalectomy.[9] Having succeeded to remove the metastatic adrenal tumor laparoscopically, without rupturing the capsule, with minimal hospital stay and minimal postoperative pain and disability, we suggest that the current indications for laparoscopic adrenalectomy can include the removal of small metastatic adrenal lesions in selected cases.

References:

1. Ayabe H, Tsuji H, Hara S, Tagawa Y, Kawahara K, Tomita M. Surgical management of adrenal metastasis from bronchogenic carcinoma. *J Surg Oncol.* 1995;58:149-154.

2. Higashiyama M, Doi O, Kodama K, Yokouchi H, Imaoka S, Koyama H. Surgical treatment of adrenal metastasis following pulmonary resection for lung cancer: comparison of adrenalectomy with palliative therapy. *Int Surg.* 1994;79:124-129.

3. Kirsch AJ, Oz MC, Stoopler M, Ginsburg M, Steinglass K. Operative management of adrenal metastases from lung carcinoma. *Urology.* 1993;42:716-719.

4. Lo CY, Van Heerden JA, Soreide JA, et al. Adrenalectomy for metastatic disease to the adrenal glands. *Br J Surg.* 1996;83:528-531.

5. Luketich JD, Burt ME. Does resection of adrenal metastases from non-small cell lung cancer improve survival? *Ann Thorac Surg.* 1996;62:1614-1616.

6. Raviv G, Klein E, Yellin A, Schneebaum S, Ben-Ari G. Surgical treatment of solitary adrenal metastases from lung carcinoma. *J Surg Oncol.* 1990;43:123-124.

7. Reyes L, Parvez Z, Nemoto T, Regal A-M, Takita H. Adrenalectomy for adrenal metastasis from lung carcinoma. *J Surg Oncol.* 1990;44:32-34.

8. Twomey P, Montgomery C, Clark O. Successful treatment of adrenal metastases from large-cell carcinoma of the lung. *JAMA.* 1982;248:581-583.

9. Linos DA, Stylopoulos N, Boukis M, Souvatzoglou A, Raptis S, Papadimitriou J. Anterior, posterior, or laparoscopic approach for the management of adrenal diseases? *Am J Surg.* 1997;173:120-125.

10. Allard P, Yankaskas BC, Fletcher RH, Parker A, Halvorsen RA. Sensitivity and specificity of computed tomography for the detection of adrenal metastatic lesions among 91 autopsied lung cancer patients. *Cancer.* 1990;66:457-462.

11. Salvatierra A, Baamonde C, Llamas JM, Cruz F, Lopez-Pujol J. Extrathoracic staging of bronchogenic carcinoma. *Chest.* 1990;97:1052-1058.

12. Ettinghausen SE, Burt ME. Prospective evaluation of unilateral adrenal masses in patients with operable non-small-cell lung cancer. *J Clin Oncol.* 1991;9:1462-1466.

13. Oliver TW, Bernardino ME, Miller JI, Mansour K, Greene D, Davis WA. Isolated adrenal masses in nonsmall-cell bronchogenic carcinoma. *Radiology.* 1984;153:217-218.