

## Quantification of Colloid Bodies in Oral Lichen Planus and Oral Lichenoid Reaction - A Histochemical Study

Hitesh Vij<sup>1</sup>, Ruchiika Vij<sup>1</sup>, Nirmala N Rao<sup>2</sup>, Raghu Radhakrishnan<sup>3</sup>, Vineeta Gupta<sup>4</sup>

<sup>1</sup> Senior Lecturer. Dept. of Oral Pathology & Microbiology. Institute of Dental Studies & Technologies, Modinagar, Uttar Pradesh, India.

<sup>2</sup> Professor. Dept. of Oral Pathology & Microbiology. Manipal College of Dental Sciences, Manipal, Karnataka, India.

<sup>3</sup> Professor and Head. Dept. of Oral Pathology & Microbiology. Manipal College of Dental Sciences, Manipal, India.

<sup>4</sup> Professor. Dept. of Oral Pathology & Microbiology. Institute of Dental Studies & Technologies, Modinagar, Uttar Pradesh, India.

*Correspondence:*

40 A/3 Ashok Nagar,

New Delhi-110018.

Email – ruchiika@gmail.com

Received: 01/12/2010

Accepted: 11/02/2011

Vij H, Vij R, Rao NN, Radhakrishnan R, Gupta V. Quantification of Colloid Bodies in Oral Lichen Planus and Oral Lichenoid Reaction - A Histochemical Study. J Clin Exp Dent. 2011;3(3):e207-11.  
<http://www.medicinaoral.com/odo/volumenes/v3i3/jcedv3i3p207.pdf>

Article Number: 50446 <http://www.medicinaoral.com/odo/indice.htm>  
© Medicina Oral S. L. C.I.F. B 96689336 - eISSN: 1989-5488  
eMail: [jced@jced.es](mailto:jced@jced.es)

### Abstract

**Aim:** Oral lichen planus and oral lichenoid reaction are familiar keratotic lesions found on the oral mucosa. Colloid bodies can be microscopically appreciated in both these lesions. The aim of this study was to identify as well as examine the frequency of colloid bodies in oral lichen planus and oral lichenoid reaction by histochemical means.

**Method:** The material for the study included 12 formalin-fixed paraffin-embedded tissue blocks (7 oral lichen planus and 5 oral lichenoid reaction), retrieved from the Department of Oral Pathology and Microbiology, MCOADS, Manipal. Sections stained with hematoxylin-eosin (H&E) and periodic acid-Schiff (PAS) with diastase to identify, locate and examine the frequency of colloid bodies in oral lichen planus and oral lichenoid reaction.

**Results:** It was observed that the colloid bodies in case of oral lichen planus were present in either epithelium or connective tissue but usually close to the epithelium-connective tissue junction. While in oral lichenoid reaction colloid bodies were mostly seen in lower spinous layer of epithelium.

**Conclusion:** Colloid bodies can be used as one of the criteria to differentiate oral lichen planus from oral lichenoid reaction. However, further studies are required to permit more objective distinction between oral lichen planus and oral lichenoid reaction.

**Key Words:** Apoptosis, civatte bodies, colloid bodies, oral lichen planus, oral lichenoid reaction.

## Introduction

Lichen planus is the most common dermatological disease with oral manifestations and oral lichen planus (OLP) is one of the frequently encountered mucosal conditions. It is an immunologically based, chronic inflammatory mucocutaneous disorder of undetermined etiology (1). It is a subacute or chronic dermatosis that may involve skin, mucous membranes, hair follicles and nails (2). Although first described by Erasmus Wilson (3), the etiology still remains obscure. Clinical and immunohistochemical studies strongly support an immunologic basis for the disease. The two most important histological features of OLP are the subepithelial band like inflammatory infiltrate predominated by lymphocytes and destruction of epithelial basal cell layer (4).

Oral lichen includes oral lichen planus and oral lichenoid reaction (OLR), and is known to affect about 2% of the population (1). OLR mainly constitute adverse contact reactions to foreign materials in the oral cavity while changes with unknown etiology are termed OLP. OLRs are clinically similar to OLP. The term OLP is considered to represent those lesions which generally appear bilaterally except few cases of unilateral presentation and where no trigger can be identified, thus are idiopathic whereas lichenoid reactions are those that are unilateral and associated with drug intake, systemic disease, food or flavor allergies, hypertension or diabetes mellitus (5,6).

An important histological feature of both these conditions is the presence of degenerating cells referred to as apoptotic bodies. Apoptosis is a well controlled form of cell death and this tightly regulated mechanism may be the contributing cause of basal cell destruction in OLP (7,8). Based on electron microscopic studies, previous investigators have described the colloid or Civatte bodies to be typical of apoptotic cells (9,10). In the present study an attempt was made to identify, locate and examine the frequency of the colloid bodies in OLP and OLR by employing PAS with diastase stain as well as to ascertain if these parameters can help to differentiate the two lesions. It is essential to make this distinction as the line of treatment for both the conditions varies.

## Materials and Method

The material for the study included 12 formalin fixed paraffin embedded tissue blocks retrieved from archives of department of Oral pathology and Microbiology, MCOOS, Manipal. These were divided into two groups. Group I consisted of 7 clinically and histologically diagnosed cases of OLP and Group II included 5 clinically and histologically diagnosed cases of OLR.

H&E stained sections along with the clinical presentation were used to reconfirm the diagnosis of OLP and OLR using the following criteria (11-14):

OLP:

- Bilateral presentation
- Well-defined subepithelial band of chronic inflammatory infiltrate composed predominantly of lymphocytes
- Liquefactive degeneration of the basal cell layer
- Absence of eosinophils and neutrophils

OLR:

- Unilateral presentation
- Poorly differentiated lower border of the subepithelial inflammatory infiltrate zone
- Presence of a substantial number of plasma cells in the lymphocytic infiltrate
- Perivascular infiltrate
- Increased number of colloid bodies
- Presence of acute inflammatory cells, such as eosinophils and neutrophils

Sections were prepared from each of the tissue blocks and stained using PAS with diastase. Further both the H&E and PAS with diastase stained slides were used to identify, locate and examine the frequency of colloid bodies in OLP and OLR. In addition the intensity, nature and distribution of inflammatory cell infiltrate was also examined.

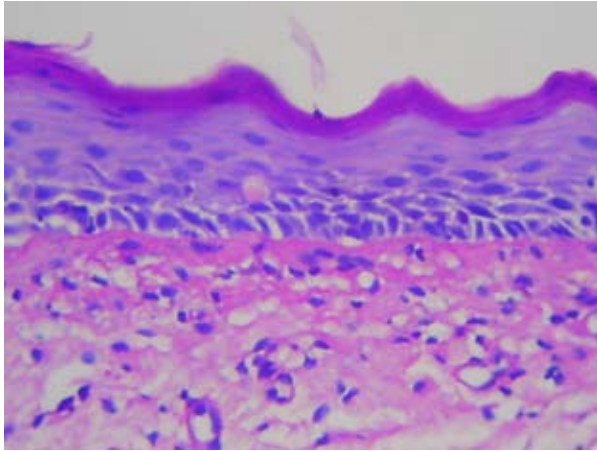
The frequency of colloid bodies was evaluated in both the lesions along with the location of the colloid bodies i.e. they are present either in the epithelium (basal, parabasal or spinous layer region) or in the connective tissue.

In addition it was also assessed if the intensity, nature and distribution of inflammatory cell infiltrate were associated with the number and location of the colloid bodies.

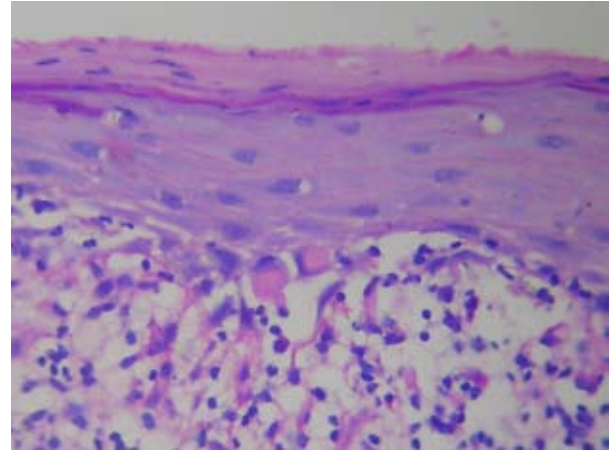
To eliminate the subjective bias, 2 observers independently evaluated all the slides. Statistical analysis was done using SPSS version 14 (Statistical Package for Social Sciences, Chicago, Illinois, USA) and the findings obtained by the two observers were subjected to Kendall's tau-b test. The p value thus obtained was found to be non-significant and hence the observations made by only one observer were considered for further statistical analysis.

## Results

In the present study, sections from both the groups (I and II) were analyzed with respect to their clinical and histopathological features. It was observed that the colloid bodies in case of OLP were present in either epithelium or connective tissue but usually close to the epithelium-connective tissue junction. This implies that even when colloid bodies were present in epithelium they were seen in basal or para-basal layers (Fig. 1,2). While in OLR colloid bodies were mostly seen in lower spinous layer of epithelium (Fig. 3). One of the slides of OLR showed colloid bodies close to the epithelium-connective tissue junction (Table 1).



**Fig. 1.** Civatte body in basal layer in OLP {PAS after diastase treatment (X40)}



**Fig. 2.** Colloid bodies in connective tissue in OLP {PAS after diastase treatment (X40)}

It was also observed that the number of colloid bodies increased with an increase in the degree of inflammation in slide of both OLP as well as OLR. The inflammatory infiltrate in OLP was chiefly of lymphocytes and was seen sub-epithelially. OLR in addition to lymphocytes exhibited plasma cells, mast cells and eosinophils, and the inflammatory cell infiltrate was seen not only sub-epithelially but also in deeper portions of connective tis-

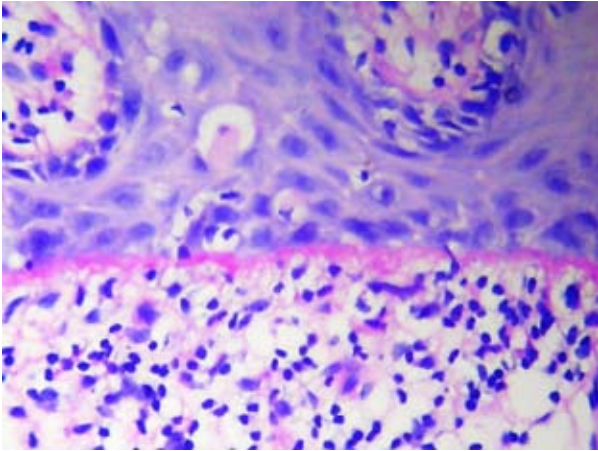
sue though the density of the same was relatively more sub-epithelially (Table 1).

Chi-Square test was applied to compare the results of number of colloid bodies in epithelium and connective tissue in cases of OLP and OLR. Comparison of number of colloid bodies in epithelium gave a non significant p value (0.632) whereas comparison of the same in connective tissue yielded a significant p value of 0.032.

S.no.	Colloid bodies			Inflammatory infiltrate		
	Number	Location	Adjacent break in basment membrane	Intensity	Level	Nature (type of cells)
<b>ORAL LICHEN PLANUS (Group-I)</b>						
1	3 1	c.t. epi. (b)	-	Mild	U	L
2	3 1	epi. (pb) epi. (b)	-	Moderate	U	L
3	4 5	c.t. epi. (b)	present in 2 areas	Moderate	U	L
4	4	c.t.	-	Moderate	U	L
5	3+3 2	epi. (b+pb) c.t.	present in 1 area	Intense	U	L
6	3 2	c.t. epi. (pb)	-	Intense	U	L
7	3 3	c.t. epi. (b)	present in 1 area	Moderate	U	L
<b>ORAL LICHENOID REACTION (group-II)</b>						
8	4	epi. (spinous)	-	Intense	U+Lo	L,P,M
9	1 2 1	c.t. epi. (b) epi. (spinous)	-	Moderate	U+Lo	L,P,E,M
10	1	epi. (spinous)	-	Mild	U	L
11	4 2	epi. (spinous) epi. (b)	-	Moderate	U+Lo	L,P,Ac.
12	4	epi. (spinous)	-	Moderate	U+Lo	L,P,E,M

c.t. – connective tissue, epi. – epithelium, b – basal, pb - para basal, U – Upper, Lo – Lower, L – lymphocytes, P – plasma cells, E – eosinophils, M - macrophage, Ac.- Acute

**Table 1.** Data showing colloid bodies and inflammatory infiltrate in OLP and OLR



**Fig. 3.** Civatte body in spinous layer in OLR {PAS after diastase treatment (X40)}

### Discussion

OLP is thought to be an immunologically mediated disorder and most studies of lichen planus have centered on the immunopathologic nature of the disease. In these studies the different cell populations of the lymphocytic infiltrate and how their cytokines may be involved in the disease process have been investigated. The present study was undertaken, first, to locate and examine the frequency of colloid bodies in the OLP and correlate them with intensity, type and distribution of inflammatory cell infiltrate and second, to correlate the above features with those of OLR. Further an attempt was made to see if these criteria can be used to set apart the two lesions under consideration.

In OLP, basal epithelial cells undergo apoptotic change, a process traditionally termed liquefaction degeneration. Apoptosis or physiologic cell death is a process of genetically programmed cell death by which senescent, DNA damaged and diseased cells are eliminated from the body (15). Apoptotic bodies may sometimes be totally cytoplasmic, existing as small shrunken cells or hyaline residues (9). Previous investigators have described the colloid or civatte bodies to be typical of apoptotic cells (9,10).

These bodies have been variously termed cytoid, hyaline, colloid or cytoid bodies. Their formation and transport was initially described by Sabouraud (16). These hyaline bodies are rounded, homogenous, eosinophilic bodies which may be found in the deeper parts of epithelium and more frequently in connective tissue. They are known as civatte bodies (in epithelium), colloid bodies (in connective tissue) and preferably-hyaline bodies. They are 10-25  $\mu\text{m}$  in size and situated mostly within or above the inflammatory cell infiltrate typical of this condition. Ultrastructurally these bodies have been described as fibrillar and their fibrillar ultrastructure indicates a tonofilament origin. Electron microscopy has confirmed that they are derived from cytoplasm of degene-

rated basal cells. These bodies give a positive periodic-acid Schiff reaction and are diastase resistant (17).

In the present study, the colloid bodies in cases of OLP were seen both in epithelium and connective tissue. This was in consistent with study of Neppelberg et al. (4) in which they found that apoptotic cells were most often seen in basal region intraepithelially or in inflammatory infiltrate subepithelially. They also noticed more apoptotic cells intraepithelially in areas with basal cell destruction.

However, in the cases of OLR most of colloid bodies were seen in lower and higher spinous layers which is in accordance with results of Van Den Haute et al. (18). They reported that cytoid bodies are situated higher in granular and cornified layers. they also observed presence of few eosinophils, exocytosis of lymphoid cells into upper epidermis and deeper perivascular infiltrate. These findings were also observed in our cases.

In our study more colloid bodies were seen in cases of OLP in which there was dense lymphocytic transgression of epithelial-connective tissue junction than in case in which lymphocyte were beneath the basal layer. These findings are in accord with generally held view of a causal role for lymphocytes and their cytokines in the induction of epithelial apoptosis. These findings were also observed in cases of OLR.

It should be recalled that apoptosis is a relatively brief event, lasting only 2 to 3 hours in vivo, when the third dimension is also taken into account the rate of apoptosis per square millimeter of epithelium could in fact be high. Moreover, apoptosis does not occur synchronously throughout a tissue, one would not expect to see many cells undergoing apoptosis at any given time. Thus, number of apoptosis (colloid bodies) in single sections may belie their significance in the disease process (9,19).

Thus in the present study, we observed with increase in density of inflammatory cells particularly of lymphocytes, the number of colloid bodies also increased. Also, the number of colloid bodies was more in cases of OLP than in cases of OLRs. Hence colloid bodies can be used as one of the criteria to differentiate OLP and OLR. However, further studies with a larger sample size and definitive immunohistochemical markers are required to permit more objective distinction between OLP and OLR.

### References

1. Huber MA. Oral lichen planus. *Quintessence Int.* 2004;35:731-52.
2. Scully C, el-Kom M. Lichen planus: review and update on pathogenesis. *J Oral Pathol.* 1985;14:431-58.
3. Wilson E. On Leichen Planus. *J Cutan Med Dis Skin.* 1869;3:117. Quoted in: Scully C, el-Kom M. Lichen planus: review and update on pathogenesis. *J Oral Pathol.* 1985;14:431-58.
4. Neppelberg E, Johannessen AC, Jonsson R. Apoptosis in oral lichen planus. *Eur J Oral Sci.* 2001;109:361-4.
5. Rogers RS 3rd, Bruce AJ. Lichenoid contact stomatitis: is inorganic mercury the culprit? *Arch Dermatol.* 2004;140:1434-8.
6. Segura-Egea JJ, Bullón-Fernández P. Lichenoid reaction asso-

- ciated to amalgam restoration. *Med Oral Patol Oral Cir Bucal*. 2004;9:423-4; 421-3.
7. Wyllie AH, Kerr JFR, Currie AR. Cell death: the significance of apoptosis. *Int Rev Cytol*. 1980;68:251-306.
  8. Cohen JJ. Apoptosis. *Immunol Today*. 1993;14:126-30.
  9. Kerr JFR, Wyllie AH, Currie AR. Apoptosis: a basic biological phenomenon with wide ranging implications in tissue kinetics. *Br J Cancer* 1972;26:239-57.
  10. Weedon D. Letter: Civatte bodies and apoptosis. *Br J Dermatol* 1974;91:357.
  11. McCartan BE, McCreary CE. Oral lichenoid drug eruptions. *Oral Dis*. 1997;3:58-63.
  12. McCartan BE, Lamey PJ. Expression of CD1 and HLA-DR by Langerhans cells (LC) in oral lichenoid drug eruptions (LDE) and idiopathic oral lichen planus (LP). *J Oral Pathol Med*. 1997;26:176-80.
  13. McCartan BE, Lamey P. Lichen planus--specific antigen in oral lichen planus and oral lichenoid drug eruptions. *Oral Surg Oral Med Oral Pathol Oral Radiol Endod*. 2000;89:585-7.
  14. McCartan BE, McCreary CE, Healy CM. Studies of drug-induced lichenoid reactions: criteria for case selection. *Oral Dis*. 2003;9:163-4.
  15. Bursch W, Kleine L, Tenniswood M. The biochemistry of cell death by apoptosis. *Biochem Cell Biol*. 1990;68:1071-4.
  16. Sabouraud R. Sur quelques points de l'anatomie pathologique du lichen plan de Wilson. *Annl Derm Syph*. 1910;1:491-505. Quoted in: Griffin CJ, Jolly M, Smythe JD. The fine structure of epithelial cells in normal and pathological buccal mucosa. II. Colloid body formation. *Aust Dent J*. 1980;25:12-9.
  17. Ebner H, Gebhart W. Light and electron microscopic differentiation of amyloid and colloid or hyaline bodies. *Br J Dermatol*. 1975;92:637-45.
  18. Van Den Haute V, Antoine JL, Lachapelle JM. Histopathological discriminant criteria between lichenoid drug eruption and idiopathic lichen planus: retrospective study on selected samples. *Dermatologica*. 1989;179:10-3.
  19. Bloor BK, Malik FK, Odell EW, Morgan PR. Quantitative assessment of apoptosis in oral lichen planus. *Oral Surg Oral Med Oral Pathol Oral Radiol Endod*. 1999;88:187-95.