

# Investigation of the effects of Enoxaparin, Fondaparinux, and Rivaroxaban used in thromboembolism prophylaxis on fracture healing in rats

A. DEMIRTAS, I. AZBOY, M. BULUT, B.Y. UCAR, U. ALABALIK<sup>1</sup>, N.S. NECMIOGLU

Department of Orthopaedics and <sup>1</sup>Department of Pathology, Dicle University Medical Faculty, Diyarbakir, Turkey

**Abstract.** – **BACKGROUND:** Today, there is a small number of studies on the effects of Enoxaparin and Fondaparinux used commonly in the prevention of venous thromboembolism on healing of fracture cases.

**AIM:** The aim of this study was to investigate clinically, radiologically and histopathologically, the effects of Enoxaparin, Fondaparinux and Rivaroxaban used in thromboembolism prophylaxis on fracture healing in a rat model of femur fracture.

**MATERIALS AND METHODS:** Thirty-two male Sprague Dawley rats were randomized into four groups (n=8): the control group (Group 1), the Enoxaparin group (Group 2), the Fondaparinux group (Group 3), and Rivaroxaban group (Group 4). Under general anesthesia, a standard closed fracture was created in the left femur of each rat using an osteotome. Group 1 was given saline solution (1 cc/day, sc), Group 2 Enoxaparin (100 anti Xa IU/kg/day, sc), Group 3 Fondaparinux (0.2 mg/kg/day, sc), and Group 4 Rivaroxaban (3 mg/kg/day, po) for 21 days. After all rats were sacrificed at the end of day 21, their left femurs were disarticulated at the level of the hip and knee. The bony union was radiologically, clinically, and histopathologically evaluated.

**RESULTS:** No differences were found between the groups in terms of clinical, radiological, and histopathological findings in fracture healing ( $p = 0.849$ ,  $p = 0.731$ , and  $p = 0.395$ , respectively).

**CONCLUSIONS:** Enoxaparin, Fondaparinux and Rivaroxaban used in thromboembolism prophylaxis cause no significant changes in fracture healing with short term follow up. Thus, they can be safely used in cases of fractures.

*Key Words:*

Thromboembolism, Fracture healing, Enoxaparin, Fondaparinux, Rivaroxaban.

of the musculoskeletal system and which can be a cause of mortality unless the necessary precautions are taken. Fracture cases that are common in orthopedic practice, particularly those operated on for fractures of the lower extremity, carry risk for the development of VTE. In patients undergoing hip fracture surgery who received no prophylaxis, the prevalence of total deep vein thrombosis has been reported to be 50-60%, that of fetal pulmonary embolism to be 4-12%, and that of total deep vein thrombosis in fractures of the lower extremity distal to the hip to be 28%<sup>1,2</sup>.

Today, there is a small number of studies on the effects of Enoxaparin and Fondaparinux used commonly in the prevention of VTE on healing of fracture cases. Our literature review revealed no reports on Rivaroxaban, a novel oral agent.

In the present study, we investigated clinically, radiologically and histopathologically the effects of prophylactic doses of Enoxaparin, Fondaparinux, and Rivaroxaban on fracture healing.

## Materials and Methods

A total of 32 male Sprague Dawley rats (weight: 230-262 g) were used. All procedures were carried out in Dicle University, Sabahattin Payzın Research Laboratory after the approval of the, Animal Experiments Local Ethics Committee, Dicle University, was obtained.

The rats used were randomized into four groups (n=8): the control group (Group 1), Enoxaparin group (Group 2), Fondaparinux group (Group 3), and Rivaroxaban group (Group 4). The rats were followed for 48 hours in the laboratory setting and were kept under the 12 hour light/12 hour dark cycle at 22°C. The rats were fed tap water and standard rodent feed *ad libitum*.

## Introduction

Venous thromboembolism (VTE) is an important complication that can occur due to injuries

All rats were operated on by the same surgeon on the same day. Prior to surgery, the rats were anaesthetized with a combination of 50 mg/kg of Ketamine (Ketalar®, Pfizer, Istanbul, Turkey) and 10 mg/kg of Xylazine (Rompun®, Bayer, Istanbul, Turkey). The surgical procedure followed the technique developed by Bonnarens and Einhorn<sup>3</sup>. Accordingly, the left knee of each rat was shaved and prepared with povidone iodine (Batticon, ADEKA, Istanbul, Turkey). A 2 cm longitudinal incision was made on the anteromedial surface, and the joint capsule was opened medial to the patella. The patella was moved laterally, the knee was flexed, and the femur condyles were exposed. 1 mm of Kirschner wire (Hipokrat®, Izmir, Turkey) was retrogradely inserted between the femur condyles into the intramedullary channel using an electric drill (Figure 1). The knee was brought to extension and the patella was reduced. The capsule was then sutured with 3/0 vicryl (Atramat®, Mexico City, Mexico). The skin was closed with 2/0 silk sutures (Sterisilk®, SSM Steril Sağlık Malzemeleri A.S., Istanbul, Turkey). Subsequently, the wound site was swabbed with povidone iodine. A standard closed femur fracture was created using an osteotome. The fracture was confirmed with the clinical examination and radiological evaluation (Figure 2). No antibiotic prophylaxis was administered during or after operation.

Group 1 was given 1 cc saline solution (I.E. Ulugay, Istanbul, Turkey) sc once daily, starting immediately after the operation. Group 2 was given 100 anti-Xa IU/kg of Enoxaparin (Clexan, Sanofi- Aventis, Istanbul, Turkey) sc once daily, starting 12 hours after the operation<sup>4</sup>. Group 3 was given 0.2 mg/kg of Fondaparinux (Arixtra,

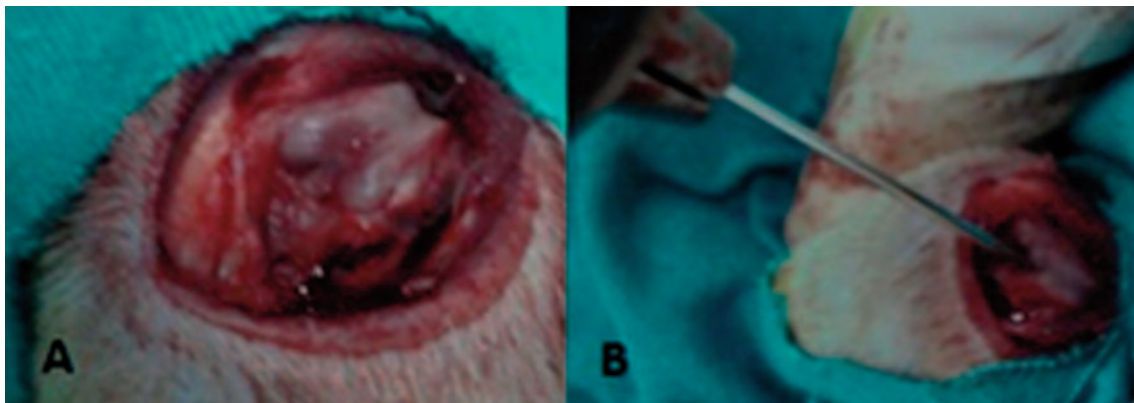
GlaxoSmithKline's, Istanbul, Turkey) sc once daily, starting 6 hours after the operation<sup>5,6</sup>. Group 4 was given 3 mg/kg of Rivaroxaban (Xarelto, Bayer, Istanbul, Turkey) once a day orally, starting 6 hours after the operation<sup>7</sup>. Drug administration was continued for 21 days. All rats were sacrificed by cervical dislocation at the end of day 21.

After the rats were sacrificed, their left femurs were disarticulated at the level of the hip and knee. All soft tissues on the femur surface were carefully excluded without damaging the callus tissue. All left femurs were clinically, radiologically, and histopathologically evaluated.

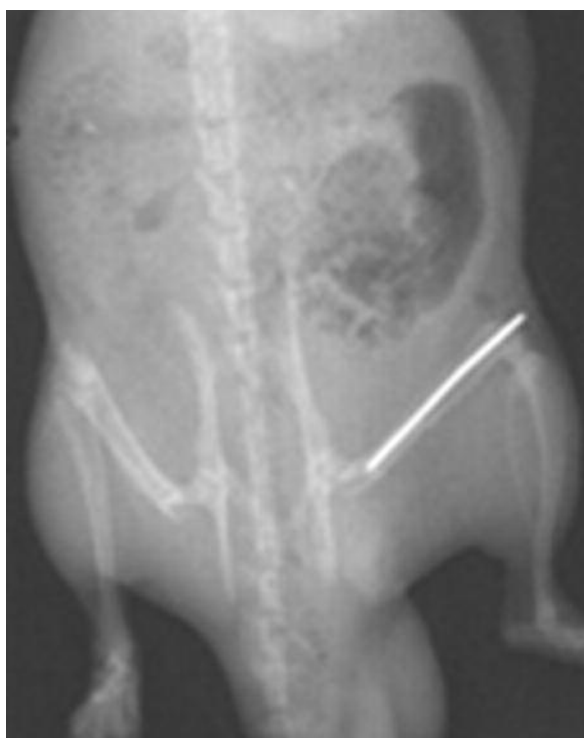The clinical findings were evaluated using the scoring system developed by Akman et al<sup>8</sup>. According to the scoring system, in which pathological mobility is evaluated subjectively by two independent orthopedists: no mobility in two planes (antero-posterior/lateral) in the fracture line presents complete fusion (scores 2), mobility in one plane presents moderate fusion (score 1), mobility in both planes presents no fusion (score 0).

The radiological findings were evaluated by two independent orthopedists using the scoring system developed by Lane et al (0 = no healing, 1 = callus formation, 2 = onset of bony union, 3 = starting disappearing fracture line, 4 = complete bony union)<sup>9</sup>. For this purpose, antero-posterior (AP) and lateral radiographs of the left femur of each rat were obtained. After the findings of AP and lateral radiographs were separately scored, the total score was divided in two and the score was calculated for each rat.

For histopathological evaluation, all femurs were fixed in 10% formalin solution for 3 days.



**Figure 1.** Exposure of rat femur condyles and retrograde placement of the Kirschner wire. **A**, Exposure of femoral condyles. **B**, Retrograde placement of the Kirschner wire into the intramedullary channel.



**Figure 2.** Radiological image of rat femur fracture.

Then, the bones were decalcified in 10% nitric acid. Three sections were taken from the fracture line of each femur. Subsequently, 4 micron-sections were prepared from parafin-embedded tissues. The sections were stained with hematoxylin eosin and were evaluated by a pathologist according to the histological healing scale published by Huo et al (Table I)<sup>10</sup>.

**Table I.** Scoring system for the histological evaluation of fracture healing.

Score	Histological findings
1	Fibrous tissue
2	Predominantly fibrous tissue with little cartilage tissue
3	Equal amounts of fibrous and cartilage tissue
4	Only cartilage tissue
5	Predominantly cartilage tissue with little immature (woven) bone
6	Equal amounts of cartilage and immature bone tissue
7	Predominantly immature bone with little cartilage tissue
8	Healing with immature (woven) bone
9	Immature bone with little mature bone
10	Healing with mature (lamellar) bone

### Statistical Analysis

All data were recorded and analyzed using SPSS v 15.0 (SPSS Inc., Chicago, IL, USA). The Kruskal Wallis test was used for comparison between the groups. A  $p$  value of less than 0.05 was considered statistically significant.

## Results

### Clinical Findings

According to the clinical findings, the control group had a mean score of 1.87; the Enoxaparin group had a mean score of 1.62; the Fondaparinux group had a mean score of 1.75; and the Rivaroxaban group had a mean score of 1.62. No statistically significant differences were noted in fracture healing between the groups in terms of clinical findings ( $p = 0.849$ ).

### Radiological Findings

Radiologically, findings of union were found in all groups (Figure 3). According to the radiological findings, the control group had a mean score of 2.87; the Enoxaparin group had a mean score of 2.75; the Fondaparinux group had a mean score of 2.75; and the Rivaroxaban group had a mean score of 2.62. In terms of radiological findings, no statistically significant difference was found between the groups in fracture healing ( $p = 0.731$ ).

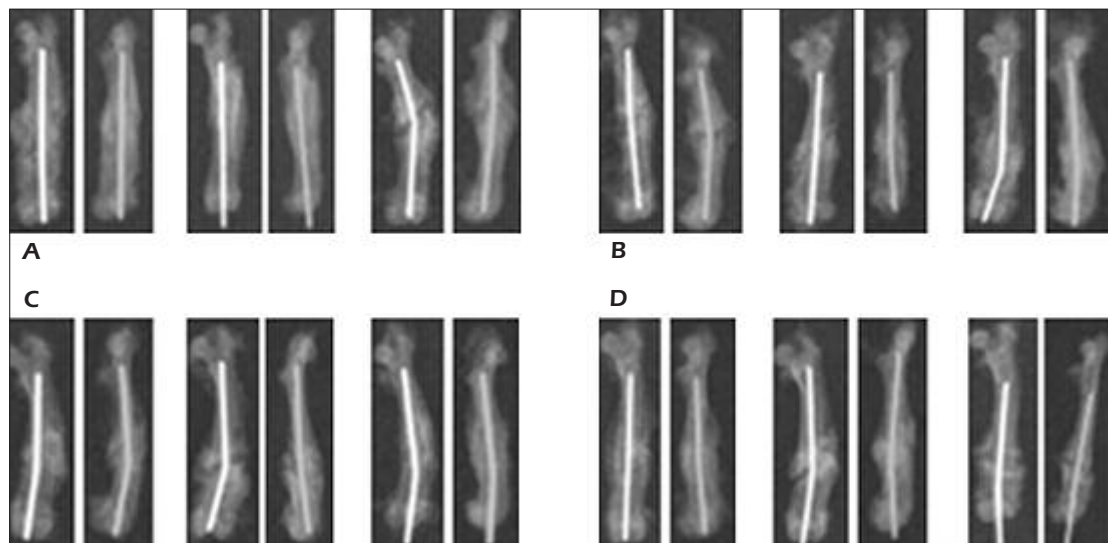
### Histopathological Findings

Histopathologically, findings of union were found in all groups (Figure 4). According to the histopathological findings; the control group had a mean score of 7.5; the Enoxaparin group had a mean score of 6.75; the Fondaparinux group had a mean score of 7.37; and the Rivaroxaban group had a mean score of 6.87. In terms of histopathological findings, there was no statistically significant difference between the groups in fracture healing ( $p = 0.395$ ).

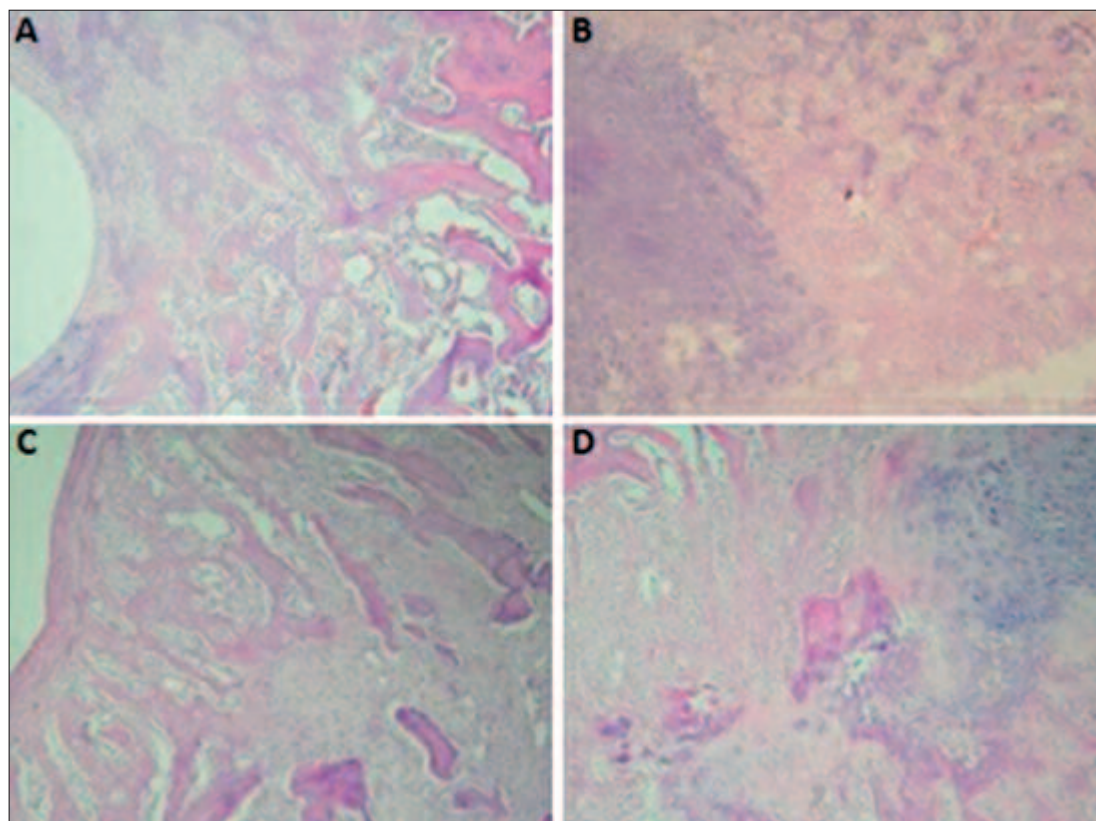
## Discussion

Fracture healing is a dynamic process that is composed of stages of inflammation, repair, and remodeling and governed by cellular and biochemical agents. A number of factors have been reported to have an effect on this process<sup>11,12</sup>.

Despite the studies on the pharmacokinetic and pharmacodynamic effects of the drugs used



**Figure 3.** *A, B*, AP and lateral X-ray images of femoral fracture samples of the control and experimental groups at the end of the experiment. (Samples of the *A*, Control group. *B*, Enoxaparin group. *C*, Fondaparinux group. *D*, Rivaroxaban group).



**Figure 4.** Histopathological images of femoral fracture samples from the rats in the control and experimental groups at the end of the experiment. *A*, An image of stage 9 callus tissue in the fracture line in a rat from the control group, H&E,  $\times 100$ . *B*, An image of stage 6 callus tissue in the fracture line in a rat from the Enoxaparin group, H&E,  $\times 100$ . *C*, An image of stage 9 callus tissue in the fracture line in a rat from the Fondaparinux group, H&E,  $\times 100$ . *D*, An image of stage 7 callus tissue in the fracture line in a rat from the Rivaroxaban group, H&E,  $\times 100$ .

for VTE prophylaxis, their effects on fracture healing remain to be elucidated.

Low-dose standard heparin, one of the first agents used for thromboembolism prophylaxis, enhances the binding of anti-thrombin to thrombin and acts through the inhibition of factor Xa. Several studies have reported that standard heparin causes osteoporosis by decreasing the rate of bone formation and increasing the rate of bone resorption. The use of heparin has been limited because of its adverse effects, such as thrombocytopenia, and the need for monitoring of coagulation parameters, besides its leading to osteoporosis<sup>13-19</sup>.

Low molecular weight heparins (LMWHs) can not bind to thrombin efficiently and exert their main effect through the inhibition of factor Xa. LMWHs are associated with a lower risk of thrombocytopenia compared to standard heparin and do not require monitoring of coagulation parameters. Most studies on LMWHs have reported adverse effects on the bone cycle; however, there are other studies suggesting the opposite<sup>19-22</sup>.

Casele and Laifer<sup>23</sup> evaluated changes in bone density in 16 women receiving Enoxaparin sodium during pregnancy with measurements taken within 2 weeks of starting therapy, at 6-8 weeks postpartum, and 6 months postpartum. In patients who received Enoxaparin sodium for a mean duration of 25 weeks, no significant change was noted in mean bone density from baseline measurements to measurements at 6 weeks postpartum. The measurements at 6 months postpartum revealed a significant decrease in bone density and 14% of the patients experienced a bone loss of more than 10%.

In a cell culture study, Kock and Handschin<sup>24</sup> investigated the effects of four different LMWHs (nadroparin, Enoxaparin, dalteparin, certoparin) on osteoblast growth, finding that LMWHs in four different groups inhibited osteoblast growth. They concluded that the risk of osteoporosis could not be excluded in patients receiving long-term therapy.

Hurley et al<sup>25</sup> analyzed the effects of LMWHs on collagen synthesis in 21-day fetal rat calvariae and suggested that different LMWHs were as inhibitory as standard heparin on collagen synthesis. Thus, they concluded that LMWHs offered no further protection against heparin-induced osteoporosis.

In a study evaluating the effect of dalteparin on fracture healing by Hak et al<sup>26</sup>, a stabilized femur fracture was created in rats and radiological, histological, and mechanical properties of the rats treated for two weeks were compared at weeks 2, 3,

and 6. No statistically significant difference was noted in the dalteparin group when compared to the control group in terms of fracture healing. In this investigation, no significant delay was found in fracture healing in Enoxaparin-treated rats compared to the control group. We have attributed this finding to the short duration of the experiment and the prophylactic doses used. Considering the report by Casele and Laifer<sup>23</sup> and Kock and Handschin<sup>24</sup>, and in the light of the current literature, we consider that long-term use of LMWHs at therapeutic doses leads to osteoporosis.

Fondaparinux is a synthetic and selective inhibitor of Factor Xa. Fondaparinux does not inactivate thrombin and has no effect on platelet function, and does not require monitoring of coagulation parameters<sup>27</sup>. Despite the limited number of studies on Fondaparinux, no adverse effects on the bone cycle have been reported<sup>28</sup>.

In a study by Matziolis et al<sup>29</sup>, the effects of dalteparin, Enoxaparin, standard heparin and Fondaparinux on human osteoblasts were examined. As a result, it was found that mitochondrial activity and protein synthesis of osteoblasts treated with Fondaparinux were significantly higher than in the other groups. Similar effects were demonstrated for the matrix collagen type 2 content and calcification. Within the concentration range investigated (0.01-100 microg/ml), Fondaparinux was found to have no inhibitory effects on human osteoblasts and it was suggested that Fondaparinux could be used to prevent heparin-induced negative effects on fracture healing and implant integration.

A study by Handschin et al<sup>30</sup> investigated the effects of Fondaparinux and dalteparin, a LMWH, on human osteoblasts *in vitro*. It was found that incubation with dalteparin led to a dose-dependent inhibition of osteoblast proliferation, protein synthesis and phenotype markers such as osteocalcin and alkaline phosphatase genes. No inhibitory effect was observed in the cells treated with Fondaparinux.

Hawkins and Evans<sup>31</sup> reported that Fondaparinux was safer and more effective compared to LMWHs and standard heparin in pregnant women who received long term antithrombotic therapy and that osteoporosis could be decreased with the use of Fondaparinux instead of heparin during pregnancy. In this study, there was no significant delay in fracture healing in Fondaparinux-treated rats compared to the control or other experimental groups. These findings are consistent with the studies in the literature, indicating

that Fondaparinux has no negative effects on fracture healing. However, in this research, the absence of a significant difference between Fondaparinux and Enoxaparin in fracture healing is not consistent with the literature; this might have been caused by negative effects of LMWHs on the bone metabolism in a dose-dependent manner, as reported in the study by Handschin et al<sup>30</sup>.

Rivaroxaban, a novel oral agent, is a direct inhibitor of factor Xa. Rivaroxaban can be administered orally at a stable dose and does not require monitoring of coagulation parameters<sup>32,33</sup>. There are studies reporting that Rivaroxaban is superior to Enoxaparin in the prevention of VTE in patients undergoing total hip and knee arthroplasty, though there are other studies indicating similar effects for both<sup>33,34</sup>. There are no reports in the literature addressing the effects of Rivaroxaban on fracture healing.

In this investigation, no significant delay was found in fracture healing in Rivaroxaban-treated rats compared to the control and other experimental groups. We consider that Rivaroxaban can be used as an alternative to other anti-thrombotic agents due to its ability to be used orally and no requirement for monitoring, thus, considerably facilitating patient compliance.

## Conclusions

Antithrombotic agents, Enoxaparin, Fondaparinux, and Rivaroxaban, when used at prophylactic doses, cause no significant changes in fracture healing with short-term follow up in terms of clinical, radiological, and histopathological aspects. Thus, they can be safely used in fracture cases which require thromboembolism prophylaxis. Further researches with short and long-term follow up with different doses investigating many parameters that together affect the bone cycle could provide more precise information about the effects of these agents on fracture healing.

## Conflict of Interest

None declared.

## References

- 1) GEERTS WH, HEIT JA, CLAGETT GP, PINEO GF, COLWELL CW, ANDERSON FA JR, WHEELER HB. Prevention of venous thromboembolism. *Chest* 2001; 119: 132S-175S.
- 2) ERIKSSON BI, LASSEN MR; PENTASACCHARIDE IN HIP-FRACTURE SURGERY PLUS INVESTIGATORS. Duration of prophylaxis against venous thromboembolism with Fondaparinux after hip fracture surgery: a multicenter, randomized, placebo-controlled, double-blind study. *Arch Intern Med* 2003; 163: 1337-1342.
- 3) BONNARENS F, EINHORN TA. Production of a standard closed fracture in laboratory animal bone. *J Orthop Res* 1984; 2: 97-101.
- 4) FOLWARCZNA J, JANIEC W, GAWOR M, PYTLIK M, KACZMARCZYK-SEDLAK I, NOWINSKA B. Effects of Enoxaparin on histomorphometric parameters of bones in rats. *Pol J Pharmacol* 2004; 56: 451-457.
- 5) SCHLITT A, BUERKE M, HAUROEDER B, PEETZ D, HUNDT F, BICKEL C, SCHAEFER I, MEYER J, RUPPRECHT HJ. Fondaparinux and Enoxaparin in comparison to unfractionated heparin in preventing thrombus formation on mechanical heart valves in an ex vivo rabbit model. *Thromb Haemost* 2003; 90: 245-251.
- 6) CHUNG LT, HOLTON HL, SILVERMAN PR. The effect of Fondaparinux versus Enoxaparin in the survival of a congested skin flap in a rabbit model. *Ann Plast Surg* 2006; 56: 312-315.
- 7) WEINZ C, SCHWARZ T, KUBITZA D, MUECK W, LANG D. Metabolism and excretion of Rivaroxaban, an oral, direct factor Xa inhibitor, in rats, dogs, and humans. *Drug Metab Dispos* 2009; 37: 1056-1064.
- 8) AKMAN S, GOU A, SENER N, BILGIC B, AKSOY B. Siçan tibia kırıkları sonrası uygulanan diklofenak-sodyum'un kırık kaynaması üzerine etkileri. *Hacettepe Ortopedi Dergisi* 2001; 11: 55-60.
- 9) LANE JM, SANDHU HS. Current approaches to experimental bone grafting. *Orthop Clin North Am* 1987; 18: 213-225.
- 10) HUO MH, TROIANO NW. The influence of ibuprofen on fracture repair: biomechanical, biochemical, histologic and histomorphometric parameters in rats. *J Orthop Res* 1991; 9: 383-390.
- 11) PHILLIPS AM. Overview of the fracture healing cascade. *Injury* 2005; 36: S5-S7.
- 12) BRINKER MR. Bone. In: *Fundamentals of Orthopaedics*. Philadelphia, PA: Saunders 1999; pp. 1-7.
- 13) DOUKETIS JD, GINSBERG JS, BURROWS RF, DUKU EK, WEBBER CE, BRILL-EDWARDS P. The effect of long-term heparin therapy during pregnancy on bone density. A prospective matched cohort study. *Thromb Haemost* 1996; 75: 254-257.
- 14) MONREAL M, VINAS L, MONREAL L, LAVIN S, LAFOZ E, ANGLES AM. Heparin related osteoporosis in rats. A comparative study between unfractionated heparin and a low-molecular weight heparin. *Haemostasis* 1990; 20: 204-207.
- 15) VON MANDACH U, AEBERSOLD F, HUCH R, HUCH A. Short-term low-dose heparin plus bedrest impairs bone metabolism in pregnant women. *Eur J Obstet Gynecol Reprod Biol* 2003; 106: 25-30.
- 16) CHIGOT P, DE GENNES C, SAMAMA MM. Osteoporosis induced either by unfractionated heparin or low molecular weight heparin. *J Mal Vasc* 1996; 21: 121-125.

- 17) SIMMONS HA, RAISZ LG. Effects of acid and basic fibroblast growth factor and heparin on resorption of cultured fetal rat long bones. *J Bone Miner Res* 1991; 6: 1301-1305.
- 18) BARBOUR LA, KICK SD, STEINER JF, LOVERDE ME, HEDDLESTON LN, LEAR JL, BARÓN AE, BARTON PL. A prospective study of heparin-induced osteoporosis in pregnancy using bone densitometry. *Am J Obstet Gynaecol* 1994; 170: 862-869.
- 19) SHAUGHNESSY SG, YOUNG E, DESCHAMPS P, HIRSH J. The effects of low molecular weight and standard heparin on calcium loss from fetal rat calvariae. *Blood* 1995; 86: 1368-1373.
- 20) MUIR JM, ANDREW M, HIRSH J, WEITZ JI, YOUNG E, DESCHAMPS P, SHAUGHNESSY SG. Histomorphometric analysis of the effects of standard heparin on trabecular bone *in vivo*. *Blood* 1996; 88: 1314-1320.
- 21) STREET JT, MCGRATH M, O'REGAN K, WAKAI A, MCGUINNESS A, REDMOND HP. Thromboprophylaxis using a low molecular weight heparin delays fracture repair. *Clin Orthop Relat Res* 2000; 381: 278-289.
- 22) PETTILA V, LEINONEN P, MARKKOLA A, HIILESMAA V, KAAJA R. Postpartum bone mineral density in women treated for thromboprophylaxis with unfractionated heparin or LMW heparin. *Thromb Haemost* 2002; 87: 182-186.
- 23) CASELE HL, LAIFER SA. Prospective evaluation of bone density in pregnant women receiving the low molecular weight heparin Enoxaparin sodium. *J Matern Fetal Med* 2000; 9: 122-125.
- 24) KOCK HJ, HANDSCHIN AE. Osteoblast growth inhibition by unfractionated heparin and by low molecular weight heparins: an *in-vitro* investigation. *Clin Appl Thromb Hemost* 2002; 8: 251-255.
- 25) HURLEY MM, KREAM BE, RAISZ LG. Structural determinants of the capacity of heparin to inhibit collagen synthesis in 21-day fetal rat calvariae. *J Bone Miner Res* 1990; 5: 1127-1133.
- 26) HAK DJ, STEWART RL, HAZELWOOD SJ. Effect of low molecular weight heparin on fracture healing in a stabilized rat femur fracture model. *J Orthop Res* 2006; 24: 645-652.
- 27) WALENGA MJ, JESKE PW, BARA L, SAMAMA MM, FAREED J. Biochemical and pharmacologic rationale for the development of a synthetic heparin pentasaccharide. *Thromb Res* 1997; 86: 1-36.
- 28) RAJGOPAL R, BEAR M, BUTCHER MK, SHAUGHNESSY SG. The effect of heparin and low molecular weight heparins on bone. *Thromb Res* 2008; 122: 293-298.
- 29) MATZIOLIS G, PERKA C, DISCH A, ZIPPEL H. Effects of Fondaparinux compared with dalteparin, Enoxaparin and unfractionated heparin on human osteoblasts. *Calcif Tissue Int* 2003; 73: 370-379.
- 30) HANDSCHIN AE, TRENTZ OA, HOERSTRUP SP, KOCK HJ, WANNER GA, TRENTZ O. Effect of low molecular weight heparin (dalteparin) and Fondaparinux (Arixtra) on human osteoblasts *in vitro*. *Br J Surg* 2005; 92: 177-183.
- 31) HAWKINS D, EVANS J. Minimising the risk of heparin-induced osteoporosis during pregnancy. *Expert Opin Drug Saf* 2005; 4: 583-590.
- 32) FUSARO M, CREPALDI G, MAGGI S, D'ANGELO A, CALO L, MIOZZO D, FORNASIERI A, GALLIENI M. Bleeding, vertebral fractures and vascular calcifications in patients treated with warfarin: hope for lower risks with alternative therapies. *Curr Vasc Pharmacol* 2011; 9: 763-769.
- 33) BORRIS LC. Rivaroxaban and dabigatran etexilate: two new oral anticoagulants for extended postoperative prevention of venous thromboembolism after elective total hip arthroplasty. *Arch Orthop Trauma Surg* 2010; 130: 583-589.
- 34) TURUN S, BANGHUA L, YUAN Y, ZHENHUI L, YING N, JIN C. A systematic review of Rivaroxaban versus Enoxaparin in the prevention of venous thromboembolism after hip or knee replacement. *Thromb Res* 2011; 127: 525-534.