

Endodontic Management of Taurodontism in Maxillary Molar: A Case Report

Yogesh R Sahu¹, Aditi Jain²

¹Reader, Department of Conservative Dentistry and Endodontics, Maitri Dental College and Research Centre, Durg, Chhattisgarh, India,

²Senior Lecturer, Department of Conservative Dentistry and Endodontics, Maitri Dental College and Research Centre, Durg, Chhattisgarh, India

Abstract

Taurodontism is a dental anomaly characterized by enlarged pulp chamber which may reach the proximity of root apex, apical displacement of the pulpal floor, and no constriction at the level of the cement-enamel junction. Despite the clinical challenges in endodontic therapy, taurodontism has received little attention from clinicians. In performing root canal treatment on such teeth, one should appreciate the complexity of the root canal system, canal obliteration and configuration, and the potential for additional root canal systems. This case report presents the taurodontism in tooth number 26 and 36. A conventional root canal treatment was carried out for these pulpally involved teeth.

Key words: Anomaly, Bull's tooth, Enlarged pulp chamber, Taurodontism

INTRODUCTION

Taurodontism is an anomaly of tooth which is characterized by enlarged pulp chamber, apical displacement of the pulpal floor, and lacks of constriction at the level of the cement-enamel junction (CEJ).

This anomaly was first reported in the remnants of prehistoric hominids by De Terra in 1903 and by Gorjanovic, Kramberger, and Aldoff in 1907, and in 1909 Pickeril¹ noted this in modern man. However, the term taurodontism (bull's tooth) was first coined by Sir Arthur Keith in 1913.²

The term taurodontism comes from "taoros" and "odontos," meaning bull's tooth (Keith, 1913; Terezhalmay *et al.*, 2001), a condition that has been found in ancients Neanderthals where the teeth resemble that of cud chewing animals.

It is seen in both the permanent and deciduous dentition, unilaterally or bilaterally although permanent molar teeth

are most commonly affected and infrequently in premolars also.³ While it appears most frequently as an isolated anomaly, its association with several syndromes such as hypophosphatasia or alteration of sex chromosomes such as Klinefelter's syndrome, Trisomy 21, or Down's syndrome.^{1,4}

Incidence, as shown by an Israel study, was 5.6 %. It was reported to be lower than 1% in modern man, 3% in primitives, Eskimos, and American Indians.⁵ This retrograde or atavistic feature is because of its decrease in its incidence.

Despite the clinical challenges in endodontic therapy, taurodontism has received little attention from clinicians. In performing root canal treatment on such teeth, one should appreciate the complexity of the root canal system, canal obliteration and configuration, and the potential for additional root canal systems. Careful exploration of the grooves between all orifices particularly with magnification, use of ultrasonic irrigation, and a modified filling technique are of particular use.

Taurodontism in endodontic aspect presents challenge in non-surgical root canal therapy during negotiation, instrumentation, and obturation of the root canals.

This paper describes two case reports of the conventional endodontic treatment carried out with taurodontic teeth.

Access this article online



www.ijss-sn.com

Month of Submission : 06-2016
Month of Peer Review : 07-2016
Month of Acceptance : 08-2016
Month of Publishing : 08-2016

Corresponding Author: Dr. Aditi Jain, Department of Conservative Dentistry and Endodontics, Maitri College of Dentistry and Research Centre, Anjora, Durg - 491 001, Chhattisgarh, India. E-mail: aditijain300789@gmail.com

CASE REPORTS

Case 1

A 24-year-old male patient reported to the Department of Conservative Dentistry and Endodontics, YMT Dental College, Navi Mumbai, with pain in maxillary left posterior region since 2 weeks. On clinical examination, deep caries was seen with 26. The tooth was tender on percussion. Pre-operative radiographic examinations showed large pulp chamber and short roots, suggesting taurodontism. Periapical area was within normal limit (Figure 1a). The patient's medical history and family history ruled out other diseases/pathologies occurring in association with taurodontism. Based on clinical and radiographic findings, diagnosis of irreversible pulpitis with acute apical periodontitis was made and endodontic therapy was planned for the same.

Under rubber dam and local infiltration of maxillary first molar, proper access opening made. The careful exploration revealed large pulp chamber, negotiation of the canals done, and it was found that three canals were originating deep into chamber. The working lengths were estimated using an apex locator (Propex, Dentsply) and then confirmed by radiograph (Figure 1b). After confirmation of three root canals mesiobuccal, distobuccal, and large palatal canal, the canals were prepared using a step back instrumentation technique up to 30# K file instruments for mesiobuccal and distobuccal canal and #40 for palatal canal at apex. A 2.5% of sodium hypochlorite and normal saline (sodium chloride injection I.P 0.9% w/v) was alternatively used as irrigants at every change of instruments. The canals were dried with sterile paper points and were dressed with calcium hydroxide paste. The access cavities were then temporarily sealed with intermediate restorative material. After an uneventful inter-appointment gap obturation of the root canals was undertaken by lateral condensation technique (Figure 1c). After obturation, the patient was followed up at regular intervals.

Case 2

A 35-year-old male patient reported to the Department of Conservative and Endodontics, YMT Dental College, Kharghar, Navi Mumbai, with chief complaint of pain in the lower left posterior region since 1 month. On clinical examination, large mesioproximal caries was seen with mandibular left third molar. Tooth was sensitive to percussion. The periapical radiograph showed large radiolucent periapical lesion at apex. Features of taurodontism were evident in intraoral periapical radiograph with mandibular left third molar. The patient's medical history and family history ruled out other diseases/pathologies occurring in association with taurodontism.

Under local anesthesia, access cavity preparation done, pulp extirpation done with all three canals before instrumentation. Both initial and final working length determined and confirmed with apex locator and radiograph. Instrumentation done with step back technique, mesiobuccal and mesiolingual canals were prepared till #30 size K file and distal canal was prepared till #40 size K file. Normal saline and 2.5% sodium hypochlorite were used as an irrigation solution after each instrumentation. Calcium hydroxide closed dressing given for 1 week. The canals were obturated with 2% gutta percha using lateral condensation technique (Figure 2).

DISCUSSION

Taurodontism is an anomaly of multi-rooted teeth, characterized by enlargement of the pulp chamber. Widdowson defined taurodontism as the vertical deepening of pulp cavity at the expense of roots.⁶

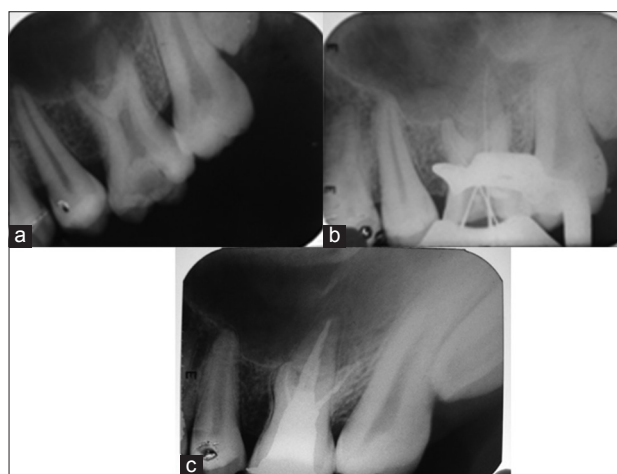


Figure 1: (a) Pre-operative, (b) working length determination, (c) post obturation

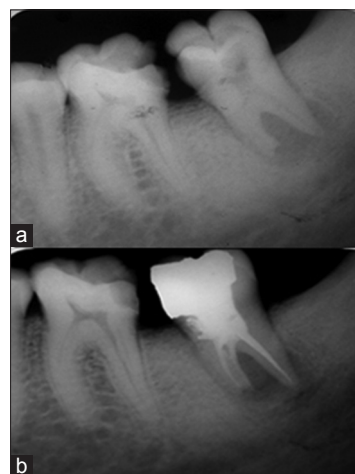


Figure 2: (a) Pre-operative, (b) post-operative

In 1928, Shaw classified taurodontism into hypo, meso, and hyper taurodontism. In 1978, Shiffmann and Chanannel⁷ established more objective criteria on the basis of determined measurement of a tooth. A tooth is called taurodont when the distance from the lowest point of the pulp chamber roof (a) to the highest point of the floor (b) when divided by the distance from A to the root apex (c) should be equal to the or >0.2 mm and/or the distance from B to cement CEJ (d) should be >2.5 mm.

The etiology of taurodontism is unclear. It is thought to be caused by the failure of Hertwig's epithelial root sheath diaphragm to invaginate the proper horizontal level.^{8,9} Some reports suggest that taurodontism may be genetically transmitted (Fischer, 1963; Witkop, 1971; Goldstein and Gottlieb, 1973) and could be associated with an increased number of X chromosomes.¹⁰

According to Mangion,¹¹ taurodontism may be: A retrograde character, a primitive pattern, Mendelian recessive character, atavistic feature, a mutation.

While genetic transmission can be demonstrated in most cases, other external factors can also damage developing dental structures such as infection (osteomyelitis), disrupted developmental homeostasi, high-dose chemotherapy,¹² and a history of bone marrow transplantation.¹³

In taurodontism, the pulp chamber is extremely large and elongated with much greater apico-occlusal height than normal, and thus, extends apically below the CEJ. The CEJ constriction is less marked than that of the normal tooth, giving the taurodont a rectangular shape. Furthermore, the furcation is displaced apically, resulting in shorter roots while enlarging the body of the tooth.^{2,9,14}

Clinically, a taurodont appears as a normal tooth. In fact, because the body and roots of a taurodont tooth lie below the alveolar margin, its distinguishing features cannot be recognized clinically.¹⁵ Therefore, the diagnosis of taurodontism is usually a subjective determination made from diagnostic radiographs.¹⁶ The radiographic characteristics of taurodont tooth are: Extension of the rectangular pulp chamber into the elongated body of the tooth, shortened roots and root canals, location of furcation (near the root apices), despite a normal crown size.^{9,15}

Although permanent mandibular molars are most commonly affected,¹⁷ taurodontism can be seen in both the permanent and deciduous dentition (very low incidence),^{9,17,18} unilaterally or bilaterally, and in any combination of teeth or quadrants.¹⁵

A taurodont tooth shows a wide variation in the size and shape of the pulp chamber, varying degrees of obliteration and canal configuration, apically positioned canal orifices and the potential for additional root canal systems. Therefore, root canal treatment becomes a challenge.^{17,19,20} Moreover, while the radiographic feature of a taurodont tooth is characteristic, pre-treatment radiographs produce little information about the root canal system. The results of pulp testing contribute little information about the effect of a large pulp chamber on tooth sensitivity.²¹

Durr *et al.* suggested that morphology could hamper the location of the orifices, thus creating difficulty in instrumentation and filling. Each taurodont tooth may have extraordinary root canals in terms of shape and number. A complicated root canal treatment has been reported for a mandibular taurodont tooth with five canals, only three of which could be instrumented to the apex.²² Therefore, careful exploration of the grooves between all orifices, especially with magnification, has been recommended to reveal additional orifices and canals.²⁰

Because the pulp of a taurodont is usually voluminous, to ensure complete removal of the necrotic pulp, 2.5% sodium hypochlorite has been suggested initially as an irrigant to digest pulp tissue. Application of final ultrasonic irrigation may ensure that no pulp tissue remains.

Because of the complexity of the root canal anatomy and the proximity of the buccal orifices, complete filling of the root canal system in taurodontism is challenging. A modified filling technique has been proposed, which consists of combined lateral compaction in the apical region with vertical compaction of the elongated pulp chamber, using the system B device (EIE/Analytic Technology, San Diego, CA, USA).²⁰

In cases of hypertaurodont (where the pulp chamber nearly reaches the apex and then breaks up into two or four channels) vital pulpotomy; instead of routine pulpectomy may be considered as the treatment of choice.^{16,23}

Placement of post for tooth reconstruction in these large chambered teeth should be avoided.²⁰

CONCLUSION

Taurodont teeth show wide variations in the size and shape of pulp chambers, varying degrees of obliteration and canal complexity, lower level of canal orifices, and the potential for additional or extra root canal systems. It is very important for a general practitioner to be familiar of taurodontism and its complex root canal system, its clinical

significance, complication, and important endodontic consideration during its management.

Although endodontic management is very complex in taurodontic molars, this report describes the uneventful successful endodontic management of taurodontism in molar teeth with a promising prognosis.

REFERENCES

1. Mark T, Jesper MT. Taurodontism in down's syndrome. *Oral Surg* 1981;51:632-6.
2. Keith A. Problems relating to the teeth of the earlier forms of prehistoric man. *Proc R Soc Med* 1913;6:103-24.
3. Goldstien E, Gottlieb MA. Taurodontism: Familial tendencies demonstrated in eleven of fourteen case reports. *Oral Surg* 1973;36:131-44.
4. Stewart RE. Taurodontism in X-chromosome aneuploid syndromes. *Clin Genet* 1974;6:341-4.
5. Ruprecht A, Batniji S, el-Neweihi E. The incidence of taurodontism in dental patients. *Oral Surg Oral Med Oral Pathol* 1987;63:743-7.
6. Lehtinen R. Taurodontism. A report of a case with familiar occurrence. *Suom Hammaslaak Toim* 1971;67:71-3.
7. Shiffmann A, Chanannel I. Prevalence of taurodontism found in radiographic dental examination of 1,200 young adult Israeli patients. *Community Dent Oral Epidemiol* 1978;6:200-3.
8. Hamner JE 3rd, Witkop CJ Jr, Metro PS. Taurodontism; Report of a case. *Oral Surg Oral Med Oral Pathol* 1964;18:409-18.
9. Terezhalmay GT, Riley CK, Moore WS. Clinical images in oral medicine and maxillofacial radiology. Taurodontism. *Quintessence Int* 2001;32:254-5.
10. Jafarzadeh H, Azarpazhooh A, Mayhall JT. Taurodontism: A review of the condition and endodontic treatment challenges. *Int Endod J* 2008;41:375-88.
11. Manjion JJ. Two cases of taurodontism in modern human jaw. *Br Dent J* 1962;113:309-12.
12. Greenberg MS, Glick M. *Burket's Oral Medicine-Diagnosis and Treatment*. 10th ed. Hamilton, ON, Canada: BC Decker; 2003.
13. Vaughan MD, Rowland CC, Tong X, Srivastava DK, Hale GA, Rochester R, *et al*. Dental abnormalities in children preparing for pediatric bone marrow transplantation. *Bone Marrow Transplant* 2005;36:863-6.
14. Sert S, Bayrl G. Taurodontism in six molars: A case report. *J Endod* 2004;30:601-2.
15. White SC, Pharoah MJ. *Oral Radiology: Principles and Interpretation*. 5th ed. St. Louis, USA: Mosby; 2004.
16. Neville BW, Damm DD, Allen CM, Bouquot JE. *Oral & Maxillofacial Pathology*. 5th ed. Philadelphia, PA: WB Saunders; 2002.
17. Rao A, Arathi R. Taurodontism of deciduous and permanent molars: Report of two cases. *J Indian Soc Pedod Prev Dent* 2006;24:42-4.
18. MacDonald-Jankowski DS, Li TT. Taurodontism in a young adult Chinese population. *Dentomaxillofac Radiol* 1993;22:140-4.
19. Hargreaves KM, Goodis HE. *Seltzer and Bender's Dental Pulp*. 3rd ed. Chicago: Quintessence Publishing Co.; 2002.
20. Tsesis I, Shifman A, Kaufman AY. Taurodontism: An endodontic challenge. Report of a case. *J Endod* 2003;29:353-5.
21. Durr DP, Campos CA, Ayers CS. Clinical significance of taurodontism. *J Am Dent Assoc* 1980;100:378-81.
22. Hayashi Y. Endodontic treatment in taurodontism. *J Endod* 1994;20:357-8.
23. Shifman A, Buchner A. Taurodontism. Report of sixteen cases in Israel. *Oral Surg Oral Med Oral Pathol* 1976;41:400-5.

How to cite this article: Sahu YR, Jain A. Endodontic Management of Taurodontism in Maxillary Molar: A Case Report. *Int J Sci Stud* 2016;4(5):271-274.

Source of Support: Nil, **Conflict of Interest:** None declared.