Multi-detector computed tomography venography (MDCTV) as a diagnostic tool in the management of patients with atypical, complicated and/or recurrent varicose veins

Poster No.: C-0889

Congress: ECR 2012

Type: Scientific Paper

Authors: A. Lawson[1], P. Rischbieter[2], J. Owen[1], T. Peedikayil[1], S. Beningfield[1]; [1]Cape Town/ZA, [2]Oxford/UK

Keywords: Abdomen, CT, Catheter arteriography, Embolisation, Stents, Hemodynamics / Flow dynamics, Varices

DOI: 10.1594/ecr2012/C-0889

Purpose

Varicose veins are one of the most common diseases in the world and since the introduction of less-invasive treatments, such as laser ablation and radiofrequency thermal ablation, there has been an increase in the interest in this disease(1). Routine surgical intervention remains the principal definitive management for large, unsightly varicose veins. A Trendellenburg strip is performed which entails the ligation of the common femoral vein at the saphenofemoral junction and removal of the native vein in its entirety from the leg.

A sub-group of patients develop recurrent varicose veins post surgery or atypical varicose veins. It is this group of patients who might benefit from multi-modality imaging to address the underlying causative lesion not addressed at the primary intervention or presentation.

We evaluate the role of MDCTV as a diagnostic tool in the management of this sub-set of patients compared to conventional venography which is considered the gold standard of venous imaging.

Methods and Materials

We performed a retrospective review of 21 patients who had undergone both MDCTV and conventional transfemoral, transjugular or transpopliteal venography between January 2008 and April 2011 for the management of recurrent varicose veins and/or chronic venous ulcers. The study was approved by our institutional review board.

MDCTV was performed using a 16-slice CT scanner. Spiral acquisition was commenced 180 seconds after intravenous injection of 150ml of 350mmol/l iodinated contrast medium. A reconstruction interval of 1.5-mm was used. Subset data reconstruction was performed in the curved coronal plane with particular reference to the course of the common and external iliac veins through the pelvis. Axial venous calibre measurements were performed and stenotic segments were measured on the reconstructed images. Readers were blinded to the findings from the conventional venography datasets. Secondary imaging outcomes were to identify anatomical anomalies, pelvic masses or compression of venous structures by native vessels.

Conventional venography was performed by the resident vascular surgeon. After a diagnostic flush, endovascular stenting or coiling was performed if a significant stenosis was verified or significant venous reflux was demonstrated.

Images for this section:

Fig. 1: Selected frame of a substracted venogram with self expanding metallic stent across left common iliac vein stenosis pre-deployment.

Fig. 2: Frame grab during deployment and balloon dilatation of the stent in Fig 1.

Results

MDCTV and venography were compared in twenty one patients (6 males, 15 females (average age 55 years, range 33-78 years); eight also underwent endovascular iliac vein stenting. The area under the receiver operator curve (ROC) curve for percentage iliac vein stenosis determined on MDCTV versus venography was 0.75. Four false positive (19%) iliac vein stenoses were reported on MDCTV. Aetiologically these stenoses were attributed to post phlebitic changes in 6 patients, May Thurner syndrome in 1 patient and idiopathic in 1 patient.

Ten patients underwent gonadal vein coil embolisation. Gonadal vein size over 5.2mm (range 1-11mm) on MDCTV predicted significant venographic reflux requiring coil embolisation. Three patients who underwent embolization (30%) did not have gonadal vein enlargement on MDCTV.

Images for this section:

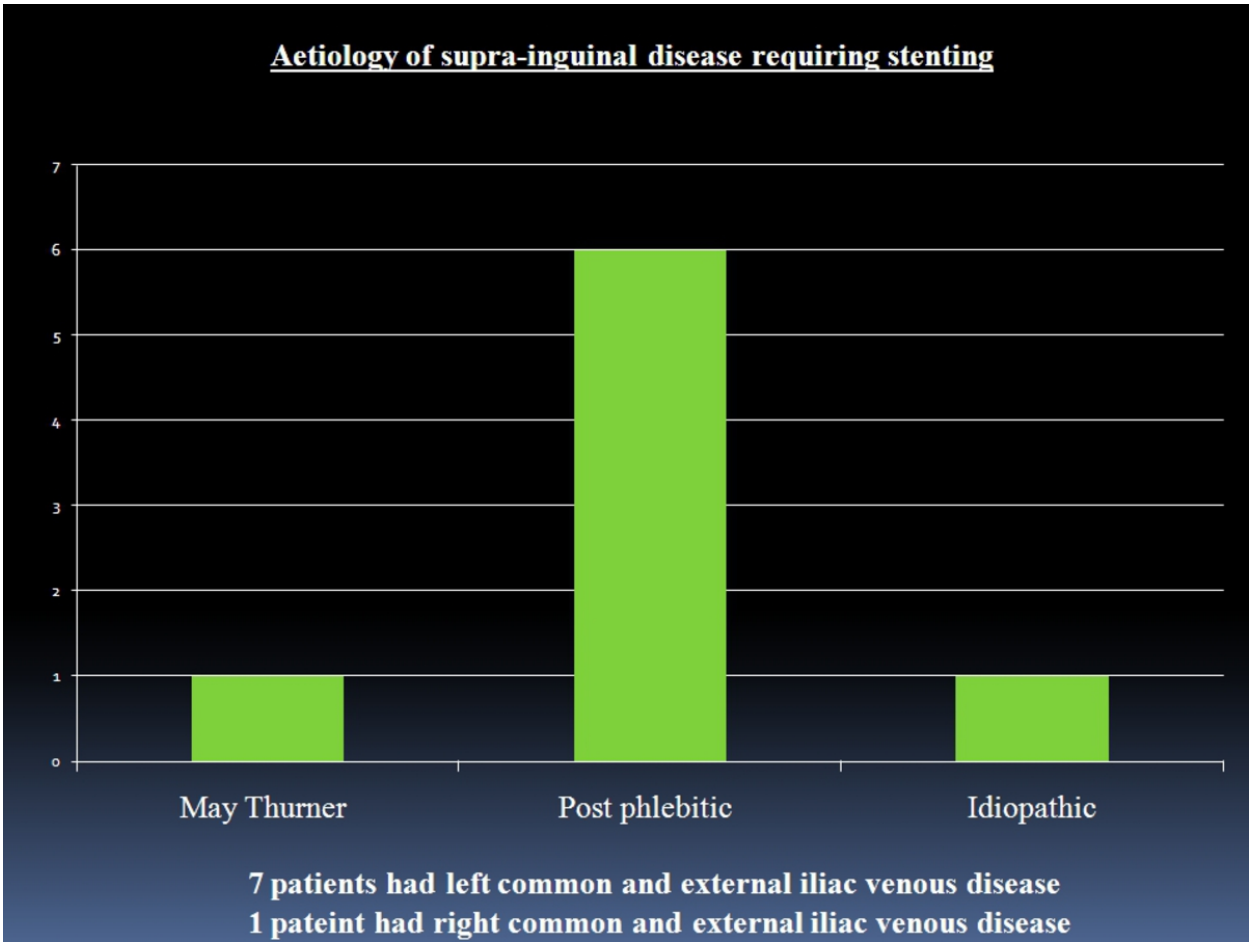

Fig. 3: Aetiology of iliac vein stenoses.

Conclusion

Currently limited data exists on the use of MDCTV and its role in complex varicose venous disease. We present a small cohort of cases where MDCTV findings correlate well with conventional venographic findings. Our study focuses on a subset of patients with complex venous disease where the underlying causative lesions are above the level of the inguinal canal and involve mainly the common/external iliac veins or gonadal veins. The mainstay of imaging was to reveal pathology that could be managed endovascularly either by iliac vein stenting(2, 3) or gonadal vein coil embolisation.

Preoperative evaluation of varicose veins must reveal the primary cause of varicosity, secondary reflux, and the distribution of varicosity, including perforating veins(1). Handheld Doppler and duplex sonography have become the modern non invasive gold standard(4). Sonography can evaluate hemodynamic information and anatomical data. Its main limitation is the lack of adequate visualization above the inguinal ligament.

MDCTV provides excellent information on the deep venous system above and below the inguinal canal. Multiplanar reformations and volume rendering provide both an assessment of venous compression and overall varicosity distribution(5). The major limitation of MDCTV is the lack of dynamic venous flow information limiting the interrogation of points of reflux. Furthermore MDCTV requires contrast medium administration and ionizing radiation (1.6-3.9 mSv(1)) and no insight to venous valvular function can be gained.

A clinical scoring system documenting the severity of venous disease is described by Ekloff et al(6). In our study, patients with clinical stage C6 venous disease were more likely to require iliac stenting. It is in this group that an almost 20% false positive rate was recorded at MDCTV. In light of the clinical severity score these patients may still benefit from diagnostic conventional venography with the adjunctive use of endovascular ultrasound to delineate potential stenoses missed at both conventional and MDCTV. Patients with C4 disease were more likely to require gonadal vein coiling. Selecting the latter group of patients purely on MDCTV findings is not recommended.

Varicose venous disease is a complex entity and careful patient selection and intervention is required for successful and curative management. This study indicates that although MDCT contributes to the multi-modality approach in venous disease, more extensive work needs to be done before it can play a larger role in definitive interventional decision making.

Images for this section:

Clinical staging

Clinical, etiological factors, anatomical distributions and pathophysiology - CEAP *

Iliac vein stenting grp	6 with C6, VDS 2	2 with C4, VDS 2	
Gonadal vein coiling grp	5 with C4, VDS 2	3 with C3, VDS 2	2 with C2, VDS 1

Score	Venous Disability Score
0	Asymptomatic
1	Symptomatic, but able to carry out usual activities* with-out compressive therapy
2	Able to carry out usual activities* only with compression and/or limb elevation
3	Unable to carry out usual activities* even with compression and/or limb elevation
*Usual activities = patients activities before the onset of disability due to venous disease.	

Class	Clinical Stage
C0	No visible or palpable signs of venous disease
C1	Telangiectases, reticular veins, malleolar flare
C2	Varicose veins
C3	Edema without skin changes
C4	Skin changes ascribed to venous disease (pigmentation (a), venous eczema, lipodermatosclerosis (b))
C5	Skin changes (as defined above) in conjunction with healed ulceration
C6	Skin changes (as defined above) in conjunction with active ulceration

*Eklof et al Journal of Vascular Surgery 2004 Vol 40, no. 6, pp 1248-1252

Fig. 4: Clinical disease severity index.

References

1. Lee W, Chung JW, Yin YH, Jae HJ, Kim SJ, Ha J, et al. Three-Dimensional CT Venography of Varicose Veins of the Lower Extremity: Image Quality and Comparison with Doppler Sonography. Am J Roentgenol. 2008 October 1, 2008;191(4):1186-91.

2. Titus JM, Moise MA, Bena J, Lyden SP, Clair DG. Iliofemoral stenting for venous occlusive disease. Journal of Vascular Surgery. 2011;53(3):706-12.

3. Rosales A, Sandbæk G, Jørgensen JJ. Stenting for Chronic Post-thrombotic Vena Cava and Iliofemoral Venous Occlusions: Mid-term Patency and Clinical Outcome. European Journal of Vascular and Endovascular Surgery. 2009;40(2):234-40.

4. Meissner MH, Eklof B, Smith PC, Dalsing MC, DePalma RG, Gloviczki P, et al. Secondary chronic venous disorders. Journal of Vascular Surgery. 2007;46(6, Supplement 1):S68-S83.

5. Min S-K, Kim S-Y, Park YJ, Lee W, Jung IM, Lee T, et al. Role of three-dimensional computed tomography venography as a powerful navigator for varicose vein surgery. Journal of Vascular Surgery. 2010;51(4):893-9.

6. Eklöf B, Rutherford RB, Bergan JJ, Carpentier PH, Gloviczki P, Kistner RL, et al. Revision of the CEAP classification for chronic venous disorders: Consensus statement. Journal of Vascular Surgery. 2004;40(6):1248-52.

Personal Information

Radiology registrar