

# A Clinical Comparison of *Cerabone* (A Decalcified Freeze-dried Bone Allograft) with Autogenous Bone Graft in the Treatment of Two- and Three-wall Intrabony Periodontal Defects: A Human Study with Six-month Reentry

Nader Abolfazli<sup>1\*</sup> • Fariba Saleh Saber<sup>2</sup> • Ardeshir Lafzi<sup>3</sup> • Amir Eskandari<sup>1</sup> • Sarah Mehrasbi<sup>4</sup>

1. Assistant Professor, Department of Periodontics, Faculty of Dentistry, Tabriz University of Medical Sciences, Iran

2. Assistant Professor, Department of Prosthodontics, Faculty of Dentistry, Tabriz University of Medical Sciences, Iran

3. Professor, Department of Periodontics, Faculty of Dentistry, Tabriz University of Medical Sciences, Iran

4. Periodontist, Private Practice, Tehran, Iran

\*Corresponding Author, E-mail: abolfazli@tbzmed.ac.ir

## Abstract

**Background and aims.** Complete and predictable regeneration of tissue lost as a result of infection or trauma is the ultimate goal of periodontal therapy. Various graft materials have been successfully used in the treatment of intrabony defects. The purpose of this study was to evaluate the use of a decalcified freeze-dried bone allograft (*Cerabone*) with the autogenous bone graft as a gold standard in the treatment of human two- or three-wall intrabony periodontal defects.

**Materials and methods.** This split-mouth study was done on 10 pairs of matched two- or three-wall intrabony periodontal defects with 5 mm or more probing depth and 3 mm or more depth of intrabony component following phase I therapy. In the control sites autogenous bone graft and in the test sites decalcified freeze-dried bone allograft were used.

**Results.** At baseline, no significant differences were found in terms of oral hygiene and defect characteristics. At six months, analysis showed a significant improvement in soft and hard tissue parameters for both treatment groups as compared to preoperative measurements. There were no statistical differences in clinically-measured parameters between treatment groups after 6 months except for crestal resorption that increased significantly in control group ( $P = 0.25$ ). Defect resolution and bone fill in the test and control groups were  $2.5 \pm 0.46$  mm versus  $2.7 \pm 0.73$  mm and  $2 \pm 0.62$  mm versus  $2.20 \pm 0.52$  mm, respectively.

**Conclusion.** The results of this study demonstrated that both graft materials improved clinical parameters. The comparison of the two treatment groups did not show any significant differences in clinical parameters after six months. However, because of the limited amount of intra-oral donor bone, it is preferable to use decalcified freeze-dried bone allograft.

**Key words:** Autogenous bone graft, decalcified freeze-dried bone allograft, intrabony periodontal defects, regenerative periodontal therapy.

## Introduction

The ultimate goal of periodontal therapy is complete and predictable regeneration of lost periodontal tissue. Regenerative procedures may restore lost supporting structures of the dentition such as cementum, periodontal ligament and bone to previously diseased root surface.<sup>1</sup> Several studies demonstrated that the use of graft materials has better clinical results when compared with open flap debridement for the treatment of intrabony defects.<sup>2,3</sup>

The materials most commonly used in the treatment of intrabony defects have been autografts and allografts.<sup>4,5</sup> The bone replacement grafts may aid in forming a scaffold for the host's resident cells in order to provide either osteoinductive or osteoconductive pathways or may have osteogenesis factors.<sup>5,6</sup> Bowers et al<sup>7</sup> have shown that the addition of graft materials to periodontal defects in closed environment augments the potential for periodontal regeneration.

Autogenous bone has been used with success and may be harvested from intra- or extra-oral sites.<sup>8-10</sup> The main disadvantage of intra-oral autogenous bone graft is the limited amount of intra-oral donor bone and the main disadvantages of extra-oral autogenous bone grafts such as iliac crest are the need for hospitalization, risk of potential ankylosis, and root resorption.<sup>11</sup>

Clinically, decalcified freeze-dried bone allograft (DFDBA) has demonstrated the ability to reduce a defect depth more than 50% in 78% of sites, while surgical debridement only resulted in more than 50% defect fill in 38% of the sites.<sup>4</sup> Histological evidence of a new attachment apparatus in humans revealed that DFDBA has the ability to regenerate cementum, periodontal ligament, and bone.<sup>7</sup>

The purpose of this study was to compare the use of a newly-introduced DFDBA (Cerabone) and autogenous bone graft in the treatment of two- or three-wall periodontal osseous defects.

## Materials and Methods

### Patient selection

In this split-mouth clinical trial, five patients, 4 females and 1 male (mean age, 35 ± 11 years), referring to the Department of Periodontics, Tabriz Faculty of Dentistry, were

included. All patients had at least one pair of matched two- or three-wall intrabony periodontal defects with 5 mm or more probing depth and 3 mm or more depth of intrabony component, determined by bone sounding following phase I therapy and re-evaluation prior to surgery. Medical and dental histories were reviewed for the following exclusion criteria: (1) any systemic condition that would preclude periodontal surgery, (2) female patients who were pregnant or planned on becoming pregnant within the next 9 months, (3) failure to maintain good oral hygiene (Loe & Silness),<sup>12</sup> (4) patients who had received antibiotic therapy within the past six months, (5) patients who were undergoing orthodontic therapy, and (6) Smokers.

Patients were entered to the study based on the following inclusion criteria: At least one pair of matched two- or three-wall intrabony periodontal defect with 5 mm or more probing depth and 3 mm or more depth of intrabony component determined by bone sounding following phase I therapy and re-evaluation prior to the surgery.

### Procedures

The study design was approved by the Ethics Committee and Research Council of Tabriz University of Medical Sciences. The purpose of this investigation was explained in detail to the patients and they signed an informed consent. All patients underwent initial therapy including full mouth scaling and root planing, restoring decays and correction of restorations, and occlusal adjustment when indicated as well as receiving oral hygiene instructions.

Plaque control was assessed at each scaling and root planing appointment. Four weeks following completion of initial therapy, re-evaluation examination was performed.

At the time of the surgery, plaque index (Loe & Silness)<sup>12</sup> and gingival index (Silness & Loe)<sup>13</sup> were recorded and clinical parameters were measured with a William's periodontal probe from a fixed reference point using a customized acrylic stent to control angulation and position errors. All baseline clinical parameters were obtained on the day of the surgery by one examiner, who was masked to the type of treatment. Final parameters were

taken six months post-operatively by the same examiner.

Soft tissue measurements included:

1- Clinical probing depth (PD): free gingival margin to the base of the pocket.

2- Clinical attachment level (CAL): inferior margin of the stent to the base of the pocket.

3- Gingival marginal level: inferior margin of the stent to the free gingival margin. Subtraction of measurements of this parameter at baseline and six months post-surgery presented gingival recession.

#### *Surgical protocol*

All surgical procedures were performed by one surgeon. Surgical sites were anesthetized utilizing 0.2% lidocaine with 1:80,000 epinephrine. Following buccal and lingual sulcular incisions, full thickness flaps were raised. Granulation tissue was removed to allow visualization of the defect. Root surfaces were scaled and root planed by hand and ultrasonic instrumentation.

Hard tissue measurements were made with the same stent:

1- Inferior margin of the stent to the alveolar crest (Stent-AC).

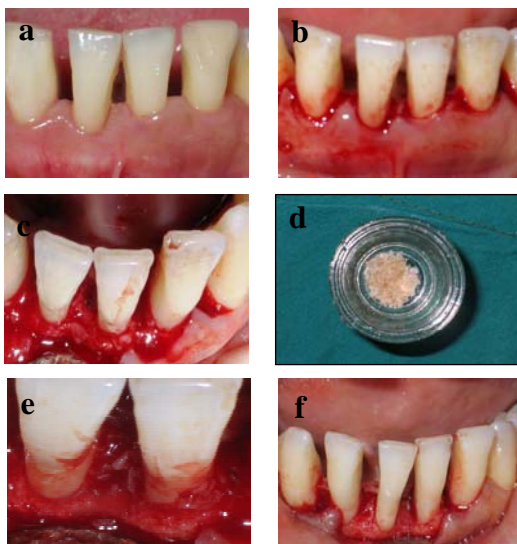
2- Inferior margin of the stent to the base of the defect (Stent-DB).

3- Alveolar crest to the base of the defect (AC-DB).

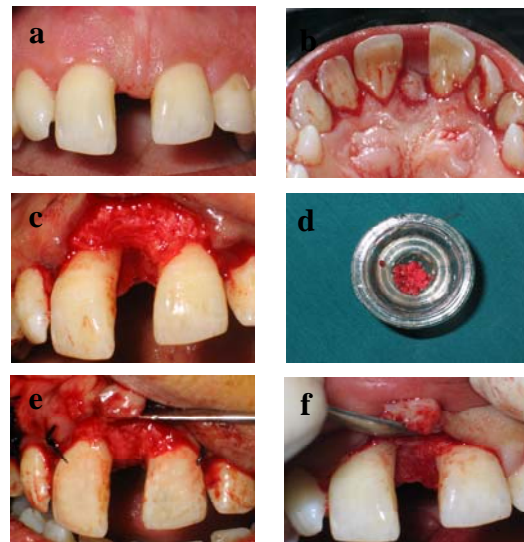
Subtractions of baseline and 6-month follow-up of the three measurements were used to determine alveolar crestal resorption, defect fill and defect resolution, respectively.

One defect from each pair of intrabony defects was randomly selected by the toss of a coin to be treated with either autogenous bone graft (ABG) or Cerabone DFDBA (Tissue Regeneration Corporation, Tehran, Iran). Autogenous bone chips were taken by means of hand instruments from the surgical site or an adjacent edentulous area. DFDBA used in this study was manufactured according to the standards and guidelines of American Association of Tissue Banks (AATB). Defects were overfilled with the bone grafts. Closure was accomplished using 4-0 suture in vertical mattress fashion and periodontal dressing was used (Figures 1 & 2).

Six months after primary surgery, a re-entry surgery was done to evaluate the results of different treatment protocols.



**Figure 1.** Pretreatment view of mandibular left first incisor (a); sulcular incision (b); reflection and debridement (c); DFDBA (d); placement of the graft material (e); re-entry 6 months later (f).



**Figure 2.** Pretreatment view of maxillary incisor (a); Papilla preservation flap (b); reflection and debridement (c); ABG (d); placement of the graft material (e); re-entry 6 months later (f).

*Post-operative care*

Patients were instructed to rinse twice daily for four weeks with a 0.2% chlorhexidine gluconate solution. Acetaminophen 325 mg qid and amoxicillin 500 mg tid for 10 days were prescribed.

The patients were appointed at 7 days following surgery for removal of the periodontal dressing and sutures. Two weeks after surgery and then every month, patients had a professional prophylaxis and oral hygiene reinforcement. Soft and hard tissue measurements were repeated in the six-month follow-up.

*Statistical analysis*

The paired *t*-test was used to compare soft and hard tissue measurements taken prior to surgery (baseline) and six months post-operatively. Analysis of differences between

sites utilizing ABG and DFDBA were performed by the independent sample *t*-test. Data were analyzed using SPSS 11.0 computer software.

**Results**

A total of 5 patients with 10 pairs of intrabony defects received surgical therapy. All 5 subjects returned for re-evaluation after six months. 10 sites were treated with DFDBA and 10 sites were treated with ABG. Clinical evaluation of post-operative healing revealed excellent soft tissue response to both treatment methods without any complications. All patients maintained an excellent level of plaque control during the six-month period following treatment.

There were no significant differences in baseline soft and hard tissue parameters between DFDBA and ABG group (Table 1).

**Table 1. Comparison of soft and hard tissue parameters at baseline in mm**

	Sites treated with DFDBA	Sites treated with ABG	P-value
<b>PD</b>	6.6 ± 1.83	6.5 ± 1.5	0.912
<b>CAL</b>	10 ± 1.76	9.7 ± 1.82	0.853
<b>Stent-GM</b>	3.4 ± 1.07	3.2 ± 0.78	0.739
<b>Stent-AC</b>	8.8 ± 1.54	8 ± 1.69	0.315
<b>Stent-DB</b>	12.3 ± 2.11	11.5 ± 1.5	0.481
<b>AC-DB</b>	3.5 ± 0.97	3.5 ± 0.52	0.579

PD, probing depth; CAL, clinical attachment level; GM, gingival margin; AC, alveolar crest; DB, defect base.

Soft tissue recession increased following surgical procedures. A significant reduction in probing depth and gain in clinical attachment level occurred with both DFDBA and ABG. Probing depth decreased  $3.1 \pm 1.12$  mm in DFDBA group and  $3.4 \pm 1.31$  mm in ABG group. Clinical attachment level gains were  $2.5 \pm 0.93$  mm and  $2.8 \pm 0.77$  mm in the DFDBA and ABG group, respectively (Table

2). However, there were no significant differences between the two groups in soft tissue parameters after six months.

Alveolar crest resorption increased significantly in ABG group ( $P = 0.025$ ) (Table 3).

Bone fill and defect resolution significantly improved in both groups; however, there were no significant differences between the two groups after six months (Table 3).

**Table 2. Comparison of soft tissue parameters at baseline and 6 months after in mm**

Parameters	PD		CAL		Stenet-GM	
	DFDBA	ABG	DFDBA	ABG	DFDBA	ABG
<b>Baseline</b>	$6.6 \pm 1.83$	$6.5 \pm 1.5$	$10 \pm 1.76$	$9.7 \pm 1.82$	$3.4 \pm 1.07$	$3.2 \pm 0.78$
<b>After 6 months</b>	$3.5 \pm 0.97$	$3.1 \pm 0.31$	$7.5 \pm 1.77$	$6.9 \pm 1.97$	$4 \pm 1.49$	$2.7 \pm 0.94$
<b>P-value *</b>	$P = 0.005$	$P = 0.005$	$P = 0.005$	$P = 0.005$	$P = 0.034$	$P = 0.025$
<b>P-value †</b>	$P = 0.634$		$P = 0.613$		$P = 0.511$	

PD, probing depth; CAL, clinical attachment level; GM, gingival margin.

\* Baseline and six months post-operatively.

† Between two groups.

**Table 3. Comparison of hard tissue parameters at baseline and 6 months after in mm**

Parameters	Stent-AC		Stent-DB		AC-DB	
	DFDBA	ABG	DFDBA	ABG	DFDBA	ABG
<b>Baseline</b>	$8.8 \pm 1.54$	$8 \pm 1.89$	$12.3 \pm 2.11$	$11.5 \pm 1.5$	$3.5 \pm 0.97$	$3.5 \pm 0.52$
<b>After 6 months</b>	$9.3 \pm 2$	$8.5 \pm 2.12$	$10.3 \pm 2$	$9.3 \pm 2$	$1 \pm 0.66$	$0.8 \pm 0.42$
<b>P-value *</b>	$P = 0.59$	$P = 0.25$	$P = 0.004$	$P = 0.004$	$P = 0.005$	$P = 0.004$
<b>P-value †</b>	$P = 0.83$		$P = 0.493$		$P = 0.424$	

AC, alveolar crest; DB, defect base.

\* Baseline and six months post-operatively.

† Between two groups.

### Discussion

Regeneration of lost attachment apparatus is the treatment of choice for intrabony defects in contemporary clinical practice. This clinical study evaluated clinical changes in intrabony periodontal defects following the use of DFDBA and ABG. The results of this study demonstrated that both treatment methods provide statistically significant improvements in hard and soft tissue measurements. In addition, statistical analysis of data revealed no significant differences between the two treatment methods with regards to soft and hard tissue measurements except for crestal resorption in ABG group.

In clinical case-series where intra-oral autogenous grafts were used for the treatment of intrabony periodontal defects, a mean bone fill ranging from 3 mm to 3.5 mm was reported.<sup>2,4,8,9</sup> The mean bone fill was 2.98 mm in the study of Froum et al<sup>2</sup> using bone blending and 3.5 mm in the study of Hiatt & Schallhorn<sup>4</sup> using intra-oral cancellus bone. In the present study, the mean bone fill using ABG was  $2.20 \pm 0.52$  mm. The differences in the results of this study and other studies may be due to the type of autogenous bone used, the type of osseous defects, and the higher initial defect depth.

In the present study, mean bone fill and defect resolution in DFDBA group were  $2 \pm 0.62$  mm and  $2.5 \pm 0.46$  mm, respectively. Guillemain et al<sup>14</sup> using DFDBA reported 1.9 mm and 2.1 mm bone fill and defect resolution, respectively. Masters et al<sup>15</sup> found a mean bone fill of 2.2 mm in DFDBA group which is comparable to our finding.

Gulliemin et al<sup>14</sup> reported a higher initial probing depth than that of our study, but the probing depth reduction was less than our findings (2.4 mm vs. 3.1 mm, respectively). In their study, clinical attachment level gain and gingival recession were 2.8 mm and 4 mm, while in ours these parameters were found to be 2.5 mm and 0.6 mm, respectively. These differences were observed in hard tissue parameters which may be justified by the fact that Gulliemin et al did not exclude smokers nor defined the morphology of the defects.

Parashis et al<sup>16</sup> found the reduction of probing depth and gain of clinical attachment level in DFDBA group to be 3.6 mm and 3.2 mm, respectively. The initial probing depth ( $\geq 6$  mm) was more than that of our study and this

could be a reason for such improvements. While the initial defect depth ( $\geq 4$  mm) was also more than that of our study, the defect resolution was less (35.4% vs. 70%, respectively). This may be due to the different post-operative care in that study in which they emphasized the importance of wound stability during immediate post-surgery period after regenerative therapy through exclusion of trauma from oral hygiene, periodontal dressing and early suture removal. In that study sutures were removed 2 weeks after surgery, no periodontal dressing were applied and patients did not use plaque control for 6 weeks.

Gurinsky et al<sup>17</sup> reported that the combination therapy with DFDBA and Emdogain resulted in 3.6 mm reduction in probing depth, 3 mm gain of clinical attachment level and 3.7 mm bone fill. It could be suggested that the improvement of these parameters compared to our results was due to the biologic effect of Emdogain.

A higher bone fill in DFDBA group compared to our study was reported by Masters et al.<sup>15</sup> A distinct limitation of their study was the variation in the types of defects treated including the number of osseous walls, the depth and width of the defects and adjacent root anatomy. The number of walls appeared not to be associated with defect fill, but root anatomy did affect treatment outcome. Some defects were located on the mesial of maxillary first bicuspid associated with a deep groove or maxillary molars with deep class II furcation involvement. The anatomical factors lead to difficulty in plaque control and compromise the success of the treatment. The disagreement in the results of the present study and those of other studies may be due to differences in study design, patient selection, type and depth of defect treated, location of defect measurement, and the DFDBA used.

It has been suggested that the osteoinductivity function of DFDBA is dependent on the age of the donor,<sup>18</sup> particle size,<sup>19</sup> and the method of preparation in the tissue bank.<sup>20</sup> Schwartz et al<sup>18</sup> reported that DFDBA should be harvested from donors under the age of 50 years and that the best age is 0-29 years old. The donors in this study were 19 years old which is in accordance with the study of Schwartz et al.

Particle size is another important factor which can cause differences in healing response.<sup>20</sup> However, one study stated that there

is no significant differences in bony defect fills for two particle sizes tested (250-500  $\mu\text{m}$  & 850-1000  $\mu\text{m}$ ).<sup>21</sup> Despite this, the particle size reported to have the best response is 250-750  $\mu\text{m}$  similar to the range used in this study.<sup>22</sup>

The preparation method of DFDBA in tissue banks is also an important factor in osteoinductivity function of DFDBA.<sup>20</sup> The DFDBA used in this study was prepared according to the guidelines of American Association of Tissue Bank.

One of the limitations in this study was the sample size. A larger sample size may have demonstrated statistically significant differences between the two groups. The large variability in patient response to therapy also created large standard deviations which limited the ability for statistical analysis to demon-

strate differences between treatment groups. Histologic evaluation is also recommended for determining the type of the regenerated tissues.

In conclusion, within the limits of this study, both graft materials were beneficial for treatment of intrabony defects with no significant differences. However, because of the limited amount of intra-oral donor bone, it is preferable to use DFDBA for the treatment of large intrabony defects.

#### Acknowledgments

The authors would like to thank the Tissue Regeneration Corporation for providing the DFDBA.

#### References

1. American Academy of Periodontology. *Glossary of Periodontal Terms*, 4th ed. Chicago: American Academy of Periodontology; 2001:44.
2. Froum SJ, Ortiz M, Witkin RT, Thaler R, Scopp IW, Stahl SS. Osseous autografts. III. Comparison of osseous coagulum-bone blend implants with open curettage. *J Periodontol* 1976;47:287-94.
3. Hawley CE, Miller J. A histologic examination of a free osseous autograft. Case report. *J Periodontol* 1975;46:289-93.
4. Hiatt WH, Schallhorn RG. Intra-oral transplants of cancellous bone and marrow in periodontal lesions. *J Periodontol* 1973; 44:194-208.
5. Bowers GM, Chadroff B, Carnevale R, Mellonig J, Corio R, Emerson J, et al. Histologic evaluation of new attachment apparatus formation in humans. Part II. *J Periodontol* 1989;60:675-82.
6. Mellonig JT, Bowers GM, Cotton WR. Comparison of bone graft materials. Part II. New bone formation with autografts and allografts: a histological evaluation. *J Periodontol* 1981;52:297-302.
7. Bowers GM, Chadroff B, Carnevale R, Mellonig J, Corio R, Emerson J, et al. Histologic evaluation of new attachment apparatus formation in humans. Part I. *J Periodontol* 1989;60:664-74.
8. Nabers CL, O'leary TJ. Autogenous bone transplants in the treatment of osseous defects. *J Periodontol* 1965;36:5-14.
9. Robinson E. Osseous coagulum for bone induction. *J Periodontol* 1969;40:503-10.
10. Diem CR, Bowers GM, Moffitt WC. Bone blending: a technique for osseous implants. *J Periodontol* 1972;43:295-7.
11. Nabers CL, Reed OM, Hamner JE 3rd. Gross and histologic evaluation of an autogenous bone graft 57 months postoperatively. *J Periodontol* 1972;43:702-4.
12. Loe H, Silness J. Periodontal disease in pregnancy. I. Prevalence and severity. *Acta Odontol Scand* 1963;21:533-551.
13. Silness J, Loe H. Periodontal disease in pregnancy. II. Correlation between oral hygiene and periodontal condition. *Acta Odontol Scand* 1964;22:121-35.
14. Guillemin MR, Mellonig JT, Brunsvold MA. Healing in periodontal defects treated by decalcified freeze-dried bone allografts in combination with ePTFE membranes (I). Clinical and scanning electron microscope analysis. *J Clin Periodontol* 1993;20:528-36.
15. Masters LB, Mellonig JT, Brunsvold MA, Nummikoski PV. A clinical evaluation of demineralized freeze-dried bone allograft in combination with tetracycline in the treatment of periodontal osseous defects. *J Periodontol* 1996;67:770-81.

16. Parashis A, Andronikaki-Faldami A, Tsiklakis K. Comparison of 2 regenerative procedures--guided tissue regeneration and demineralized freeze-dried bone allograft--in the treatment of intrabony defects: a clinical and radiographic study. *J Periodontol* 1998;69:751-8.
17. Gurinsky BS, Mills MP, Mellonig JT. Clinical evaluation of demineralized freeze-dried bone allograft and enamel matrix derivative versus enamel matrix derivative alone for the treatment of periodontal osseous defects in humans. *J Periodontol* 2004;75:1309-18.
18. Schwartz Z, Somers A, Mellonig JT, Carnes DL Jr, Dean DD, Cochran DL, et al. Ability of commercial demineralized freeze-dried bone allograft to induce new bone formation is dependent on donor age but not gender. *J Periodontol* 1998;69:470-8.
19. Mellonig JT, Levey RA. The effect of different particle sizes of freeze-dried bone allograft on bone growth. *J Dent Res* 1984;63:222 (Abstract 461).
20. Shigeyama Y, D'Errico JA, Stone R, Somerman MJ. Commercially-prepared allograft material has biological activity in vitro. *J Periodontol* 1995;66:478-87.
21. Fucini SE, Quintero G, Gher ME, Black BS, Richardson AC. Small versus large particles of demineralized freeze-dried bone allografts in human intrabony periodontal defects. *J Periodontol* 1993;64:844-7.
22. Newman MG, Takei HH, Carranza FA. *Clinical Periodontology*, 9th ed. Philadelphia: Saunders; 2002:816.