

## Fetal axillary cystic hygroma: a case report and review

Osman Temizkan,<sup>1</sup> Faruk Abike,<sup>2</sup>  
Habibe Ayvaci,<sup>3</sup> Ersan Demirag,<sup>3</sup>  
Yasin Görücü,<sup>4</sup> Ecmel Isık<sup>5</sup>

<sup>1</sup>Department of Obstetrics Gynecology, Sisli Etfal Education and Research Hospital, Istanbul;

<sup>2</sup>Department of Obstetrics Gynecology, Medicana International Ankara Hospital, Ankara;

<sup>3</sup>Department of Obstetrics Gynecology, Zeynep Kamil Education and Research Hospital, Istanbul;

<sup>4</sup>Department of Radiology, Haseki Education and Research Hospital, Istanbul;

<sup>5</sup>Department of Pathology, Zeynep Kamil Education and Research Hospital, Istanbul, Turkey

### Abstract

Cystic hygroma (CH) is a lymphatic malformation occurring different parts of fetal body, typically in the region of the fetal neck and axillary, abdominal wall, mediastinal, inguinal and retroperitoneal areas. CH has been associated with fetal aneuploidy, hydrops fetalis, structural malformations and intrauterine fetal death.

A 24-year-old gravida 1, para 1 was admitted to our hospital at 28 weeks of gestation. Ultrasonographic examination determined 28 weeks of gestation, singleton, alive fetus who had a mass derived from the right axillary region which was extending to the anterior and posterior thoracic wall with fluid-filled cavities about 12 cm in size. There was no evidence of intrathoracic or intraabdominal extension of mass. Cordocentesis was performed and karyotype examination was normal 46 XY. The fetal demise was found after the first visit. The patient was delivered vaginally after labor induction with oxytocin infusion. The fetal autopsy confirmed the diagnosis of CH.

The fetal CH carries high risk of aneuploidy and fetal malformations. Patients that have been diagnosed with CH in antenatal follow-ups should be assessed in terms of other anomalies. Fetal karyotyping should be done and the patient should be monitored for fetal hydrops. The birth should be planned in a multidisciplinary hospital and as neonatal resuscitation could be needed, pediatricians should be consulted.

### Introduction

Cystic hygroma (CH) is a lymphatic malformation occurring in different parts of fetal body, typically in the region of the fetal neck and axillary, abdominal wall, mediastinal, inguinal and retroperitoneal areas.<sup>1,2</sup> CH may result from a complete or incomplete obstruction in the lymphatics that prevents communication with the venous system and causes cysts.<sup>3</sup> The hygroma describes an endothelial-lined mass consisting of small to medium-sized lumina containing lymphatic fluid, together with a mixture of loose collagen tissue, adipose tissue and, occasionally, vascular tissue. The cysts may be unilocular, but more often the structure contains multiple cysts infiltrating the surrounding structures and distorting the local anatomy.<sup>4</sup> The lack of lymphatic drainage leads to an increased volume of flow in the venous system, resulting in large veins.<sup>5</sup> The septated CH may result from a complete obstruction in the lymphatic sacs that prevents communication with the venous system and causes lymph fluid to accumulate and dissect into tissues, thus creating large multilocular cysts. Nonseptated CH may result from a temporary accumulation of lymph fluid due to incomplete obstructions of lymphatic drainage.<sup>6,7</sup> Increased lymphatic pressure may sometimes overcome the incomplete obstructions, thus explaining the higher spontaneous resolution rate reported with nonseptated CH.<sup>6-8</sup>

CH has been associated with fetal aneuploidy, hydrops fetalis, structural malformations and intrauterine fetal death.<sup>9-11</sup> In particular they may be associated with Turner syndrome, Noonan syndrome, Trisomies, cardiac anomalies and fetal hydrops.<sup>12</sup> Two distinct categories of fetal CH have been described: those diagnosed in later pregnancy, which tend to be isolated lymphangiomas, and those diagnosed in early pregnancy, which are commonly associated with other malformations.<sup>13,14</sup> Retrospective case series describing the prenatal diagnosis of this condition suggest that those diagnosed early in pregnancy are associated with a poor prognosis.<sup>8,13,14</sup> When CH appears septated, the prognosis is considered even worse than the nonseptated form.<sup>8,15</sup> Axillary CH was rarely reported and determined often in midgestation.<sup>16,17</sup> The purpose of this study was to evaluate karyotypic, ultrasonographic and prognostic factors of CH diagnosed during pregnancy and to describe an axillary localized CH case.

### Case Report

A 24-years-old woman, gravida 1, para 1, admitted to our antenatal clinic for gestational

Correspondence: Osman Temizkan, Sisli Etfal Education and Research Hospital, Department of Obstetrics Gynecology, 34377 Sisli Istanbul, Turkey.

Tel. +90.505.7655176 - Fax: +90.212.2431121.

E-mail: mdtemizkan@yahoo.com

Key words: cystic hygroma, axillary, karyotype, diagnosis, treatment, prognosis.

Conflict of interest: the authors report no conflicts of interest.

Received for publication: 10 April 2011.

Accepted for publication: 27 July 2011.

This work is licensed under a Creative Commons Attribution NonCommercial 3.0 License (CC BY-NC 3.0).

©Copyright O. Temizkan et al., 2011  
Licensee PAGEPress, Italy  
Rare Tumors 2011; 3:e39  
doi:10.4081/rt.2011.e3

follow-up. The patient didn't take any antenatal care until admission to our clinic. Her socioeconomic status was not good. The woman didn't use folic acid drugs neither before the pregnancy nor during the pregnancy. She was nonsmoker and nondrinker. There was no systemic illness and operation in her past medical history. Patient's vital signs, routine blood and urine tests were found normal. Ultrasonographic examination determined 28 weeks of gestation, singleton, alive fetus who had a mass derived from the right axillary region which was extending to the anterior and posterior thoracic wall with fluid-filled cavities about 12 cm in size (Figure 1). Fetal biometry was appropriate for gestational age, placenta and amniotic fluid were normal. No other fetal anomalies were identified. Color velocity imaging demonstrated no flow through the mass. The diagnosis of axillothoracic CH was corrected by magnetic resonance imaging (MRI) examination (Figure 2). There was no evidence of intrathoracic or intraabdominal extension of mass. Fetal thorax and abdomen were found normal in MRI examination. The cordocentesis was performed after the patient's informed consent was taken. Karyotype examination was normal 46 XY. Patient was followed up as outpatient by the high risk pregnancy department. The patient admitted to antenatal clinic 3 weeks later again because of the lack of fetal movements. In ultrasonographic evaluation, fetal demise was found. The mass was seen as the same size, and there wasn't any sign of hydrops fetalis, the amniotic fluid was found normal. The patient delivered vaginally after labor induction with oxytocin infusion. Multiple cord entanglements were found around fetal neck.

During the delivery, fetal or cystic damage was not happened. In postnatal examination a multicystic, transluminating mass was seen which measured 15 cm was in maximum diameter. The mass was extending from axilla to anterior and posterior thoracic wall. There was no fetal anomaly in fetal macroscopic examination except axillothoracic cystic mass and there was no apparent invasion of the mass into chest cavity and no parenchymal lung disease. As a result of the fetal autopsy and pathological findings, it was diagnosed as CH. Histological examination demonstrated cystic lymphangioma with dilated communicating lymphatic vessels lined by normal epithelium and cystic areas with rare aggregates of lymphocytes (Figure 3). Additional fetal anomaly wasn't detected.

## Discussion

Fetal CH is a congenital malformation in which distended fluid-filled spaces develop, typically in the region of the fetal neck. Cystic hygromas are slow-growing benign tumours resulting from a developmental anomaly of the lymphatic system.<sup>18</sup> The lymphatic system begins to develop in 6 weeks, and then combines with venous system. The inability of combination between venous system and lymphatic system results in CH.<sup>18,19</sup>

CH has been associated with fetal aneuploidy, hydrops fetalis, structural malformations and intrauterin fetal death.<sup>9-11</sup> It is reported to occur between 1 in 6000 and 1 in 16,000 live births but it is estimated to be much more than this proportion as we take into account the abortions (1/875).<sup>18,19</sup> CH can occur anywhere in the body, but 75% involve the posterior neck, 20% the axilla and 1% the mediastinum, groin and retroperitoneum.<sup>19,20</sup> In particular they may be associated with Turner syndrome, Noonan syndrome, Trisomies, cardiac anomalies, fetal hydrops.<sup>12</sup> If this inability is severe, the progressive peripheral lymph edema and hydrops develops and results in early fetal loss.<sup>19</sup> Two distinct categories of fetal CH have been described: those diagnosed in later pregnancy, which tend to be isolated lymphangiomas, and those diagnosed in early pregnancy, which are commonly associated with other malformations.<sup>13,14</sup> Retrospective case series describing the prenatal diagnosis of this condition suggest that those diagnosed early in pregnancy are associated with a poor prognosis.<sup>8,13,14</sup> When CH appears septated, the prognosis is considered even worse than the nonseptated form.<sup>8,15</sup> The CH in later gestation, which likely represents a lymphangioma that is not associated with either aneuploidy or other fetal malformations, and can be expected to yield a good prognosis.<sup>13,14</sup> CH incidence is

equal in both sexes, but the inguinal CH is 5 times more common in men.<sup>21</sup>

A total of 38,167 patients were enrolled at 15 study centers, and a total of 134 cases of CH were diagnosed in this population. Chromosomal abnormality was diagnosed in 67 of 132 cases (51%) of CH.<sup>22</sup> 18 cases having cystic CH were detected, 8 cases (44.4%) were found to have a 45, X karyotype, 3 cases were found to be mosaic Turner syndrome (16.7%), 5 cases (27.7%) had normal karyotype, 1 case (5.6%) trisomy 13, and 1 case (5.6%) trisomy 21.<sup>23</sup> Fifty-seven cases of CH among 8155 screenings (0.7%). 35 of the cases (61.4%) were non-septated and 22 of the cases (38.6%) were septated CH. Chromosomal abnormalities were found in 23 of the cases (40.3%). The most common abnormality in nonseptated CH was trisomy 21 (8 cases, 25%) and in septated CH was Turner syndrome (4 cases, 21.1%). The most common associated structural malforma-

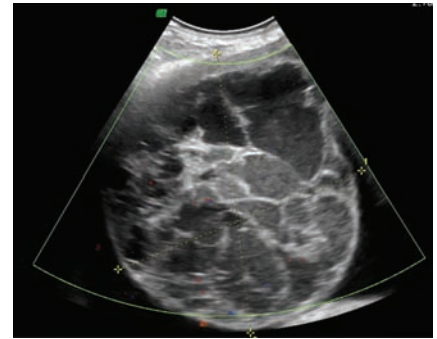


Figure 1. Ultrasonography showing a large multiseptate mass in the right axilla and a Doppler scanning no vascularity in the mass.

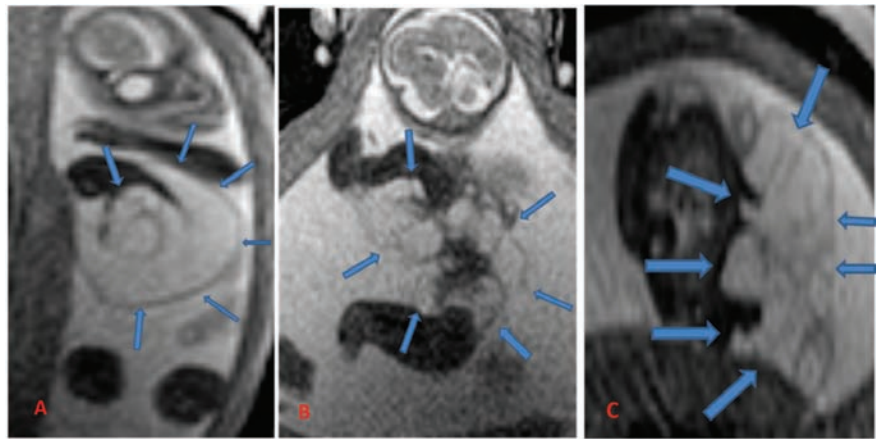


Figure 2. Antenatal T2 weighted MR images of multiculer giant hiperintens cystic higroma (arrow) which arise from right arm, axilla, pectoral region and right thorax. (A) A coronal oblique section which includes bilateral upper extremity and low extremity, (B) a parasagittal cross section at the level of right arm and leg, (C) an axial image at the level of axilla.

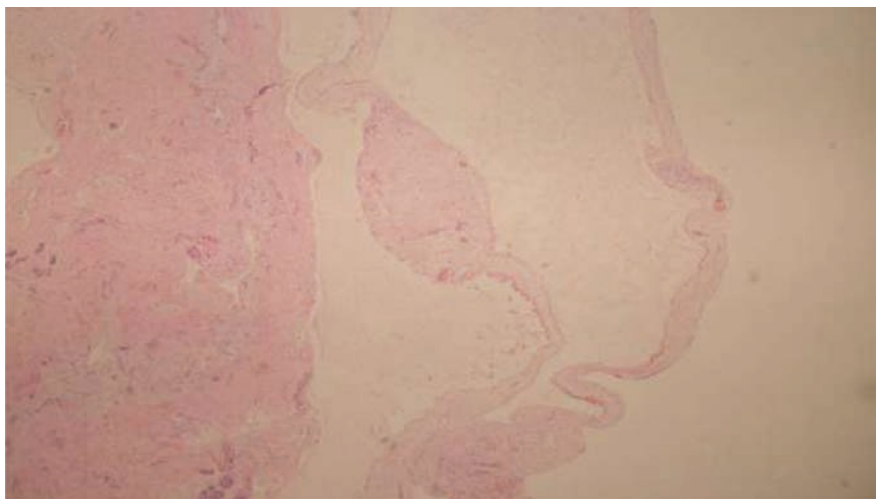


Figure 3. Histological examination demonstrated lymphatic endothelium lining cyst wall at the surface and cystic dilatated lymphatic vessels at the subcutan tissue.

tion was cardiac abnormalities (in 7 cases, 20%) in nonseptated CH cases and nonimmune hydrops (in 12 cases, 54.5%) in septated CH cases.<sup>24</sup>

Sixty-four cases of CH in 8524 patients were detected (0.75%). Thirty-nine (60.9%) were of non-septated and 25 (39.1%) were of septated CH. Chromosomal abnormalities were present in 25 (39.1%). The most common abnormality in non-septated CH was trisomy 21 (27.8%), and that in septated CH was Turner syndrome (23.8%). Nine of the infants were live-born and were subsequently followed up but, two had cardiac pathology and died after cardiac operation, two others were diagnosed with axillary CH, had an excellent prognosis. Only three cases had, at birth and in the follow-up period, no complications. It was indicated that the CH is highly correlated with adverse perinatal outcome.<sup>25</sup>

Previously, a large multicenter study reported that there were 134 cases of CH among 38,167 screened patients (1 in 285). Chromosomal abnormalities were diagnosed in 67 (51%), including 25 trisomy-21, 19 Turner syndrome, 13 trisomy-18, and 10 others. Major structural fetal malformations (primarily cardiac and skeletal) were diagnosed in 22 of the remaining 65 cases (34%). Overall, survival with normal pediatric outcome was confirmed in 17% of cases (22 of 132). The CH has 5-fold, 12-fold, and 6-fold increased risk of aneuploidy, cardiac malformation, and perinatal death, respectively.<sup>26</sup> Chromosomal abnormalities were found 52.7% (38/72) in 72 fetuses who had detected CH at first trimester screening and, including 14 cases (36.8%) of Down syndrome. A total of 34 chromosomally normal pregnancies ended with 18 live births (52.9%), with no visible serious structural abnormalities. The 18 live-born infants were followed up for 17-98 months. Sixteen infants developed normally, while 1 developed Noonan's syndrome and 1 had a urinary tract abnormality. These data suggest that the prognosis of fetal CH detected during the first trimester is poor.<sup>27</sup>

Axillary CH is rarely reported and determined often by sonographically in midgestation.<sup>16,17</sup> Axillothoracic CH may be diagnosed during routine antenatal ultrasound follow-up. These are the masses simple or multicystic structured, hypoechogenic, with thin septa, and they may contain solid components.<sup>28,29</sup> Generally, the vascular flow isn't seen in the Doppler ultrasound examination. MRI is important in determining the characteristics of the tissue and tumor extent.<sup>30</sup> Axillary lymphangiomas account for approximately 10% of all lymphangiomas. Very few have been reported as diagnosed prenatally.<sup>6</sup> A few cases have been reported of shoulder dystocia caused by axillary lymphangioma diagnosed after delivery.<sup>7</sup> McCoy *et al.* reported, a child with bilateral axillary CH that were prenatally diagnosed at

18th week of gestation.<sup>31</sup>

Traditionally, ultrasonography has been used as the primary screening method for prenatal diagnosis, especially in cervical lesions. CT is avoided because of issues relating to radiation exposure to mother and foetus. MRI may play a role in prenatal imaging, as amongst other things it provides early comprehensive information about both the anatomy and the extension of the tumour.<sup>32</sup>

Obstetric prognosis in CH cases depends on the volume and localization of the mass. Fetal prognosis is determined by the degree of chromosomal anomalies and hydrops.<sup>33</sup> With serial ultrasound follow-up, the size of the mass is followed and for the masses that may develop dystocia so section is recommended. In isolated small masses, the standard obstetric treatment is recommended. In larger masses that may prevent the birth, intrauterine cyst aspiration may be carried out and this process also can be carried out for intrauterine diagnosis.<sup>28</sup> Generally, CH has no risk of recurrence in subsequent pregnancies. But recurrent familial CH cases have been reported in the literature.<sup>34</sup> In prenatal differential diagnosis of axillothoracic CH, simple cysts, hemangiomas, branchial cleft cysts, hemangiolympangiomas, lymphocele, teratomas, hemangioendotheliomas, ectopia cordis, amniotic band syndrome, Klippel-Trauray syndrome should be considered.<sup>35</sup>

These tumors do not show spontaneous recovery after childbirth, they are treated surgically with excision. Infiltrative and extensive masses are difficult to be extracted surgically. If total surgical excision isn't carried out, the recurrence may be seen. Other treatment options include injections of the sclerosing agent, CO<sub>2</sub> laser therapy and radiotherapy.<sup>12,35</sup> When the cyst is aspirated with an injector, it may lead to the rapid fluid accumulation and it isn't suggested as it may cause infection.<sup>12</sup> For the treatment of CH, the new modality is the use of sclerosing agents.<sup>36</sup> For the first time in 1986, by Ogita *et al.* proposed treatment of intralesional injection of OK432.<sup>37</sup> OK432 is a sclerosing agent obtained from derivative of low virulence *Streptococcus pyogenes*.<sup>38</sup> OK432 activates white blood cells; increases cytokines (such as TNF) improves endothelial permeability and improves the lymphatic drainage from the cystic area.<sup>39</sup> OK432 has been accepted as safe and effective alternative treatment.<sup>39</sup> It may be used as a primary treatment and after recurrent CH or partial surgical treatment. The success of the treatment of multicystic CH is low but it is better in simple cysts. It has no effect on post-surgical treatment after OK432 treatment. As it doesn't cause the formation of fibrosis in surgical excision area, it does not affect the surgery after the injection.<sup>35</sup> Recently, intrauterine OK432 treatments have been reported.<sup>36</sup>

The fetal CH carries high risk of aneuploidy and fetal malformations. Patients that have been diagnosed with CH in antenatal follow-ups should be assessed in terms of other anomalies, fetal karyotyping should be done and the patient should be monitored for fetal hydrops. The cyst size and structure, septa or nonseptated, localization and invasion of cyst are important prognostic factors. The axillary localization and spontaneous resolution of septa are good prognostic factors. The birth should be planned in a multidisciplinary hospital and as neonatal resuscitation could be needed, pediatricians should be consulted.

## References

- Pijpers L, Reuss A, Stewart PA, et al. Fetal cystic hygroma: prenatal diagnosis and management. *Obstet Gynecol* 1988;72:223-24.
- Cohen MM, Schwartz S, Schwartz MF, et al. Antenatal detection of cystic hygroma. *Obstet Gynecol Surv* 1989;44:481-90.
- BrumWeld CG, Wenstrom KD, Davis RO, et al. Second trimester cystic hygroma: prognosis of septated and nonseptated lesions. *Obstet Gynecol* 1996;88:979-82.
- Glasson MJ, Taylor SF. Cervical, cervicomedial and intrathoracic lymphangioma. *Prog Pediatr Surg* 1991;27:62-83.
- Gallagher PG, Mahoney MJ, Gosche JR. Cystic Hygroma in the fetus and newborn. *Semin Perinatol* 1999;23:341-56.
- Bronshtein M, Rottem S, Yoffe N, Blumenfeld Z. First-trimester and early second-trimester diagnosis of nuchal cystic hygroma by transvaginal sonography: diverse prognosis of the septated from the nonseptated lesion. *Am J Obstet Gynecol* 1989; 161:78-82.
- Bronshtein M, Bar-Hava I, Blumenfeld I, et al. The difference between septated and nonseptated nuchal cystic hygroma in the early second trimester. *Obstet Gynecol* 1993;81:683-7.
- Bernstein HS, Filly RA, Goldberg JD, Golbus MS. Prognosis of fetuses with a cystic hygroma. *Prenat Diagn* 1991;11:349-55.
- Katz VL, Watson WJ, Thorp JM Jr, et al. Prenatal sonographic findings of massive lower extremity lymphangioma. *Am J Perinatol* 1992;9:127-9.
- Singh S, Baboo ML, Pathak IC. Cystic lymphangioma in children: report of 32 cases including lesions at rare sites. *Surgery* 1971;69:947-51.
- Allanson JE. Lymphangiomyoma. In: Stevenson RE, Hall JG, Goodman RM, et al. *Human malformations and related anomalies*. Vol 2. Oxford: Oxford University



- Press; 1993. pp. 293-305.
12. S Naz Masood, Muhammad Faraz Masood. Case report of fetal axillo-thoraco-abdominal cystic hygroma. *Arch Gynecol Obstet* 2010;281:111-15.
  13. Langer JC, Fitzgerald PG, Desa D, et al. Cervical cystic hygroma in the fetus: clinical spectrum and outcome. *J Pediatr Surg* 1990;25:58-62.
  14. Thomas RL. Prenatal diagnosis of giant cystic hygroma: prognosis, counseling, and management: case presentation and review of the recent literature. *Prenat Diagn* 1992;12:919-23.
  15. Tanriverdi HA, Hendrik HJ, Ertan AK, et al. Hygroma colli cysticum: prenatal diagnosis and prognosis. *Am J Perinatol* 2001; 18:415-20.
  16. Panditt SK, Rattan KN, Budhirajfl S, Sofanki RS. Cystic lymphangioma with special reference to rare sites. *Indian J Pediatr* 2000;67:339-41.
  17. Zanotti SD, LaRusso S, Coulson C. Prenatal sonographic diagnosis of axillary cystic lymphangiomas. *J Clin Ultrasound* 2001;29:112-5.
  18. Song TB, Kim CH, Kim SM, et al. Fetal axillary cystic hygroma detected by prenatal ultrasonography: a case report. *J Korean Med Sci* 2002;17:400-2.
  19. Bossert T, Gummert JF, Mohr FW. Giant cystic lymphangioma of the mediastinum. *Eur J Cardiothorac Surg* 2002;21:340.
  20. Nakazato Y, Ohno Y, Nakata Y, et al. Cystic lymphangioma of the mediastinum. *Am Heart J* 1995;129:406-9.
  21. Sheth S, Nussbaum AR, Hutchins GM, Sanders RC. Cystic hygromas in children: sonographic-pathologic correlation. *Radiology* 1987;162:821-4.
  22. Fergal D, Malone, MD, Robert H, et al. First-Trimester Septated Cystic Hygroma. *Obstet Gynecol* 2005;106:288-94.
  23. Alpman A, Cogulu O, Akgul M, et al. Prenatally diagnosed Turner syndrome and cystic hygroma: incidence and reasons for referrals. *Fetal Diagn Ther* 2009;25:58-61.
  24. Gedikbasi A, Gul A, Sargin A, Ceylan Y. Cystic hygroma and lymphangioma: associated findings, perinatal outcome and prognostic factors in live-born infants. *Arch Gynecol Obstet* 2007;276:491-8.
  25. Gedikbasi A, Oztarhan K, Aslan G, et al. Multidisciplinary approach in cystic hygroma: prenatal diagnosis, outcome, and postnatal follow-up. *Pediatr Int* 2009;51:670-7.
  26. Malone FD, Ball RH, Nyberg DA, et al. First-trimester septated cystic hygroma: prevalence, natural history, and pediatric outcome. *Obstet Gynecol* 2005;106:288-94.
  27. Graesslin O, Derniaux E, Alanio E, et al. Characteristics and outcome of fetal cystic hygroma diagnosed in the first trimester. *Acta Obstet Gynecol Scand* 2007;86:1442-6.
  28. Senoh D, Hanaoka U, Tanaka Y et al. Antenatal ultrasonographic features of fetal giant hemangiolympangioma. *Ultrasound Obstet Gynecol* 2001;17:252-4.
  29. Rosati P, Guariglia L. Prognostic value of ultrasound findings of fetal cystic hygroma detected in early pregnancy by transvaginal sonography. *Ultrasound Obstet Gynecol* 2000;16:245.
  30. Rasidaki M, Sifakis S, Vardaki E, et al. Prenatal diagnosis of a fetal chest wall cystic lymphangioma using ultrasonography and MRI: a case report with literature review. *Fetal Diagn Ther* 2005;20:504-7.
  31. McCoy MC, Kuller JA, Chescheir NC, et al. Prenatal diagnosis and management of massive bilateral axillary cystic lymphangioma. *Obstet Gynecol* 1995;85:853-6.
  32. Caire JT, Ramus RM, Magee KP, et al. MRI of fetal genitourinary anomalies. *AJR Am J Roentgenol* 2003;181:1381-5.
  33. Gedikbasi A, Gul A, Sargin A, Ceylan Y. Cystic hygroma and lymphangioma: associated findings, perinatal outcome and prognostic factors in live-born infants. *Arch Gynecol Obstet* 2007;276:491-8.
  34. Tricoire J, Sarramon MF, Rolland M, Lefort G. Familial cystic hygroma. Report of 8 cases in 3 families. *Genet Couns* 1993;4: 265-9.
  35. Atalar MH, Cetin A, Kelkit S, Buyukayhan D. Giant fetal axillo-thoracic cystic hygroma associated with ipsilateral foot anomalies. *Pediatr Int* 2006;48:634-7.
  36. Sasaki Y, Chiba Y. Successful intrauterine treatment of cystic hygroma colli using OK-432. A case report. *Fetal Diagn Ther* 2003;8:391-6.
  37. Ogita S, Tsuto T, Nakamura K, et al. OK-432 therapy for lymphangioma in children: why and how does it work? *J Pediatr Surg* 1996;31:477-80.
  38. Smith RJ, Burke DK, Sato Y, et al. OK-432 therapy for lymphangiomas. *Arch Otolaryngol Head Neck Surg* 1996;122: 1195-9.
  39. Schmidt B, Schimpl G, Hollwarth ME. OK-432 therapy of lymphangiomas in children. *Eur J Pediatr* 1996;155:649-52.