



Tuberculous infection in a total knee replacement performed for medial tibial plateau fracture : A case report

Anish P. KADAKIA, Rhodri WILLIAMS, Victor G. LANGKAMER

From the Weston General Hospital, Weston-super-Mare, United Kingdom

There has been increasing interest in performing acute total knee replacement for periarticular knee fractures in elderly osteoporotic patients. This is comparable to treating femoral neck fractures with arthroplasty. We present a case of tuberculous infection in a primary total knee replacement performed for a medial tibial condyle fracture, in an 85-year-old Caucasian female with a previously asymptomatic knee. The incidence of tuberculosis is gradually increasing. We highlight the problem with musculoskeletal tuberculosis in relation to the delay in diagnosis and subsequent initiation of treatment.

Keywords : tuberculosis ; total knee replacement ; periarticular knee fracture.

CASE REPORT

An 85-year-old previously mobile and independent Caucasian lady presented to the accident and emergency department two weeks after a fall onto her left knee from standing height. She had initially continued to mobilise but the discomfort and mobility in her left knee gradually worsened over the ensuing two weeks. Radiograph of her left knee performed on admission showed a Schatzker type IV tibial plateau fracture (fig 1).

Her chest radiograph showed evidence of previous scarring in the right apical lobe and she was asymptomatic. She denied having any chest infection including tuberculosis in the past. She also did not have any problems with that knee before the fall.

It was decided to perform a Waldemar Link (New Splint PLC, Hampshire. UK) Rotating Hinge total knee replacement. Operative findings revealed that the bone was “mushy” and porotic and hence specimens were sent for histopathology. This confirmed bone necrosis. There was no evidence of caseation, epitheloid cells or Langhans giant cells (fig 2).

The immediate postoperative period was complicated by a cellulitis and then a serous discharge from the lower end of the surgical wound. Her C-reactive protein, white cell count and erythrocyte sedimentation rate were elevated. The discharging fluid was sent for microbiological analysis, coagulase negative staphylococcus was isolated and she was started on Flucloxacillin and Benzylpenicillin. The cellulitis settled but she developed a chronic discharging sinus from the lower end of the wound. She was continued on the same antibiotics. Her inflammatory markers started falling over the next few weeks but the sinus kept discharging serous

- Anish P. Kadakia, MB BS, MRCS, Senior House Officer.
- Rhodri Williams, MB BS, MRCS, Senior House Officer.
- Victor G. Langkamer, MB BS, FRCS, Consultant.

Department of Orthopaedic Surgery, Weston General Hospital, Weston-super-Mare, United Kingdom.

Correspondence : Mr Anish Kadakia, 37 Barley Close, Glenfield, Leicester, LE3 8SB, United Kingdom.

E-mail : akadakia@rediffmail.com.

© 2007, Acta Orthopædica Belgica.

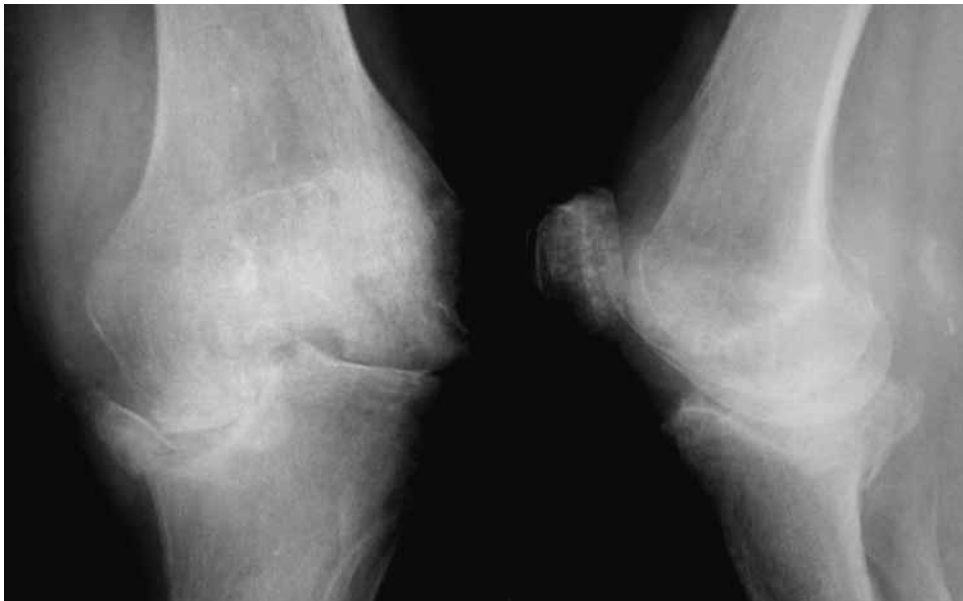


Fig. 1. — Preoperative radiograph left knee demonstrating 2 week old Schatzker IV fracture

fluid. The sinus was debrided and the specimen sent for culture and sensitivity. All the repeat specimens grew coagulase negative staphylococcus. During this time she had a painless range of knee motion from 0° to 100° and she was mobilising full weight bearing on the ward with the help of a walking frame. There was no radiological evidence of implant loosening. Antibiotics were stopped after 8 weeks and she was discharged from the hospital with regular dressings of the chronic sinus.

She was reviewed a month later with persistent discharging sinus and a painless range of knee motion (fig 3). She had developed an intractable cough and in view of the scarring on the chest radiograph, samples of her sputum were sent for culture and sensitivity including acid-fast bacilli (AFB) smears. Ziehl Nelson (ZN) stain of one of the samples was positive for AFB. The fluid from the sinus was also sent for AFB smears and one of the specimens demonstrated AFB. She was started on 4-drug anti-tuberculous treatment (ATT). The original bone specimen sent for histopathology at time of surgery was re-examined for AFB. ZN stain of the bone tissue showed AFB. While she was on the ward, on anti-tuberculous treatment, the sinus healed and her general condition improved. She was subsequently discharged from the hospital

with a maintenance dose of ATT. Her knee radiographs, throughout, did not show any evidence of loosening or lysis. On completion of 6 months of ATT, the sinus completely healed and she maintained a painless range of knee motion.

DISCUSSION

Wolfgang (14) first reported total knee replacement (TKR) for an intercondylar femoral fracture in a patient with rheumatoid arthritis. Subsequently, several authors have reported their experience of TKR for distal femur and proximal tibial fractures in elderly patients with osteoporosis (2,3,9-11,16). They have shown early rehabilitation and mobility in this patient group.

Tuberculosis (TB) is a serious disease of global importance, with the number of cases of tuberculosis notified in the UK each year increasing over the last 15 years. This is contributed by the HIV epidemic (1).

The infection in the knee in this case could have been (i) a preexisting lesion with a resultant tuberculous pathological fracture, (ii) a result of haematogenous spread from an asymptomatic pulmonary lesion or (iii) reactivation of latent disease in the knee following the trauma. Schatzker type IV

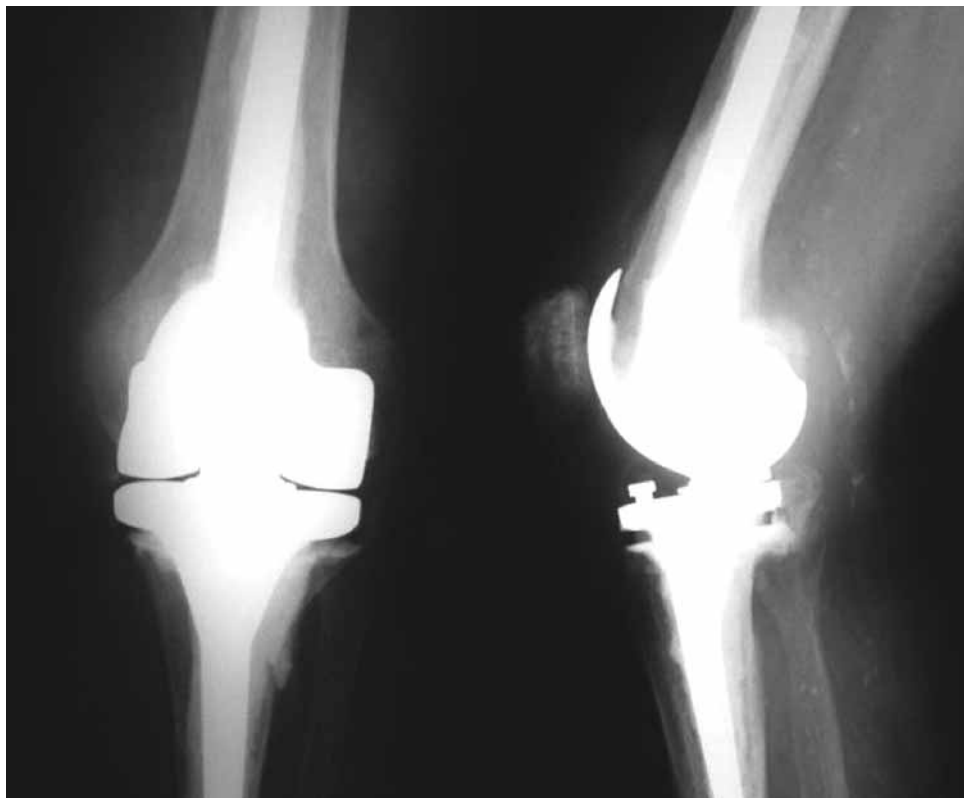

Fig. 2. — Postoperative radiograph demonstrating Waldemar Link Rotating Hinge TKR

fracture is an uncommon fracture especially in the elderly with a low-velocity injury. There were no preexisting symptoms in that knee. In view of the clinico-radiographic and operative findings, bone specimens were sent for histology but did not show obvious pathology. Retrospectively this specimen did show AFB which could have reached the fracture site at the time of or following the fracture. Radiographic findings of the chest on admission could have been as a result of a possible tuberculous affection in the past and the AFB could have been latent in the tibia and subsequently reactivated as a result of the trauma/surgery. Secondary contamination with coagulase negative staphylococcus further complicated the whole clinical picture and 'masked' the underlying tuberculous infection.

Osteoarticular TB of the knee is difficult to diagnose, because of its variable clinical picture and insidious nature (8). It is usually monoarticular and systemic signs or a history of pulmonary TB are seldom seen (13). Total knee replacement (TKR) is

occasionally performed on tuberculous joints which are misdiagnosed as having osteoarthritis. Tuberculous synovitis has been described as a great imitator (4). Frequent intra-articular injections of steroids may reportedly induce tuberculous arthritis (4).

This case, to our knowledge, is the first case report of TB in a total knee replacement performed for periarticular knee fracture. TKR following TB has been reported (5,7,12). Seven cases of TKR have also been reported in unsuspected TB of the knee (1,4,8,15). TKR in unsuspected TB of the knee can reactivate the disease and present diagnostic problems (8).

Patients who have recalcitrant infection should be investigated for TB. Staphylococcal superinfection can easily mask TB, further delaying diagnosis. Synovial histology, mycobacterial culture, and acid-fast bacilli smears together should confirm greater than 90% of infections (1). Extrapulmonary TB can develop in immunocompromised patients

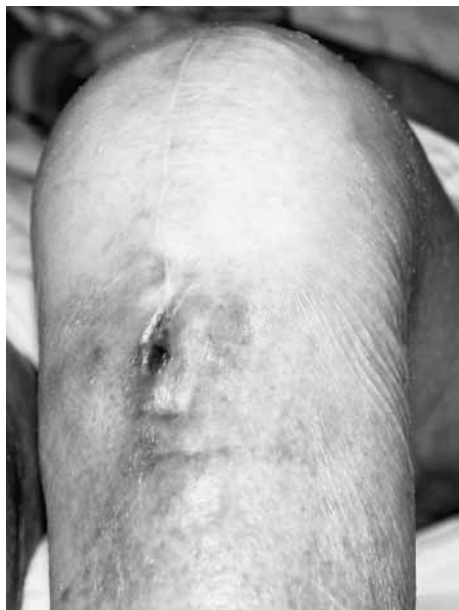

Fig. 3. — Chronic discharging tuberculous sinus over the knee

and this should be investigated in relevant cases (1).

Cured or quiescent TB of the knee can be treated with arthroplasty, which can provide good functional improvement but prophylactic ATT is indicated because of the risk of reactivation of the infection (5). Hardinge *et al* (6) have reported successful treatment of 21 cases of total hip replacement in old tuberculous hips without recourse to antibiotics.

CONCLUSION

This case demonstrates the insidious nature and the low index of suspicion in diagnosing tuberculous infection following TKR. The presence of a discharging sinus and absence of obvious inflammatory signs clinically should raise the probability of TB infection and appropriate investigation (the triad of AFB smears, mycobacterial culture and synovial histology) is recommended. This case emphasises the point that in the presence of unusual fracture pattern and also unusual operative findings, samples should be sent for both microbiological and histological assessment. In addition, as TB screening is not routinely performed we suggest that it should be requested specifically in suspi-

cious cases in light of the increasing incidence of TB worldwide.

REFERENCES

1. **Al-Shaikh R, Goodman SB.** Delayed-onset Mycobacterium tuberculosis infection with staphylococcal superinfection after total knee replacement. *Am J Orthop* 2003 ; 32 : 302-305.
2. **Appleton P, Moran M, Houshian S, Robinson CM.** Distal femoral fractures treated by hinged total knee replacement in elderly patients. *J Bone Joint Surg* 2006 ; 88-B : 1065-1070.
3. **Bell KM, Johnstone AJ, Court-Brown CM, Hughes SPF.** Primary knee arthroplasty for distal femoral fractures in elderly patients. *J Bone Joint Surg* 1992 ; 74-B : 400-402.
4. **Besser MI.** Total knee replacement in unsuspected tuberculosis of the joint. *Br Med J* 1980 ; 280 : 1434.
5. **Eskola A, Santavirta S, Konttinen YT et al.** Arthroplasty for old tuberculosis of the knee. *J Bone Joint Surg* 1988 ; 70-B : 767-769.
6. **Hardinge K, Cleary J, Charnley J.** Low-friction arthroplasty for healed septic and tuberculous arthritis. *J Bone Joint Surg* 1979 ; 61-B : 144-147.
7. **Kim YH.** Total knee arthroplasty for tuberculous arthritis. *J Bone Joint Surg* 1988 ; 70-A : 1322-1330.
8. **Marmor M, Parnes N, Dekel S.** Tuberculosis infection complicating total knee arthroplasty : report of 3 cases and review of the literature. *J Arthroplasty* 2004 ; 19 : 397-400.
9. **Nau T, Pfliegerl E, Erhart J, Vecsei V.** Primary total knee arthroplasty for periarticular fractures. *J Arthroplasty* 2003 ; 18 : 968-971.
10. **Pearse EO, Klass B, Bendall SP, Railton GT.** Stanmore total knee replacement versus internal fixation for supracondylar fractures of the distal femur in elderly patients. *Injury* 2005 ; 36 : 163-168.
11. **Rosen AL, Strauss E.** Primary total knee arthroplasty for complex distal femur fractures in elderly patients. *Clin Orthop* 2004 ; 425 : 101-105.
12. **Su JY, Huang TL, Lin SY.** Total knee arthroplasty in tuberculous arthritis. *Clin Orthop* 1996 ; 323 : 181-187.
13. **Watts HG, Lifeso RM.** Tuberculosis of bones and joints. *J Bone Joint Surg* 1996 ; 78-A : 288-298.
14. **Wolfgang GL.** Primary total knee arthroplasty for intercondylar fracture of the femur in a rheumatoid arthritic patient : a case report. *Clin Orthop* 1982 ; 171 : 80-82.
15. **Wray CC, Roy S.** Arthroplasty in tuberculosis of the knee : Two cases of missed diagnosis. *Acta Orthop Scand* 1987 ; 58 : 296-298.
16. **Yoshino N, Takai S, Watanabe Y et al.** Primary total knee arthroplasty for supracondylar/condylar femoral fracture in osteoarthritic knees. *J Arthroplasty* 2001 ; 16 : 471-475.