

Research Article

MRI detected prevalence of abnormalities in patients of knee pain

Ritu Mehta^{1*}, Neha Singh Agrahari¹, Sanjeev Agarwal², Abhishek Bhargava¹

¹Department of Radiodiagnosis, ²Department of Surgery, Geetanjali Medical College and Hospital, Udaipur, Rajasthan, India

Received: 04 July 2015

Revised: 14 July 2015

Accepted: 06 August 2015

***Correspondence:**

Dr. Ritu Mehta,

E-mail: sanjuritu@gmail.com

Copyright: © the author(s), publisher and licensee Medip Academy. This is an open-access article distributed under the terms of the Creative Commons Attribution Non-Commercial License, which permits unrestricted non-commercial use, distribution, and reproduction in any medium, provided the original work is properly cited.

ABSTRACT

Background: In patients of knee pain diagnosis has utmost important for treatment and to avoid unnecessary surgery. MRI is a non-invasive procedure in evaluation of knee joint. So this study was planned find out the prevalence of abnormalities detected by MRI in patients of knee pain.

Methods: Fifty patient of knee pain were examined after taking permission from institutional ethics committee by using Siemens Avanto MR machine with a superconducting magnet and field strength of 1.5 tesla using dedicated knee coil (Flex), which were referred from department of Orthopedics & Rheumatology.

Results: In this present study 72% patients were males and 28% patients females and their ages ranging from (11-80) years. Knee pain was found common in age group 31-40 years. Menisci lesions (44%) were more common as compared to ligament lesions (14%) in patients of knee pain. Osteoarthritis was found in 40 % of patients of knee pain. Joint effusion and marrow edema was found with incidence of 74% and 62% respectively. 4% patients were suffering from intraarticular tumors.

Conclusions: Knee pain can occur at any stage of life due to various causative factors. MRI can demonstrate the exact nature and extent of bony as well as soft tissue abnormality. This has increase the use of MRI in evaluation of patients of knee pain.

Keywords: MRI, Knee pain, Menisci, Osteoarthritis

INTRODUCTION

Knee problems may be responsible for much of musculoskeletal disability in elderly persons. The prevalence of abnormalities increased with age, as might be expected. Knee pain is considered as most frequent symptom related to knee problems which brings patient to the hospital. Knee pain and related symptoms may come as a result of damage to one or more of the soft tissue structures that stabilize and cushion the knee joint, including the ligaments, muscles, tendons, and menisci or due to non-traumatic injury like infection, inflammation etc.¹ Presentation of knee pain in a middle-aged or older patient often leads to an x-ray of the knee but MRI is being used in clinical practice to facilitate diagnostic

decisions. The potential for MRI to be more sensitive to earlier disease, detecting change, and the capacity of this technology to visualize joint structural changes beyond gross changes in bone and in the joint space, has resulted in great interest in the use of MRI for assessing diagnostic status, disease severity and monitoring progression.^{2,3} MRI visualizes most components of the joint, including articular cartilage, menisci, intra-articular ligaments, synovium, bone marrow, subchondral cysts, and other periarticular and intra-articular lesions that are not detectable by radiography.⁴ Various studies have reported structural changes in people with knee osteoarthritis by radiographic findings. Very few data are available regarding what structural changes are present in patients of knee pain and also this type of study was not

conducted in our institute. So, this study was planned to find out the prevalence of abnormalities detected by MRI in patients of knee pain which will guide the physician in making treatment strategies according to diagnosis.

METHODS

This prospective study was carried out for a period of six month after taking the permission from institutional ethics committee. A total of 50 patients referred to the department of Radio- diagnosis from department of Orthopedic and Rheumatology with complaints of knee pain were recruited. Patients’ socio-demographic data, clinical history and physical examination findings were recorded after taking informed consent to correlate the findings. The patients of knee trauma and who had no complaint of knee pain were not included in this study.

Procedure:

MRI acquisition knees were imaged by using Siemens Avanto MR machine with a superconducting magnet and field strength of 1.5 tesla using dedicated knee coil (Flex).

Each examination consisted of the following: coronal intermediate-weighted (repetition time msec/echo time msec, 2200/20) and T2- weighted (2200/80) dual spin-echo images (number of signals acquired, two; section thickness, 5 mm; intersection gap, 0.5 mm; field of view, 160 mm; acquisition matrix, 205×256; and number of sections, 18), sagittal intermediate-weighted (2200/20) and T2- weighted 4 (2200/80) dual spin-echo images (number of signals acquired, two; section thickness, 4 mm; intersection gap, 0.4 mm; field of view, 160 mm; acquisition matrix, 205×256; and number of sections, 20), sagittal three dimensional T1- weighted spoiled gradient-echo frequency-selective fat suppressed images (46/2.5; one signal acquired; flip angle, 40°; section thickness, 3 mm; section overlap, 1.5 mm; no gap; field of view, 180 mm; acquisition matrix, 205×256; and number of sections, 80), and transverse intermediate weighted (2500/7.1) and T2-weighted (2500/40) turbo spin echo fat-suppressed images (number of signals acquired, two; section thickness, 2 mm; no gap; field of view, 180 mm; acquisition matrix, 205×256; and number of sections, 62). Total acquisition time, which included the initial survey sequence, was 30 minutes. Protocol of examination was in line with European society of musculoskeletal radiology (ESSR). It starts with the patient in supine position and slightly externally rotates the foot by about 10-15 degrees to stretch the anterior cruciate ligament. Pack some cushions around the knee to help it stay motion free. A small cushion under the ankle helps to keep the leg straight. Evaluation of the knee including the patello-femoral joint, medial and lateral compartments as well as related tendons and ligaments and the popliteal fossa is performed with a high resolution proton density sequence acquired in 3 planes: Axial, Sagittal and Coronal. Evaluation of bone marrow for contusion

requires a T2 fat saturation sequence in either coronal or sagittal planes. If the patient has a suspicious mass then T1 fat saturation images are helping to determine if the mass is benign or malignant and better delineate its full extent. Obtained MRI images were diagnosed by an experienced musculoskeletal radiologist for the presence of ligament injury, tear, strain and laxity, as well as menisci degeneration and tear, joint effusion, subchondral and bone marrow edema, bony contusion, bursitis, baker cyst and tumor were noted in all patients.

Statistical analysis:

Data were expressed in percentages in comparison tables and graphs. Statistical analysis was performed using Microsoft Excel Software and the standard Statistical Package for the Social Sciences version 15 for windows.

RESULTS

Total 50 patients were recruited with in a study period of six month. MRI of knee was conducted in patients who were complaining knee pain. Of these 50 patients 36 (72%) were male and 14 (28%) were female, with male to female ratio of 2.6:1. Mean age of the patients was 42 years (range 11 to 80 years). They were classified into age groups and out of these groups 12 were found to be in age group between 31-40 years. In this age group 8 were male and 4 were female patients (Table 1).

Table 1: Distribution of patients according to age group and sex.

Age group	Males	Females	Number of patients (Total 50)	Percentage
<10	0	0	0	0
11-20	04	01	05	10
21-30	09	01	10	20
31-40	08	04	12	24
41-50	08	03	11	22
51-60	05	04	09	18
61-70	02	0	02	4
71-80	0	01	01	2

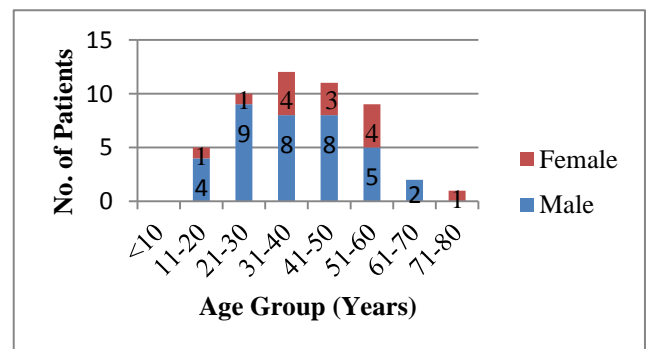


Figure 1: Demographic profile of patients including age & sex (n=50).

Table 2: Most common knee pathologies detected by MRI in patients of knee pain and their distribution with sex.

Knee pathologies	Male	Female	Total patients (50)
Joint effusion	25	12	37 (74%)
Bone marrow edema	22	9	31 (62%)
Meniscal lesions	15	7	22 (44%)
Osteoarthritis	10	10	20 (40%)
Ligament lesions	4	3	7 (14%)
Baker's cyst	4	2	6 (12%)
Ganglion cyst	4	1	5 (10%)
Subchondral edema	1	1	2 (4%)
Tumor	1	1	2 (4%)
Pateller Subluxation	1	1	2(4%)

Table 3: Types of meniscal lesion detected by MRI in patients of knee pain.

Meniscal degeneration (Grade 1)	7
Meniscal degeneration (Grade 2)	15
Total	22

Joint effusion was most frequently found knee pathology constituting 74% in patients of knee pain followed marrow edema (62%), meniscal lesion (44%), and osteoarthritis (40%). Osteomyelitis, simple bone cyst, bone infarct and chondromalacia patellae were least common constituting 2% incidence of each (Table 2). Meniscal injury (44%) was found more common in patients of knee pain as compared to ligament injury. Table 3 shows different grades of meniscal lesions in patients of knee pain.

DISCUSSION

MRI is a valuable tool in the evaluation and management of patients of knee pain and it has been established as an effective, noninvasive test for identifying different knee pathologies.⁵ MRI affects the treatment of patients with knee problems because it shows entire lesion in multiple planes so that exact diagnosis and treatment can be planned. Studies have shown that surgery of the knee is less frequently performed after MRI than initially planned before MRI.^{6,7}

In this study fifty patients of knee pain were evaluated by MRI. Knee pain was found to be common in males (72%) as compared to females. Similar results were reported in other studies too.^{8,9} This could be because of more activities in young males during sports as compared to females and they are also more prone to accidents. In our study most affected age group was 31-40 years. This supports the reasoning that it is more common in young

adult. One study has reported more females as compared to male. We could not find exact reason for that.

Joint effusion was found to be most frequent associated lesion constituting 74%. In another study joint infusion was reported in 63.8%.⁸ Higher percentage of joint effusion in our study and other study too could be due to more synovial reactions in patients of knee pain. Bone marrow edema was also found in 62% of patients of knee pain. This much high percentage of marrow edema in patients of knee pain may be due to non-specific finding which is simply fluid accumulation within the bone when there is any insult to bone. A recent systematic review reported that bone marrow lesions and effusion were associated with knee pain.¹⁰

Menisci lesions were found in 44% patients. Depending on the patient's age, a prevalence of meniscal lesion up to 36% has been reported.¹¹ In our study most of the menisci lesions was found in males. Similar results have reported by other studies too of higher incidence of menisci injuries in male.^{12,13}

Grade I/II injury (signal changes) are common in our study because these are mostly occur with degeneration changes in knee joint and more common in 3rd and 4th decade¹⁴ and in our study most of the patients were in age between 31-50. A meta-analysis based on 22 studies described an overall sensitivity of 88% and specificity of 94% for detecting meniscal lesions with different grades.¹⁵ This would avoid unnecessary arthroscopic examination.¹

Osteoarthritis was found in 40 % of patients of knee pain with equal prevalence in both male and female. Baker's cyst which is mostly present with osteoarthritis patient was found in 12% in patients. Similar incidence of baker's cyst has been reported by other study conducted by Nasir A.⁹ In other studies incidence of osteoarthritis was found more in females and age above 50. The prevalence of osteoarthritis varies greatly depending on the definition used, age, sex and geographical area studied.^{16,17}

Difference in our study could be due to more patients in age group 21-50 years. MRI is an excellent tool for diagnosis of intraarticular tumors which in our study shows 4% incidence. MRI is accurate, noninvasive technique for evaluating the structures of the knee, marrow space, synovium and periarticular soft tissue concerning the knee.^{18,19}

To conclude, knee pain can occur at any stage of life due to various causative factors. Most of the patients in our study found to be males. MRI gives the noninvasive diagnosis to the patients for their appropriate treatment. This has increase the use of MRI in evaluation of patients of knee pain.

Funding: No funding sources

Conflict of interest: None declared

Ethical approval: Approved by Institutional Ethics Committee

REFERENCES

1. Yadav R, Kachewar SG. Role of MRI in evaluation of painful knee. *Int J Med Res Health Sci.* 2014;3(1):84-7.
2. Guermazi A, Burstein D, Conaghan P, Eckstein F, Hellio Le Graverand-Gastineau MP, Keen H, et al. Imaging in osteoarthritis. *Rheum Dis Clin North Am* 2008;34:645e87.
3. Hunter D, Hellio Le Graverand M, Eckstein F. Radiologic markers of osteoarthritis progression. *Curr Opin Rheumatol.* 2009;21:110-7.
4. Guermazi A, Roemer FW, Hayashi D. Imaging of osteoarthritis: update from a radiological perspective. *Curr Opin Rheumatol.* 2011;23:484-91.
5. Pompan DC. Reassessing the role of MRI in evaluation of knee pain. *American Family physician.* 2012;85(3):224.
6. Mackenzie R, Dixon AK, Keene GS, Hollingworth W, Lomas DJ, Villar RN. Magnetic resonance imaging of the knee: assessment of effectiveness. *Clin Radiol* 1996;51:245-50.
7. Maurer EJ, Kaplan PA, Dussault RG, et al. Acutely injured knee: effect of MR imaging on diagnostic thinking and therapeutic decisions. *Radiology* 1997;204:799-805.
8. Mansour MAM, Ahmed RA, Ibrahim A, Elhoussein N, Aljuaid SA. Magnetic resonance imaging diagnostic procedures for knee joint injuries at taif hospital, Saudi Arabia. *IOSR Journal of Nursing and Health Science.* 2015;4(2):37-46.
9. Nasir A. The role of magnetic resonance imaging in the knee joint injuries, international research journal of medical sciences. 2013;1(5):1-7.
10. Yusuf E, Kortekaas MC, Watt I, Huizinga TW, Kloppenburg M. Do knee abnormalities visualised on MRI explain knee pain in knee osteoarthritis? A systematic review. *Ann Rheum Dis.* 2011;70:60-7.
11. Boden SD, Davis DO, Dina TS, et al. A prospective and blinded investigation of magnetic resonance imaging of the knee: abnormal findings in asymptomatic subjects. *Clin Orthop.* 1992;282:177-85.
12. Nikolaou VS, Chronopoulos E, Savvidou C et al. MRI efficacy in diagnosing internal lesions of the knee: a retrospective analysis. *J Trauma Manag Outcomes.* 2008;2:4.
13. Khanda GE, Akhtar W, Ahsan H, Ahmad N. Assessment of menisci and ligamentous injuries of the knee on magnetic resonance imaging: correlation with arthroscopy. *J Pak Med Assoc.* 2008;58:537-40.
14. Stoller DW, Martin C, Crues JV 3rd, Kaplan L, Mink JH. Menisci tears: pathologic correlation with MR imaging. *Radiology* 1987;163(3):731-5.
15. Mackenzie R, Palmer CR, Lomas DJ, Dixon AK. Magnetic resonance imaging of the knee: diagnostic performance studies. *Clin Radiol* 1996;51:251-7.
16. Litwic A, Edwards M, Dennison E, Cooper C. Epidemiology and Burden of Osteoarthritis. *Br Med Bull.* 2013;105:185-99.
17. Heidari B. Knee osteoarthritis prevalence, risk factors, pathogenesis and features: Part I. *Caspian J Intern Med.* 2011; 2(2): 205-12.
18. Kachewar SG, Kulkarni DS. Distant perijoint calcifications: sequel of non-traumatic brain injury-a review and case report. *Journal of Clinical and Diagnostic Research* 2013;7:2606-9.
19. Kachewar SG, Singh H. Perigenicular Heterotopic Ossification: A rare sequelae of non-traumatic brain injury. *Nepal Journal of Neurosciences.* 2010;1:21-3.

Cite this article as: Mehta R, Agrahari NS, Agarwal S, Bhargava A. MRI detected prevalence of abnormalities in patients of knee pain. *Int J Res Med Sci* 2015;3:2572-5.