Check for updates

CASE REPORT

Case Report: Traumatic vein of Labbé hemorrhagic infarction - a distinct neurosurgical entity [version 1; referees: 1 approved with reservations, 1 not approved]

Sunil Munakomi , Bijoy Kumar

Department of Neurosurgery, College of Medical Sciences, Chitwan, Bharatpur, 44207, Nepal

v1 **First published:** 19 Aug 2015, **4**:586 (doi: 10.12688/f1000research.6910.1)
Latest published: 19 Aug 2015, **4**:586 (doi: 10.12688/f1000research.6910.1)

Abstract

Traumatic vein of Labbé haemorrhagic infarction is a distinct neurosurgical entity which requires special attention due to the important nature of the area it drains and its higher propensity for early uncal herniation. Herein we discuss the case of a 55 year-old male presenting with altered sensorium following a road traffic accident. His computerized tomogram (CT) head was suggestive of traumatic vein of Labbé haemorrhagic infarction which was subsequently confirmed by magnetic resonance (MR) venography. Due to impending herniation, he underwent urgent craniotomy and evacuation of hematoma.The patient made an uneventful recovery and was subsequently discharged home.This diagnosis should always be kept in mind for a patient with petrous bone fracture, transverse sinus thrombosis and hematoma in the mid and posterior temporal lobe.

Open Peer Review

Referee Status: ? ✗

	Invited Referees 1	2
version 1 published 19 Aug 2015	? report	✗ report

1 **Carlos Bagley**, Duke University School of Medicine USA

2 **Hazem Al-Khawaja**, Erasmus University Medical Center Netherlands

Discuss this article

Comments (0)

Corresponding author: Sunil Munakomi (sunilmunakomi@gmail.com)

How to cite this article: Munakomi S and Kumar B. **Case Report: Traumatic vein of Labbé hemorrhagic infarction - a distinct neurosurgical entity [version 1; referees: 1 approved with reservations, 1 not approved]** *F1000Research* 2015, **4**:586 (doi: 10.12688/f1000research.6910.1)

Grant information: The author(s) declared that no grants were involved in supporting this work.

Competing interests: The authors declared no competing interests.

First published: 19 Aug 2015, **4**:586 (doi: 10.12688/f1000research.6910.1)

Introduction

Dural venous sinus thrombosis after blunt head trauma has been reported in few case series[1–6]. Only a few studies have been done on outcome following traumatic vein of Labbé haemorrhagic infarction[7]. It is an important neurosurgical entity because of the involvement of the area that it drains in language comprehension and processing, as well as possessing a higher propensity for causing early uncal herniation with a sometimes fatal outcome[8–10]. As such, stringent monitoring of the patients and early surgical evacuation if required is the key to the successful management of this condition. One of the important differential diagnoses for vein of Labbé infarction is traumatic temporal artery damage wherein damage to the medial temporal region including the insular territory is also seen. Another entity to be excluded is transverse sinus thrombosis. This case highlights the importance of close observation of patients with petrous bone fracture and transverse sinus thrombosis for evolving vein of Labbé haemorrhagic infarction and early uncal herniation. There have only been a few studies highlighting this clinical entity and the cumulative advice from these is the suggestion of performing cerebral venographic studies in suspected cases so as to make a timely and correct surgical decision.

Case report

A 55-year-old Nepalese male from a remote village in Nawalparasi, Nepal was brought to the emergency room after being hit by a moving car. Medical history turned up no significant past medical illnesses or surgical interventions. At the time of arrival, his Glasgow coma scale (GCS) was E3M5V4. Vital parameters like blood pressure (130/80), pulse rate (76/min), respiratory rate (23/min) and oxygen saturation (99% at room air) were within normal range. Both of his pupils were equally sized and equally reactive to light. A primary and secondary injury survey did not reveal other systemic injuries. An urgent head CT scan revealed the presence of a hyperdense lesion in the right temporal region with mild effacement of the ipsilateral ambient cisterns and widening of the cerebellopontine cisterns suggestive of early uncal herniation (Figure 1). We made the provisional diagnosis of traumatic vein of Labbé hemorrhagic infarction with traumatic contusions as the main differential diagnosis. Screening MR venography proved the findings of traumatic vein of Labbé haemorrhagic infarction through identification of the absence of vein of Labbé on the right side (Figure 2).

Due to the risk of imminent herniation, patient's relatives were counseled regarding the benefits and risks involved in the surgical management. After verbal and written consent, the patient was taken up for surgery. Fronto-temporo-parietal flap craniotomy was performed. Durotomy was done and the posterior temporal corticostomy with evacuation of the hematoma was undertaken. Brain was lax and pulsatile at the end of the procedure. Patient was extubated the following morning after a repeat CT showed resolution in the herniation effect without any untoward post-operative events. Patient was started on the antiepileptic Sodium Valproate (300 mg intravenously, every 8 hours) for seizure prophylaxis and was advised to continue on this regiment for at least 6 months. Patient showed remarkable improvement, attaining a GCS score of E4M5V5 but with deficits in the prosody of his speech, attributable to the involvement of his right temporal lobe. The patient was early ambulated after the second post-operative day so as to prevent

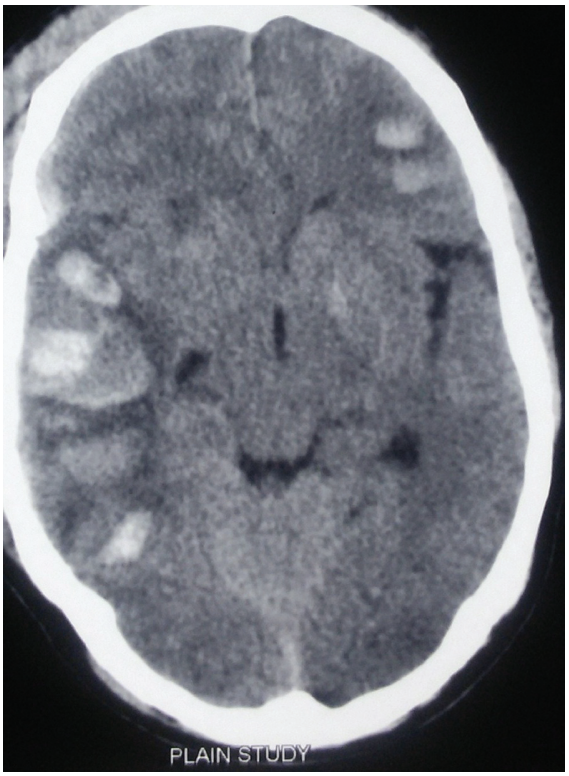

Figure 1. CT Brain showing hyperdense lesion in the right vein of Labbé territory with evidence of obliteration of ipsilateral ambient cistern.

Figure 2. MR Venography showing absence of vein of Labbé on the right side.

complications like chest infection and deep venous thrombosis due to prolonged immobilization. He was discharged home on the seventh post-operative day, after removal of his wound stitches, with the advice of taking the antiepileptic regularly. The patient was followed up in the outpatient clinic 3weeks later. Patient still had some deficits to prosody of his speech but language fluency and content were normal. Repeat CT showed complete resolution in hematoma and mass effects (Figure 3). Patient was advised to continue with the antiepileptic medication (Sodium Valproate 300mg via oral route three times daily) for 6 months.

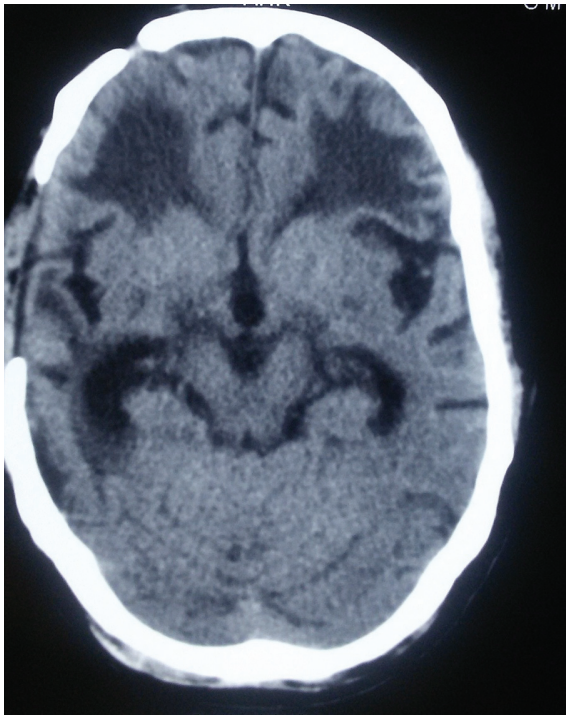

Figure 3. Repeat CT head at the time of follow up showing resolution in hematoma and in the mass effect previously observed.

Discussion

Named after the French surgeon Charles Labbé, the vein of Labbé (also known as the inferior anastomotic vein) crosses the temporal lobe between the Sylvian fissure and the transverse sinus and connects the superficial middle cerebral vein and the transverse sinus.

Since there is higher propensity for early uncal herniation and concurrent rapid neurological deterioration, any traumatic temporal lobe lesion poses an enigma for neurosurgeons.

Impact injury and counterblow are the main causes of injuries to the vein of Labbé, which can consequently lead to serious traumatic cerebral infarction with its associated poor prognosis[7]. Temporal bone fracture was associated in 15 of all the 16 cases in a study by Long *et al.*[7]

In a study by Giannetti *et al.*[11], CT scan findings such as medio-olateral diameter of the lesion, location of the hematoma, status of the ambient cisterns and position of the midline structures were used as a criteria to decide which patients would benefit from early surgery. In this case, we used the location of the hematoma, its volume and features of obliteration of ambient cisterns to assess the need to surgically evacuate the hematoma.

In previous studies of patients with blunt head trauma who have skull fractures extending to a dural venous sinus or jugular bulb, multi-detector CT venography identified dural venous sinus thrombosis (DVST) in 40.7% of cases, and of these 55% were occlusive[12]. There is a high risk of evolution of vein of Labbé haemorrhagic infarction in the subsets of patients with petrous bone fracture. So proper monitoring is justified for any signs and symptoms of increased intracranial pressure.

Also given the nature of the area of brain that vein of Labbé drains (language processing and comprehension), there is a need for long-term follow up of these patients to determine any neurological sequelae.

Conclusion

A high index of suspicion needs to be kept in patients with petrous bone fractures for probable vein of Labbé hemorrhagic infarction following transverse sinus thrombosis. In those with traumatic venous infarction, stringent monitoring needs to be taken for evidence of early uncal herniation. In case of lesions more than 25ml, anisocoria, uncal herniation and asymmetric ambient cisterns, early surgical evacuation is justified.

Consent

Written consent for publication of clinical data and images was sought and received from the son of the patient.

Author contributions

SM wrote and formatted the paper. BMK revised and edited the final format. All authors have seen and agreed to the final content of the manuscript.

Competing interests

The authors declared no competing interests.

Grant information

The author(s) declared that no grants were involved in supporting this work.

References

1. Stiefel D, Eich G, Sacher P: **Posttraumatic dural sinus thrombosis in children.** *Eur J Pediatr Surg.* 2000; **10**(1): 41–44.
PubMed Abstract | Publisher Full Text
2. Miller JD, Jennett WB: **Complications of depressed skull fracture.** *Lancet.* 1968; **2**(7576): 991–995.
PubMed Abstract | Publisher Full Text
3. Carlucci GA: **Injury to the longitudinal sinus accompanying a depressed fracture of the skull.** *Am J Surg.* 1939; **45**(1): 120–124.
Publisher Full Text
4. Kaplan A: **Compound depressed fractures of the skull involving the superior longitudinal sinus.** *Am J Surg.* 1947; **74**(1): 80–85.
PubMed Abstract | Publisher Full Text
5. Reilly HP Jr, Erbengi A, Sachs E Jr, *et al.*: **Penetration of the sagittal sinus by a depressed skull fracture. Roentgenographic diagnosis in an asymptomatic boy.** *JAMA.* 1967; **202**(8): 841–842.
PubMed Abstract | Publisher Full Text
6. Kinal ME: **Traumatic thrombosis of dural venous sinuses in closed head injuries.** *J Neurosurg.* 1967; **27**(2): 142–145.
Publisher Full Text
7. Long LS, Xin ZC, Wang WM, *et al.*: **[Clinic analysis of 16 patients of craniocerebral trauma with Labbé vein injury].** *Zhonghua Wai Ke Za Zhi.* 2011; **49**(11): 1022–5.
PubMed Abstract
8. Heiskanen O, Vapalahti M: **Temporal lobe contusion and haematoma.** *Acta Neurochir (Wien).* 1972; **27**(1): 29–35.
PubMed Abstract | Publisher Full Text
9. Maurice-Williams RS: **Temporal lobe swelling: a common treatable complication of head injury.** *Br J Surg.* 1976; **63**(3): 169–172.
PubMed Abstract | Publisher Full Text
10. McLaurin RL, Helmer F: **The syndrome of temporal-lobe contusion.** *J Neurosurg.* 1965; **23**(3): 296–304.
PubMed Abstract | Publisher Full Text
11. Giannetti AV: **Post-traumatic temporal lobe lesions: natural history and treatment.** *Arq Neuro-Psiquiatr.* 1998; **56**(4): 859–859.
Publisher Full Text
12. Delgado Almandoz JE, Kelly HR, Schaefer PW, *et al.*: **Prevalence of traumatic dural venous sinus thrombosis in high-risk acute blunt head trauma patients evaluated with multidetector CT venography.** *Radiology.* 2010; **255**(2): 570–7.
PubMed Abstract | Publisher Full Text

Open Peer Review

Current Referee Status: ? ✗

Version 1

Referee Report 14 September 2015

doi:10.5256/f1000research.7440.r10171

✗

Hazem Al-Khawaja
Department of Neurosurgery, Brain Tumor Center, Erasmus University Medical Center, Rotterdam, Netherlands

Sunil Munakomi and Bijoy Kumar presented an interesting case report about a traumatic vein of Labbé haemorrhagic infarction.

However, several aspects need to be considered before acceptance.

- Major: lack of specificity. The first CT brain presented is an urgent early CT scan, showing multi traumatic injuries, with contra coup contusions. It is not evident that the right-sided haemorrhagic defects are infarctions or contusions.

  Furthermore, the CT brain after decompressive craniectomy shows no residual infarction in the region of vein of labbé. This is strange since the treatment does not provide any recovery of the thrombosis in the vein of labbé.

  The case presented is a result of early decompression in a TBI patient.
- Major: The surgery that is performed is far from delicate and not in line with TBI guidelines.

  The bone flap that is performed is very small; removal of such small flap is a high risk for developing mushroom like herniation of the brain after decompression. Furthermore the authors performed haemorrhage removal during surgery. The haemorrhage is within the brain, meaning they removed contusions sq. infarction. This part of treatment is only performed in highly complicated cases where there is no choice but to remove the brain.

I have read this submission. I believe that I have an appropriate level of expertise to state that I do not consider it to be of an acceptable scientific standard, for reasons outlined above.

Competing Interests: No competing interests were disclosed.

Referee Report 04 September 2015

doi:10.5256/f1000research.7440.r10009

?

Carlos Bagley
Department of Surgery, Division of Neurosurgery, Duke University School of Medicine, Durham, NC, 27710, USA

This is a very interesting article on a challenging, and potentially devastating, clinical entity. The patient in this manuscript had an excellent outcome, it would be valuable to present factors that are associated with good versus poor outcomes. In addition, although the alternative causes of a similar clinical picture were mentioned, more information could be presented regarding how one might differentiate one underlying cause from another, the management of each cause, and the associated outcomes.

I have read this submission. I believe that I have an appropriate level of expertise to confirm that it is of an acceptable scientific standard, however I have significant reservations, as outlined above.

Competing Interests: No competing interests were disclosed.