THE

GLASGOW MEDICAL JOURNAL.

No. VI. JUNE, 1926.

ORIGINAL ARTICLES.

A METHOD OF SUPPORTING THE BULGING BRAIN IN EXTENSIVE DECOMPRESSIVE TREPHINING.*

BY ARCHIBALD YOUNG, M.B., C.M., B.Sc., F.R.F.P.S.G.,
Regius Professor of Surgery, University of Glasgow.

IN my presidential address, last year, I drew attention to the fact that the operation of trephining or trepanning was one of great antiquity. I indicated that evidences of its having been performed even in pre-historic times were to be found amongst skulls of the Stone Age. I told you of the conclusions of Victor Horsley on the skulls in the Broca Museum in Paris, viz., that the operative openings were nearly always over the site of representation of movement on the cerebral cortex; that the patients had probably suffered from Jacksonian epilepsy; that the operation would probably gain a certain reputation for the cure of convulsions generally; that at least some of the operations would result in cure. I quoted

* A communication delivered at a meeting of the Royal Medico-Chirurgical Society of Glasgow on 23rd October, 1925.

Ballance as saying—"It is, indeed, of surprising interest to note that thousands of years before trephining was deliberately employed for the treatment of organic disease of the brain a decompressive craniectomy was performed in many parts of the world as a therapeutic measure for pain in the head, for fits, for insanity (the Biblical disease 'possessed of the devil'), and for fracture of the skull."

I pointed out, also, that it was quite clear, from Hippocrates' writings, that he trephined for the purpose of decompression, to relieve inflammation, for the evacuation of pus and blood, and for the extraction of foreign bodies. What was even more striking, it seemed to me, was the fact—it is on record—that he recommended the use of the trephine for the treatment of blindness occurring without any visible disease of the eye—"surely the very earliest known evidence of the recognition of the value of decompressive trephining for the relief of what we now know as optic neuritis, and its consequent blindness." Celsus also urged the performance of the operation of trephining in cases of head injury, even where there was no obvious fracture of the skull—not merely, that is, for the evacuation of blood known or suspected to be there, but as a relief to intracranial pressure, however explained. From the times of Hippocrates, Celsus, &c., through the centuries, further references are found in medical writings to the applications of trephining or trepanning, not only for the treatment of fracture of the skull, but also for the relief of pressure by blood or pus, and for the treatment of "dolor capitis." I showed you illustrative plates taken from various classical works, showing not only many of the instruments employed, but pictures of these operations actually in progress.

It is established, therefore, that decompressive trephining is an operation hallowed by antiquity, and, indeed, it would be strange if it had not occurred to the mind of careful observers throughout the ages. Accidental demonstration of the effect of opening the skull must often enough have been forthcoming. It must have happened, from time to time, that the more distressing effects of intracranial pressure were relieved by operative procedures undertaken with no such immediate purpose.

Is there not, too, the pointer of Nature herself. It is well known to-day—it must have been evident long ago—that in the hydrocephalus of infancy, pressure intracranially accomplishes its own relief—at least for a time—by delaying the closure of fontanelles, by delaying the closure of sutures, by leading often to their very wide separation?

What are the applications of the operation of decompressive trephining to-day?

Its chief field of established usefulness is probably in cases of intracranial tumour, where it may be carried out—and is frequently carried out—as a merely palliative procedure, for the relief of the intense headache accompanying so many of these conditions; for the treatment of the vomiting which is so often a marked feature of them; and for the preservation of vision, through the assuagement of papillœdema, and the arrestment of the degenerative effects of optic neuritis. But this by no means covers the whole field of its application and usefulness. There are cases of acute compression, due directly to injury, in which a decompressive operation, by relieving pressure on the pons and medulla, even in the absence of localised blood accumulation, may constitute a reasonable procedure in treatment. And the operation has even been recommended, and carried out, for the treatment of intractable headache, without gross evidence of fracture or depression of bone. It has been performed, too, as an operation of election in cases of epilepsy, quite apart from any idea of possible search for a removable or localisable cause for the epileptic or epileptiform seizures. And it should be said that in a very encouraging number of cases it has proved effectual in leading to the cessation, or at least the substantial amelioration, of such epileptic fits.

It is, I think, recognised even by its most enthusiastic advocates, and by the most skilful cerebral surgeons, that the possibilities of radical surgical treatment of intracranial tumours are at best not brilliant. Improving diagnosis and improving technique have, it is true, done much to brighten the outlook in this direction, but the limits of success are even yet severely circumscribed. Statistics are difficult to collate, and even more difficult to interpret, but it is probably not too much to say

that, though the immediate results of operations on intracranial tumours to-day may be greatly more favourable than they used to be, as regards mere mortality—it has been stated, for example, that the immediate mortality has fallen from over 70 per cent to about 30 per cent—perhaps half of the patients may be able to leave hospital, but very few of those live more than a few years, and fewer still ever become useful members of society again.

In such circumstances it is not at all surprising that the tendency towards the purely palliative operation of decompressive trephining should have greatly strengthened in recent years. At the same time, it is only fair to state that a considerable field still exists for the adoption of what one might describe as a combination of both procedures, viz., the planning of the exploratory or radically-intentioned operation in such a way that it may be combined with, or replaced by, a decompressive procedure.

It may be said, then, that in a case of suspected intracranial tumour, where such a tumour cannot be localised, or is probably placed so deeply, or in such a difficult position, that removal is not possible, or is inadvisable, a decompressive trephining should be done. This means that the skull and the dura should be opened, so as to relieve tension. It may surely be accepted almost as an axiom that no patient should be allowed to become blind from optic neuritis if it is in the power of the cerebral surgeon to accomplish this. And this it assuredly is, provided that the case is brought under observation in time. One can hardly over-estimate, also, the enormous relief such a decompressive operation is able to bring to the subjects of intracranial tumour, in lessening or eliminating vertigo, in diminishing or preventing vomiting, and in assuaging or abolishing altogether the intense headache which often forms such a distressing feature of the clinical picture. The transition from the pre-operation conditions of failing sight, recurring vomiting, and often agonising headache, to the post-operation condition of comparative comfort, once seen, is not likely to be readily forgotten.

The following may be taken as representing the chief possible lines of decompressive procedures; and it may be said, too, that

they are taken in the order which may be regarded as suggesting the chronological sequence of their historical development:—

1. *Decompressive trephining as a part of, or as the completion of, a direct craniectomy.*—In this procedure, if, in a case of suspected intracranial tumour, the skull is opened over the actual site of the tumour, even where such tumour is incapable of removal, the direct local relief may be—theoretically, ought to be—of some advantage. The chief disadvantage, however, is that where the tumour is large, or the intracranial tension great, tumour and brain are almost certain to bulge through the opening made in the skull and dura, and the result is almost equally certain to be a gross and serious laceration of the bulging brain against the edges of the dural and bony opening, with serious effects in the way of brain damage, and perhaps irrevocable palsy of parts of the body or limbs related to the side of the brain implicated. Such a procedure, then, as an operation of election, must seldom be advisable.

2. *Intermuscular-temporal decompression, by the method of Harvey Cushing, or some modification of this method.*—Cushing devised the method of opening skull and dura underneath the temporal muscle, which was split, and its fibres retracted, so as to uncover sufficient bone to allow of the making of a gap of some size. The object of the technique was, and is, to make the gap in the bone in such a situation as to provide a fairly strong muscular support for the hernia of brain which was the necessary result, if the prime purpose of the operation, viz., substantial relief of intracranial tension, were to be achieved. The so-called "*sub-temporal decompression*" procedure, in which the temporal muscle, instead of being split, is cut through transversely near to its upper attachment, and turned downwards temporarily, is merely a variant of the same procedure, though it certainly allows of more extensive removal of bone than does the original form of the operation proposed and developed by Cushing. It may be convenient to remind you, also, that Cushing, in his operation for *cerebellar decompression*, sought to accomplish the same purpose of brain support or control by means of his "cross-bow" incision, the transverse limb of which was placed above

the level of upper attachment or origin of the cervical muscles. At the conclusion of his cerebellar decompression operation he is accustomed to close the large "cross-bow" wound most carefully and most laboriously, layer by layer.

3. *Decompression by the conversion of an osteoplastic flap procedure into a purely decompressive one.*—Here it is to be presumed that the surgeon has embarked on an operation originally intended to display a tumour capable of removal, with the purpose, or at least the hope, of its radical extirpation; and either a tumour is not found or one is found which does not admit of removal. The operation is capable of conversion into a purely decompressive one in various ways. The bone included in the osteoplastic flap is easily taken away, and the flap of soft tissues alone is sutured in position. Or, as Cushing advised, the lower portion of the bone flap may be cut away, and this supplemented by cutting away also a corresponding area of bone from the skull below the base of the osteoplastic flap, leaving the major part of the bone of the flap to support the upper brain surface. Or—and this is a method which I have followed in several cases—the margins of the bone in the flap may be nibbled away all round, so as to prevent, or at least delay, its reunion with the adjacent osseous edges once it has been replaced, so that the bulging, protruding brain and dura will have its support or protection, while it will not limit or prejudice the relief of intracranial pressure which is sought.

4. *More extensive decompression.*—This has come into vogue with not a few surgeons by reason of the realisation of the fact that a decompression, if it is to be effective, must fulfil its main function, must really provide a sufficient opening, not merely for the immediate requirements of the case, but also for future needs. The opening in the bone, if it is to be sufficient, and therefore efficient, for its present and future purpose, must be substantial. Otherwise, the operation fails of its purpose. It may provide for present relief, but not for the maintenance of relief for any considerable, or at least for a prolonged, period of time. Even at the time, too, unless the gap is large, in cases of great tension, the risk of laceration of extruded brain against the edges of the bone is a real one. It is necessary, also,

to emphasise the fact that, mere opening of the bone, without free opening of the dura, is of little or no value. The dura has very little elasticity, does not readily stretch, and Ballance and Sherrington showed, long ago, that, in a recently killed dog, even when half the vault of the skull had been cut away, it was not possible to get the dural cavity to receive or contain more than an additional 0·5 c.cm. of fluid. Mere removal of bone, then, is not sufficient as an effective palliative measure —even if the area of bone removed be very large—as it hardly alters the volume of the intradural space. If relief is to be effectively achieved, not only must the area of bone removed be large, but the dura must be freely opened, removed, reflected, or so adjusted, as to allow of free brain protrusion, increasing, it may be, to very large dimensions, as the tumour progresses in size. It must be recognised, by any surgeon who sets out to do an effective decompression operation, that a hernia of brain is the prime purpose of the operation, and that provision for this should be generous and large; that generous provision is also the safest and surest way to accomplish the purpose of the operative procedure, viz., substantial and lasting relief of the compression symptoms.

It is obvious, of course, that the control or support of the bulging brain in such an extensive decompression operation is bound to be more difficult than where the opening in bone and in dura is less considerable. Bulging of the brain may be, to a certain extent, prevented or limited at the time of the performance of the operation, by several expedients, such as by keeping the head well elevated during its execution, by tapping the ventricle, and allowing excess of cerebro-spinal fluid to drain off during its progress, or, as suggested recently by Cushing and Weed, by the intravenous injection of hypertonic saline shortly before the dura is opened, so producing a marked temporary shrinkage of the whole brain. It is the subsequent support of the herniated brain that is the problem that this contribution is chiefly concerned with.

Of course, in almost any form of decompressive procedure, it is usual to make some provision afterwards to protect the bulging scalp tumour. This is achieved by the use of external shields of different kinds—thin metal supports, celluloid

moulds, &c. These are all, however, additional to the surgical provision.

We have seen that, in various ways, muscular, fascial, or combined muscular and fascial supports have been devised; and these, in the more limited decompressions, have proved, in varying degrees, of service. The pericranium has also been used for the same purpose, and in some cases reliance has been placed upon the preservation and adjustment of parts of the dural flaps. To a certain extent these have also served their purpose. It is known, too, that even where extensive

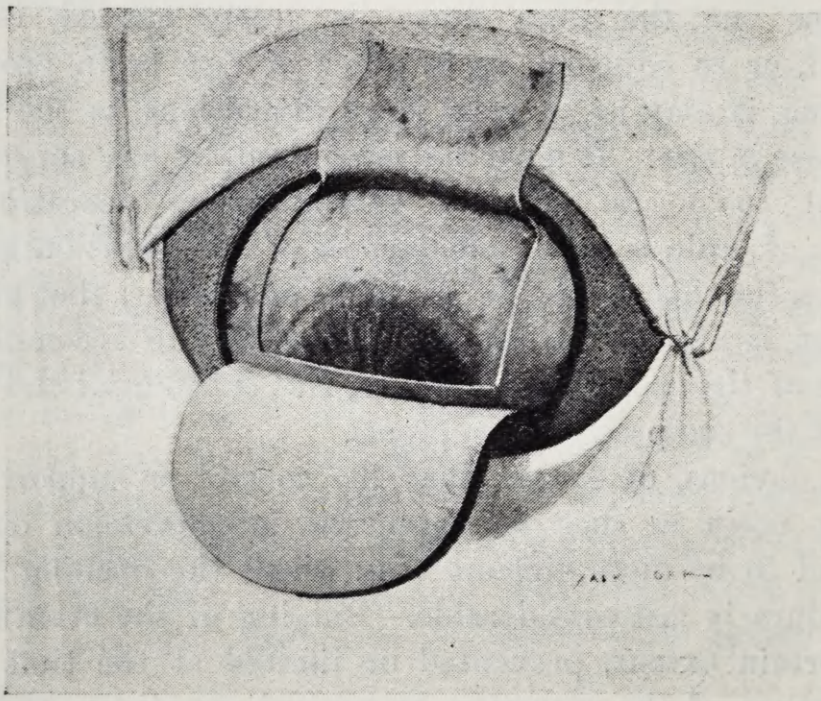

FIG. 1.
Scalp flap turned down. Fascial-pericranial flap turned up.

areas of dura have been removed, or where the dural defect is considerable, a new dural covering should be, and is, regenerated. But, in an extensive decompression operation such as that to which I have referred last above, it seems desirable and even necessary to make some provision for brain control and support at the operation itself and in the period immediately following. It is in the provision of such immediate support and control that I believe the following simple procedure finds its sphere of usefulness.

The method may be outlined very briefly as follows:—

A very large flap of scalp is raised from the side of the head, and is turned downwards. Its base is as low down as is conveniently possible—almost down to the zygoma if necessary. Its free border extends well up towards the sagittal line. This flap includes all the layers of the scalp, down to the pericranium above and to the temporal fascia below, but it should penetrate neither of these. It is turned down well out of the way, and is protected from injury and infection by large aseptic gauze pads. A second flap is then

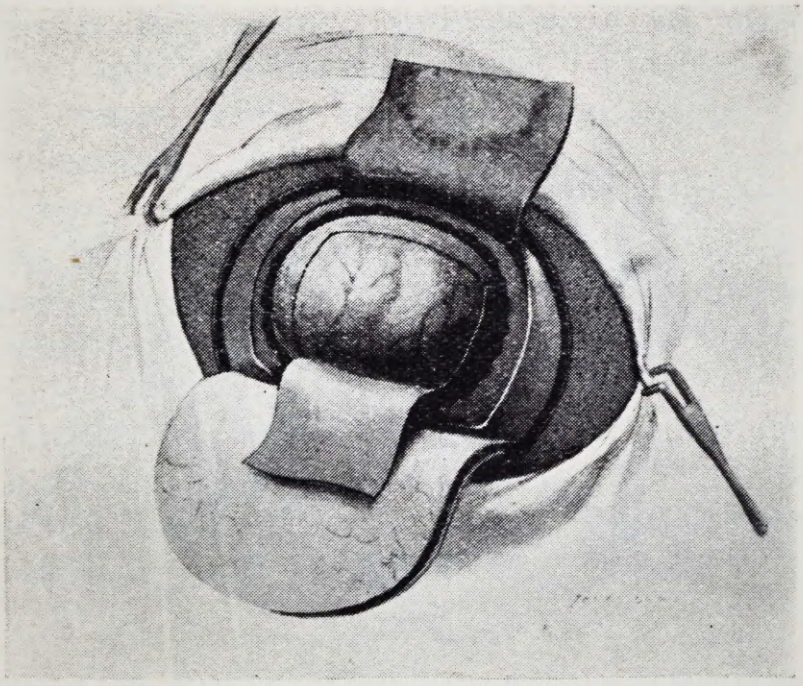

FIG. 2.
Dural flap turned down. Brain bulging.

outlined, somewhat smaller than the first, and with its base towards the upper free edge of the first flap. Its free border reaches well down upon the surface of the temporal muscle. This flap, which includes temporal fascia below, and pericranium continuous with it above—a fascial-pericranial flap—is reflected upwards, and, like the first, is appropriately protected (Fig. 1). The temporal muscle, with the remaining lower part of the temporal fascia, is then displaced well downward, out of the way, and the operator proceeds to open up the underlying bone, making as large and roomy an opening as

may be desired, its only limits being those imposed by the size of the initial scalp flap. The manner of making the opening in the bone will depend upon the preference and practice of the individual operator. Once the large gap in the bone has been fashioned, its edges are carefully rounded off, and rendered smooth, so as to lessen the risk of later damage to the extruded brain, once the dura has been opened.

The dura is opened by the raising of a third flap, which is, like the first, turned downwards (Fig. 2). It should be sufficiently

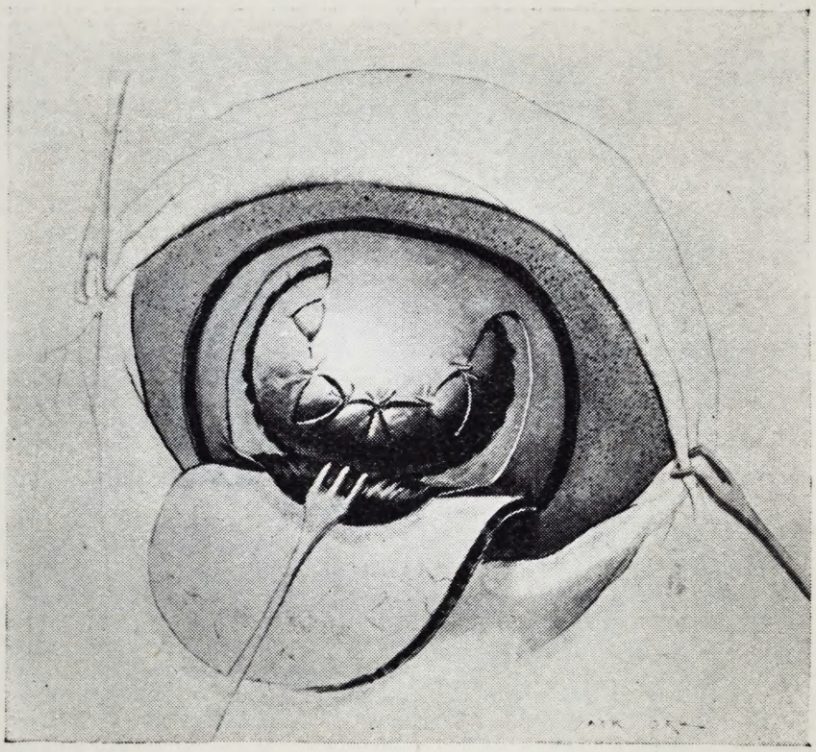

FIG. 3.

Dural flap sutured to fascial-pericranial flap, with or without overlap.

less in area than the size of the bone gap to allow of the marginal portions of dura furnishing some protection to the brain from pressure and laceration on the bone edges. Before this dural flap is actually cut, hæmostasis should be provided for by careful ligation of any considerable vessels. In cases of considerable intracranial tension, it will be found that the full length and width of the second and third flaps are required. In cases where tension is less than was expected, excess can easily be cut away, or part of either flap may be used to supplement

the support by making a double fold of the excess as reinforcement. When the brain has been sufficiently inspected and any necessary detail of technique has been carried out, the second flap—*i.e.*, the fascial-pericranial flap—is brought down and is sutured to the free edge of the dural flap, *i.e.*, the third flap, or, if there be excess, to such a level of this as to give the necessary degree of support to the bulging brain, the excess being used either to reinforce the support, as indicated above, or being cut away and used to make good any defects at the lateral margins or angles of the gap (Fig. 3). Hæmostasis having been adequately provided for in respect of the first, or scalp flap, the latter is then replaced, and its edges are carefully and closely sutured in place once more. A copious absorbent external dressing, firmly bandaged, is then applied over the whole, and the operation is complete.

The steps in the procedure are sufficiently illustrated in the three drawings I am able to show, and I should say that these drawings were not made by the artist from mere descriptions given him. They were made by him during the actual execution of such an operation.

The procedure, as I have endeavoured to describe it, and as it is illustrated in the drawings, is presented to you as an operative procedure of value in such extensive decompression operations as those to which I have referred.