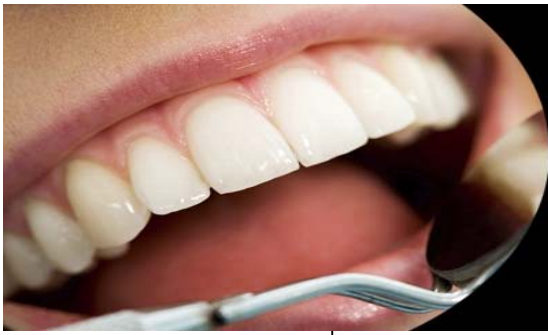



ISSN Print: 2394-7489
ISSN Online: 2394-7497
IJADS 2015; 1(4): 68-70
© 2015 IJADS
www.oraljournal.com
Received: 07-07-2015
Accepted: 08-08-2015

Masayasu Iwase
Department of Dentistry and
Oral Surgery, Hakujikai
Memorial General Hospital,
Tokyo, Japan.

Michiko Ito
Department of Oral and
Maxillofacial Surgery, School of
Dental Medicine, Tsurumi
University, Yokohama, Japan.

Hanon Katayama
Division of Community Based
Comprehensive Dentistry,
Department of Special Needs
Dentistry, School of Dentistry,
Showa University, Tokyo,
Japan.

Hiroaki Nishijima
Department of Dentistry and
Oral Surgery, Jinkokai Hospital,
Atsugi, Japan.

Gen Kondo
Department of Dentistry and
Oral Surgery, Jinkokai Hospital,
Atsugi, Japan.

Correspondence
Masayasu Iwase
Department of Dentistry and
Oral Surgery, Hakujikai
Memorial General Hospital,
Tokyo, Japan.

A case of an asymptomatic giant sialolith in the hilum of the submandibular gland

Masayasu Iwase, Michiko Ito, Hanon Katayama, Hiroaki Nishijima, Gen Kondo

Abstract

Sialoliths most commonly occur in the submandibular gland. We present a case of a giant sialolith in the hilum of the submandibular gland. A 58-year-old male patient was referred to our department for treatment of a fracture in the right mandible with swelling and pain; he did not complain of any complications in the left mandibular region. In a panoramic radiograph and CT examinations, a large radiopaque mass was revealed in the left submandibular region. We made a diagnosis of a sialolith in the submandibular gland. The sialolith was removed by sialoadenectomy of the submandibular gland under general anesthesia. The dimensions of the removed specimen were 41×18×15 mm. The pathological diagnosis of the extirpated submandibular gland was chronic sialadenitis. The patient progressed favorably after surgery without any complications.

Keywords: Giant Sialolith, Submandibular Gland, Sialoadenectomy, Chronic Sialadenitis.

1. Introduction

Sialoliths often cause sialolithiasis, the most common salivary gland disease. Sialoliths most often occur in the submandibular glands, rarely occurring in the parotid glands and other salivary glands^[1]. Approximately 80% of sialoliths are reported to be less than 10 mm in size, and a review of the literature has shown the occurrence of abnormally large sialoliths (more than 15 mm) to be rare^[1, 2]. The typical symptoms of sialoliths are pain and swelling due to obstruction of the salivary ducts, classically at meals^[1]. However, if the secretion of saliva is maintained, the disease progresses asymptotically, as revealed in a few of cases^[1]. Giant sialoliths have been reported to remain asymptomatic for many months prior to presentation^[3]. Here, we describe the diagnosis and management of a case of an asymptomatic giant sialolith of approximately 40mm in the hilum of the submandibular gland.

2. Case Report

A 59-year-old male patient was referred from an emergency hospital to our department for the treatment of a mandible fracture with malocclusion, trismus, and pain caused by a traffic injury. The patient had a medical history of angina pectoris, and took anti-platelet agents regularly. Clinical examination revealed right submandibular swelling and pain, trismus, and deranged occlusion. The presence of the fracture was confirmed on a panoramic radiograph (Fig. 1). The panoramic radiograph and computed tomography (CT) scans simultaneously showed a massive, club-shaped radiopaque image in the left submandibular region (Figs. 2 and 3).

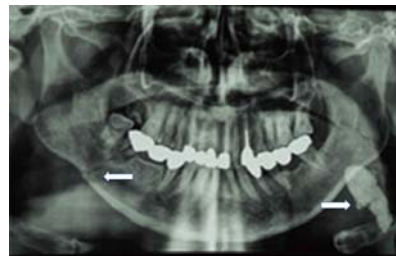


Fig 1: Orthopantomography showing a large radiopaque mass (arrow) in the left submandibular region, and bone fracture (arrow) in the right mandible.

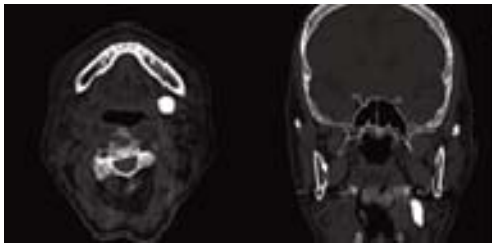


Fig 2: CT showing a large radiopaque mass in the left submandibular region.

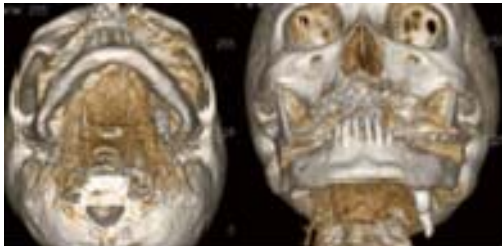


Fig 3: 3D-CT showing a large club-shaped bone-like mass in the left submandibular region.

In addition, we could palpate the firm mass in the submandibular region, but the patient did not complain of any symptoms other than slight oppressive pain in the left mandible. We made a diagnosis of a sialolith in the left submandibular gland. For the mandible fracture, we performed mandibular repositioning fixation using titanium plates under general anesthesia. The patient did not show any symptoms of a sialolith during observation of his progress. Six months after mandibular fracture surgery, we performed titanium plate removal and extirpation of the sialolith by sialoadenectomy under general anesthesia, because the sialolith was in the hilum of the submandibular gland (Fig. 4). The removed sialolith weighed 8.4 g and measured 41 x 18 x 15 mm (Fig. 5). Histopathological examination of the submandibular gland showed features of chronic sialadenitis (Fig. 6). As for the patient's progress, it was favorable without any complications, such as facial paralysis after surgery.

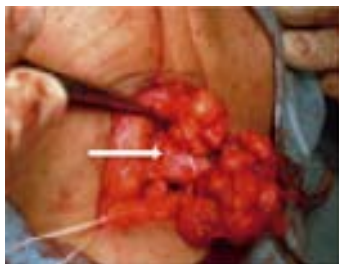

Fig 4: Photograph showing extirpation of a salivary calculus (arrow), as well as the submandibular gland.

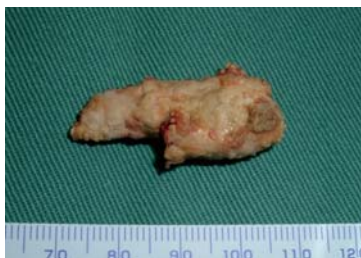

Fig 5: Photograph showing a giant sialolith measuring 41 x 18 x 15 mm.

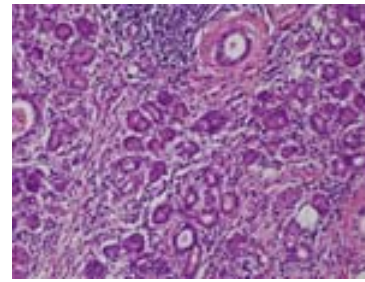


Fig 6: Histopathological examination of the submandibular gland showed features of chronic sialadenitis (HE-stain, x 200).

3. Discussion

Sialoliths are often accompanied by recurrent attacks of pain and swelling in the involved salivary gland. The pain and swelling usually occur during meals. Because sialoliths are usually symptomatic, patients often receive medical attention long before a sialolith becomes large. A growing sialolith increases obstruction of salivary secretion, which leads to various complications, such as swelling, pain, and secondary infection of the gland, and finally to the need for surgical intervention [2]. However, if the duct adjacent to the sialolith is able to dilate, allowing normal secretion of saliva around the sialolith, it might be asymptomatic and eventually allow the creation of a giant sialolith [3]. In the present case, it is suggested that the sialolith became gigantic because it was asymptomatic.

A previous report has indicated that giant sialoliths are rare, defining their size as 15 mm [2] or 35 mm [4] or larger. In general, giant sialoliths have been frequently described in the body of the salivary glands, and they have rarely been reported in the salivary ducts without symptoms [5]. In the present case, the giant sialolith was more than 40 mm, and was located in the hilum of the submandibular gland.

The location, size, and configuration of the sialolith are important factors when planning intervention for a giant sialolith [6]. The goal of treatment for a giant sialolith, as well as for a standard-size sialolith, is restoration of normal salivary secretion. Although chronic sialadenitis secondary to persistent obstruction from a giant sialolith leads to a fibrotic and poorly functioning gland, symptoms apparently resolve after sialolith removal [7]. On the other hand, long-term obstruction in the absence of infection can lead to atrophy of the gland with resultant lack of secretory function and ultimately fibrosis [8]. Therefore, sialoadenectomy is desirable for long-term salivary gland obstruction, otherwise denaturation of the salivary gland occurs [1]. The pathological findings of the present case also showed dilation of the salivary ducts and acinar atrophy, and thus a diagnosis of chronic sialadenitis was made.

Sialoliths should be removed by the least invasive procedure available to avoid risk of complications. Sialolithotomy is a well-reported technique for the transoral removal of a ductal sialolith, including giant sialoliths, without duct stenosis and lingual nerve damage [3, 7]. However, as for the transoral removal of a proximal sialolith, it has been reported that there is increased risk of lingual nerve damage [6].

Recently, there have been reports of an interventional technique for the removal of sialoliths. Sialendoscopy is now an established intervention for sialolith removal, and has been described for use in giant sialoliths [9]. The incorporation of extracorporeal shock-wave lithotripsy and basket retrieval for sialolith removal has been also shown to be an effective modality and an alternative to conventional excision [10].

Conflicting views exist with regard to the surgical treatment of

a sialolith in the hilum of the submandibular gland, with the options being excision of the submandibular gland or transoral removal of the sialolith alone [6, 7]. In general, whenever the sialolith can be palpated transorally, the best option is removal through the transoral approach [6, 10]. On the other hand, previous studies have indicated that an intraglandular sialolith necessitates sialoadenectomy [10]. Therefore, in the present case, we performed sialoadenectomy of the submandibular gland, along with the giant sialolith, because we determined that transoral removal would be difficult given the location, configuration, and size of the sialolith. Sialoadenectomy of the gland is indicated to carry a risk of temporary or permanent marginal mandibular nerve palsy. There was no damage to the nerves in the present case. Although previous studies have introduced various invasive approaches to the management of sialoliths, physicians should choose a safe and certain method according to the circumstances of the sialolith. Here we reported on the diagnosis and management of an unusually giant sialolith arising in the hilum of the submandibular gland.

4. References

1. Lustmann J, Regev E, Melamed Y. Sialolithiasis. A survey on 245 patients and review of the literature. *Int J Oral Maxillofac Surg.* 1990; 19:135-138.
2. Bodner L. Giant salivary gland calculi: Diagnostic imaging and surgical management. *Oral Surg Oral Med Oral Pathol Oral Radiol Endod* 2002; 94:320-323.
3. Manjunath R, Burman R. Giant submandibular sialolith of remarkable size in the comma area of Wharton's Duct: A case report. *J Oral Maxillofac Surg.* 2009; 67:1329-1332.
4. Ledesma-Montes C, Garces-Ortiz M, Salcido-Garcia JF, Hernandez-Flores F, Hernandez-Guerrero JC. Giant sialolith: Case report and review of the literature. *J Oral Maxillofac Surg.* 2007; 65:128-130.
5. Leung AKC, Choi MCK, Wagner GAL. Multiple sialoliths and a sialolith of unusual size in the submandibular duct: A case report. *Oral Surg Oral Med Oral Pathol Oral Radiol Endod* 1999; 87:331-333.
6. Park JS, Sohn JH, Kim JK. Factors influencing intraoral removal of submandibular calculi. *Otolaryngol Head Neck Surg* 2006; 135:704-709.
7. MuGurk M, Makdissi J, Brown JE. Intra-oral removal of stones from the hilum of the submandibular gland: report of technique and morbidity. *Int J Oral Maxillofac Surg.* 2004; 33:683-686.
8. Teymoortash A, Tiemann M, Schrader C, Werner JA. Characterization of lymphoid infiltrates in chronic obstructive sialadenitis associated with sialolithiasis. *J Oral Pathol Med.* 2004; 33:300-304.
9. Wallace E, Tausin M, Hagan J, Schaitkin B, Walvekar RR. Management of giant sialoliths: Review of the literature and preliminary experience with interventional sialendoscopy. *Laryngoscope* 2010; 120:1974-1978.
10. McGurk M, Escudier MP, Brown JE. Modern management of salivary calculi. *Br J Surg.* 2005; 92:107-112.