

Management of Diaphyseal Fractures of Long Bones in Children with Intramedullary Flexible Nail Nailing

Gaurav Sachdeva¹, Suhas Kamble¹

¹Department of Orthopaedics, Padmashree Dr. D. Y. Patil Medical College, Hospital and Research Centre, Pimpri, Pune, Maharashtra, India.

Institute at which research was conducted: Padmashree Dr. D. Y. Patil Medical College, Pune, India.

University Affiliation of Thesis: D. Y. Patil University.

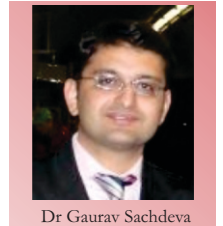
Year of Acceptance: 2012

Address of Correspondence

Dr. Gaurav Sachdeva

Department of Orthopaedics, Padmashree Dr. D. Y. Patil Medical College, Hospital and Research Centre, Pimpri, Pune, Maharashtra, India.

E mail: g_s2001in@yahoo.com



Dr Gaurav Sachdeva

Abstract: Background: Ideally, fixation of paediatric diaphyseal fractures should produce an “internal splint” that shares loads, maintains reduction until hard callus formation, and does not endanger the growth areas or blood supply. Results from several studies have shown that FIN / TENS fixation meets these requirements because it allows rapid mobilization, potentially no risk for osteonecrosis, low risk for physeal injury, and reduced risk for refracture. ESIN meets the requirements of this ideal device.

Materials and methods: 31 cases of Diaphyseal fractures in 30 Patients were included. Final outcome was graded excellent, satisfactory or poor based on criteria described by Flynn et al.

Result: The results according to Flynn et al were Excellent in 26 patients (86.67%) , Satisfactory in 3 patients (10%), and Poor in 1 patient (3.33%).

Conclusion: Enders nailing is a simple and useful technique for stabilization of Diaphyseal fractures in long bones in children as it permits adequate rotational stabilization.

Keywords: Diaphyseal fractures, titanium elastic nail, intramedullary nail, children

THESIS SUMMARY

Introduction:

Recently there has been a growing trend towards surgical treatment of Diaphyseal fractures in children .To some extent this reflects a more interventionist attitude among Orthopaedic Surgeons but is also due to technical development, notably that of ESIN(Barry & Paterson, 2004).The treatment for children between the ages of 6 and 10 years is the most controversial. Many such patients may be treated successfully with immediate closed reduction & casts. However, external fixation and flexible intramedullary rod fixation are being used more frequently, particularly in patients with multiple trauma.However, in older children and adolescents operative treatment should be

considered to avoid complications such as delayed union, malunion, rotational deformity, refracture, knee stiffness, limb length discrepancy and psychosocial problems.Operative treatment results in shorter hospitalization and early mobilization, which has psychological, social, educational and economic advantages over conservative treatment. A variety of therapeutic alternatives mentioned above such as external fixator, compression plating, rigid Intramedullary nailing and elastic stable intramedullary nailing are being used for Diaphyseal fractures in children.

With the use of external fixator, there is a high incidence of pin tract infection, refracture after removal of external fixator. Also the external fixator is more uncomfortable and

cumbersome for the child (Linhart & Roposch, 1999)Submuscular Compression plating needs two major operations - one for insertion and another one for the removal of the plate (Gonzalez et. al.1995).Rigid intramedullary nails have their own pros and cons. They not only increases risk of AVN of femoral head in children and adolescents (Thometz and Lamdan, 1995), but also there is a high incidence of abnormalities at the proximal end of the femur including coxa valga, arrest of growth of greater trochanter, thinning of the neck of the femur because of damage to trochantero-cervical region.

Ideally, fixation of paediatric diaphyseal fractures should produce an “internal splint” that shares loads, maintains reduction until hard callus formation, and does not endanger

the growth areas or blood supply. Results from several studies have shown that FIN / TENS fixation meets these requirements because it allows rapid mobilization, potentially no risk for osteonecrosis, low risk for physeal injury, and reduced risk for refracture. ESIN meets the requirements of this ideal device (Flynn et al. 2001).

Upper age limit for ESIN in Pediatric Diaphyseal fracture is until the time of closure of the proximal growth plate after which conventional rigid locked intramedullary nailing can be used safely. Sanders J.O et al (2001) The choice of treatment may be influenced by the age of the child, the level and pattern of the fracture and to a great extent, by regional, institutional or surgeons preferences.

Materials and methods:

This is a Prospective Study based on patients admitted with Diaphyseal Fractures in Long Bones in the age group of 6 years - 16 years. The study was done on 31 cases of Diaphyseal fractures in 30 Patients. All recent Diaphyseal fracture of Transverse, short oblique, minimally comminuted type were included. Postoperative data collected was no. of nails, postoperative immobilization, period of hospital stay, period of radiological union, return to normal work, any complication, time to nail removal. Radiographs were evaluated for alignment, nail size, nail shape (C or S), callus formation, nail position, and measurement of fracture location. Final outcome was graded excellent, satisfactory or poor based on criteria described by Flynn et al.

Results:

The results according to Flynn et al were Excellent in 26 patients (86.67%), Satisfactory in 3 patients (10%), and Poor in 1 patient (3.33%). Only 3 patients (10.03%) had complication in the form of skin erosion (superficial infection). 23 patients (76.67%) had radiological callus within 8 weeks of operation, while 7 patients (23.33%) had there radiological callus by 12 weeks. 24 patients (80%) had a hospital stay of upto 10 days, while only 6 patients (20%) had a stay of more than 10 days. The geometry of fracture was Transverse (54.80%), Oblique (22.60%) and unicortical comminution (12.90%).

Conclusion:

The following conclusion could be drawn from the present study:

- 1) Enders nailing is a simple and useful technique for stabilization of Diaphyseal fractures in long bones in children as it permits adequate rotational stabilization.
- 2) It is suitable for short oblique or transverse fractures and fractures with unicortical comminution. Unstable fractures with long obliquity or significant comminution are not suitable for stabilization with Enders nailing on account of its relatively poor longitudinal stability.
- 3) Early callus formation and better healing time following use of Enders nail indicates advantages of undreamed nails over plating osteosynthesis and external fixator in fracture healing, specially in fresh fractures.
- 4) Minimum of two Enders nails with use of both medial & lateral portals is desirable to provide adequate rotational stability and to counteract the angular stresses produced in humerus, femur and tibia. One nail is sufficient in radius & ulna.

5) Significant incidence of distal migration of the nail and knee pain at a later stage is one the limiting factor of Enders Nail in Diaphyseal fracture in long bones in children which can be prevented by use of a locking 4mm screw / K-wire through the eye of enders nail. However disappearance of symptoms with nail removal does neutralize these problems to some extent, though, one has to wait till sound bony union before the nails can be removed.

Elastic stable intramedullary nailing is an excellent method of managing most, but not all, pediatric diaphyseal fractures that need operative stabilization. It is by no means the only technique nor is there evidence yet that it is superior to other methods. Its advantages make it a valuable choice to consider in managing these fractures. Ultimately, the choice should reflect best evidence and also incorporate patient preferences.

Key Words:

Diaphyseal fractures, titanium elastic nail, intramedullary nail, children

Bibliography

1. Gardner, MJ, Lawrence BD, Griffith MH. *Surgical treatment of pediatric femoral shaft fractures. Current Opinion In Pediatrics* 2004; 16(1): 51-57.
2. M. Barry, Paterson JMH. *Flexible intramedullary nails for fractures in children, J Bone Joint Surg Br* 2004; 86(B): 947-53.
3. Linhart WE, Roposch A. *Elastic stable intramedullary nailing for unstable femoral fractures in children: preliminary results of a new method. J Trauma.* 1999 Aug; 47(2): 372-8.
4. Gonzalez HP, Burgos F J, Rapariz JM; *Intramedullary nailing of the femur in children, Effects on its proximal end. Journal of Bone and Joint Surgery Br;* 77-B (2): 262-266.
5. Thometz JG, Lamdan R. *Osteonecrosis of the Femoral Head after Intramedullary Nailing of a Fracture of the Femoral Shaft in an Adolescent. JBJS* 1995 Sept (9); 77-A.
6. Flynn JM, Hresko T, Reynolds RA, Blasier RD, Davidson R, Kasser J. *Titanium elastic nails for pediatric femur fractures: a multicenter study of early results with analysis of complications. J Pediatr Orthop* 2001 Jan-Feb; 21(1): 4-8.
7. Sanders JO, Browne RH, Mooney JF, et al. *Treatment of femoral fractures in children by pediatric orthopedists: Results of a 1998 survey. J Paeds Orthop* 2001 July/Aug; 21(4): 436-441.
8. http://www.maitrise-orthop.com/corpusmaitri/orthopaedic/oillier_synth/oillie_us.shtml.
9. Hackethal KH. *Bundle nailing: a method of marrow nailing of long tubular bones. Langenbecks Arch Klin Chir Ver Dtsch Z Chir* 1961; 298:1001-3.

10. Eriksson E, Hovelius L. Ender nailing in fractures of the diaphysis of the femur. *J Bone Joint Surg Am* 1979 Dec; 61(8): 1175-81.
11. Knothe U, Melissa L, Tate K, Stephan MP. 300 Years of Intramedullary Fixation - from Aztec Practice to Standard Treatment Modality. *Eur J Trauma* 26(5): 217-225.
12. Rush LV, Rush HL. Technique for Longitudinal Pin Fixation of Certain Fractures of the Ulna and of the Femur. *JBJS Am* 1939 July; 21(3): 619-626.
13. Irani RN, Nicholson JT, Chung SM. Long term results in treatment of femoral fractures in young children by immediate spica immobilization. *J Bone Joint Surg Am* 1976 Oct; 58(7): 945-51.
14. Ligier JN, Metaizeau JP, Prevot J, Lascombes P. Elastic stable intramedullary nailing of long bone shaft fractures in children. *Z Kinderchir* 1985 Aug; 40(4): 209-12.78
15. Holschneider AM, Vogl D, Dietz HG. Differences in leg length following femoral shaft fractures in childhood. *Z Kinderchir*. 1985 Dec; 40(6): 341-50.
16. Mann DC, Weddington J, Davenport K. Closed Ender nailing of femoral shaft fractures in adolescents; *J Pediatr Orthop*. 1986 Nov-Dec; 6(6): 651-5.
17. LIGIER JN, METAIZEAU JP, PREVOT J, LASCOMBES P. Elastic Stable Intramedullary Nailing of Nailing of Femoral Shaft Fractures in Children. *J Bone Joint Surg Br* 1988; 70-B: 74-7.
18. Herndon WA, Mahnken RF, Yngve DA, Sullivan JA. Management of femoral shaft fractures in the adolescent. *J Pediatr Orthop*. 1989 Jan-Feb; 9(1): 29-32.
19. Reeves RB, Ballard RL, Hughes JL. Internal fixation versus traction and casting of adolescent femoral shaft fractures. *J Pediatr Orthop* 1990 Sept/October; 10(5): 592-595.
20. Hansen TB. Fractures of the femoral shaft in children treated with an AO-compression plate: report of 12 cases followed until adulthood. *Acta Orthop Scand* 1992; 63: 50-2.
21. Heinrich SD, Drvaric DM, Darr K, MacEwen GD. The operative stabilisation of paediatric diaphyseal femur fractures with flexible intramedullary nails: a prospective analysis. *J Pediatr Orthop*. 1994 July/Aug; 14(4): 501-7.
22. Karaoglu S, Baktir A, Tuncel M, Karakas ES, Sakir TM. Closed Ender nailing of adolescent femoral shaft fractures, injury. *Injury* 1994 Oct; 25(8): 501-6.
23. Hughes BF, Sponseller PD, Thompson JD. Paediatric Femur Fractures: Effects of Spica Cast Treatment on Family and Community. *J Pediatr Orthop*. 1995 July/Aug; 15(4): 457-60.
24. Canale ST, Tolo VT. Fractures of the femur in children. *J Bone Joint Surg Am*. 1995 Feb; 77-A(2): 294-31.
25. Carey TP, Galpin RD. Flexible intramedullary nail fixation of pediatric femoral fractures. *Clin Orthop*. 1996 Nov; 332: 110-118.
26. Buckley SL. Current trends in the treatment of femoral shaft fractures in children and adolescents. *Clin Orthop Relat Res* 1997 May; (338): 60-73.
27. Bar-On E, Sagiv S, Porat S. External fixation or flexible intramedullary nailing for femoral shaft fractures in children. *J Bone Joint Surg Br*. 1997 Nov; 79(6): 975-8.
28. Mazda K, Khairouni A, Pennecot G F et al; Closed flexible intramedullary nailing of the femoral shaft fractures in children. *J Pediatr Orthop (part B)* 1997; 6: 198-202.
29. Liebergall M, Jaber S, Laster M, Abu SK, Mattan Y, Segal D. Ender nailing of acute humeral shaft fractures in multiple injuries. *Injury* 1997 Nov-Dec; 28(9-10): 577-80. 79
30. Moehing DH. Flexible intramedullary fixation of femoral fractures. *Clin Orthop Relat R*. 1998; 227: 190-200.
31. Linhart WE, Roposch A. Elastic Stable Intramedullary Nailing for Unstable Femoral Fractures in Children Preliminary Results of a New Method. *Journal of Trauma-Injury Infection & Critical Care* 1999 August; 47(2): 372-378.
32. Flynn JM, Leudtke L, Ganley TJ, Pill SG. Titanium elastic nails for pediatric femur fractures: lessons from the learning curve. *Am J Orthop* 2002 Feb; 31(2): 71-4.
33. Kiely N. Mechanical properties of different combinations of flexible nails in a model of a pediatric femoral fracture. *J Pediatr Orthop* 2002 Jul-Aug; 22(4): 424-7.
34. Buechsenschuetz KE, Mehlman CT, Shaw KJ, Crawford AH, Immerman EB. Femoral shaft fractures in children: traction and casting versus elastic stable intramedullary nailing. *Journal of Trauma-Injury Infection & Critical Care* 2002; 53(5): 914-921.
35. Yamaji T, Ando K, Nakamura T, Washimi O, Terada N, Yamada H. Femoral shaft fracture callus formation after intramedullary nailing: a comparison of interlocking and Ender nailing. *J Orthop Sci*. 2002; 7(4): 472-6.
36. Luhmann SJ, Schootman M, Schoenecker PL, Dobbs MB, Gordon JE. Complications of titanium elastic nails for pediatric femoral shaft fractures. *J Pediatr Orthop* 2003 Jul-Aug; 23(4): 443-7.
37. Rybka D, Trc T, Mrzena V. Conservative treatment of femoral fractures in children In data from the Orthopaedic Clinic of the 2nd Medical Faculty of Charles University. *Acta Chir Orthop Traumatol Cech* 2003; 70: 170-6.
38. Shah, MH, Heffernan G. Mc Guinness AJ. Early experience with titanium elastic nails in a trauma unit. *Ir Med J*. 2003 Jul-

- Aug; 96(7): 213-4.
39. Rohde RS., Mendelson SA, Grudziak JS Acute synovitis of the knee resulting from intra articular penetration as a complication of flexible intramedullary nailing of paediatric femur fractures: Report of two cases. *J Pediatr Orthop* 2003 Sep-Oct.; 23(5): 635-8.
 40. Metaizeau JP, Ancien A. Stable elastic intramedullary nailing for fractures of the femur in children. *J Bone Joint Surg Br.* 2004; 86-B(7):954-7.
 41. Jubel A, Andermahr J, Isenberg J, Schiffer G, Prokop A, Rehm KE., Experience with elastic stable intramedullary nailing (ESIN) of shaft fractures in children, *Orthopade.* 2004 Aug; 33(8): 928-35.
 42. Mahar AT, Lee SS, Impelluso T, Newton PO. Biomechanical comparison of stainless steel for fixation of simulated femoral fractures. *J Pediatr Orthop.* 2004 Nov-Dec 24(6): 638-41.80.
 43. Song HR, Chang WO, Hyun DS, Sung JK, Kyung HS, Baek SH et al. Treatment of femoral shaft fracture in young children : a comparison between conservative treatment and retrograde flexible nail. *J Pediatr Orthop B* 2004 July; 13(4): 275-280.
 44. Narayanan UG, Joshua HE, Andrew MW, Mercer R, Benjamin AA. Complications of elastic stable intramedullary nail fixation of paediatric femoral fractures, and How to avoid them. *J Pediatr Orthop* 2004 Jul-Aug 24(4): 363-9.
 45. Ngom G, Fall I, Dieme C, Sy MH, Sane JC, Ba PA, et al. Evaluation of the management of femoral shaft fractures in children by flexible intramedullary nailing. *Dakar Med* 2004; 49(3): 162-6.
 46. Houshian S, Bajaj sk Forearm fractures in children. Single bone fixation with elastic stable intramedullary nailing in 20 cases. *Injury.* 2005 Dec; 36(12):1421-6.
 47. Sink EL, Gralla J, Repine M. Complications of paediatric femur fractures treated with titanium elastic nails: a comparison of fracture types. *J Pediatr Orthop.* 2005 Sep-Oct; 25(5): 577-80.
 48. Slongo Theddy F, Hunter James B ; The principles of elastic stable intramedullary nailing in children., *Complications and failures of the ESIN technique.* *Injury.* 2005 Feb; 36.
 49. Mani US, Sabatino CT, Sanjeev S, Svach DJ, Suslak A; Behrens FF. Biomechanical comparison of flexible stainless steel and titanium nails with external fixation. *J Pediatr Orthop.* 2006 Mar-Apr; 26(2): 182-87.
 50. Lascombes P, Haumont T, Journeau P. Use and abuse of flexible intramedullary nailing in children and adolescents. *J Pediatr Orthop* 2006 Nov-Dec; 26(6): 827-34.
 51. Salem KH, Lindemann I, Keppler P. Flexible intramedullary nailing in paediatric lower limb fractures, *J Pediatr Orthop.* 2006 Jul-Aug; 26(4): 505-9.
 52. Gaid M, Jeer P. Cost analysis of managing paediatric femoral shaft fractures: flexible intramedullary nailing versus non-operative management. *Acta Orthop Belg* 2006 April; 72(2): 170-5.
 53. Singh R, Sharma SC, Magu NK, Singla A. Titanium elastic nailing in pediatric femoral diaphyseal fractures. *Indian J Orthop* 2006; 40(1):29-34.
 54. Ramseier LE, Bhaskar AR, Cole WG, Horward AW. Treatment of open femur fractures in children: comparison between external fixator and intramedullary nailing. *J Pediatr Orthop* 2007 October/November; 27(7):748-50
 55. Saikia KC, Bhuyan SK, Bhattacharya TD, Saikia SP. Titanium elastic nailing in femoral diaphyseal fracture in children in 6-16 years of age. *Indian J Orthop.* 2007 Oct-Dec; 41(4): 381-385.81
 56. Goodwin R, Mahar AT, Richard O, Suzanne S, Newton OP. Biomechanical evaluation of retrograde stabilization for femoral fracture: The effect of fracture level. *J Pediatr Orthop.* 2007 Dec; 27(8): 873-876.
 57. Rathjen K, Riccio A, Garza DDL. Stainless steel flexible intramedullary fixation of unstable femoral shaft fracture in children. *J Pediatr Orthop.* 2007 June; 27(4); 432-441.
 58. Kraus R, Schiefer U, Schafer C, Meyer C, Schnettler R. Elastic Stable Intramedullary Nailing in Pediatric Femur and Lower Leg Shaft Fractures: Intraoperative Radiation Load. *J Pediatr Orthop* 2008 Jan; 28(1): 14-16.
 59. Ying L, Stabile KJ, Shilt SJ. Biomechanical Analysis of Titanium Elastic Nail Fixation in a Pediatric Femur Fracture Model. *J Pediatr Orthop.* 2008 Dec; 28(9): 874-878.
 60. Wall EJ, Jain V, Vagmin V, Mehlman CT, Crawford AV. Complications of Titanium and Stainless Steel Elastic Nail Fixation of Pediatric Femoral Fractures]. *Bone Joint Surg Am.* 2008; 90:1305-1313.
 61. Khazzam M, Tassone C, Liu XC, Lyon R, Freeto B, Schwab J et al. Use of flexible intramedullary nail fixation in treating femur fractures in children. *Am J Orthop (Belle Mead NJ)* 2009 Mar; 38(3): E49-55.
 62. Garg S, Matthew BD, Perry LS, Scott JL, Gordon JE. Surgical treatment of traumatic pediatric humeral diaphyseal fractures with titanium elastic nails. *J Child Orthop* 2009 April; 3(2): 121-127.
 63. Gamal EA, Mohamed FM, Mohamed AK. *Acta Orthop. Belg.*, 2009; 75: 512-520.
 64. Weiss JM, Choi P, Ghatan C, Skaggs DL, Kay RM. Complications with flexible nailing of femur fractures more than double with child obesity and weight >50 kg. *J Child Orthop* 2009 Feb; 3(1): 53-8.

65. Saseendar S, Menon J, Patro D. Treatment of femoral fractures in children: is titanium elastic nailing an improvement over hip spica casting?. *J Child Orthop* 2010; 4(3):245–251.
66. Fernandez FF, Eberhardt O, Wirth T. Elastic stable intramedullary nailing as alternative therapy for the management of paediatric humeral shaft fractures *Z Orthop Unfall*. 2010 Jan; 148(1):49-53.
67. Nishikant K, Laljee C. Titanium Elastic Nails for Pediatric Femur Fractures: Clinical and Radiological Study. *Surgical Science* 2010; 1: 15-19.
68. Iqbal M, Manzoor S, Cheema GM, Ahmed E. Comparative Study of Fracture Shaft of Femur in Children Treated with Titanium Elastic Nail and Early External Fixator. *Annals* 2010 Apr – Jun; 16(2): 82-86.
69. Sink EL, Francis F, John P, Katherine F, Jane Gralla. Decreased Complications of Pediatric Femur Fractures With a Change in Management. *J Pediatric Orthop* 2010 October/November; 30 (7): 633–637. 82
70. Navdeep S, Kanav P, Suhail V, Harish D. Closed reduction and internal fixation of fractures of the shaft of the femur by the Titanium Elastic Nailing System in children. *The Internet Journal of Orthopedic Surgery*. 2010; 17(1).
71. Kanthimathi B, Kumar AK. Flexible Intramedullary Nailing for Paediatric Shaft of Femur Fractures – Does the Number of Nails Alter the Outcome? . *Malaysian Orthopaedic Journal* 2011;5(2): 28-33.
72. Hosalkar HS, Nirav KP, Robert HC, Glaser DA, Morr MA, Herman MJ. Intramedullary Nailing of Pediatric Femoral Shaft Fracture; *J Am Acad Orthop Surg* August 2011; 19:472-481.
73. Brinker MR, Cook SD, Dunlap JN, Christakis P, Elliot MN. Early Changes in Nutrient Artery Blood Flow Following Tibial Nailing With and Without Reaming: A Preliminary Study. *Journal of Orthopaedics Trauma* 1999 Feb; 13(2): 129-133.
74. Muller, AllogwerM, Willeneger H – *Manual of Internal Fixation*, Berlin, Springer, 1977
75. lynn JM, Skaggs DL, Sponseller PD, Ganley TJ, Kay RM, Kellie KK. The operative management of pediatric fractures of the lower extremity. *J Bone Joint Surg Am*. 2002; 84: 2288–300.

Conflict of Interest: Nil
Source of Support: None

Full Thesis and Master Chart available on
www.journalmedicalthesis.com

How to Cite this Article:

Sachdeva G, Kamble S. Management of Diaphyseal Fractures of Long Bones in Children with Intramedullary Flexible Nail Nailing. *Journal Medical Thesis* 2013 July-Sep; 1(1):37-41