no leishmania. The dual infection present was only detected by the dual examination.

Results in other diseases.—Not only is the method of considerable value in the diagnosis of kala-azar; it is also of special value in the diagnosis of malaria. Here, indeed, we have been forced to revise entirely our original estimate of the value of examination of thick blood films in malaria. For cases with very scanty parasites in the peripheral blood, the method is invaluable. It is also of special value in that all too common type of malarial case encountered in general practice in the tropics,—the patient who has taken sufficient quinine to render the search for parasites in thin blood films hopeless, but insufficient to control the fever.

In malaria the thick film method shews up growing trophozoite, schizont and gametocyte forms far better than it does young ring forms, and in the latter case it may often be difficult to determine the species present. In one case the microscope field appeared to be full of myriads of little dots of chromatin: only careful examination shewed in each instance the attached tag of faintly staining cytoplasm; the case was one of severe malignant tertian malaria with innumerable fine hair-like ring forms present. In such cases diagnosis is better established of course by the examination of thin films.

Our results to date in malaria are insufficient for analysis, but a few interesting cases may be mentioned:—

(1) An Anglo-Indian patient was admitted from the Andamans suffering from very severe chronic malignant tertian malaria, as proved on examination of thin blood films. He was put on to cinchona febrifuge mixture. On the 7th day the patient was still mildly febrile. Examination of thin blood films shewed nothing: but several young trophozoites of *L. malariæ* were encountered in the first thick film examined. Enquiries shewed that the patient had been taking the mixture irregularly.

(2) Prolonged search of a thin film from a case of quartan malaria shewed only two young ring forms. A thick film, taken at the same moment, shewed 10 mature rosettes and some free merozoites.

(3) In three patients, where kala-azar was suspected, the aldehyde test was completely negative. Examination of thin films shewed nothing. Before doing spleen puncture, thick films were examined, and *L. malariæ* encountered.

(4) A sample of a newly introduced remedy for malaria,—"Smalarina,"—having been received for trial, a suitable case of benign tertian malaria was selected and admitted to hospital. The treatment was administered strictly in accordance with the instructions on the pamphlet accompanying the sample. Up to the 17th day of treatment the patient ran a high intermittent fever, at first with rigors on alternate days, later with daily rigors and an irregularly febrile chart. Thin blood films shewed *P. vivax* up to the 16th day of treatment, but not subsequently. Parasites were, however, present in thick blood films on the 17th, 19th, 20th and 21st days of treatment. The patient's condition, however, was now so bad that the "Smalarina" treatment had to be discontinued, and cinchona febrifuge mixture given, with successful results.

A further matter in which we have found such thick films useful is in carrying out the differential lecocyte count in cases of leucopænia, as all types of leucocytes stain well and can be readily identified (with a few exceptions). The differential leucocyte count is often a matter of considerable difficulty in kala-azar, owing to the leucopænia present. In such thick films, however, a differential count upon 500 leucocytes can be relatively easily carried out. Lastly, the method is probably applicable to all cases where the search for very scanty blood-inhabiting protozoa in thin fims is very difficult, in man, birds and animals. In brief, we have here what we have for a long time desired, but never previously obtained in our own experience, a method of dehæmoglobinizing and staining thick blood films, which does not destroy or distort cell fixation images, and which gives good results.

SUMMARY.

A method of taking, dehæmoglobinizing and staining thick blood films is described, which, in the authors' experience (on only some 70 cases) enables a positive diagnosis to be given in kala-azar by the discovery of the parasite in such films in some 67 per cent. of cases, and which has also proved to be of value in the diagnosis of difficult cases of malaria, and in carrying out the differential leucocyte count in cases of leucopænia.

REFERENCES.

Das Gupta, B. M., 1922.—The Diagnosis of Kala-Azar by Peripheral Blood Culture. *Indian Med. Gaz.*, LVII, 6, p. 217 (Abstract).

James, S. P., 1920.—"Malaria at Home and Abroad." London, John Bale, Sons & Danielsson.

Knowles, R., 1920.—A Study of Kala-Azar. *Indian Journ. Med. Res.*, VIII, 1, p. 140.

Knowles, R., Napier, L. E., and Das Gupta, B. M., 1923.—The Kala-Azar Transmission Problem. *Indian Med. Gaz.*, LVIII, 7, p. 321.

Stitt, E. R., 1923.—"Practical Bacteriology, Blood Work and Animal Parasitology." 7th edition, London, H. K. Lewis & Co.

Szilard, P., 1923.—A method for the Isolation of White Blood Cells. *Journ. of Lab. & Clin. Med.*, VIII, 10, p. 661.

OF *ENTAMŒBA HISTOLYTICA* CARRIERS.

By HUGH W. ACTON,
MAJOR, I.M.S.,
and
R. KNOWLES,
MAJOR I.M.S.,
Calcutta School of Tropical Medicine.

To the biologist, the conception of the ideal relationship between host and parasite is that of perfect symbiosis; both host and parasite living together in mutual agreement, each leading an independent existence, yet each helpful to the other. Such an ideal relationship is reached in the case of the lichens; it may also possibly be

Figs. 1 to 19. As seen in Saline Emulsion of Stools.

Semi-diagrammatic, but drawn from actual specimens.

Entamœba histolytica cysts; figs. 1 to 8.

1. Mononucleate cyst; nucleus invisible; dull area of diffuse glycogen in upper half.
2. Mononucleate cyst; nucleus invisible; two prominent chromatoid bars; small glycogen vacuole in left half.
3. Tetranucleate cyst; nuclei invisible; two prominent chromatoid bars; no glycogen.
4. Tetranucleate cyst; nuclei invisible; no chromatoid bars; no glycogen.
5. Mononucleate minuta type of cyst; nucleus invisible; dull mass of glycogen to right.
6. Tetranucleate cyst; nuclei invisible; two prominent chromatoid bars; no glycogen.
7. Early phases of degeneration in stale stools; cytoplasm becoming progressively vacuolated; breaking down chromatin of nucleus now visible; chromatoid substance breaking down.
8. Final phase of degeneration of the cyst, which is now scarcely recognisable. From a stale stool.

Entamœba coli cysts; figs. 9 to 11.

9. Binucleate cyst with enormous, dully refringent glycogen vacuole; nuclei clearly visible and in process of division.
10. Typical adult 8-nucleate cyst; nuclei very clearly visible.
11. Giant cyst, with irregular contour, and 16 clearly visible nuclei. These forms constitute some 0.1 per cent. of *E. coli* cysts.

Endolimax nana cysts; figs. 12, 13.

Note their small size, usually oval shape, nuclei invisible, refractile volutin granules. No. 12 has a filamentous chromatoid line dimly shewing in the left part of the cyst, a feature occasionally seen in *E. nana* cysts.

Iodamœba butschlii cysts; figs. 14, 15.

Note the very thick cyst wall, irregular and varied shape; the prominent but dull mass of the glycogen vacuole, and almost invisible single nucleus.

Giardia (Lamblia) intestinalis cyst; fig. 18.

Note its oval shape, also the clear space at the lower pole between the cyst wall and the encysted parasite. Four nuclei above, pair of axostyles below, crossed by two prominent crescentic fibrils, all shewing up very clearly.

Fig. 17; large yeast with prominent vacuole and single chromatin dot.

Blastocystis hominis; fig. 18.

Typical form. Note its large central mass of para-glycogen shewing up with a refractile green look. Around this a rim of very transparent cytoplasm studded with a few brightly refractile nuclei of small size. *Blastocystis hominis* is a fungus of high type.

Chilomastix mesnili cyst; fig. 19.

Note its lemon-like shape and the clear space at the anterior pole. No structures visible, except a few brightly refractile volutin granules.

Figs. 20 to 37. As seen in Iodine Emulsion of Stools.

Entamœba histolytica cysts; figs. 20 to 27. Cf. figs. 1 to 8.

20. Mononucleate cyst with diffuse glycogen. Nucleus with fine central karyosome.
21. Mononucleate cyst with prominent glycogen vacuole in upper part, one chromatoid bar across the lower half, and "histolytica type" of nucleus.
22. Tetranucleate cyst with two chromatoid bars and nuclei shewing up well.
23. Tetranucleate cyst with no chromatoid bars and no glycogen. Nuclei typical.
24. Mononucleate minuta type of cyst with prominent glycogen vacuole in upper half.
25. Mononucleate minuta type of cyst with two chromatoid bars.

26 & 27. Degenerating cysts from stale stools. Cf. figs. 7 & 8.

Entamœba coli cysts; figs. 28 to 30. Cf. figs. 9 to 11.

28. Typical binucleate cyst with enormous, deeply staining glycogen vacuole. Nuclei elongated and in process of division.
29. Typical adult 8-nucleate cyst. Note its coarsely granular appearance in iodine as compared with the smoother look of the *E. histolytica* cyst. Cf. figs. 23 & 29. Nuclei of "coli type"; with prominent excentric karyosome and thick deposit of chromatin on nuclear membrane.
30. Giant *E. coli* cyst with 12 nuclei.

Endolimax nana cysts; figs. 31 & 32. Cf. figs. 12 & 13.

31. Mononucleate cyst. Nucleus in upper pole, scarcely visible. Bright refractile volutin granules.
32. Tetranucleate adult cyst; nuclei scarcely visible and in a cluster in upper pole. Below, in lower half, bright refractile volutin granules.

Iodamœba butschlii cysts; or "Iodine cysts;" figs. 33 & 34. Cf. figs. 14 & 15.

Note their curious deep green staining in iodine and the intensely stained glycogen vacuole. Shape and size varied. Single nucleus but dimly visible. Bright refractile volutin granules.

Giardia (Lamblia) intestinalis cyst; fig. 35. *Vide* fig. 18.

Blastocytis hominis; fig. 36. The large central mass of para-glycogen stains a deep brown and the marginal rim of cytoplasm a faint green. Four small refractile nuclei visible in the rim..

Chilomastix mesnili cyst; fig. 37. *Vide* and cf. fig. 19. The nucleus is visible in iodine and shews the characteristic signet-ring appearance. To the right inside the cyst the shadow outline of the cytostome and fourth signet-ring appearance. To the right inside the cyst the shadow outline of the cytostome and fourth flagellum within it. Note the clear space at the anterior pole.

PLATE.

CYSTS OF THE COMMONER INTESTINAL PROTOZOA.

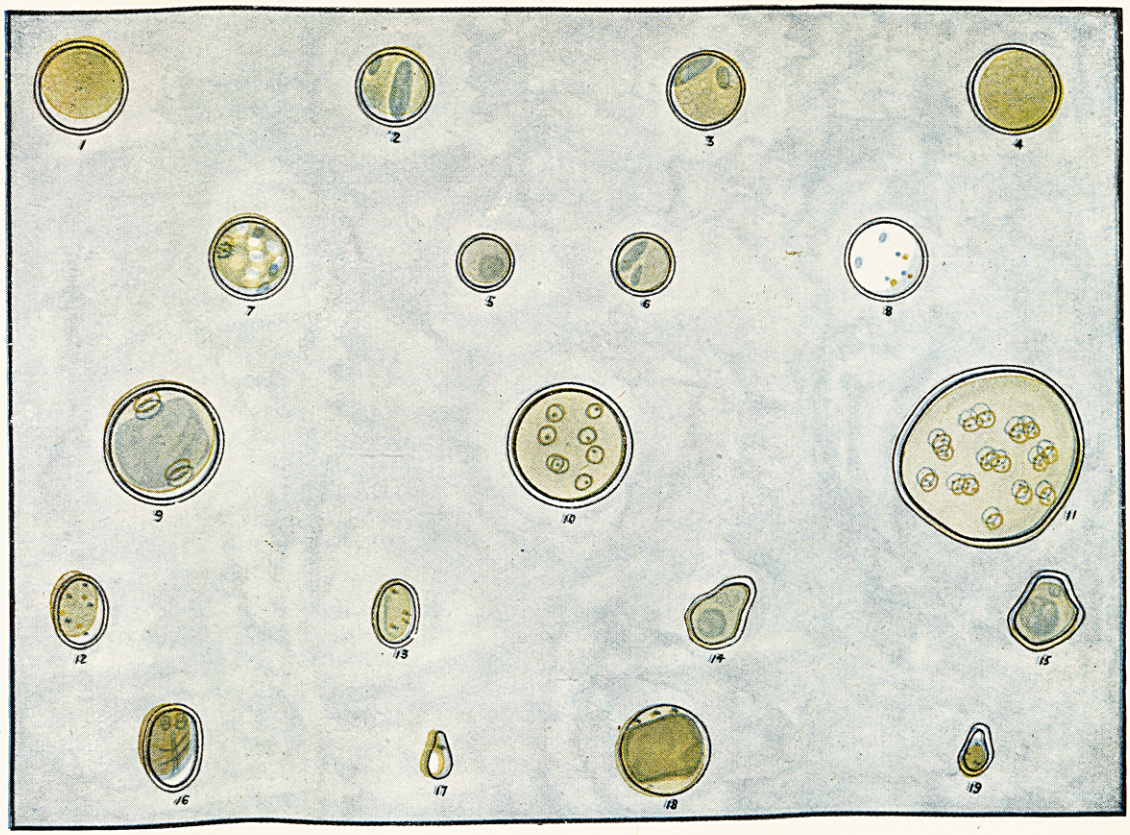

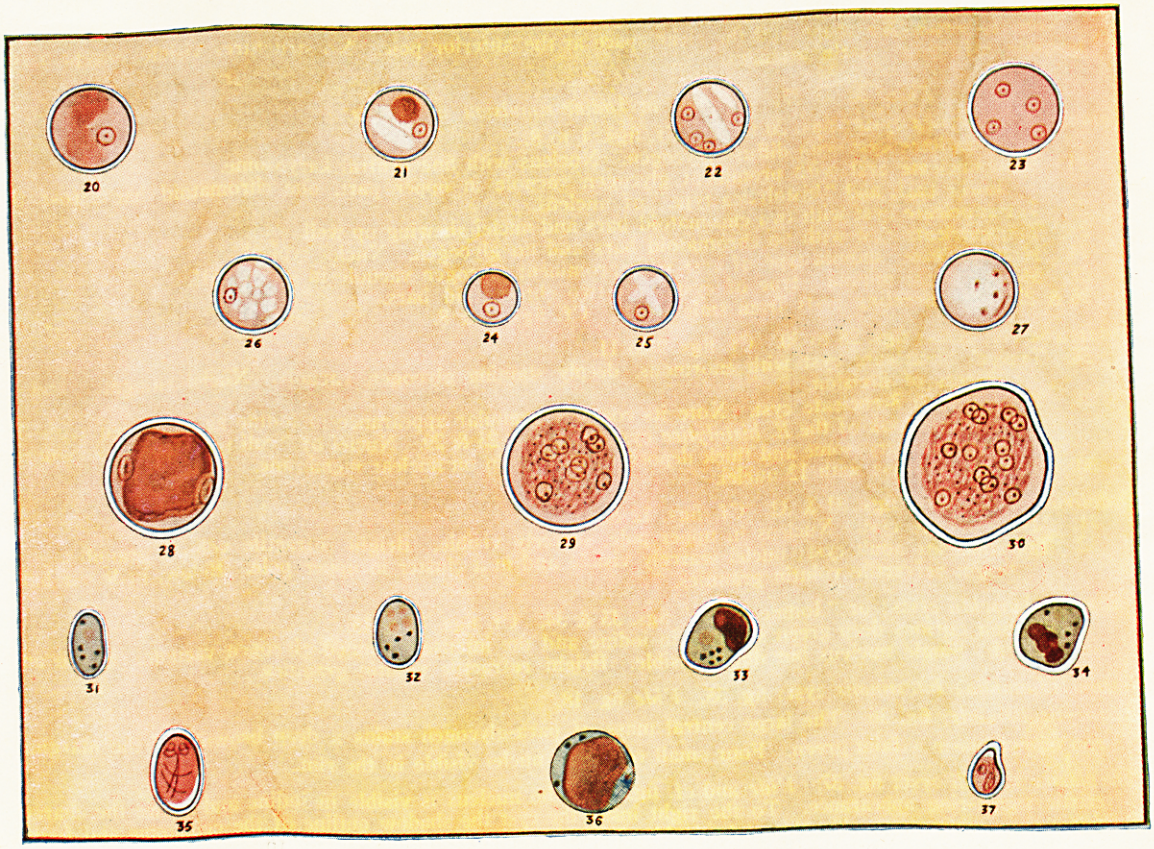

the case in infection of man with *Entamœba coli,* a possibly useful scavenger of the human colon.

In the case of infection with *E. histolytica,* the existence of the "healthy" carrier state is usually held to be unaccompanied by clinical symptoms. Here, although the parasite may be destroying the mucous membrane of the patient's colon, yet Nature is as constantly at work repairing it, and Dobell pictures the entamœbæ as living in the mucous membrane of the "healthy" carrier amid the balanced warfare which results; as Colonel Alcock well describes it in a review of Dobell and O'Connor's "Intestinal Protozoa of Man," the carrier of *E. histolytica* is here portrayed as "being in the position of Prometheus, with amœbæ perpetually gnawing at his gut, and the gut renewing itself as fast as it is eaten away—but unlike Prometheus, in suffering no torments during the process." Clinical experience during the last three years, however, leads us to doubt whether the "healthy" carrier of *E. histolytica* is always free from clinical symptoms; more often he suffers from irregularity of the bowels, is off colour, sometimes thin and losing weight; whilst in general he is not sufficiently ill to seek medical advice, we are far from assured that he is usually free from symptoms.

An interesting point about the incidence of carrier infections with *E. histolytica* is its different geographical incidence. Thus in England, according to several reports of recent years, the incidence in the general population is some 2 to 4 per cent.; in Bengal in general it is some 10 per cent.; among the followers in Indian regiments in Mesopotamia during the war—over a two years' study—it was found to be some 33 per cent. by the senior writer. Even in India there is often a marked difference as between urban and rural areas; thus in Calcutta, the incidence is very low amongst city patients, sweepers and not hospital patients being the richest source of material shewing the parasite; on the other hand, amongst patients from the *mofussil* admitted to Calcutta hospitals, the incidence is considerably higher. These findings are correlated with (1) general methods of sanitation and especially conservancy methods, where the almost universal water-carriage conservancy methods in England account for the low incidence; and (2) with climatic conditions. Thus in Mesopotamia and similar countries the prevalence of the *shimal,* a hot, dry wind blowing fiercely for weeks on end, favours desiccation of the stools passed on to the desert soil and dissemination of the cysts of *E. histolytica* which are deposited on such soil. Such a factor may account for the very different incidence in the carrier state between the Mesopotamian deserts and Calcutta city.

There is a very curious idea which is very prevalent that a "histolytica carrier" is a person carrying the *cysts* of *E. histolytica* in his intestine, such a person being often erroneously referred to in medical literature as a "cyst carrier." As Dobell and O'Connor (1921) explain, this confusion of thought is as illogical as to consider a person infected with hookworms as an "egg-carrier." The patient infected with hookworms passes ova of hookworms in his stools; similarly the "histolytica carrier" has active, vegetative *E. histolytica* living in and at the expense of the mucosa of his colon; and from these vegetative forms are derived the cysts which are passed in his formed stools. Should such a person contract bacillary dysentery, or diarrhœa due to non-amœbic causes, he may commence to pass scanty motile vegetative forms of *E. histolytica* in his stools, a source of considerable confusion to the inexperienced laboratory worker. Finally, should the local resistance of such a carrier be unduly reduced from extraneous causes, he may go down with an attack of true amœbic dysentery.

In this connection, as explained in a previous paper—(Acton and Knowles, 1924),—the examination of the microscopical character of the stools and of their degree of acidity or alkalinity, as measured in terms of the hydrogen ion potential, is of great value in coming to a correct differential diagnosis. By degrees it is hoped that the entirely erroneous conception of a "cyst-carrier" so frequent in the war and post-war literature, may be eliminated, and the true facts be grasped by the medical profession in the tropics.

The Clinical Symptoms in the E. histolytica Carrier.

Clinically we may recognise two well marked types of *E. histolytica* carriers; the first the thin, lean, cadaverous individual whose food assimilation is inadequate, who tends to be faddy and irritable, who is vaguely ill, without knowing what is wrong with him; the second the fat jovial type, with good food assimilation, a *bon viveur,* who soon discovers, however, that indulgence in "short drinks" at the club bar is apt to be followed by trouble. Together with minor ulceration of the colon mucosa by the entamœbæ goes a train of ill-defined symptoms, the elements of which may be presented as follows:—

(*a*) *Irregularity in the state of the bowels.*—The histolytica carrier has usually marked irregularity in the state of the bowels. Marked constipation may be a symptom, especially in the adult European female where amœbic dysentery has been followed by visceroptosis. On the other hand, in the usual type of case, constipation for two or three days is apt to be followed by a morning of diarrhœa with frequent stools. Especially so is this the case with the second type of carrier depicted; a few "short drinks" at the bar in the evening are followed by looseness of the bowels the next morning. The lower down the colon the lesions, the greater the tendency to looseness; such patients usually have two or three stools each morning, often with adherent mucus, and are then comfortable for the rest of the day. Dysentery is a rare complication in such persons, with an incidence of only some 5 per cent.

(*b*) *Pain*—usually described as vague and colicky, and not infrequently setting in half an hour or so after meals. This may be associated with lesions of and sometimes adhesions in the splenic and hepatic flexures; whilst hyperchlorydria may sometimes be present.

(*c*) *Fever,* of an erratic and irregular type, often not perceived by the patient, and only to be detected by taking a four hourly temperature chart; the temperature shewing occasional rises to 99° or 99.4°F.; sometimes with a daily rise suggestive of early amœbic hepatatis but without any localising symptoms in the liver. The temperature chart shewn is such an instance, a European female patient, aged 17, who was a carrier of *E. histolytica,* where all attempts to find any other cause for the low fever had negative results, but where combined bismuth and emetine treatment cured the fever.

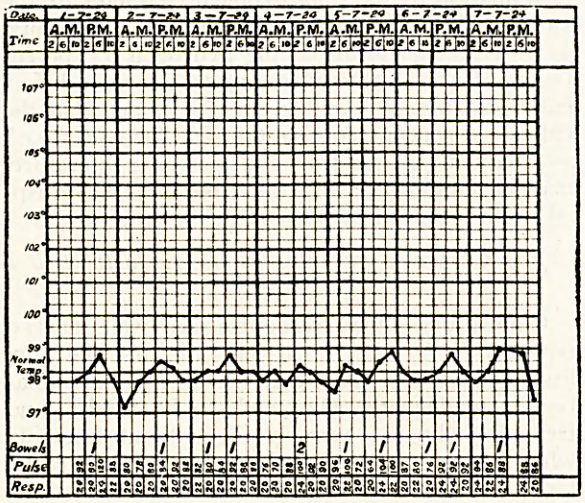

Lily, E., European female, *E. histolytica* carrier. All other examinations for any other possible cause of fever gave negative findings.

Finally, there may ensue complications, which may send the patient to seek for medical advice. Of these we would specifically mention:—

(*d*) *Bacterial embolism,* where bacteria from the intestine may pass through the minute ulcers present in the colon mucosa of the carrier into the blood stream. In most cases the bacteræmia is due to a hæmolytic streptococcus, as isolated in blood culture from such carriers; and these "streptococcal showers" in the blood stream may result in the most unexpected symptoms, apparently unconnected with any amœbic lesion:—arthritis, neuritis, sciatica, brachial or lumbar neuralgia, urticaria, giant urticaria, erythema nodosum. Together with such lesions in a chronic subject, with repeated blood invasion by hæmolytic streptococci, often goes a mild but progressive anæmia; any pernicious anæmic state being rare however.

(*e*) *Absorption of poisonous pressor bases from the ulcerated gut.*—In such carriers the bacterial flora of the gut is often very different from that of healthy persons, streptococci often being a prominent feature on plating the stools, also yeasts, and late lactose-fermentors. If such infections lead to the production of the appropriate pressor bases in the gut, we may get such conditions as asthma, urticaria, giant urticaria, and leucoderma, amenable in such instances to emetine treatment. Some examples may be quoted:—

(*a*) Anglo-Indian female, aged 42, suffered from asthma for two years, and was constipated. Examination of the stools shewed *E. histolytica* cysts. She was given a course of 12 doses of emetine hydrochloride, gr. i. The attacks of asthma ceased after the sixth injection and she has been free now for two years.

(*b*) Hindu female, aged 9, suffering from leucoderma, white patches on the face, chest, abdomen, hands and feet. *E. histolytica* cysts found, and a course of emetine given. In about six months' time all the patches disappeared except two small patches on the outer side of each ankle.

(*c*) European female, aged 28, suffered from attacks of swelling of the face and arms for the last six months. *E. histolytica* cysts were found and she was also sensitive to potatoes. After a course of emetine the giant urticaria disappeared and she is now able to eat potatoes without any ill effects.

In brief we may state that the common carrier of *E. histolytica* infection is not always or even usually free from all clinical symptoms, and that sometimes a careful search of the stool for cysts of this parasite in such conditions as arthritis, neuritis, asthma, urticaria, leucoderma and erythema nodosum may be followed by discovery of the cysts, the appropriate bismuth and emetine treatment, and recovery from the symptoms of which the patient originally complained.

Laboratory Diagnosis of the E. histolytica Carrier.

Here we may consider the proof of the infection present under the following heads:—

(*a*) *Macroscopic* examination of the stools, where one may often find definite traces of mucus adherent to the scybalæ, or in a loose stool; such stools often being very offensive in character, and containing much undigested residues, especially of meat, peas, vegetables, etc.

(*b*) *Reaction,* which is usually alkaline to litmus, whereas the stool of acute amœbic dysentery is usually acid. Actively motile *E. histolytica* is usually found at a pH of about 6.35, whereas the cysts occur at a pH varying from 6.09 to 7.49 with a mean at 7.24, and in a much more alkaline environment.

(*c*) *Microscopically by the finding of E. histolytica cysts.*—Only such a positive finding can confirm the presence of the carrier state, and examinations in suspected cases should be frequent and repeated. If the stool be loose, the motile and vegetative or the pre-cystic forms may be encountered, and the former is usually readily identified if the stool be fresh. Cysts, however,

constitute the more usual finding. The technique for the examination has already been given in a previous paper,—(Acton and Knowles, 1924); —and may be here summarised by saying that examination of thin emulsions of the interior of the stool in both (*a*) normal saline, and in (*b*) a solution of iodine 1 part; potass. iodide 2 parts, and water 100 parts is essential.

The examination of stools for the cysts of *E. histolytica* is not easy, and the more experienced the laboratory worker, the more difficult he recognises such a procedure to be. The mere presence of entamœbic cysts of any type in the stool does not constitute evidence of histolytica infection; it is necessary to be certain that the cysts are those of the species of entamœba concerned. And to the laboratory worker who is still uncertain as to identification we may recommend two procedures; the first the careful study of Dobell and O'Connor's "Human Intestinal Protozoa," the second the repeated and careful examination of stools of sweepers, in which sooner or later typical cysts of all the four common intestinal entamœbæ of man will be encountered. The study of such material is an education in itself.

The cyst of *E. histolytica* has been so admirably described by Dobell and by Dobell and O'Connor that any further description of it is almost superfluous. For the benefit of those who have not access to the literature, however, we may note the following points in its identification. These, as well as the cysts of the other common intestinal protozoa of man are illustrated in the accompanying colour plate.

The cyst of *E. histolytica* is usually spherical and with a relatively thin but clear-cut cyst wall. Very rarely indeed (far less so than is the case with the cyst of *E. coli*) it is somewhat oval or distorted. In size it varies in diameter from 6 to 18 μ; four "races" of different diameters being recognised; thus some persons usually pass small cysts, others larger cysts. As encystment proceeds and as the pre-cyst passes into the adult cyst, the single nucleus divides into two and later four nuclei. But, whereas with *E. coli* some 87 per cent. of cysts seen in the formed stool are adult and 8-nucleate, *E. histolytica* shews greater variation; some 53 per cent. of cysts being adult 4-nucleate ones, but mono- and bi-nucleate cysts being frequently encountered in the same stool.

Glycogen is a variable feature in the cyst of *E. histolytica*. Sometimes it is prominent, and may be seen as a prominent glycogen vacuole in the mono-nucleate phase. This, however, is not usual; more usually what glycogen is present is diffused throughout the cyst and stains as a diffuse brown with iodine. The big, deeply-staining glycogen vacuole, so often a prominent feature of the cyst of *E. coli* at the bi-nucleate phase, is not seen with *E. histolytica*.

The nuclei are *invisible* in saline emulsion of a fresh stool; with iodine they shew the typical "histolytica characters," having a fine central dot-like karysome, a thin deposit of chromatin on the inner aspect of the nuclear membrane, and being of much finer and more delicate type than are the nuclei of the *E. coli* cyst.

Finally, as the most distinctive feature of the *E. histolytica* cyst, we have the presence of coarse chromatoid bars, the most characteristic feature of this species of cyst. Here a word of caution is necessary. When present, such chromatoid masses are unmistakable; but their entire absence does not negative a diagnosis of *E. histolytica*. Present in some 30 per cent. or more of histolytica cysts, their appearances may vary widely. In saline emulsion they may be (*a*) but dimly visible as dull, bar-like masses with indefinite outline; (*b*) very prominent indeed, so that they stand out as the most prominent feature of the cyst, with bright, very refractile clear-cut outline, and absolutely unmistakable; or (*c*) of intermediate, dull, semi-refractile appearance. They are always rod-, bar-shaped or massive in size when present, and the cyst may be full of such masses or may shew only one or two, or none. In iodine emulsion they scarcely shew up at all.

Lastly, one may draw attention to a point of real diagnostic value. In iodine emulsion the cyst of *E. coli* has a peculiar deep brown *granular* look; that of *E. histolytica* a smooth, *non-granular* appearance; that of *I. butschlii* a clear greenish colour with its prominent mahogany-brown glycogen vacuole.

But if the stool be some hours old, appearances have changed in the cyst. Of all cysts of *E. histolytica* present, all mono- and bi-nucleate cysts have degenerated, and some 50 per cent. of the adult tetra-nucleate ones. As the cysts die in the passed stool, their cytoplasm becomes progressively more and more vacuolated, the vacuoles being spherical and tending to fuse together. The nucleus or nuclei commence to disintegrate with the result that one or more irregular greenish refractile rings, easily visible, replace the delicate invisible nuclear membranes and their deposit of chromatin of the fresh cyst as seen in saline, and erratic refractile particles of chromatin are seen within them. The contents of the cyst tend to shrink away from the cyst wall, leaving an empty peripheral zone within the cyst wall, and in the centre a mass of vacuolated protoplasm. Finally, the ultimate picture of a degenerated histolytica cyst in a stale stool is a thin refractile cyst wall, practically devoid of contents, and very misleading in appearance.

The tyro in stool examinations is usually content to merely look for "cysts"; the more experienced worker knows how difficult the diagnosis of species is; the worker who has had considerable experience begins to appreciate the difficulties which are encountered with aberrant forms and degenerated cysts. A thin emulsion which will give clear definition, a good lens, and patience are

the three chief pre-requisites for accuracy; and the laboratory worker who has not examined some 1,000 stools is still a tyro at identification. One final point may be noticed; if a stool shews numerous entamœbic cysts, almost all of which are tetranucleate, the infection present is either one with *E. histolytica* or one with *E. nana*, since the tetranucleate phase of the *E. coli* cyst is the rarest form encountered. The cyst of *E. nana* is readily identified by (*a*) its usual presence in very great numbers in the stool; (*b*) its oval shape and small size, although many cysts of *E. histolytica* may be as small in diameter; (*c*) its bright volutin granules, which are usually prominent; and (*d*) its faintly greenish tinge in iodine emulsion as against the smooth brown appearance of the histolytica cyst.

For the sake of the beginner, the plate illustrating this paper has been included, and has been drawn from original preparations, although the splendid plates of Dobell and of Dobell and O'Connor render it almost superfluous, except to such readers as have not access to the literature.

The presence of Charcot-Leyden crystals is an added factor in diagnosis. These have been described in our previous paper (*loc. cit.*), and need here be no further commented on. The presence of these crystals is sufficient to establish a diagnosis of "amœbic infection probably present," and further search in such cases will usually reveal the presence of cysts of *E. histolytica*. It only remains to add that the diagnosis of histolytica carriers through the post is a simple and easy procedure; a typical portion of fresh stool should be finely emulsified in a pestle and mortar in the iodine solution referred to above, be poured into a test tube which is then corked and posted to the laboratory. On receipt the sample is centrifuged and the deposit examined for cysts. The cyst of *E. histolytica* is well preserved in such an emulsion for two to three weeks.

(*d*) *Cultural Examination of the Stool.*—This affords indirect but useful aid. On a MacConkey plate the stool of a histolytica carrier usually yields a large number of small colonies, both of lactose-fermentors and of non-lactose-fermentors. Streptococci and yeasts are often prominent, also late lactose-fermentors and lactose-fermentors quite different from those in a healthy stool, not infrequently the *B. proteus*. A suggestive culture shewing such a bacteriological picture should lead one to search the stools for *E. histolytica* cysts again, and its value should not be neglected.

Treatment.

When it comes to the question of treatment of histolytica carriers, we are up against a difficult proposition. Since some 10 to 15 per cent. of humanity in the tropics are such carriers, it is obviously impossible to eradicate the infection on any wide scale, and all such attempts with reference to bodies of troops in the United Kingdom have now been abandoned. In the case of regimental and other messes and restaurants the case is different; here carriers who handle foodstuffs should be sought for and radically treated. With regard to the ordinary "healthy" carrier, the advisability of treatment is a question of the symptoms shewn. If symptoms such as those above outlined are present, then full and efficient treatment is indicated.

We have to-day by no means reached finality in the treatment of either amœbic dysentery or of the histolytica carrier; in fact emetine may some day be replaced by some far more efficient drug. In the meantime, however, it is the sheet anchor of treatment. For the carrier the treatment to be given should be one or two courses of the combined bismuth and emetine treatment advocated in our former paper (Acton and Knowles, 1924), with the exception that the patient need not be confined to bed whilst under treatment. Possibly the use of emetine intravenously with a full course of bismuth by the mouth may prove to be more efficacious than that of emetine subcutaneously. The toxicity of emetine is very considerable, but we believe that a safe margin may be found for intravenous medication and are at present studying the possibilities of combining Deek's intensive bismuth treatment orally with emetine administered intravenously. We would emphasise, however, that when once detected the carrier needs quite as vigorous treatment as does the case of acute amœbic dysentery, and especially so if there is any history of dysentery in the case, or if he handles foodstuffs.

After treatment the stools of the carrier should be examined once a week for at least six, and preferably eight weeks, for *E. histolytica* cysts, as nothing but repeated examinations will ensure that cure is complete.

REFERENCES.

Acton, H. W. and Knowles, R., 1924.—On the Dysenteries of India. *Ind. Med. Gaz.*, July, 1924. LIX. No. 7, p. 325.

Dobell, C., 1919.—The Amœbæ Living in Man. London, John Bale, Sons and Danielsson.

Dobell, C., and O'Connor, F. W., 1921.—The Intestinal Protozoa of Man. London, John Bale, Sons and Danielsson.

A NEW DEVICE FOR IONIZATION OF THE URETHRA.

By J. H. BARRETT,

CAPTAIN I.M.S.

Bannu, N. W. F. P.

THE following is a description of two electrodes which were found successful in the ionic