

Final Nasolacrimal Ostium After External Dacryocystorhinostomy

Bülent Yazici, MD; Zeynep Yazici, MD

Objective: To evaluate the nasolacrimal ostium created after successful external dacryocystorhinostomy.

Methods: This prospective study included 41 successful primary external dacryocystorhinostomies performed in 41 patients with nasolacrimal duct obstruction (33 women and 8 men; age range, 19-75 years). The dimensions of osteotomy were measured during surgery. Patients alternately underwent either anterior only or anterior and posterior flap anastomosis between the lacrimal sac and the nasal mucosa. Digital subtraction macrodacryocystography was performed to assess the nasolacrimal ostium 6 months after surgery.

Results: Dacryocystography showed that the lacrimal sac had re-formed in 40 (98%) of 41 patients. The nasolacrimal ostium was located at the inferior part of the re-formed sac in 37 patients (90%) and at the middle part

of the re-formed sac in 3 patients (7%). Mean ostium heights were 3.8 mm (range, 1.6-6.5 mm) in patients who underwent anterior flap anastomosis and 3.1 mm (range, 1.2-5.2 mm) in those who underwent both anterior and posterior flap anastomosis ($P = .22$). Ostium height did not correlate with osteotomy size (mean, 183 mm²; range, 132-266 mm²; $P = .10$).

Conclusions: This study confirms that after successful dacryocystorhinostomy, the nasolacrimal anastomosis contracts into a relatively small ostium. Contrary to common belief, the lacrimal sac often re-forms after surgery. The final ostium frequently develops at the inferior part of the regenerated sac. Suturing the posterior lacrimal and nasal flaps in addition to the anterior flaps does not significantly affect the ultimate ostium size.

Arch Ophthalmol. 2003;121:76-80

THE AIM OF dacryocystorhinostomy (DCR) is to create a new drainage pathway bypassing lacrimal obstruction. In external DCR, a large bony window is opened in the lateral nasal wall, and a mucosal anastomosis is created between the lacrimal sac and the nasal cavity. The success of the operation depends on the surgical anastomosis remaining patent and converting to a wide enough epithelial-lined passage.

Previous studies used nasal endoscopy and B-mode ultrasonography to assess the nasolacrimal ostium after successful DCR. The endoscopic study¹ found that the healed intranasal ostium was small relative to the intraoperative osteotomy and mucosal anastomosis; the mean final ostium diameter was only 1.80 mm. Ultrasonographically, the healed mucosal anastomosis was much larger, averaging 71 mm².² The considerable discrepancy between the results of the 2 studies was attributed to differences in both osteotomy size and anastomosis technique.²

It is well-known that the lacrimal sac can regenerate after unsuccessful DCR, as

occurs in the sump syndrome.³⁻⁶ However, it is unclear what happens to the lacrimal sac after successful DCR. Some authors²⁻⁷ believe that the sac ceases to exist as a separate anatomical structure and turns into a cavity on the lateral nasal wall, and that tears drain directly into this cavity from the canaliculi. The presence of an incompletely opened sac in patients who underwent unsuccessful DCR is considered a possible cause of surgical failure.³⁻⁵

In this study, we used digital subtraction macrodacryocystography to evaluate anatomical changes in the distal lacrimal pathway after successful DCR and to measure the final nasolacrimal ostium. This technique is considered the best available method for demonstrating the lacrimal drainage system in detail, and it has long been used for diagnostic purposes.^{8,9}

METHODS

PATIENTS

This prospective study included 41 patients with nasolacrimal duct obstruction who underwent external DCR between September 1,

From the Departments of Ophthalmology (Dr B. Yazici) and Radiology (Dr Z. Yazici), Uludag University School of Medicine, Bursa, Turkey.

1999, and April 30, 2000. There were 33 women and 8 men, ranging in age from 19 to 75 years (mean age, 44 years). The lacrimal obstruction was primary acquired in 38 patients, congenital in 2, and secondary to previous sinonasal surgery in 1. Preoperative dacryocystograms were obtained for all patients.

Patients who had a canalicular obstruction or a history of unsuccessful lacrimal surgery were excluded from the study. The right eye was selected in patients who underwent bilateral simultaneous DCR. We excluded 7 of the initially recorded 48 patients because of posterior flap inadequacy (3 patients), lack of follow-up (2 patients), and unsatisfactory postoperative dacryocystography (2 patients). Informed consent was obtained from the patients after the aims and the potential risks of the procedures had been fully explained. The study protocols were in accord with the Uludag University Faculty of Medicine institutional guidelines and the Declaration of Helsinki.

PROCEDURES

External DCR was performed under local anesthesia in all but 2 patients on an outpatient basis. All operations were performed or supervised by one surgeon (B.Y.). After skin incision, the subcutaneous soft tissues were separated by blunt dissection down to the periosteum. The periosteum and the lower half of the anterior limb of the medial canthal tendon were incised and reflected with a periosteal elevator to expose the lacrimal sac fossa. The thin lacrimal bone was infrafractured, and a rectangular bony opening was created using a Kerrison punch. Bone removal included the bone beneath the medial canthal tendon superiorly, the superomedial part of the nasolacrimal duct inferiorly, and the frontal process of the maxilla anteriorly. The ethmoid cells between the lacrimal sac and the nasal mucosa were carefully cleaned. The vertical and anteroposterior dimensions of the bony opening were measured with calipers.

Two different techniques were alternately used to anastomose the lacrimal sac to the nasal cavity. In patients assigned to anterior flap anastomosis, an H-shaped incision was made in the lacrimal sac and a U-shaped incision was made in the nasal mucosa. The sac was opened from the upper limit of the fundus down into the proximal nasolacrimal duct. The posterior flap was completely resected and sent for pathologic examination. In patients assigned to anterior and posterior flap anastomosis, a horizontal H-shaped incision was made in both tissues. Flaps were trimmed and sutured together using 6-0 plain catgut. Surgery was completed by closing the orbicularis muscle and skin separately. Silicone intubation was not performed in any patient.

Postoperative medication included 0.1% dexamethasone sodium phosphate and 3% ofloxacin eyedrops 4 times daily for 1 week. Patients were seen 1 day, 1 week, 3 months, and 6 months after surgery, and lacrimal irrigation was performed at each visit. Surgery was considered successful when the patient had no or minimal conditional epiphora and the fluid passed freely without reflux on lacrimal irrigation.

Six months after surgery, digital subtraction macrodacryocystography was performed by the same physician (Z.Y.) in all patients. Digital fluoroscopic equipment coupled with a television monitoring system (Siemens Polytron 1000 DSA Multiscop; Siemens, Erlangen, Germany) was used at $\times 2$ magnification. The patient was put in the supine position. A radiopaque ruler (model 07-533; Nuclear Associates, Invision Co, New York, NY) was placed near the patient's cheek in the same plane with the medial canthus. Under topical anesthesia, thin dacryocystography cannulas (Song Naso-Lacrimal Duct Stent Set; Cook, Queensland, Australia) were inserted into both inferior canaliculi. A digital scout radiograph was obtained as a

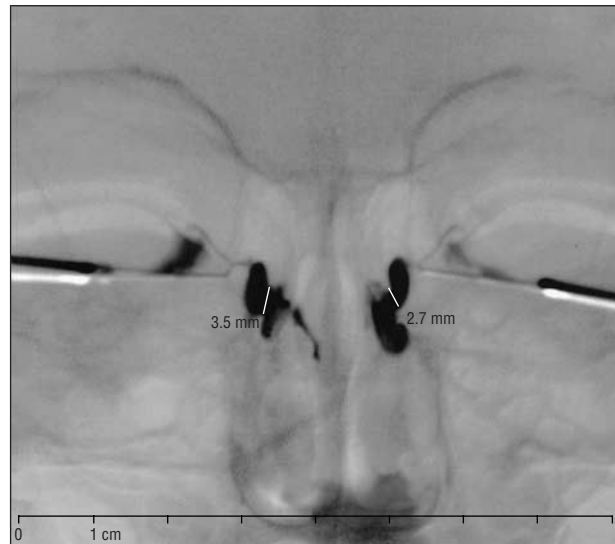


Figure 1. Digital subtraction macrodacryocystogram after bilateral external dacryocystorhinostomy. On both sides the lacrimal sac cavity appears to be re-formed and filled with contrast medium.

mask. Then, sequential digital images were obtained during injection of a water-soluble contrast medium (Omnipaque, 300 mg/mL; Nycomed, Carrigtwohill, Ireland) at a rate of 3 exposures per second. The images were reviewed on the monitor, and the best image of the nasolacrimal ostium was selected.

The radiopaque ruler served as a calibration object. It was visible in all subtracted images. For measurement, if need, we switched the subtracted image to the native image with the anatomical background. Calibration defined the number of pixels per centimeter and, thus, permitted the calculation of lengths. The distance between the superior and inferior limits of the ostium was marked on the monitor. The system then calculated this distance and displayed the result as converted from pixels to the corresponding measurement in millimeters. The course of the contrast medium, the contours of the medial sac wall, the anatomy of the bony background, and the contours of the lacrimal sac on the other side were helpful in deciding on the location of the ostium. We also measured a 2-mm distance on the radiopaque ruler in the images of 15 patients to assess the accuracy of the measurement method regarding small distances. The device measured the 2-mm distance with a mean absolute difference of 0.09 mm (range, 0.0-0.2 mm).

STATISTICAL ANALYSIS

The correlation between osteotomy size and height of the final ostium was tested using Pearson correlation analysis. The osteotomy area was calculated by multiplying the vertical and anteroposterior dimensions of the bony opening. The 2 anastomosis groups were compared for ostium height using the *t* test.

RESULTS

External DCR was successful in all patients. Postoperative dacryocystography demonstrated that the lacrimal sac had re-formed in 40 patients (98%) as a cavity filled with contrast medium (**Figure 1**). The contrast medium passed from an ostium on the medial lacrimal sac wall into the nasal cavity. The nasolacrimal ostium was located at the inferior part of the sac in 37 patients (90%) (**Figure 2**) and at the middle part of the sac in 3 pa-

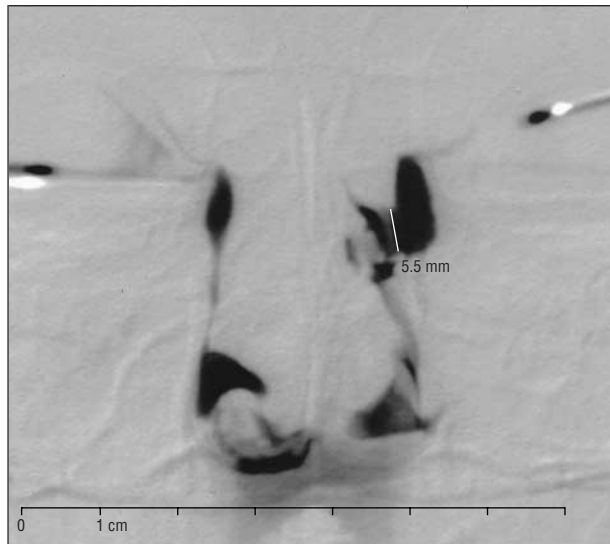


Figure 2. Digital subtraction macrodacryocystogram. Patient's left side, The nasolacrimal ostium developed at the inferior part of the lacrimal sac in 90% of patients after external dacryocystorhinostomy. Patient's right side, The nasolacrimal duct appears to be narrowed.

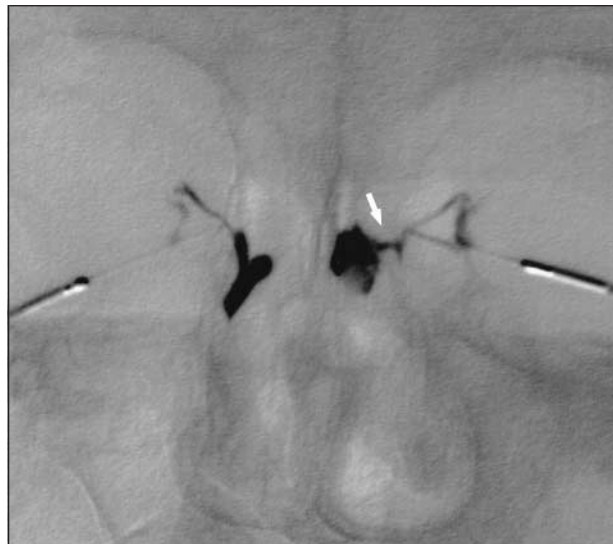

Figure 4. Patient's left side, No regeneration of the sac occurred after external dacryocystorhinostomy. A fistulous tract (arrow) connects the common canaliculus to the nasal cavity. Patient's right side, The nasolacrimal ostium appears at the inferior part of the regenerated sac.

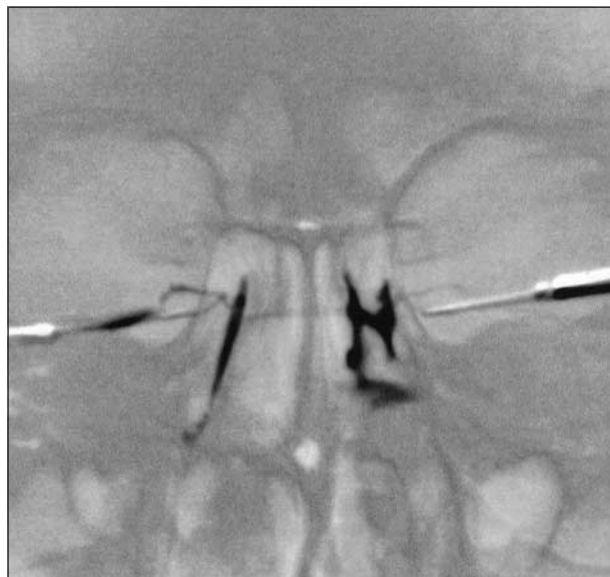

Figure 3. The early phase of postoperative dacryocystography. Patient's left side, The nasolacrimal ostium is located at the middle part of the lacrimal sac. Patient's right side, The contrast medium filling the sac.

tients (7%) (**Figure 3**). In 1 patient (2%), the sac had not re-formed, and the contrast medium drained through a fistulous tract into the nasal cavity (**Figure 4**).

Demographic and clinical characteristics of the 2 patient groups are listed in the **Table**. The mean ostium height was 3.8 mm (range, 1.6-6.5 mm) in patients who underwent anterior flap anastomosis and 3.1 mm (range, 1.2-5.2 mm) in patients who underwent both anterior and posterior flap anastomosis; the difference was not statistically significant ($P = .22$, unpaired t test). For all patients, the mean ostium height was 3.5 mm.

The mean osteotomy area was 183 mm² when calculated for all patients (range, 132-266 mm²). The correlation between intraoperative osteotomy size and fi-

Characteristics of 2 Patient Groups Randomized by Anastomosis Technique Used During External Dacryocystorhinostomy

Variable	Anastomosis Technique		P Value*
	Anterior Flap (n = 22)	Anterior and Posterior Flap (n = 19)	
Age, mean (range), y	42.3 (25-67)	46.4 (19-75)	.43
Sex, F/M	17/5	16/3	...
Cause of obstruction, No. of patients			
Idiopathic	19	19	...
Congenital	2	0	...
Sinonasal surgery	1	0	...
Intraoperative osteotomy size, mean (range), mm ²	179 (132-243)	188 (143-266)	.37
Nasolacrimal ostium height, mean (range), mm†	3.8 (1.6-6.5)	3.1 (1.2-5.2)	.22

*Calculated using the unpaired t test. Ellipses indicate not applicable.

†The final nasolacrimal ostium heights were measured using digital subtraction macrodacryocystography 6 months after surgery.

nal ostium height was not statistically significant ($P = .10$, Pearson correlation analysis).

COMMENT

Linberg et al¹ first examined the nasolacrimal ostium after successful external DCR using nasal endoscopy and found that the mean ostium diameter was 1.80 mm. According to the formula and the data given in this study, the area of the ostium, calculated as an ellipse, ranged from 0.8 to 9.4 mm² (mean, 3.0 mm²). In other studies^{10,11} using nasal endoscopy, the mean ostium size was 1.5 mm² after endoscopic DCR and 10.8 mm² after external DCR with silicone intubation. Kao et al¹¹ also re-

ported that the final ostium was significantly larger when mitomycin C was used intraoperatively.

Some authors^{2,4,7} believe that the size of the nasolacrimal ostium should be much larger than is reported in endoscopic studies. Hurwitz⁴ stated that it is extremely difficult to determine the relationship between the internal punctum and the site of the anastomosed flaps and where the anastomotic site is located by using nasal endoscopy after a DCR because in a successful DCR the sac becomes incorporated into the side of the nose. To differentiate the intranasal ostium from the internal punctum, Baldeschi et al⁷ measured the distances between the lacrimal puncta and the internal aperture of the common canaliculus using a Bowman probe under endoscopic control during and after external DCR. They observed a small aperture approximately 2 mm in diameter within a mucosal depression on the nasal wall and found that the spatial location of this aperture corresponded to the internal aperture of the common canaliculus. The authors concluded that the previously reported 1.8-mm size of the intranasal ostium might in fact be the measurement of the internal punctum.

Ezra et al,² using B-mode ultrasonography in 16 cases, measured the mean size of the final nasolacrimal anastomosis as 71 mm² (range, 3-208 mm²) 6 months after DCR. This value was, on average, approximately 40% of the intraoperative size of the osteotomy. In 2 failed DCRs, anastomosis sizes were 3 and 4 mm². Ultrasonographically, they did not observe a significant sump of residual, unopened lacrimal sac in any case. Ezra et al² attribute the large difference in final ostium size between this study and others to their performing a larger osteotomy combined with partial ethmoidectomy and to the anastomosis of both the anterior and posterior mucosal flaps.

We used digital subtraction macrodacryocystography to assess the healed nasolacrimal ostium after external DCR. This method allows the recording of sequential images while contrast medium is passing through the lacrimal drainage pathway.⁹ The early images obtained while contrast medium is passing from the sac to the nasal cavity are ideal for assessment. In the later phases, the nasolacrimal ostium may be obscured by the dispersion of the contrast medium in the nasal cavity. The vertical dimension of the ostium can be measured precisely using this method. This measurement data could well represent the total ostium area that, according to endoscopic observations, is ellipsoid or round.^{1,11} In our study, the average height of the healed ostium was 3.5 mm (range, 1.2-6.5 mm) for all patients.

Nasolacrimal ostium sizes, as generated after external DCR, show a wide variation both within and among studies. It is unclear which factors are responsible for this variability. There was no significant correlation between the sizes of the intraoperative bony opening and the final nasolacrimal ostium in our study, as in the other studies.^{1,2} However, it would be inappropriate to conclude that any bone-opening size may result in a functional anastomosis. Average osteotomy area was 140 and 235 mm², respectively, in the previous 2 studies^{1,2} and 183 mm² in this study. Smaller osteotomies, which do not allow obtaining of adequate mucosal flaps, may adversely affect surgical results. Mucosal flap dimensions,

although not measured in this study, can be a significant factor determining the final ostium diameter.¹²

It is widely held that the suturing of both the anterior and posterior flaps would reduce mucosal scarring and increase the chance of surgical success.^{2-5,13,14} In this study, we compared 2 groups randomized by anastomosis technique. Mean ostium height was larger in the DCR group with anterior flap anastomosis than in those with both anterior and posterior flap anastomosis, although the difference was not statistically significant (3.8 vs 3.1 mm; $P = .22$, unpaired t test). This result is in accord with the endoscopic observation that the intranasal ostium shrinks to a small size, irrespective of whether only the anterior flaps or both the anterior and posterior flaps were used.¹

It is commonly believed that after successful DCR, the lacrimal sac has been eliminated and converted into the sidewall of the nose.^{2,4,5,7} Although postoperative endoscopy shows the intranasal aspect of the ostium, it does not give information about the rest of the lacrimal drainage pathway. In this study, postoperative dacryocystography revealed that in all patients, except one, the lacrimal sac had re-formed after external DCR. Suturing the posterior lacrimal and nasal flaps did not prevent regeneration of the sac. Rizk and Dark¹⁵ report that even after dacryocystectomy, in 10 of 28 cases the lacrimal sac had regenerated; the re-formed sacs were remarkably complete in both anatomical extent and histological architecture. We do not know how the medial sac wall could form again, although it was united with the nasal mucosa at surgery. New bone growth around the osteotomy might result in the sac being separated from the nasal cavity, but, according to the previous studies, such a condition is not likely.^{3,16}

Dacryocystography showed that in most patients (90%), the final nasolacrimal ostium developed at the lower part of the regenerated sac. This location conforms to the natural course of tear drainage. Possibly, the tear flow down the lateral sac wall toward the nasolacrimal duct after surgery and the continuous passage of fluid play a significant role in the formation of the mucosal ostium.

In 3 (7%) of 41 patients, the nasolacrimal ostium was located at the middle part of the regenerated sac, as has been described in the sump syndrome. A 2-flap technique had been used in 2 of these patients, and an anterior flap technique had been used in the other. Postoperative healing was uncomplicated in all patients. Dacryocystographic ostium heights were 2.1, 3.0, and 1.6 mm in these patients. The middle turbinate blocking the lower part of the anastomosis area could be distinguished in the postoperative dacryocystograms of 2 patients (Figure 3 and **Figure 5**). The intranasal endoscopy confirmed that the anterior tip of the middle turbinate adhered to the lateral nasal wall at the osteotomy site in both patients. The patients did not have any lacrimal symptoms during follow-up. The sump syndrome is characterized by a part of the sac remaining below the ostium in patients with failed DCR.³ It is presumed that tear stasis in the lacrimal sump may predispose infection and surgical failure.⁶ We believe that a lacrimal sump, per se, is not a rare condition after DCR as

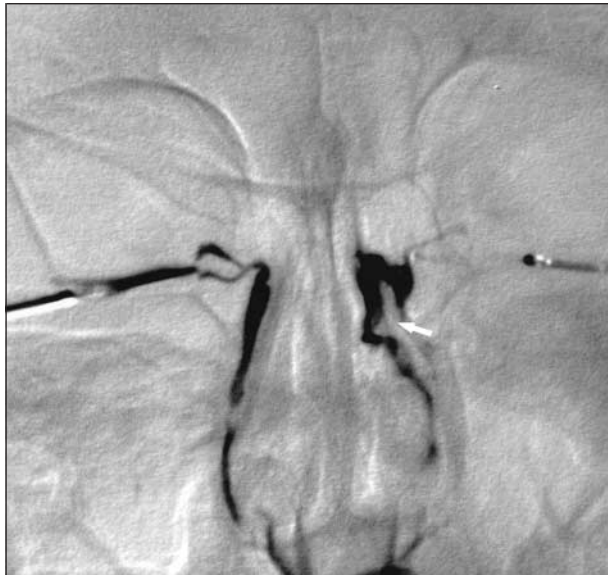

Figure 5. Patient's left side, The nasolacrimal ostium positioned at the middle part of the sac. The middle concha (arrow) appears to be medial to the lower part of ostium. The contrast medium is delineating the contour of the middle concha. Patient's right side, The contrast medium is passing freely to the nasal cavity.

previously thought, and it may not cause a problem if the final ostium is large enough and functional.

In 1 patient (2%), the lacrimal sac did not regenerate, and a fistulous tract was connecting the canalicular segment to the nasal cavity. This occurred in a 75-year-old patient receiving cytotoxic and antiproliferative agents for chronic myeloid leukemia. During surgery, he had a large sac with purulent content and underwent both anterior and posterior flap anastomosis. On the postoperative dacryocystography, the fistula height was 1.2 mm. In this patient, the sac also did not re-form well on the contralateral side after external DCR with silicone intubation (Figure 4).

The classic teaching on external DCR advises that the bone opening created at surgery be at least 15×15 mm in diameter.¹⁷⁻¹⁹ This teaching suggests that all bone between the medial wall of the sac and the nose should be removed, leaving approximately 5 mm around the internal punctum free of bone. Large osteotomy is needed to suture the full length of the sac wall to the nasal cavity and prevent canalicular obstruction due to scar formation around the internal punctum. It would also be helpful to separate the anterior and posterior flaps further. Postoperative healing is conceived so that the surgical anastomosis would remain open in all extent, the sac integrates into the nasal wall, and tears drain directly from the canaliculi into the nasal cavity. However, in our study, postoperative dacryocystography showed that the lacrimal sac regenerated after external DCR in most patients and that the surgical anastomosis converted into a relatively small ostium at the lower part of the sac.

From a critical viewpoint, it should be stated that there is a remarkable discordance anatomically between the extent of external DCR surgery and its results. New surgical techniques may lessen this discordance without compromising the high success rate of external DCR surgery.

Submitted for publication March 4, 2002; final revision received July 11, 2002; accepted September 18, 2002.

We thank Dale R. Meyer, MD, Albany, NY, for his helpful criticism and advice.

Corresponding author: Bülent Yazici, MD, Department of Ophthalmology, Uludag University School of Medicine, Gorukle Bursa, 16059 Turkey (e-mail: byazici@uludag.edu.tr).

REFERENCES

1. Linberg JV, Anderson RL, Bumsted RM, Barreras R. Study of intranasal ostium external dacryocystorhinostomy. *Arch Ophthalmol.* 1982;100:1758-1762.
2. Ezra E, Restori M, Mannor GE, Rose GE. Ultrasonic assessment of rhinostomy size following external dacryocystorhinostomy. *Br J Ophthalmol.* 1998;82:786-789.
3. Welham RA, Wulc AE. Management of unsuccessful lacrimal surgery. *Br J Ophthalmol.* 1987;71:152-157.
4. Hurwitz JJ. Dacryocystorhinostomy. In: Hurwitz JJ, ed. *The Lacrimal System*. Philadelphia, Pa: Lippincott-Raven Publishers; 1996:261-296.
5. Jordan DR. Standard external dacryocystorhinostomy. In: Mauriello JA, ed. *Unfavorable Results of Eyelid and Lacrimal Surgery*. Boston, Mass: Butterworth-Heinemann; 2000:519-530.
6. Jordan DR, McDonald H. Failed dacryocystorhinostomy: the sump syndrome. *Ophthalmic Surg.* 1993;24:692-694.
7. Baldeschi L, Nolst Trenite GJ, Hintschich C, Koornneef L. The intranasal ostium after external dacryocystorhinostomy and the internal opening of the lacrimal canaliculi. *Orbit.* 2000;19:81-86.
8. Galloway JE, Kavic TA, Raflo GT. Digital subtraction macrodacryocystography: a new method of lacrimal system imaging. *Ophthalmology.* 1984;91:956-962.
9. Steinkogler FJ, Huber E, Karmel F, Kuchar A. Dynamic documentation of digital dacryocystography. *Ophthalmic Surg.* 1993;24:556-559.
10. Zilelioglu G, Ugurbas SH, Anadolu Y, Akiner M, Akturk T. Adjunctive use of mitomycin C on endoscopic lacrimal surgery. *Br J Ophthalmol.* 1998;82:63-66.
11. Kao SC, Liao CL, Tseng JH, Chen MS, Hou PK. Dacryocystorhinostomy with intraoperative mitomycin C. *Ophthalmology.* 1997;104:86-91.
12. Hurwitz JJ. The dacryocystorhinostomy operation: indications and considerations for selection of approach. *Oper Tech Oculoplast Orbital Reconstr Surg.* 1998;1:42-48.
13. Werb A. Surgery of the lacrimal sac and nasolacrimal duct. In: Milder B, Weil BA, eds. *The Lacrimal System*. Norwalk, Conn: Appleton-Century-Crofts; 1983: 153-163.
14. Wilkins RB, Berris CE, Dryden RM, Doxanas MT, McCord CD. Lacrimal drainage system disorders. In: McCord CD, Tanenbaum M, eds. *Oculoplastic Surgery*. New York, NY: Raven Press; 1987:377-405.
15. Rizk SNM, Dark AJ. Regeneration of the lacrimal sac. *Trans Ophthalmol Soc U K.* 1967;87:695-701.
16. McLean CJ, Cree IA, Rose GE. Rhinostomies: an open and shut case? *Br J Ophthalmol.* 1999;83:1300-1301.
17. Patrinely JR, Gigantelli JW. Dacryocystorhinostomy. In: Linberg JV, ed. *Lacrimal Surgery*. New York, NY: Churchill-Livingstone Inc; 1988:151-167.
18. Buerger DG, Schaefer AJ, Campbell CB III, Flanagan JC. Acquired lacrimal disorders. In: Nesi FA, Lisman RD, Levine MR, Brazzo BG, Gladstone GJ, eds. *Smith's Ophthalmic Plastic and Reconstructive Surgery*. St Louis, Mo: Mosby-Year Book Inc; 1998:661-669.
19. Levine MR. Dacryocystorhinostomy. In: Levine MR, ed. *Manual of Oculoplastic Surgery*. 2nd ed. Boston, Mass: Butterworth-Heinemann; 1996:37-45.