Ischemic and Nonischemic Cardiomyopathy: Delayed Enhancement Patterns on Cardiac MRI

Julianna M. Czum, MD

Director, Division of Cardiothoracic Imaging
Department of Radiology
Dartmouth-Hitchcock Medical Center

Assistant Professor of Radiology and Medicine, Section of Cardiology
Geisel School of Medicine at Dartmouth

Disclosures

Consultant for M2S, Inc.

Learning Objectives

1. To discuss the physical principles and physiologic basis of myocardial delayed enhancement on cardiac MRI
2. To describe the differences in patterns between ischemic and nonischemic cardiomyopathy on cardiac MRI

Not covered

- Myocardial perfusion imaging
- Stress imaging
- Myocardial stunning and hibernation
- Many types of nonischemic cardiomyopathy

Physiology of myocardial delayed enhancement

Normal myocardium

Rapid "wash-in" of extracellular Gd contrast

Rapid "wash-out" of extracellular Gd contrast

Abnormal myocardium

Delayed contrast "wash-in" from slow perfusion

Delayed contrast "wash-out", i.e. contrast retention in interstitium due to collagen matrix in fibrosis, amyloid glycoprotein deposition, etc.

Physical Principles of Delayed Enhancement with MRI

Contrast-enhanced T1-weighted GRE

180° inversion pulse

Differential recovery of longitudinal magnetization (T1) of normal myocardium and abnormal contrast-enhanced myocardium

Null point of normal myocardium, i.e. net magnetization = zero

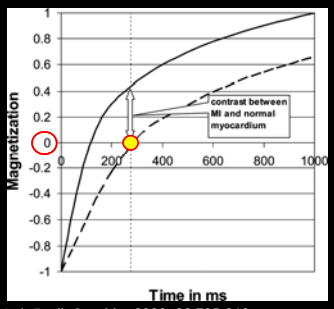

Vogel-Claussen et al. *RadioGraphics* 2006; 26:795-810

Inversion Time (TI)

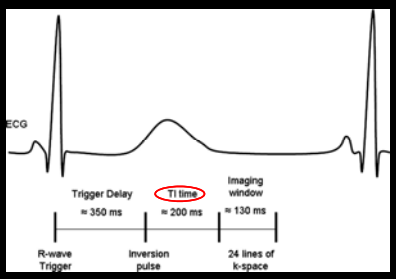

Vogel-Claussen et al. *RadioGraphics* 2006; 26:795-810

Inversion Time Selection

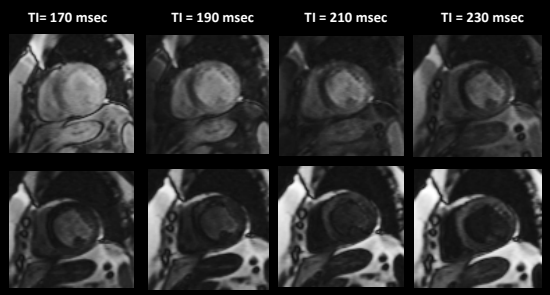

Delayed Enhancement: Localization

- Myocardial Segments
- Myocardial Layers
- Coronary Territories

Myocardial Layers

- Subendocardium
- Mesocardium
- Subepicardium
- Transmural: all layers

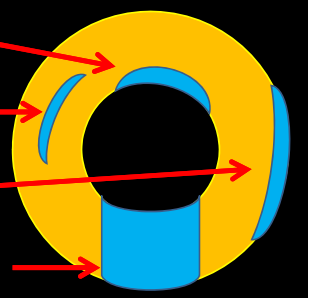

Myocardial Segmentation

Long axis: LV divided into thirds:
- Apical
- Mid
- Basal

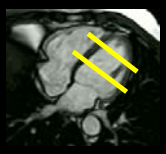

Short axis: 17 segments
- Apex: 1
- Radial division
  - Apical: 4
  - Mid: 6
  - Basal: 6

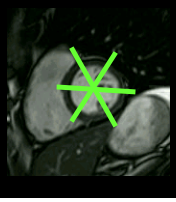

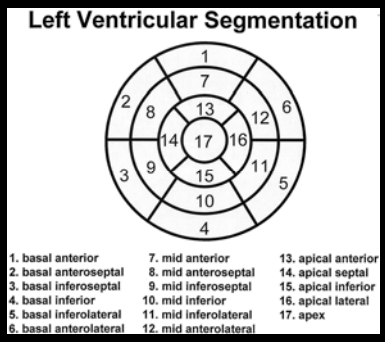

Cerqueria MD, et al. *Circulation* 2002;105:539-542

Ischemic vs Non-ischemic

Ischemic

- Focal subsendocardial or transmural delayed enhancement
- Conforms to coronary vascular territory

Non-ischemic

- Typically spares subendocardium
- Does not conform to coronary territory
- Can be focal, multifocal, or diffuse

Coronary Artery Territories

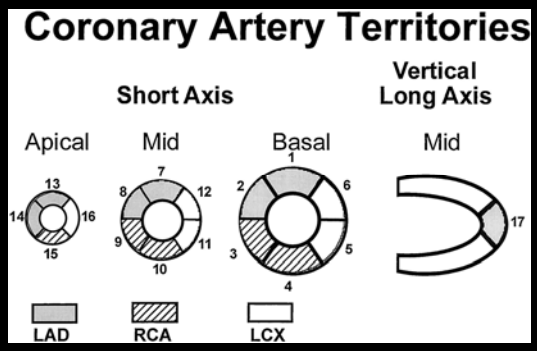

1,2,7,8,13,14,17 3,4,9,10,15 5,6,11,12,16

Cerqueria MD, et al. *Circulation* 2002;105:539-542

Ischemic Patterns

- Subendocardial
- Transmural
- Microvascular obstruction

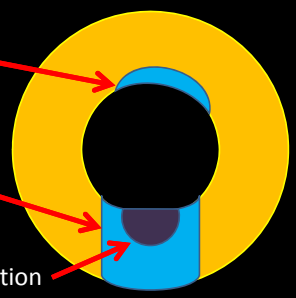

Examples

Subendocardial DE anterior wall: LAD territory

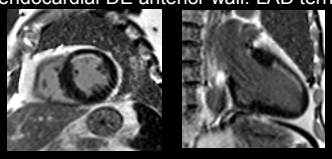

Transmural DE apex & anterior wall: LAD territory

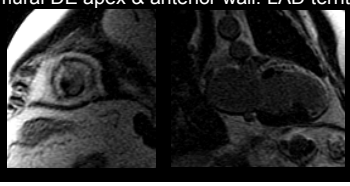

Microvascular Obstruction

Myocardial microcirculation (arterioles and capillaries)

- Obstructed: Plugged by microthrombi, neutrophils

Delayed enhancement imaging

- Infarct: Enhances slowly ("wash-in"); stays enhanced because of slow clearance ("wash-out") of extracellular contrast
- MVO
  - Remains unenhanced
  - No contrast "wash-in"; nothing for "wash-out"
  - Looks "null" like normal myocardium
  - Subendocardial core of a transmural (or near-transmural) infarction

Microvascular obstruction

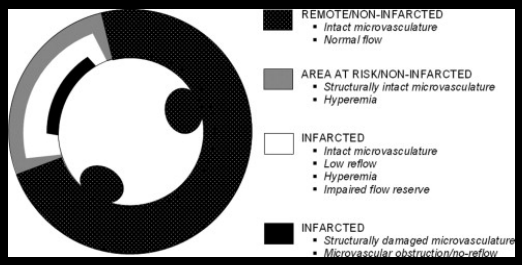

Sebastiaan CAM, et al. *JACC* 2010;55:1649-1655

MVO versus thrombus

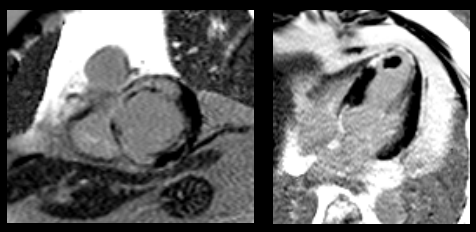

Delayed Enhancement Patterns

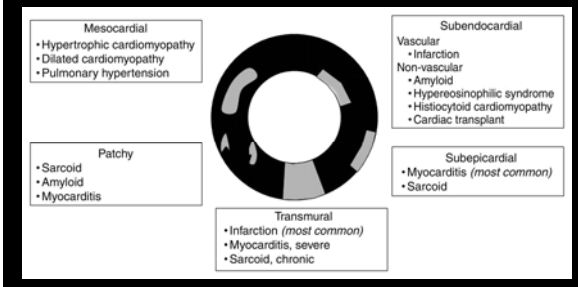

Cummings KW, et al. *RadioGraphics* 2009;29:89-103.

Nonischemic Cardiomyopathies: Selected Examples

- Myocarditis
- Amyloid
- Sarcoid
- Hypertrophic Cardiomyopathy
- Dilated Cardiomyopathy
- ARVD
- Noncompaction

Patterns

Layer:
Subendocardial, subepicardial, mesocardial

Morphology:
Linear, patchy, or nodular

Nonischemic:
>1 vascular territory when subendocardial or spare subendocardium

Myocarditis

- Mesocardium
- Subepicardium
- Patchy

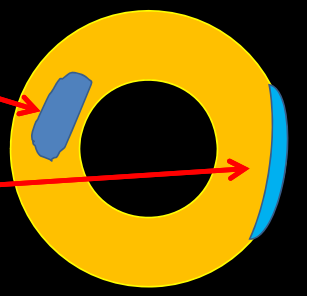

Myocarditis: 19 year old male with chest pressure and elevated troponin

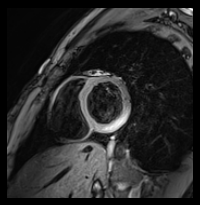

T2-weighted IR FSE
Basal inferolateral wall
High signal = edema

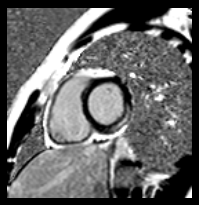

T1-weighted IR GRE
Basal inferolateral wall
High signal = DE

Amyloid

- Diffuse subendocardial or transmural

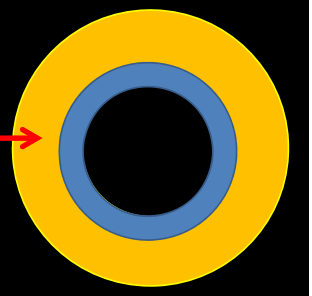

Amyloid

Inversion time selection ***BEFORE*** contrast

TI = 250 msec

11:18 AM

Inversion time selection ***AFTER*** contrast

TI = 250 msec

11:23 AM

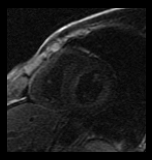

Delayed ***REPEAT*** inversion time selection

TI = 250 msec

11:37 AM

Amyloid

Delayed enhancement pattern:

- Global subendocardial or transmural
- Occasionally more patchy and scattered
- Guides endomyocardial biopsy

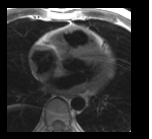

Differentiation of amyloid and "balanced" ischemic cardiomyopathy on DE:

- Hypertrophic rather than dilated and thinned myocardium
- Pan-chamber hypertrophy and delayed enhancement

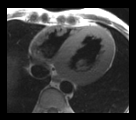

Sarcoid

- Patchy or nodular
- Subepicardial or mesocardial
- Negative if on steroids



Sarcoid

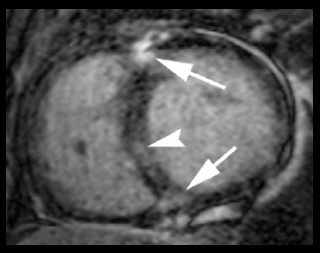

Ordovas KG and Higgins CB. *Radiology* 2011; 216:358-374.

Hypertrophic Cardiomyopathy

- Patchy or nodular
- Mesocardial (mid wall)
- Interventricular septum by RV insertion sites

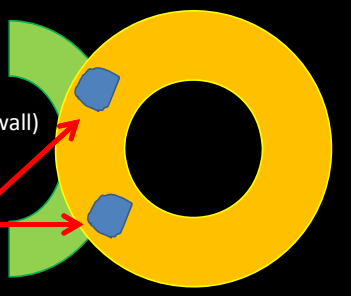

Hypertrophic Cardiomyopathy

Asymmetric septal hypertrophy

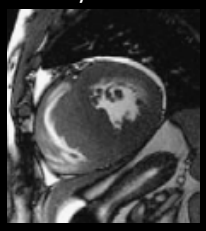

Still image from cine steady-state free precession

Delayed enhancement

White JA, Patel MR. *Magn Reson Imaging Clin No Am* 2007;541-564.

Dilated Cardiomyopathy

- Mesocardium

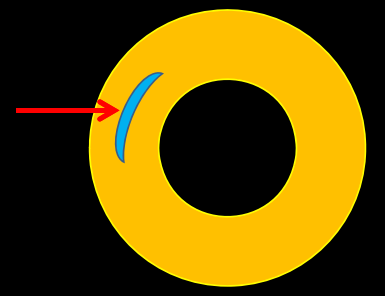

Dilated cardiomyopathy

Most common form of nonischemic cardiomyopathy

- 50%=idiopathic
- Other 50% = sequelae of myocarditis, drug toxicity, alcohol abuse

Delayed enhancement

- ± Mesocardial stripe in interventricular septum
- Marker for increased risk of sudden cardiac death: arrhythmogenic focus

Idiopathic Dilated CM

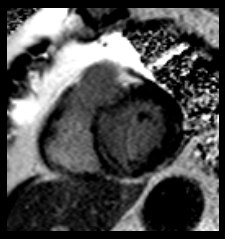

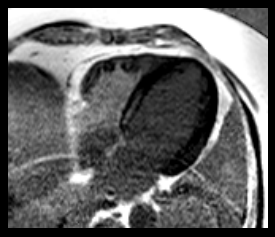

Arrhythmogenic Right Ventricular Cardiomyopathy

- Variable pattern RV free wall and interventricular septum

ARVD

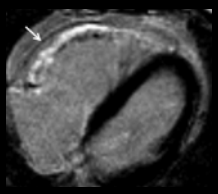

Binu P, et al. *Circ Arrhythm Electrophys* 2014;7:230-236

NOT major or minor 2010 Task Force criterion:

- Abnormal non-contrast myocardial signal suggestive of fibrofatty change
- Delayed enhancement

2010 ARVD Task Force criteria for MRI:

- RV dilatation and wall motion abnormalities **ONLY**

Abnormal myocardial signal on non-contrast MRI and/or DE: site(s) for potential myocardial biopsy

Noncompaction

- Variable foci in areas of noncompaction, i.e. hypertrabeculation

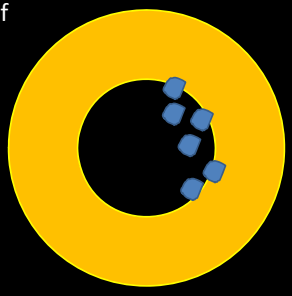

Noncompaction

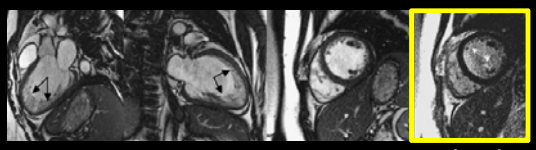

Apical-to-mid chamber LV hypertrabeculation and thinning of underlying compacted myocardium (static images from cine steady-state free precession)

Tiny foci of DE: trabeculations and papillary muscles

White JA, Patel MR. *Magn Reson Imaging Clin No Am* 2007;541-564

Delayed Enhancement Patterns

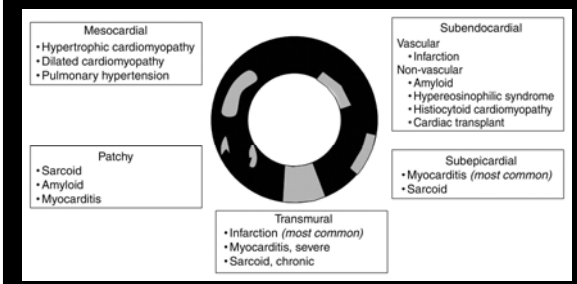

Cummings KW, et al. *RadioGraphics* 2009;29:89-103.

Algorithm for Delayed Enhancement in Patients with Cardiomyopathy

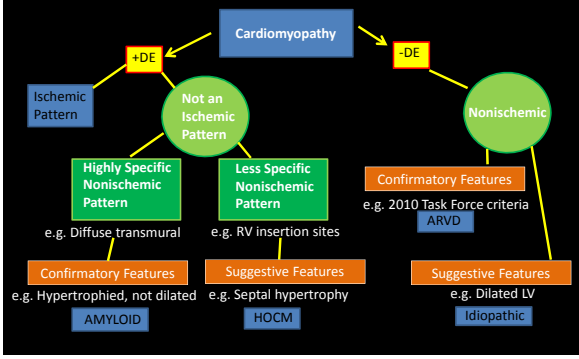

References

1. Weinsaft JW, Klem I, Judd RM. MRI for the assessment of myocardial viability. *Magn Reson Imaging Clin No Am* 2007;15:505-525.

2. White JA, Patel MR. The role of cardiovascular MRI in heart failure and the cardiomyopathies. *Magn Reson Imaging Clin No Am* 2007;541-564.