Journal of Orthopaedic Surgery 2010;18(1):98-103

Review article: *Mycobacterium marinum* infection of the hand and wrist

Jason Pui-yin Cheung,[1] Boris Fung,[1] Samson Sai-yin Wong,[2] Wing-yuk Ip,[1]
[1] Department of Orthopaedics and Traumatology, University of Hong Kong Medical Centre, Queen Mary Hospital, Hong Kong
[2] Department of Microbiology, The University of Hong Kong, Queen Mary Hospital, Hong Kong

ABSTRACT

Misdiagnosis and delayed treatment of *Mycobacterium marinum* infection is common because of its diverse manifestations. This leads to inappropriate use of antimicrobials, extension of the infection from the skin to the tenosynovium, and a poor prognosis (loss of tendons and prolonged immobilisation, secondary to multiple debridements and joint contractures). Clinicians should be aware of this type of infection, especially in subjects at risk (fishermen and aquarium enthusiasts), and those with a history of trauma coupled with exposure to water or marine life. A proactive approach to obtain a biopsy for histopathological and microbiological diagnosis is advised. Anti-mycobacterial treatment should be started promptly. The combined use of rifampicin, ethambutol, and clarithromycin appears to be effective, and debridement is indicated in patients with deep-seated infections.

Key words: *infection; Mycobacterium marinum; tenosynovitis*

INTRODUCTION

Mycobacterium marinum was first discovered in salt-water fish in 1926, but was not identified in humans until 1951.[1] Its manifestations vary from a single skin granuloma to sporotrichoid nodules and tenosynovitis of the hand, which are often misdiagnosed and treatment is commonly delayed. This mycobacterium is free-living and found worldwide in both freshwater and marine environments. Infection can be caused by direct injury from fish fins or fish bites or during the handling of fish tanks. Local trauma is an important factor predisposing to infection. We review the diagnosis and management of *M marinum* infection in the literature.

METHODS

Databases of Medline, PubMed, and the Cochrane library were searched using the key words '*Mycobacterium marinum*' and 'tenosynovitis'. Articles published in English involving *M marinum* infection of the hand and wrists were included. Epidemiology, microbiology, diagnostic difficulties,

Address correspondence and reprint requests to: Dr Jason Pui-yin Cheung, Department of Orthopaedics and Traumatology, University of Hong Kong Medical Centre, Queen Mary Hospital, Hong Kong. E-mail: jcheung98@hotmail.com

clinical presentations, culture findings, histology, treatment, and long-term outcomes (such as loss of hand function) were reviewed. References in review articles were screened for potentially relevant studies not yet identified.

EPIDEMIOLOGY

Among infections of the hand, *M marinum* accounts for 0.04 to 0.27 per 100 000 cases.[2] Most patients are aged 38 to 45 years[2–5] and are infected from water or other environmental sources through superficial abrasions. In a Singaporean study of 38 patients, 34% kept fish at home, 11% had fish-related occupations, and 32% had a history of trauma.[3] In a French study of 63 patients, 84% had exposure to fish tanks.[6] In a Hong Kong report on 24 patients, 67% were fishermen, and 67% had sustained a puncture wound prior to seawater contact.[4]

MICROBIOLOGY

M marinum is a natural pathogen of ectotherms such as frogs and fish. It has an extensive habitat and can live saprophytically in a warm aquatic environment.[7] It grows on Lowenstein-Jensen medium, forming moist, compact colonies that become evident after 2 to 3 weeks of culture. It is optimally cultured at a temperature of 25ºC to 35ºC, and therefore infection usually occurs in cooler parts of the body (such as extremities)[8]; 74% to 95% develop in the upper extremities, 36% to 59% being in the fingers.[3,6,9]

CLINICAL MANIFESTATIONS

There are no pathognomonic features of *M marinum* infection, and the presenting symptoms are diverse. Skin lesions may be single or multiple and initially may appear papulonodular. Common misdiagnoses include cellulitis or abscess, fungal and parasitic infection, tuberculosis verrucosa cutis, gout, rheumatoid arthritis, trigger finger, foreign body reaction, and skin tumour.[1,2]

20% to 33% of patients present with a sporotrichoid pattern—the spread of nodular or ulcerating skin lesions proximally along the line of lymphatic drainage to the regional lymph nodes.[2,9] This manifestation tends to persist and does not heal spontaneously.

M marinum infection is categorised into 3 types. Type I forms self-limiting verrucal lesions, type II forms single or multiple subcutaneous granulomas with or without ulceration, and type III results in deep infections involving the tenosynovium, bursa, bones or joints causing tenosynovitis, septic arthritis or osteomyelitis.[1] Deep infections of the latter type usually results from extension of cutaneous infections or direct inoculation, rather than through haematogenous spread.[10]

In a Singaporean study, 66% of patients presented with plaques, 26% with nodules, 5% with papules, and 3% with an ulcer.[3] In a French study, 67% of patients presented with nodules, of which 39% had a sporotrichoid pattern.[6] In an American study of 15 patients, 29% presented with one or more subcutaneous masses, and 57% had tenosynovitis.[5]

The presenting symptoms vary and include painful swelling associated with stiffness and numbness,[5] local pain,[9] swelling and limitation of motion and discharging sinuses.[4] In rare instances, patients present with a disseminated disease such as multiple cutaneous lesions on both sides of the upper and/or lower limbs, and even in the lungs and abdominal organs. Disseminated infections usually occur in immunocompromised patients including those taking steroids.[11,12]

Delay in presentation and delay in making a definitive diagnosis is common. In one series the mean delay from injury to presentation was 32 days.[2] In another, the median time from inoculation to appearance of a lesions was 16 (range, 0–292) days.[6] Owing to the indolent nature of early lesions, patients often do not seek medical attention until symptoms become more florid. Others reported the mean delay from the onset of symptoms to consultation to be 7.7 (range, 1–36) months,[5] and the mean delay from the onset of symptoms to a definitive diagnosis was 3.5 months, the longest delay being 8 months.[4] Furthermore, the initial diagnosis was usually erroneous.

DIAGNOSIS

Initial clinical and radiological findings are often non-specific. Plain radiography may show soft-tissue swelling only[5] and does not differentiate the disease from other granulomatous or mycobacterial infections. Magnetic resonance imaging may show exuberant tenosynovitis, fluid collection around tendons, and bone erosions, which are all features of type-III infection.[13]

A definitive diagnosis is based on a positive culture of *M marinum*. The mean time taken to detect its growth in culture was 25 days and the mean

time to bacterial identification and availability of antimicrobial susceptibility was another 26 days.[9] Therefore, the mean time from biopsy to positive bacterial profile and antimicrobial susceptibility results was 2.3 months.[9] Thus, treatment is always delayed, and the mean time to surgery has been reported as 63 (range, 33–122) days.[2] Depending on the series, only 3%[3] to 55%[14] of *M marinum* infections yield positive cultures.

Diffuse and focal granulomatous inflammation affects the tendon sheath, fibroadipose tissue and skeletal muscle.[4,15] The normal intimal lining of synovial cells and sub-intimal supportive fibrofatty tissues are replaced and thickened by masses of inflammatory infiltrate combined with granulation tissue. There is extensive ulceration with destruction of the synovial structure (Fig. 1). The residual synovial lining cells appear hypertrophic but show minimal hyperplasia. Biopsied tissues show scattered small, well-formed, epithelioid, non-caseating granulomata with Langhans giant cells.[16,17] Poorly formed granulomatous reactions with caseating necrosis are also seen.[16,17] Long, slender and beaded acid-fast bacilli are seen in fibrinous exudates or among caseous material (Fig. 2). In deeper tissue sections, focal necrotising granulomas and diffuse granulomatous inflammation can be seen extending between the fibres of adjacent skeletal muscles.[18,19] Osteomyelitis may be seen with granulomatous inflammation, and the dead bone or sequestrum is surrounded by granulation tissue and chronic inflammatory cells. There is no evidence of new bone formation.[16]

Figure 1 Extensive tenosynovitis and synovectomy

Only 46% of patients present with typical pathological findings.[6] Granulomata are present in 38% of patients, and acid-fast bacilli have been identified (using Ziehl-Neelsen stains) in 17%[9] and 13%[3] of patients. The mean duration of skin lesions is longer in those with granulomata than in those without (7.9 vs. 4.7 months).[9]

The diagnosis of *M marinum* is often delayed, primarily owing to the lack of clinical suspicion and failure to elicit a history of aquatic exposure. Clinicians should review the patient's occupational and recreational activities, including any history of penetrating injury or regular exposure to seawater or fresh water. Many patients are inoculated through superficial abrasions, which may lead to deep-seated infections rather than granulomata. Common misdiagnoses include sporotrichosis, mycobacterial infections, gout, rheumatoid arthritis, foreign body reactions, and even tumours (such as epithelioid sarcomas).

ANTIMICROBIAL TREATMENT

Antimicrobial agents and duration of treatment vary

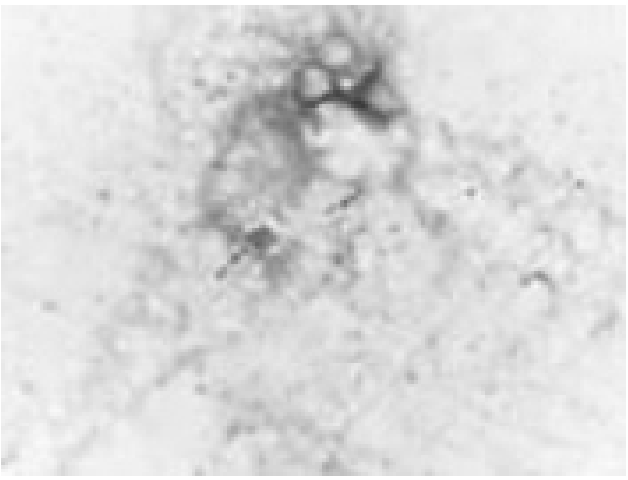

Figure 2 *Mycobacterium marinum* under Ziehl-Neelsen stain (x1000)

Table 1
Antibiotic regimens

Study	Year	Region	No. of cases	Recommended antibiotic regimen	Duration (months)	Outcome
Donta et al.[20]	1986	USA	2	Tetracycline & cotrimoxazole or rifampicin & ethambutol	3–6	All responded
Hurst et al.[5]	1987	USA	15	Tetracycline or minocycline	2–6	87% healed
Chow et al.[4]	1987	Hong Kong	24	Rifampicin & ethambutol	9	58% responded
Ljungberg et al.[21]	1987	Sweden	2	Tetracycline or ethambutol or cotrimoxazole	9	All resolved
Laing et al.[22]	1997	UK	3	Clarithromycin & ciprofloxacin	5	All responded
Ang et al.[3]	2000	Singapore	38	Minocycline or doxycycline or cotrimoxazole or rifampicin & ethambutol	3–6	69% improved
Aubry et al.[6]	2002	France	63	Clarithromycin or minocycline or doxycycline or rifampicin & ethambutol	3.5	87% cured
Ho et al.[14]	2006	Hong Kong	17	Tetracycline &/or minocycline	4.9	94% treated
Pang et al.[2]	2007	Singapore	5	Cotrimoxazole or doxycycline or xlarithromycin	3.9	80% treated
Dodiuk-Gad et al.[9]	2007	Israel	25	Clarithromycin	3	All healed

considerably (Table 1).[2–6,9,14,20–22] The optimal regimen has not been established and the choice of regimen is mainly based on the treating surgeon's preference. All drug regimens have resulted in failure and success. *M marinum* is almost always resistant to isoniazid and frequently also to streptomycin. It is susceptible *in vitro* to: rifampicin, ethambutol, clarithromycin, cotrimoxazole, some tetracyclines (doxycycline and minocycline) and certain newer quinolones (such as ciprofloxacin, levofloxacin, and moxifloxacin). For superficial infections of the skin, monotherapy with cotrimoxazole or tetracycline is sufficient. For deep-seated infections, combination therapy with or without surgical debridement is recommended.

In a French study, the median duration of antibiotic therapy was 3.5 (range, 1–25) months.[6] The regimen was significantly longer for deep infections than skin and soft-tissue infections (median, 7.5 vs 4 months, p=0.004).[6] At least 3 months of treatment is recommended, and sometimes up to 6 months, and at least 2 more months after the lesions have subsided (Table 2). 37% of patients underwent monotherapy (with minocycline, doxycycline, or clarithromycin), whereas 63% received a combination of at least 2 drugs (clarithromycin and rifampicin, minocycline or doxycycline and clarithromycin, rifampicin and ethambutol, and minocycline or doxycycline and rifampicin).[6] In all, 87% of the patients were cured.[6] Failure was related to the spread of infection to deeper structures and the skin lesion aspect of the ulcer, and not to the prescription of any specific antibiotic regimen or the duration of treatment.[6]

As rifampicin has excellent bone-penetrating ability, the American Thoracic Society and Infectious Disease Society of America recommend clarithromycin and ethambutol for most patients, with addition of rifampicin in patients with osteomyelitis or other deep infections.[23]

In our hospital, most patients were treated with rifampicin and ethambutol. In patients with no history of exposure or tuberculous involvement, empirical anti-tuberculous treatment with isoniazid, pyrazinamide, rifampicin, and ethambutol was used. This regimen confers adequate cover against both tuberculosis and *M marinum* infection. Clarithromycin and/or levofloxacin may be added in some patients when other atypical mycobacterial infections are suspected, when the patient is intolerant or allergic to other first-line drugs, or when there is extensive disease.

SURGICAL TREATMENT

Excision or debridement is necessary in patients with type-III infections refractory to antibiotics.[6] The

Table 2
Recommended treatment protocol

Condition	Treatment protocol
Standard regimen for previously untreated patient	Ethambutol and rifampicin or minocycline and rifampicin
Relapse after treatment	Clarithromycin and minocycline and ethambutol
Duration of treatment	6 months total or at least 2 more months after definite clinical improvement

excised tenosynovium is similar to giant cell tumours of the tendon sheath but less encapsulated and more adherent to surrounding structures.[5] Grossly the synovium appears thickened and varies from being oedematous to firm. Fibrin covers some of the synovial surfaces and the colour varies from light grey to beefy red to brown.[18] The mean number of debridements to achieve clearance was 3.4 (range, 2–4).[2]

REHABILITATION

Debridement and synovectomy may lead to extensive scarring, joint contracture, and loss of function. In 5 patients undergoing extensive synovectomy, the mean postoperative total active motion of the finger was only 94º (range, 55º–190º).[2] Although early mobilisation could improve hand function, it violates the principle of resting infected parts and might lead to a flare-up, wound dehiscence, and persistent sinus formation. As a compromise, immobilisation of the hand has been suggested for 7 to 10 days, by which time the wound is more stable for vigorous exercise,[15] and 88% of the patients achieved a range of motion similar to that of the unaffected hand.[4] The remaining patients underwent excision of the flexor tendons to control the infection or developed multiple joint contractures after 3 debridements.[4] In 83% of the patients, hand grip power was ≥90% of that of the normal hand.[4] None of the patients had problems with performing activities of daily living or pursuing their original occupation.[4] We recommend immobilisation of the hand for 10 to 14 days before carrying out mobilisation exercises.

PROGNOSIS

Risk factors for a poor prognosis after *M marinum* infection include an underlying immunocompromised condition secondary to disease or immunosuppressive agents. The use of systemic steroids may interfere with normal monocyte-macrophage functions.[12] An antibiotic regimen of 9 to 12 months may be needed.[12]

The infection is exacerbated when it is misdiagnosed as gout, rheumatoid arthritis or lupus and treated with steroid injections.[11] 54% of patients with *M marinum* infection received local injections of steroids before admission.[4] In 85% of such patients, there was delayed wound healing or poor response to medications and recourse to subsequent surgical debridement.[4] Persistent pain and discharging sinuses are also poor prognostic factors.[4] 90% of patients who underwent surgical debridement experienced persistent pain, whereas only 7% did so when treated conservatively.[4] Likewise, 50% of patients having surgical debridement had a discharging sinus in contrast to 14% who were treated conservatively.[4] These findings suggest that injection of steroids, persistent pain, and discharging sinuses are associated with a poor prognosis.

The main prognostic indicator in *M marinum* infections is the promptness of treatment. Delayed or inappropriate treatment can lead to the loss of hand function. For instance, intra-lesional injections of corticosteroids exacerbate the infection. Thus, clinical awareness for this infection must be stressed, especially in patients with occupational risks and seawater exposure.

REFERENCES

1. Bhatty MA, Turner DP, Chamberlain ST. *Mycobacterium marinum* hand infection: case reports and review of literature. Br J Plast Surg 2000;53:161–5.
2. Pang HN, Lee JY, Puhaindran ME, Tan SH, Tan AB, Yong FC. *Mycobacterium marinum* as a cause of chronic granulomatous tenosynovitis in the hand. J Infect 2007;54:584–8.
3. Ang P, Rattana-Apiromyakij N, Goh CL. Retrospective study of *Mycobacterium marinum* skin infections. Int J Dermatol 2000;39:343–7.
4. Chow SP, Ip FK, Lau JH, Collins RJ, Luk KD, So YC, et al. *Mycobacterium marinum* infection of the hand and wrist. Results of conservative treatment in twenty-four cases. J Bone Joint Surg Am 1987;69:1161–8.
5. Hurst LC, Amadio PC, Badalamente MA, Ellstein JL, Dattwyler RJ. *Mycobacterium marinum* infections of the hand. J Hand Surg Am 1987;12:428–35.
6. Aubry A, Chosidow O, Caumes E, Robert J, Cambau E. Sixty-three cases of *Mycobacterium marinum* infection: clinical features, treatment, and antibiotic susceptibility of causative isolates. Arch Intern Med 2002;162:1746–52.
7. Brown J, Kelm M, Bryan LE. Infection of the skin by *Mycobacterium marinum*: report of five cases. Can Med Assoc J 1977;117:912–4.
8. Stamm LM, Brown EJ. *Mycobacterium marinum*: the generalization and specialization of a pathogenic mycobacterium. Microbes Infect 2004;6:1418–28.
9. Dodiuk-Gad R, Dyachenko P, Ziv M, Shani-Adir A, Oren Y, Mendelovici S, et al. Nontuberculous mycobacterial infections of the skin: a retrospective study of 25 cases. J Am Acad Dermatol 2007;57:413–20.

10. Gluckman SJ. *Mycobacterium marinum*. Clin Dermatol 1995;13:273–6.
11. Enzenauer RJ, McKoy J, Vincent D, Gates R. Disseminated cutaneous and synovial *Mycobacterium marinum* infection in a patient with systemic lupus erythematosus. South Med J 1990;83:471–4.
12. Ho PL, Ho P, Fung BK, Ip WY, Wong SS. A case of disseminated *Mycobacterium marinum* infection following systemic steroid therapy. Scand J Infect Dis 2001;33:232–3.
13. Amrami KK, Sundaram M, Shin AY, Bishop AT. *Mycobacterium marinum* infections of the distal upper extremities: clinical course and imaging findings in two cases with delayed diagnosis. Skeletal Radiol 2003;32:546–9.
14. Ho MH, Ho CK, Chong LY. Atypical mycobacterial cutaneous infections in Hong Kong: 10-year retrospective study. Hong Kong Med J 2006;12:21–6.
15. Chow SP, Stroebel AB, Lau JH, Collins RJ. *Mycobacterium marinum* infection of the hand involving deep structures. J Hand Surg Am 1983;8:568–73.
16. Clark RB, Spector H, Friedman DM, Oldrati KJ, Young CL, Nelson SC. Osteomyelitis and synovitis produced by *Mycobacterium marinum* in a fisherman. J Clin Microbiol 1990;28:2570–2.
17. Travis WD, Travis LB, Roberts GD, Su DW, Weiland LW. The histopathologic spectrum in *Mycobacterium marinum* infection. Arch Pathol Lab Med 1985;109:1109–13.
18. Beckman EN, Pankey GA, McFarland GB. The histopathology of *Mycobacterium marinum* synovitis. Am J Clin Pathol 1985;83:457–62.
19. Collins RJ, Chow SP, Ip FK, Leung YK. Synovial involvement by *Mycobacterium marinum*. A histopathological study of 25 culture-proven cases. Pathology 1988;20:340–5.
20. Donta ST, Smith PW, Levitz RE, Quintiliani R. Therapy of *Mycobacterium marinum* infections. Use of tetracyclines vs rifampin. Arch Intern Med 1986;146:902–4.
21. Ljungberg B, Christensson B, Grubb R. Failure of doxycycline treatment in aquarium-associated *Mycobacterium marinum* infections. Scand J Infect Dis 1987;19:539–43.
22. Laing RB, Flegg PJ, Watt B, Leen CL. Antimicrobial treatment of fish tank granuloma. J Hand Surg Br 1997;22:135–7.
23. Griffith DE, Aksamit T, Brown-Elliott BA, Catanzaro A, Daley C, Gordin F, et al. An official ATS/IDSA statement: diagnosis, treatment, and prevention of nontuberculous mycobacterial diseases. Am J Respir Crit Care Med 2007;175:367–416.