



## CASE REPORT

# Disseminated Tuberculosis in a Psoriasis Patient under Adalimumab Treatment despite the Chemoprophylaxis of Latent Tuberculosis: A Case Report

Jae Hong Oh, Seung Pil Ham, Hai-Jin Park

Department of Dermatology, Ilsan Paik Hospital, College of Medicine, Inje University, Goyang, Korea

Recently, biologic therapy has become a major advance in the management of moderate-to-severe psoriasis. Although the overall safety profile of biologics is favorable, primary infection or reactivation of latent tuberculosis (TB) is the major concern in the setting of tumor necrosis factor-alpha inhibitor therapy. Therefore, the treatment of latent tuberculosis infection (LTBI) before starting biologics is mandatory to prevent the reactivation of LTBI. A 27-year-old female was treated with adalimumab due to psoriasis. As latent TB was detected by the interferon- $\gamma$  release assay, we started isoniazid treatment (300 mg/day) 3 weeks before starting adalimumab and maintained this for 6 months. Although the patient's psoriatic skin lesions improved, after 45 weeks of adalimumab therapy, she visited the emergency department because of fever and back pain for 2 weeks. Abdominopelvic computed tomography (CT) and chest CT revealed multiple nodular lesions on both lungs, peritoneal wall, mesentery, and spleen, along with ascites. In the ascitic fluid, adenosine deaminase was increased to 96.4 U/L, and *Mycobacterium tuberculosis* grew in an acid-fast bacilli culture. The patient was diagnosed with disseminated TB and treated with conventional TB medication with discontinuation of adalimumab.

Five months after the completion of TB treatment, the ustekinumab, an interleukin (IL)-12/IL-23 inhibitor, was administered. Until now, her skin lesions are under excellent control without reactivation of TB for 9 months after starting ustekinumab. (**Ann Dermatol 33(1) 77~81, 2021**)

## -Keywords-

Adalimumab, Biological products, Psoriasis, Tuberculosis, Tumor necrosis factor-alpha

## INTRODUCTION

Recently, biologic therapy has become a major advance in the management of moderate-to-severe psoriasis. Although the overall safety profile of biologics is favorable, primary infection or reactivation of latent tuberculosis infection (LTBI) is the major concern in the setting of tumor necrosis factor-alpha (TNF- $\alpha$ ) inhibitor therapy. Therefore, screening and treatment of LTBI before starting biologic agents are mandatory<sup>1</sup>.

TNF- $\alpha$  is a proinflammatory cytokine that plays an important role in psoriasis development<sup>2</sup>. Adalimumab is a recombinant human immunoglobulin G1 monoclonal antibody against TNF- $\alpha$  which is used for the psoriasis patients who are unresponsive to conventional treatment<sup>3</sup>. Herein, we report a case of disseminated tuberculosis (TB) in a patient with psoriasis treated with adalimumab despite receiving adequate chemoprophylaxis for LTBI and discussed the management of patients with LTBI requiring biologic therapy briefly.

Received August 8, 2019, Revised November 18, 2019, Accepted for publication December 11, 2019

**Corresponding author:** Hai-Jin Park, Department of Dermatology, Ilsan Paik Hospital, College of Medicine, Inje University, 170 Juhwa-ro, Ilsanseo-gu, Goyang 10380, Korea. Tel: 82-31-910-7224, Fax: 82-31-910-7227, E-mail: parkgreen24@gmail.com  
ORCID: <https://orcid.org/0000-0002-9274-9371>

This is an Open Access article distributed under the terms of the Creative Commons Attribution Non-Commercial License (<http://creativecommons.org/licenses/by-nc/4.0>) which permits unrestricted non-commercial use, distribution, and reproduction in any medium, provided the original work is properly cited.

Copyright © The Korean Dermatological Association and The Korean Society for Investigative Dermatology

## CASE REPORT

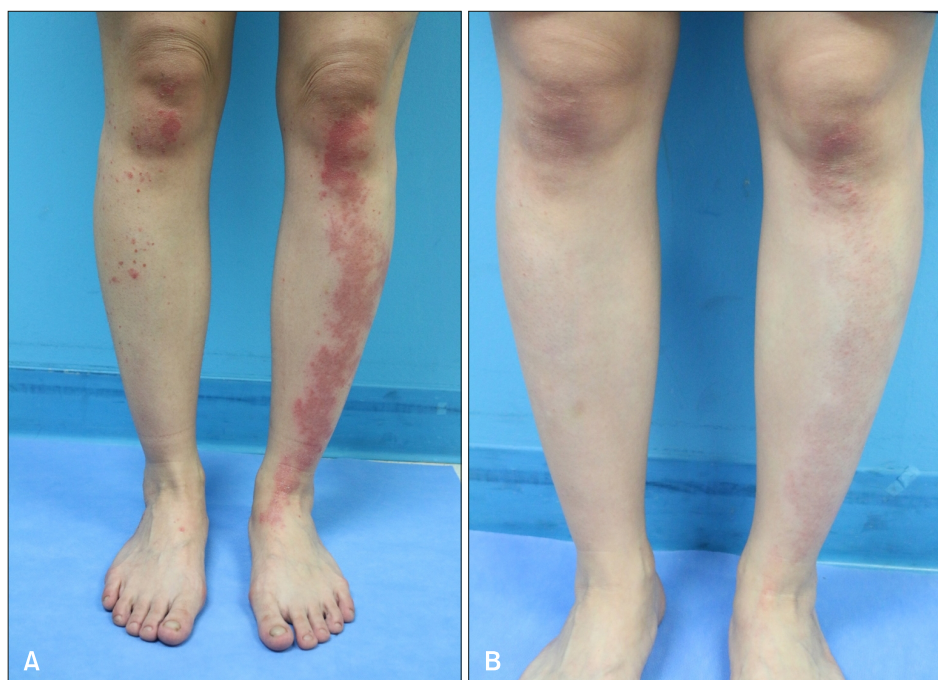
A 27-year-old female who had been diagnosed with psoriasis 8 years ago visited the dermatology department due to aggravation of psoriasis. On physical examination, scattered erythematous scaly papules and plaques were seen on the patient's entire body, especially on her lower legs. Although she was treated with narrowband ultraviolet B, cyclosporine, and methotrexate for 9 months, her symptoms gradually worsened (Psoriasis Area Severity Index [PASI] 10.5), and we considered biologic therapy (Fig. 1A).

Before starting biologics, laboratory tests were performed, including complete blood count, liver and kidney function test, hepatitis markers, venereal disease research laboratory and screening tests for TB. The patient had a history of Bacillus Calmette-Guérin (BCG) vaccination. Laboratory test results were all within normal limits. A chest radiograph was normal, but the tuberculin skin test (TST) and interferon- $\gamma$  release assay (IGRA) were both positive, with findings of 16 mm (normal, <10 mm in BCG-vaccinated person) and 7.78 IU/ml (normal, <0.35 IU/ml), respectively, which indicated LTBI. In accordance with the Centers for Disease Control and Prevention guidelines, we started isoniazid treatment (300 mg/day) 3 weeks before starting the biologics and maintained it for 6 months. After 16 weeks of adalimumab therapy, the skin lesions improved (PASI 0.8) (Fig. 1B).

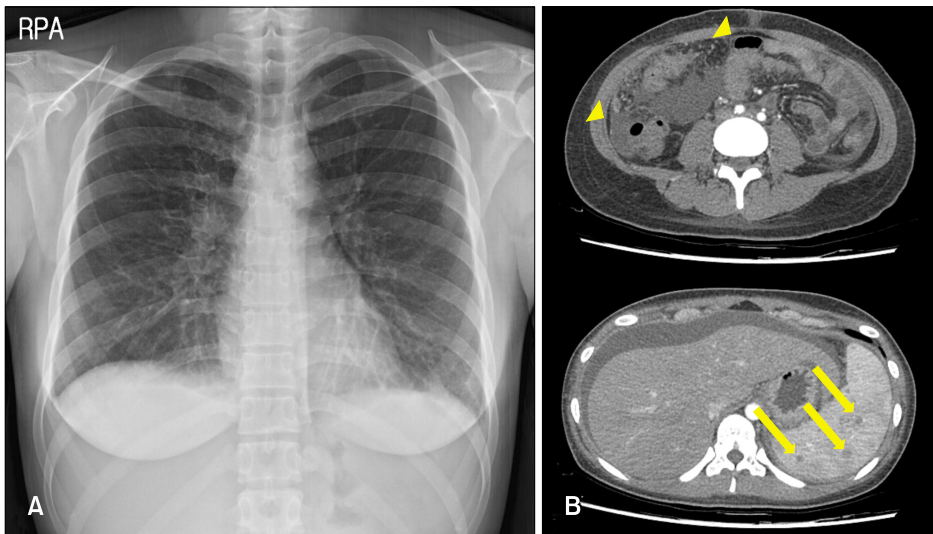
After 45 weeks of adalimumab therapy, the patient visited the emergency department with a complaint of 2 weeks of

fever with back and abdominal pain. Her body temperature was 39°C, and a positive sign for costovertebral angle tenderness was observed. On laboratory examination, white blood cell (WBC), C-reactive protein (CRP), and erythrocyte sedimentation rate (ESR) were 4,450/ $\mu$ l (normal, 4,000~10,000/ $\mu$ l), 2.9 mg/dl (normal, <0.5 mg/dl), and 39 mm/hour (normal, <25 mm/hour). A chest radiograph showed a slightly enhancing lesion on the apex of the right lung (Fig. 2A). Chest computed tomography (CT) revealed multiple nodules in both lungs with enlarged lymph nodes. Abdominopelvic CT showed nodular thickening of the peritoneum and many hypoattenuated lesions on the spleen with abundant ascites (Fig. 2B). On ascitic fluid examination, WBC and adenosine deaminase were 1,920/ $\mu$ l (normal, <500/ $\mu$ l) with 73% lymphocytes and 96.3 U/L (normal, <40 U/L), respectively. Acid-fast bacilli cultures of sputum and ascitic fluid revealed *Mycobacterium tuberculosis*. Finally, the patient was diagnosed with disseminated TB with pulmonary, peritoneal and spleen involvement. She didn't have a history of contact with a patient infected with TB during treatment.

Adalimumab treatment was discontinued immediately, and the patient was started on empirical treatment for TB with a combination of isoniazid (300 mg/day), rifampicin (600 mg/day), ethambutol (1,100 mg/day), and pyrazinamide (1,600 mg/day) for the first 2 months. Then, the treatment was followed by a continuation phase of isoniazid (300 mg/day), rifampicin (600 mg/day), and ethambutol (1,200 mg/day) for another 4 months.



**Fig. 1.** Clinical findings of the patient. (A) Erythematous scaly papules and plaques on the lower legs before adalimumab treatment. (B) After 4 months of adalimumab treatment, her skin lesions improved (We received the patient's consent form about publishing all photographic materials).



**Fig. 2.** Radiographic images of the patient. (A) Chest radiograph shows a slightly enhancing lesion on the apex of the right lung, with a mild bilateral pleural effusion. (B) Abdominopelvic computed tomography shows nodular thickening of the peritoneum (arrowheads) and many hypoattenuated lesions on the spleen (arrows), with abundant ascites.

After 6 months of TB medication along with excimer laser and topical agents, the patient's psoriatic patches spread gradually (PASI 12.7). The patient longed for receiving the biologics again and therefore ustekinumab, an interleukin (IL)-12/IL-23 inhibitor, was administered 5 months after the completion of TB treatment along with a normal chest radiograph. Until now, the patient is being monitored carefully, and her skin lesions are under excellent control without reactivation of TB for 9 months after starting ustekinumab.

## DISCUSSION

LTBI is the state in which human is infected with *M. tuberculosis* without clinical symptoms and radiographic signs, or microbiological evidence of active TB<sup>4</sup>. The risk of TB infection among the recipients of TNF- $\alpha$  blockers is 1.5~17 times higher than that in the general population<sup>1,2</sup>. TNF- $\alpha$  inhibitors are approved for many immune-mediated inflammatory diseases. Although the overall safety profile is favorable, some side effects have been identified<sup>3,5</sup>.

TNF- $\alpha$  is a proinflammatory cytokine that plays an important role in forming and maintaining granuloma to protect against mycobacterium. TNF- $\alpha$  inhibitor-associated TB has an unusual presentation with more severe and extrapulmonary patterns, which could result in a delayed diagnosis and disseminated TB<sup>6</sup>. Similar to our case, there have been two other cases of TB development in a psoriasis patient during adalimumab therapy despite chemoprophylaxis, and all of these patients had extrapulmonary symptoms<sup>7</sup>.

For screening of TB infection before initiation of biologics, thorough history taking, physical examination and a chest

radiograph should be necessary<sup>6</sup>. If clinical symptoms or findings on radiographs are suggestive of TB, an evaluation for active TB should be performed. If the results are normal, the appropriate method of the TST/IGRA combination test or the IGRA single test can be selected<sup>7,8</sup>.

The patient with LTBI should receive chemoprophylaxis with isoniazid for 6 to 9 months, rifampin for 3 to 4 months, or both drugs combined for 3 months. Although the 9-month treatment of isoniazid may be more effective, the 6-month regimen is preferred due to cost-effectiveness with better patient compliance. In addition, no significant differences in 6-month versus 12-month treatment regimens in reducing active TB risk have been shown<sup>9,10</sup>. However, in this case, the patient developed disseminated TB despite the 6-month of INH chemoprophylaxis of LTBI.

If TB is diagnosed during the use of biologics therapy, it must be discontinued immediately, and conventional TB therapy should be started<sup>7</sup>. It is safe to restart the biologic therapy after the completion of successful conventional treatment. However, if the treatment is urgent, after 2 months of intensive TB treatment, biologics can be started again along with TB treatment, only if the TB is not severe and responds well to general treatment<sup>7</sup>. Restarting anti-TNF therapy after treating patients successfully for a recurrence of TB seems to be safe although the study is limited. Abitbol et al.<sup>11</sup> reported that no recurrence of TB during a median time of ~3 years of follow-up after reintroduction of biologics in inflammatory bowel disease patients. Additionally, the rate of TB reactivation in patients receiving anti-TNF agents has been reported to be 1.5~17 fold higher for TNF- $\alpha$  inhibitors, while a low or absent risk is associated with non-anti-TNF targeted biologics<sup>2,12-14</sup>. Therefore, if a patient is diagnosed with LTBI on screening, oth-

er biologics rather than TNF- $\alpha$  inhibitors might be the better choice, even though receiving chemoprophylaxis. Therefore we administered ustekinumab (IL-12/23 inhibitor) 5 months after the completion of TB treatment and her skin lesions are under excellent control without reactivation of TB for 9 months.

In conclusion, TNF- $\alpha$  inhibitor therapy increases the TB risk, such TB symptoms are much more severe, and extrapulmonary types are more common than in general cases. Therefore, it is preferable to do a prompt examination for suspected TB symptoms, rather than regular chest radiograph<sup>15,16</sup>. Also, the possibility of reactivation of LTBI and reinfection of TB remains despite the appropriate chemoprophylaxis, especially in an endemic area. Thus, during treatment with TNF- $\alpha$  inhibitors, dermatologists should always remain alert for symptoms of TB with continual monitoring including a chest radiograph and contact history with an infectious TB patient at yearly intervals<sup>1,17-20</sup>, even if the chemoprophylaxis for LTBI was completed.

## CONFLICTS OF INTEREST

The corresponding author performed phase IV clinical trial sponsored by Janssen and AbbVie and is performing phase III clinical trial sponsored by Lilly.

## FUNDING SOURCE

None.

## DATA SHARING STATEMENT

Research data are not shared.

## ORCID

Jae Hong Oh, <https://orcid.org/0000-0003-3394-860X>  
 Seung Pil Ham, <https://orcid.org/0000-0002-4472-2043>  
 Hai-jin Park, <https://orcid.org/0000-0002-9274-9371>

## REFERENCES

- Carmona L, Gómez-Reino JJ, Rodríguez-Valverde V, Montero D, Pascual-Gómez E, Mola EM, et al. Effectiveness of recommendations to prevent reactivation of latent tuberculosis infection in patients treated with tumor necrosis factor antagonists. *Arthritis Rheum* 2005;52:1766-1772.
- Xie X, Li F, Chen JW, Wang J. Risk of tuberculosis infection in anti-TNF- $\alpha$  biological therapy: from bench to bedside. *J Microbiol Immunol Infect* 2014;47:268-274.
- Yoo WH. Multiple organ tuberculosis of lung, pleura, and peritoneum in ankylosing spondylitis during adalimumab therapy. *Rheumatol Int* 2012;32:787-790.
- Frieden TR, Sterling TR, Munsiff SS, Watt CJ, Dye C. Tuberculosis. *Lancet* 2003;362:887-899.
- Toussirot E, Streit G, Wendling D. Infectious complications with anti-TNF $\alpha$  therapy in rheumatic diseases: a review. *Recent Pat Inflamm Allergy Drug Discov* 2007;1:39-47.
- Lynch M, Roche L, Horgan M, Ahmad K, Hackett C, Ramsay B. Peritoneal tuberculosis in the setting of ustekinumab treatment for psoriasis. *JAAD Case Rep* 2017;3:230-232.
- Guinard E, Bulai Livideanu C, Barthélémy H, Viguier M, Reguiat Z, Richard MA, et al. Active tuberculosis in psoriasis patients treated with TNF antagonists: a French nationwide retrospective study. *J Eur Acad Dermatol Venereol* 2016;30:1336-1341.
- Amerio P, Amoroso G, Bardazzi F, Campanati A, Cassano N, Conti A, et al. Detection and management of latent tuberculosis infections before biologic therapy for psoriasis. *J Dermatolog Treat* 2013;24:305-311.
- Kim HW, Kim JS. Treatment of latent tuberculosis infection and its clinical efficacy. *Tuberc Respir Dis (Seoul)* 2018;81:6-12.
- Handa R, Upadhyaya S, Kapoor S, Jois R, Pandey BD, Bhatnagar AK, et al. Tuberculosis and biologics in rheumatology: a special situation. *Int J Rheum Dis* 2017;20:1313-1325.
- Abitbol Y, Laharie D, Cosnes J, Allez M, Nancey S, Amiot A, et al. Negative screening does not rule out the risk of tuberculosis in patients with inflammatory bowel disease undergoing anti-TNF treatment: a descriptive study on the GETAID cohort. *J Crohns Colitis* 2016;10:1179-1185.
- Dobler CC. Biologic agents and tuberculosis. *Microbiol Spectr* 2016;4. doi: 10.1128/microbiolspec.TNMI7-0026-2016.
- Cantini F, Nannini C, Niccoli L, Petrone L, Ippolito G, Goletti D. Risk of tuberculosis reactivation in patients with rheumatoid arthritis, ankylosing spondylitis, and psoriatic arthritis receiving non-anti-TNF-targeted biologics. *Mediators Inflamm* 2017;2017:8909834.
- Cantini F, Nannini C, Niccoli L, Iannone F, Delogu G, Garlaschi G, et al. Guidance for the management of patients with latent tuberculosis infection requiring biologic therapy in rheumatology and dermatology clinical practice. *Autoimmun Rev* 2015;14:503-509.
- Lee SH. Diagnosis and treatment of latent tuberculosis infection. *Tuberc Respir Dis (Seoul)* 2015;78:56-63.
- Go U, Park M, Kim UN, Lee S, Han S, Lee J, et al. Tuberculosis prevention and care in Korea: evolution of policy and practice. *J Clin Tuberc Other Mycobact Dis* 2018;11:28-36.
- Winthrop KL, Siegel JN, Jereb J, Taylor Z, Iademarco MF. Tuberculosis associated with therapy against tumor necrosis factor alpha. *Arthritis Rheum* 2005;52:2968-2974.
- Gardam MA, Keystone EC, Menzies R, Manners S, Skamene E, Long R, et al. Anti-tumour necrosis factor agents and tuberculosis risk: mechanisms of action and clinical management. *Lancet Infect Dis* 2003;3:148-155.
- British Thoracic Society Standards of Care Committee. BTS

- recommendations for assessing risk and for managing Mycobacterium tuberculosis infection and disease in patients due to start anti-TNF-alpha treatment. *Thorax* 2005;60:800-805.
20. Lebwohl M, Bagel J, Gelfand JM, Gladman D, Gordon KB, Hsu S, et al. From the Medical Board of the National Psoriasis Foundation: monitoring and vaccinations in patients treated with biologics for psoriasis. *J Am Acad Dermatol* 2008;58: 94-105.