

Pulmonary Arteriovenous Malformations*

Screening Procedures and Pulmonary Angiography in Patients With Hereditary Hemorrhagic Telangiectasia

Anette Drøhse Kjeldsen, MD, PhD; H. Oxhøj MD, MSc; P. E. Andersen, MD; B. Elle, MD; J. P. Jacobsen, MD; and P. Vase, MD, MSc

Background: Hereditary hemorrhagic telangiectasia (HHT) is a dominantly inherited disease with a high prevalence of pulmonary arteriovenous malformations (PAVMs). The first symptom of HHT may be stroke or fatal hemoptysis associated with the presence of PAVM.

Objective: To evaluate different screening methods applied for the identification of PAVMs.

Setting: Odense University Hospital.

Subjects: HHT patients with positive findings on contrast echocardiography (CE) who participated in a screening investigation and underwent pulmonary angiography (PA).

Methods: Different screening methods were evaluated against the results of PA. In a group of patients with positive findings on CE, we compared results of PA with the following: severity of dyspnea; results of pulse oximetry arterial oxygen saturation (SaO_2) supine and upright; supine PaO_2 in room air and while breathing 100% oxygen; size of arteriovenous shunt in supine position; chest radiograph; and intensity of contrast at CE.

Results: PA was performed in 25 HHT patients with positive findings on CE, 15 of whom had PAVM. Embolization therapy was recommended in 12 patients, and 3 patients had small PAVMs not accessible for therapy. In 10 patients, PAVM could not be demonstrated at PA. The sensitivity and specificity calculated for the screening procedures are as follows: 53% and 90%, respectively, for SaO_2 ; 60% and 100%, respectively, for chest radiograph; 73% and 80%, respectively, for PaO_2 in room air; 100% and 40%, respectively, for PaO_2 breathing 100% oxygen; and 64% and 80%, respectively, for shunt measurement.

Conclusion: Initial screening with CE followed by measurement of PaO_2 while breathing 100% oxygen seemed to be the best screening procedure for identification of patients with PAVM. Screening with chest radiograph and pulse oximetry was shown to be insufficient.

(*CHEST* 1999; 116:432–439)

Key words: hereditary hemorrhagic telangiectasia; pulmonary arteriovenous malformation; pulmonary shunt; Rendu-Osler-Weber syndrome; screening

Abbreviations: CE = contrast echocardiography; HHT = hereditary hemorrhagic telangiectasia; NYHA = New York Heart Association; PA = pulmonary angiography; PAVM = pulmonary arteriovenous malformation; SaO_2 = arterial oxygen saturation

Pulmonary arteriovenous malformations (PAVMs) are direct communications between pulmonary arteries and pulmonary veins, resulting in an ana-

tomically right-to-left shunt that reduces the arterial oxygen saturation (SaO_2). Because of the invalidation of the filter function of the lung, paradoxical embolization may occur, resulting in neurologic complications such as stroke or cerebral abscess. These conditions may even be the first clinical manifestation of PAVM.¹ Patients with large shunts are hypoxemic and may experience dyspnea, clubbing, and polycythemia. Hemoptysis is quite common and may be fatal.² PAVMs may be present at birth, but in most cases they remain unrecognized until the late teenage years. Studies suggest that PAVMs grow during life.³ Their proliferation can cause rapid

*From the Department of Otorhinolaryngology (Drs. Kjeldsen and Vase), Svendborg Hospital, Svendborg, Denmark; and the Paediatric Cardiology Unit (Dr. Oxhøj), the Department of Radiology (Drs. Andersen and Elle), and the Department of Otorhinolaryngology (Drs. Kjeldsen and Jacobsen), Odense University Hospital, Odense, Denmark.

Supported by the Danish Medical Association Research Foundation and Ingemann O' Buchs Foundation.

Manuscript received October 22, 1998; revision accepted February 25, 1999.

Correspondence to: Anette Drøhse Kjeldsen, MD, PhD, Department of Otorhinolaryngology, Odense University Hospital, DK-5000 Odense C, Denmark; e-mail: ad.kjeldsen@ishmed.ou.dk

deterioration in physical capacity, especially during pregnancy or shortly after childbirth.⁴

The prevalence of PAVMs among patients with hereditary hemorrhagic telangiectasia (HHT) has been estimated to be 15 to 33%^{3,5,6}; screening for PAVM, with the purpose of preventing complications, is therefore relevant in this group of patients. The aim of the present investigation was to evaluate different screening methods for identification of PAVM in a population of HHT patients with a high prevalence of PAVM, in order to assess the sensitivity of the tests, as well as the ease and safety of application.

MATERIALS AND METHODS

All HHT patients identified during a comprehensive epidemiologic survey in the county of Fyn, Denmark (population approximately 500,000)⁷ and their first-degree relatives (age > 18 years) were offered screening for PAVM with contrast echocardiography (CE). The HHT diagnosis was based on the following: (1) presence of multiple (> 15) telangiectatic lesions; and (2) either a family history of bleeding or recurrent episodes of bleeding. The criterion of heredity was considered to be met if the presence of telangiectatic lesions in at least one first-degree relative could be demonstrated. For the recurrent bleeding criterion, telangiectatic lesions at the bleeding site were required. Patients with positive findings on CE were offered pulmonary angiography (PA). Selective biplane PA was performed in 25 HHT patients, and these patients constitute the study population of the present investigation.

All the patients underwent a clinical examination, and they were all asked about their physical capacity. The degree of dyspnea was rated according to the New York Heart Association (NYHA) class I to IV criteria.⁸

CE was performed with a 2.5-MHz transducer (SSA-270A; Toshiba Medical Systems; Tokyo, Japan). The clearest possible apical four-chamber image was obtained with the individual in the left lateral decubitus position. Simultaneously during the 2-day recording session, double M-mode recordings were obtained to facilitate detection and timing of contrast appearance. The echo contrast, a 10 mL 3.5% polygelin solution (Hemaccel; Hoechst Marion Roussel; Frankfurt, Germany), was agitated vigorously and injected rapidly into a peripheral vein while the patient was breathing quietly. Injections that did not result in readily observable contrast in the right-sided chambers were repeated. Delayed appearance of the contrast in the left-sided chambers (*ie*, three to five heart cycles after the appearance in the right-sided chambers) was deemed to indicate presence of a pulmonary shunt. In an attempt to quantify the shunt size, the contrast intensity in the left-sided heart chambers was rated subjectively from 0 to 4, with 0 indicating no visible contrast and 4 indicating equal contrast intensities in the left-sided and right-sided chambers.

Standard chest radiographs (anteroposterior and lateral views) were taken at maximum inspiration with the subject in the standing position. Chest radiographs were evaluated by the radiologist, who performed the PA procedures.

Pulse oximetry was performed in all subjects (model N20; Nellcor; Hayward, CA) with the patient breathing room air, in both the supine and upright positions. The sensor was placed on a finger tip, and the SaO₂ was recorded after a minimum of 2 min

of quiet breathing. An SaO₂ < 96% and/or a change in SaO₂ of two or more percentage points on changing posture was considered abnormal.

Measurement of the PaO₂ in the supine position was performed with the patient breathing room air and after breathing 100% oxygen. The results obtained on room air were compared with age-adjusted reference values.⁹

Shunt measurements were performed during PA prior to contrast injection. Blood samples were obtained simultaneously from the femoral artery and from the pulmonary artery after the patient had been breathing 100% oxygen for 15 min using a mouthpiece and a noseclip. Sampling of blood from the pulmonary artery allowed exact measurement of the oxygen content in the mixed venous blood. The fraction of the pulmonary shunt was calculated according to the equation:

$$\dot{Q}_s/\dot{Q}_t = (C_{cO_2} - C_{aO_2}) / (C_{cO_2} - C_{vO_2})$$

where \dot{Q}_s is the shunt flow, \dot{Q}_t is the total pulmonary flow, C_{aO_2} is the arterial oxygen content, C_{vO_2} is the oxygen content in mixed venous blood, and C_{cO_2} is the estimated oxygen content at the postalveolar end of the pulmonary capillary calculated from the alveolar air equation, assuming no alveolar-arterial oxygen tension difference.

RESULTS

Study Population

Twenty-five patients (14 men and 11 women) were included in the study and had PA performed (mean age, 44 years; range, 25 to 75 years). All fulfilled the diagnostic criteria for HHT and had positive findings on CE.

In 15 patients (8 men and 7 women), at least one PAVM was demonstrated at PA. Twelve of these patients had PAVMs with feeding vessels > 3 mm and were referred for embolotherapy, while 3 other patients had smaller PAVMs. All clinical data are shown in Table 1. Calculations of the sensitivity and specificity of the various screening procedures are shown in Table 2. The predictive values of positive and negative test results are also shown in Table 2.

Dyspnea

Patients with PAVMs reported severe dyspnea more often than patients without PAVM, but the patients' own experiences of dyspnea did not correlate very well with the shunt size. In one patient (patient 23), no information about dyspnea could be obtained because the patient had hemiparesis and was confined to a wheelchair.

CE

Of the 24 patients who underwent CE, 14 patients (58%) had PAVMs confirmed at PA. In one patient (patient 23), CE was not performed because the PAVM was diagnosed on chest radiograph. Contrast intensity at CE prior to PA could be evaluated in 23

Table 1—Results of Screening Procedures in 25 HHT Patients*

Patient No.	Age, yr/ Gender	SaO ₂ , % (Supine/Upright)	Dyspnea		PAVM at CXR	PaO ₂ , mm Hg (Air/Ref/100% O ₂)	Shunt, %	PAVM on PA
			NYHA Class	CE Contrast Intensity				
1	25/M	96/97	II	2	No	62/90/413	15	No
2	26/F	98/98	III	2	No	116/89/507	13	No
3	31/M	97/98	II	3	No	90/87/508	13	No
4	32/F	95/92	II	4	No	73/87/273	20	RML
5	32/M	98/100	I	2	No	98/87/544	9	No
6	33/M	98/99	II	2	No	95/87/476	10	No
7	34/M	98/99	II	3	No	87/87/508	11	No
8	35/F	88/86	IV	4	Yes	54/86/94	30	RLL × 3, RML × 2
9	35/M	98/98	I	3	Yes	80/86/407	17	LUL
10	40/F	99/99	II	3	No	80/84/454	14	RML
11	40/F	98/99	IV	2	No	107/84/281	20	No
12	40/M	95/95	II	3	Yes	87/84/389	13	RML
13	43/M	97/96	IV	4	No	73/82/397	13	LLL
14	44/M	94/92	III	2	Yes	69/82/142	20	LLL
15	46/F	99/100	III	2	No	73/81/403	16	No
16	47/M	98/97	II	1	Yes	79/81/412	14	LLL
17	48/M	99/99	II	1	No	84/80/480	13	No
18	50/M	95/96	III	3	No	98/79/488	8	RLL × 2
19	52/M	96/97	II	3	No	72/78/261	25	RUL
20	55/F	98/99	III	2	No	98/78/442	14	No
21	56/M	93/91	III	4	Yes	55/77/143	24	RUL, RML, RLL, LLL
22	57/F	97/98	II	—	No	93/76/336	16	LUL
23	60/F	94/94	—	—	Yes	74/75/211	30	LUL
24	63/F	98/99	IV	2	Yes	87/74/—	—	RLL × 2
25	75/F	92/—	III	4	Yes	62/69/141	26	RLL × 2

*PAVM at CXR = PAVM demonstrated on chest radiograph; Ref = calculated age-adjusted normal PaO₂ value; RML = right middle lobe; RLL = right lower lobe; LUL = left upper lobe; LLL = left lower lobe; RUL = right upper lobe; M = male; F = female.

patients; in 1 patient, the CE videotape unfortunately was lost. Five of the patients with PAVM demonstrated at PA (38%) were rated as having grade 4 intensity of contrast, whereas none of the patients with normal PA findings were so rated. The sensitivity of CE could not be evaluated from the present study because PA was not offered to patients with negative CE results.

Chest Radiography

PAVMs could be diagnosed on chest radiographs in only 9 of the 15 patients with PAVMs on PA. Of the six patients with PAVMs on PA and negative chest radiographs, three had PAVMs with feeding

vessels > 3 mm demonstrated at PA. All 10 patients with normal PA findings had normal chest radiographs. When PA is considered the “gold standard” for identification of PAVMs, the sensitivity of chest radiographs was 60% while the specificity was 100%.

Pulse Oximetry

In nine patients (36%), SaO₂ was abnormal (eight patients had values < 96% in at least one position; in patient 5, the values changed by 2%, from 100% to 98%, on changing posture). All eight patients with a low SaO₂ had PAVMs diagnosed via PA, while the patient with high values but a 2% fall on posture change had normal PA findings. Among the patients

Table 2—Screening Procedures in HHT Patients*

Procedure	Sensitivity	Specificity	Positive Predictive Value	Negative Predictive Value
SaO ₂ < 96%	53	90	—	56
Chest radiography	60	100	100	63
CE	100 estimated	—	58	—
PaO ₂ < 500 mm Hg at 100% oxygen	100	40	70	100
PaO ₂ < age-adjusted normal value ⁹	73	80	85	67
Shunt > 15%	64	80	81	57

*PA demonstrating all PAVMs serves as the “gold standard.” All figures are percentages.

with normal SaO_2 , seven had PAVMs demonstrated at PA. The sensitivity of pulse oximetry was 53% and the specificity was 90%. Figure 1 shows the distribution of SaO_2 values in the supine position. The results obtained in the upright position were comparable.

Arterial Blood Gas Analysis

In 24 patients, analysis of PaO_2 while breathing 100% oxygen was performed (Fig 2). When we selected a high cut-off value with a PaO_2 of 500 mm Hg, the sensitivity of PaO_2 was 100% and the specificity was 40%. In all 25 participants, PaO_2 was measured while patients breathed room air, and the values were compared with age-adjusted reference values. The sensitivity was 73% and the specificity was 80%. The results are shown in Table 1 and Figure 2; in Figure 2, the distribution of PaO_2 values in patients with and without PA-documented PAVMs is shown.

Shunt Size

The pulmonary shunt size was calculated in 24 patients. The results of the comparison between shunt size and PA are shown in Figure 3. With a cut-off value of 15%, the sensitivity was 64% and the specificity was 80%.

DISCUSSION

Unexplained dyspnea, cyanosis, or reduced physical capacity may be the only clues to identify individuals with PAVM. Establishing the diagnosis of

PAVM is important in both symptomatic and asymptomatic individuals because treatment will reduce the risk of paradoxical embolus and cerebral abscess, and improve the well-being of symptomatic individuals.^{1,10,11} Treatment with embolotherapy is recommended if the diameter of the PAVM feeding vessel is > 3 mm.¹² Various screening protocols from different institutions have been suggested. At Hammersmith Hospital, pulse oximetry, chest radiography, and lung perfusion scanning using $^{99\text{m}}\text{Tc}$ -macroaggregated albumin are recommended.¹³ At Yale University, initial screening with CE, chest radiography, and shunt study is recommended, followed by helical CT scanning.¹⁴ Haitjema et al⁶ performed initial screening with chest radiographs and room-air arterial blood gas analysis.

The present study was designed to evaluate different screening procedures. For initial screening, we used CE, which is highly sensitive and therefore is believed to identify all PAVMs.¹⁵⁻²⁰ Patients with negative findings on CE were, for ethical reasons, not investigated further. A number of patients with positive findings on CE declined referral for PA, either because they had no pulmonary symptoms at all or because their general health was poor. Because of selection bias, the prevalence of PAVM demonstrated by PA in the present study is not representative of the prevalence of PAVM in HHT patients in general.

PA is used to identify embolizable PAVMs and, from a therapeutic standpoint, PA can be considered a reference method. PA findings, including all demonstrated PAVMs, were chosen as the gold standard in the calculations of sensitivity and specificity. How-

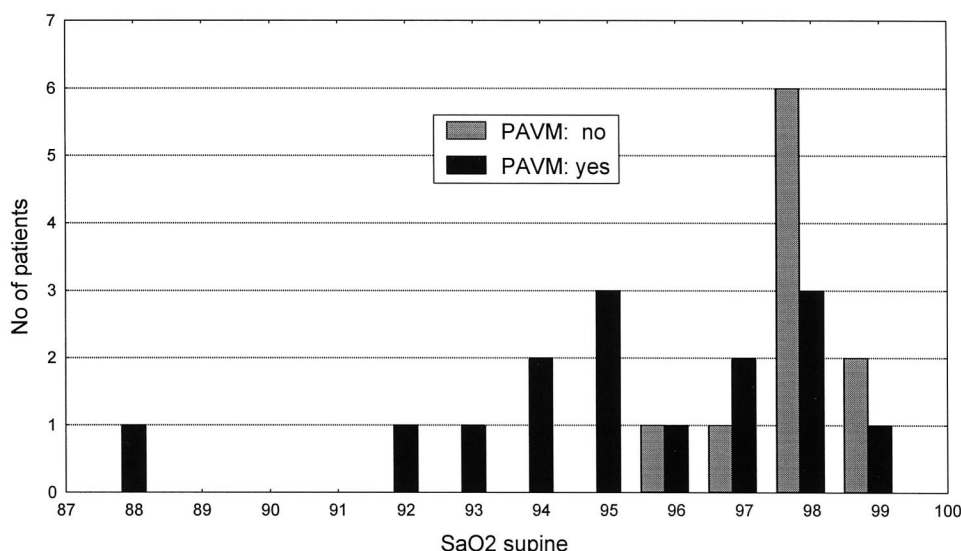


FIGURE 1. Distribution of supine SaO_2 values in patients with and without PAVMs.

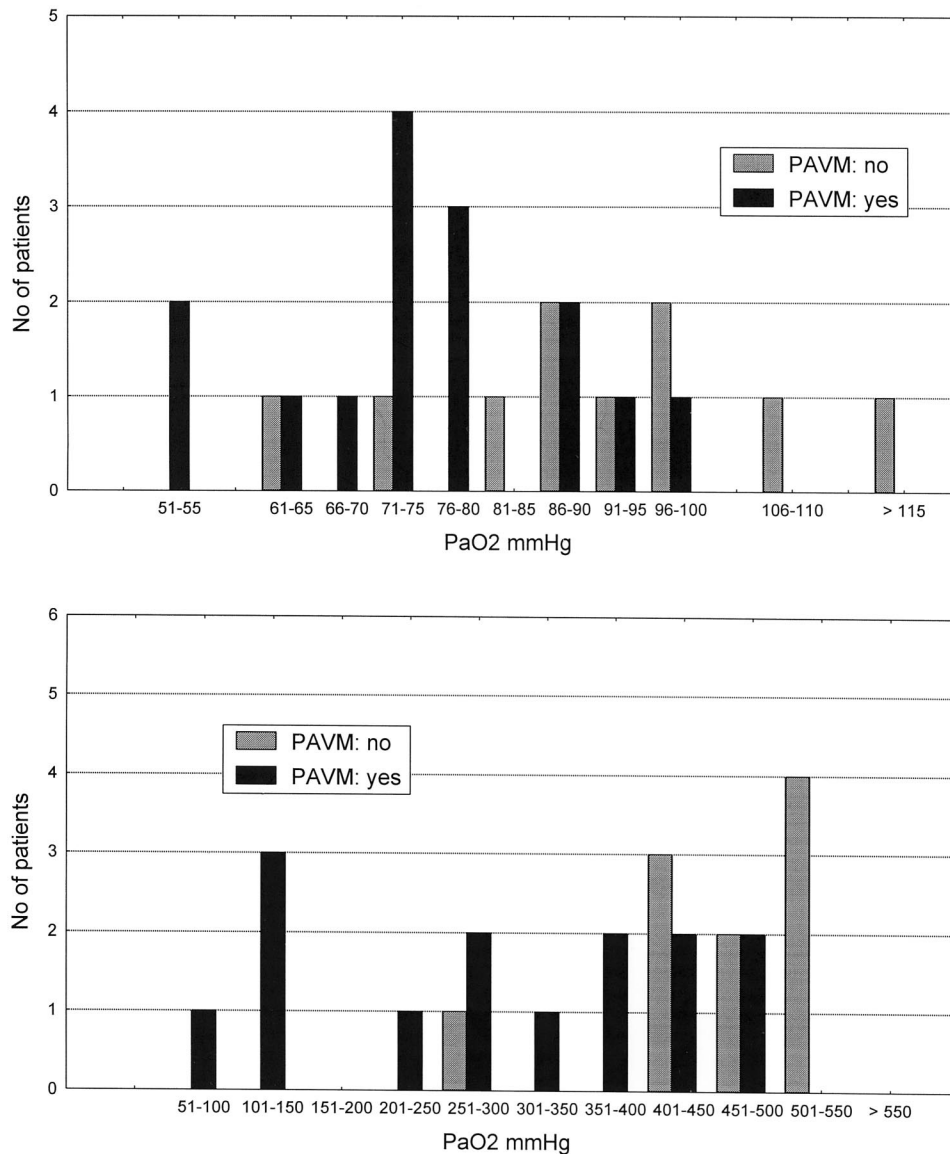


FIGURE 2. Distribution of arterial PaO₂ in patients with and without PAVMs. *Top*: values while breathing room air. *Bottom*: values while breathing 100% oxygen.

ever, widespread, diffuse minute PAVMs, which may cause significant shunt but cannot be identified with PA, have been described.²¹⁻²³ Thus, even PA cannot be considered the ultimate reference for identification of PAVM. This may very well explain why 10 of our patients had positive findings on CE and a measurable shunt, even though PAVM was not demonstrated by PA. Of the 15 patients in whom at least one PAVM was demonstrated, 12 patients had PAVMs with feeding vessels >3 mm. Embolization was recommended and subsequently carried out in our institution.²⁴

Available methods for shunt detection include radioisotope angiography with labeled microspheres,²⁵ measurement of oxygen saturation with

pulse oximetry, arterial blood gas analysis,^{12,13,21,22} and CE.^{26,27} They are all minimally invasive and can be performed on an outpatient basis. The disadvantage is that the shunt size and the morphology are not described. CE is the only shunt-detecting method that can differentiate between a cardiac and a pulmonary shunt.

Since the late 1960s, it has been well documented that microbubbles introduced in a peripheral vein produce intracardiac ultrasonic contrast.^{15,16} In the present study, we used Hemacel, which is a well-established contrast agent.^{16,28-30} When echo contrast is injected into a peripheral vein in healthy subjects, microbubbles > 8 μm are sieved by the pulmonary capillaries, whereas smaller microbubbles

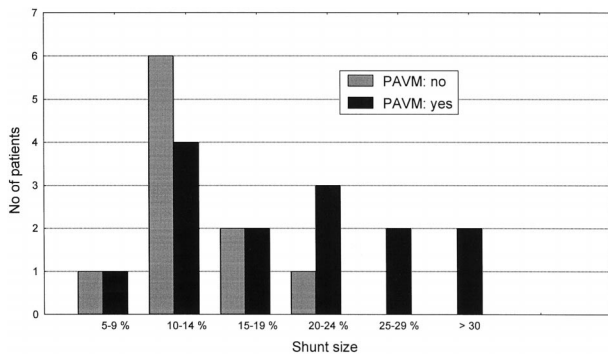


FIGURE 3. Distribution of shunt size in patients with and without PAVMs.

dissolve in the pulmonary circulation before they reach the left side of the heart,¹⁷⁻²⁰ making CE a highly sensitive screening procedure for the detection of PAVM.¹⁵ In two studies of children with heart disease, PAVM was diagnosed in 2 of 889 patients and 18 of 82 patients, respectively.^{23,31} PAVM was diagnosed in 3 of 167 adults studied with transesophageal CE to assess patency of foramen ovale.³² No false-positive outcomes were reported in any of these studies.

In the present study, we correlated the intensity of echo contrast with the results of PA. Patients with PAVMs did seem to have a higher contrast intensity, and all five patients who had grade-4 contrast intensity had PAVMs demonstrated at PA. However, the rating of contrast intensity is not an objective parameter and can only be used semiquantitatively. PAVM was not verified at PA in 42% of our patients who had positive CE findings; these patients represent false-positive test results with respect to the need for therapy. The majority of these patients had reduced PaO₂ while breathing either room air or 100% oxygen, and their positive CE findings are probably related to microscopic arteriovenous malformations.

In clinical practice, when dealing with a population at high risk of potentially hazardous complications, it is very important to use a highly sensitive method to exclude those patients who are not at risk from undergoing further and more invasive procedures. Because all patients with significant PAVMs are likely to be identified by CE,¹⁵ this procedure seems to fulfill this criterion.

Pulse oximetry with the patient breathing room air has the advantage of being easily applicable, even at home. The disadvantage is that patients with hypoxemia from causes other than pulmonary shunting have false-positive test results with respect to PAVM. Furthermore, false-negative test results are common because the development of PAVM may be a regional phenomenon, and the impact of regional

arterial desaturation may be blunted by the mixture of blood from other parts of the lungs.²³ With the SaO₂ cut-off value used in the present study, 96%, we failed to diagnose PAVMs in seven patients.

Because PAVMs are typically located in the basal parts of the pulmonary circulation, a decrease in PaO₂ caused by PAVM is most pronounced in the upright position in the majority of patients.^{21,33} Posture-related changes in SaO₂ were observed in only five patients; in one of them, PAVM was not detected by PA, whereas the other four (patients 4, 8, 14, and 21) had large PAVMs in the lower lobes. In the majority of patients, we did not observe large variations in SaO₂ on changing posture.

Our results indicated a high sensitivity of PaO₂ measurements with the patients breathing 100% oxygen, because all patients with PAVMs were identified. However, the rather high cut-off value of 500 mm Hg also produced many false-positive results. The results of room-air PaO₂ measurements were compared with an age-adjusted reference value.⁹ The screening failed to diagnose PAVM in four patients, and embolotherapy was recommended for all four. Evaluation of the results obtained in the upright position did not alter the conclusion. The discomfort of arterial puncture and the low specificity may disqualify room-air PaO₂ measurements as an initial screening procedure.

Measurement of shunt size was performed just prior to PA with the patient in the supine position. In previous shunt studies using the 100% oxygen method, the venous oxygen content was estimated.^{6,14,34} In the present study, mixed venous blood could be sampled in the pulmonary artery, allowing a more precise shunt calculation. We calculated the shunt assuming that there was no alveolar-arterial oxygen tension difference. All 25 patients had shunts > 5%, although PAVMs were demonstrated at PA in only 15 patients. These results indicate that small PAVMs, which cannot be demonstrated by means of PA, may be common in HHT patients. The significance of the microscopic shunts needs further inves-

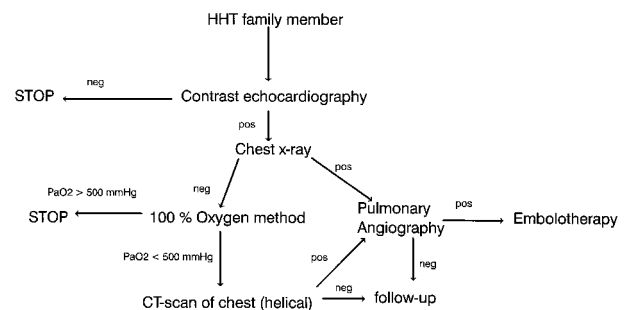


FIGURE 4. Algorithm for PAVM screening.

tigation. The present study gave no indication as to whether a small PAVM will increase in size over the long term, or whether patients with microscopic PAVMs have an increased risk of paradoxical embolus, either bacterial or bland thrombus. These issues also need further study.

The degree of dyspnea was recorded according to the NYHA classification.⁸ The severity of self-reported dyspnea did not correlate very well with the size of the shunt or with the measured PaO₂. These findings may partly be explained by the fact that patients with PAVM are used to having a reduced physical capacity. Three of the four patients who reported severe dyspnea had PAVMs. The degree of self-reported dyspnea has limited relevance in screening for PAVM.

Standard chest radiographs may demonstrate PAVM as a pulmonary mass connected by enlarged arteries and veins. Unfortunately, many PAVMs remain undetected by this method because they are located posteriorly in the lung behind the diaphragm, or they may be hidden in the hilar region.³⁵ In such cases, the diagnosis may be difficult, even for skilled radiologists.¹⁰ Furthermore, the malformation may resemble, and be mistaken for, a neoplasm or a tuberculoma.³⁶ In one of our patients, chest radiographic findings had previously been misinterpreted as cancer at the referring hospital; the diagnosis was corrected at the university hospital. In the present study, the sensitivity of the chest radiograph was only 60%: the PAVM diagnosis was missed in six patients even though the radiographs were evaluated by a specialist in radiology on the look out for PAVM. With these results, we could not confirm the results from an earlier Dutch study⁶ in which the results of PA and chest radiography were compared in 98 HHT patients, and the sensitivity and specificity of standard chest radiography were 83.3% and 91.7%, respectively. Therefore, we recommend that a negative findings on chest radiograph in an HHT patient should be followed by more sensitive screening procedures.

Helical CT scanning seems to be very promising method in establishing the PAVM diagnosis.³⁷⁻³⁹ Helical CT scanning was not considered in the present study, because it was not available at our institution at that time. The screening procedures recommended are shown in Figure 4.

CONCLUSION

Screening for PAVMs among HHT patients is highly recommended because a PAVM may cause potentially hazardous complications. A screening protocol should be able to safely identify all PAVMs,

with the smallest possible number of patients proceeding to extensive investigations (PA in this study). We have evaluated different screening procedures and conclude that CE followed by measurement of PaO₂ after breathing 100% oxygen fulfills these requirements. However, a high cut-off value (500 mm Hg) for PaO₂ measurements is recommended. Our results also indicate that screening with chest radiography, pulse oximetry, and room-air PaO₂ is insufficient and cannot be recommended.

REFERENCES

- 1 Hewes RC, Auster M, White RI Jr. Cerebral embolism: first manifestation of pulmonary arteriovenous malformation in patients with hereditary hemorrhagic telangiectasia. *Cardiovasc Intervent Radiol* 1985; 8:151-155
- 2 Ference BA, Shannon TM, White RI Jr, et al. Life-threatening pulmonary hemorrhage with pulmonary arteriovenous malformations and hereditary hemorrhagic telangiectasia. *Chest* 1994; 106:1387-1390
- 3 Vase P, Holm M, Arendrup H. Pulmonary arteriovenous fistulas in hereditary hemorrhagic telangiectasia. *Acta Med Scand* 1985; 218:105-109
- 4 Showlin CL, Winstock AR, Peters AM, et al. Medical complications of pregnancy in hereditary hemorrhagic telangiectasia. *Q J Med* 1995; 88:879-887
- 5 Kjeldsen AD. Epidemiological and clinical aspects of hereditary hemorrhagic telangiectasia, Mb [thesis]. Osler. Odense, Denmark: Odense University; 1998
- 6 Haitjema T, Disch F, Overtom TT, et al. Screening family members of patients with hereditary hemorrhagic telangiectasia. *Am J Med* 1995; 99:519-524
- 7 Kjeldsen AD, Vase P, Green A. Hereditary hemorrhagic telangiectasia: a population-based study of prevalence and mortality in Danish patients. *J Intern Med* 1999; 245:31-39
- 8 Criteria Committee of the New York Heart Association. Nomenclature and criteria for diagnosis of diseases of the heart and great vessels. 9th ed. Boston, MA: Little, Brown & Co, 1994
- 9 Mellemgaard K. The alveolar-arterial oxygen difference: its size and components in normal man. *Acta Physiol Scand* 1966; 67:10-20
- 10 Guttmacher AE, Marchuk DA, White RI Jr. Hereditary hemorrhagic telangiectasia. *N Engl J Med* 1995; 333:918-924
- 11 Sisel RJ, Parker BM, Bahl OP. Cerebral symptoms in pulmonary arteriovenous fistula: a result of paradoxical emboli (?). *Circulation* 1970; 41:123-128
- 12 White RI Jr, Lynch-Nyhan A, Terry P, et al. Pulmonary arteriovenous malformations: techniques and long-term outcome of embolotherapy. *Radiology* 1988; 169:663-669
- 13 Hughes JM. Intrapulmonary shunts: coils to transplantation. *J R Coll Physicians Lond* 1994; 28:247-253
- 14 Wirth JA, Pollak JS, White RI Jr. Pulmonary arteriovenous malformations. In: George RB, Douglas G, Campbell GD Jr, et al, eds. *Current pulmonology and critical care medicine* (vol 17). St. Louis, MO: Mosby Year-Book, 1996; 261-298
- 15 Gramiak R, Shah PM. Echocardiography of the aortic root. *Invest Radiol* 1968; 3:356-366
- 16 Ernst A, Cikes I, Custovic F. Polygelin colloid solution as an echocardiographic contrast agent. *J Cardiovasc Ultrasonography* 1984; 3:143-145
- 17 Meltzer RS, Tickner EG, Popp RL. Why do the lungs clear ultrasonic contrast? *Ultrasound Med Biol* 1980; 6:263-269

- 18 Meltzer RS, Reisner SA. Contrast echocardiography in the Doppler color flow imaging era [editorial]. *J Am Coll Cardiol* 1989; 13:687-688
- 19 Meltzer RS, Tickner EG, Sahines TP, et al. The source of ultrasound contrast effect. *J Clin Ultrasound* 1980; 8:121-127
- 20 Berwing K, Schlepper M. Echocardiographic imaging of the left ventricle by peripheral intravenous injection of echo contrast agent. *Am Heart J* 1988; 115:399-408
- 21 Dutton JA, Jackson JE, Hughes JM, et al. Pulmonary arteriovenous malformations: results of treatment with coil embolization in 53 patients. *AJR Am J Roentgenol* 1995; 165:1119-1125
- 22 Chilvers ER, Whyte MK, Jackson JE, et al. Effect of percutaneous transcatheter embolization on pulmonary function, right-to-left shunt, and arterial oxygenation in patients with pulmonary arteriovenous malformations. *Am Rev Respir Dis* 1990; 142:420-425
- 23 Bernstein HS, Brook MM, Silverman NH, et al. Development of pulmonary arteriovenous fistulae in children after cavopulmonary shunt. *Circulation* 1995; 92:309-314
- 24 Andersen PE, Kjeldsen AD, Oxhøj H, et al. Embolotherapy for pulmonary arteriovenous malformations in patients with hereditary hemorrhagic telangiectasia (Rendu-Osler-Weber syndrome). *Acta Radiologica* 1998; 39:723-726
- 25 Ueki J, Hughes JM, Peters AM, et al. Oxygen and ^{99m}Tc-MAA shunt estimations in patients with pulmonary arteriovenous malformations: effects of changes in posture and lung volume. *Thorax* 1994; 49:327-331
- 26 Barzilai B, Waggoner AD, Spessert C, et al. Two-dimensional contrast echocardiography in the detection and follow-up of congenital pulmonary arteriovenous malformations. *Am J Cardiol* 1991; 68:1507-1510
- 27 Hernandez A, Strauss AW, McKnight R, et al. Diagnosis of pulmonary arteriovenous fistula by contrast echocardiography. *J Pediatr* 1978; 93:258-261
- 28 Santoso T, Roelandt J, Mansyoer H, et al. Myocardial perfusion imaging in humans by contrast echocardiography using polygelin colloid solution. *J Am Coll Cardiol* 1985; 6:612-620
- 29 Zotz R, Duwe L, Erbel R, et al. [Right heart ventriculography using Gelifundol]. *Z Kardiol* 1989; 78:95-100
- 30 Ernst A, Breyer B, Scoggins W, et al. Correlation of left heart high blood velocities measured with continuous-wave Doppler and contrast echocardiography. *J Cardiovasc Ultrasonography* 1988; 7:329-334
- 31 Van Hare GF, Silverman NH. Contrast two-dimensional echocardiography in congenital heart disease: techniques, indications and clinical utility. *J Am Coll Cardiol* 1989; 13:673-686
- 32 de Belder MA, Tourikis L, Griffith M, et al. Transesophageal contrast echocardiography and color flow mapping: methods of choice for the detection of shunts at the atrial level? *Am Heart J* 1992; 124:1545-1550
- 33 Hughes JM. Pulmonary arteriovenous malformations in hereditary hemorrhagic telangiectasia. *Semin Respir Crit Care Med* 1998; 19:79-89
- 34 Whyte MK, Peters AM, Hughes JM, et al. Quantification of right to left shunt at rest and during exercise in patients with pulmonary arteriovenous malformations. *Thorax* 1992; 47:790-796
- 35 Flower CD. Imaging pulmonary arteriovenous malformations [editorial]. *Br Med J Clin Res Ed* 1987; 294:1633-1634
- 36 Prager RL, Laws KH, Bender HW Jr. Arteriovenous fistula of the lung. *Ann Thorac Surg* 1983; 36:231-239
- 37 Touloupoulos P, Costello P. Helical (spiral) CT of the thorax. *Radiol Clin North Am* 1995; 33:843-861
- 38 White RI Jr, Pollak JS. Pulmonary arteriovenous malformations: diagnosis with three-dimensional helical CT; a breakthrough without contrast media [editorial; comment]. *Radiology* 1994; 191:613-614
- 39 Remy J, Remy Jardin M, Giraud F, et al. Angioarchitecture of pulmonary arteriovenous malformations: clinical utility of three-dimensional helical CT. *Radiology* 1994; 191:657-664

Need a reason
to attend
CHEST 1999
in Chicago?

Reason
46

Join the
Speakers' Bureau

We have 65.

CHEST 1999 • October 31 - November 4 • Chicago, Illinois
For more information call 800-343-2227 or visit ChestNet
at www.chestnet.org/CHEST/1999/announce.html