

Morphometric Characteristics of Neuropeptide Y Immunoreactive Neurons in Cortex of Human Inferior Parietal Lobule

Dragan Krivokuća¹, Laslo Puškaš², Nela Puškaš³ and Mirela Erić¹

¹ Department of Anatomy, School of Medicine, University of Novi Sad, Novi Sad, Serbia

² Department of Anatomy, School of Medicine, University of Belgrade, Belgrade, Serbia

³ Department of Histology and Embriology, School of Medicine, University of Belgrade, Belgrade, Serbia

ABSTRACT

The aim of this study was to demonstrate and precisely define the morphology of neurons immunoreactive to neuropeptide Y (NPY) in cortex of human inferior parietal lobule (IPL). Five human brains were used for immunohistochemical investigation of the shape and laminar distribution of NPY neurons in serial section in the supramarginal and angular gyrus. Immunoreactivity to NPY was detected in all six layers of the cortex of human IPL. However a great number of NPY immunoreactive neurons were found in the white matter under the IPL cortex. The following types of NPY immunoreactive neurons were found: Cajal-Retzius, pyramidal, inverted pyramidal, »double bouquet« (bitufted), rare type 6, multipolar nonspinous, bipolar, voluminous (»basket«), and chandelier cells. These informations about morphometric characteristics of NPY immunoreactive neurons in cortical layers, together with morphometric data taken from brains having schizophrenia or Alzheimer's-type dementia may contribute to better understanding patogenesis of these neurological diseases. The finding of Cajal-Retzius neurons immunoreactive to NPY points to the need for further investigations because of great importance of these cells in neurogenesis and involment in mentioned diseases instead of their rarity.

Key words: human, parietal lobe, neurons, immunohistochemistry, neuropeptide Y

Introduction

Inferior parietal lobule (IPL) consists of two gyri: angular (AG) and supramarginal (SG). According to Brodmann's division, its cortex belongs to two areas: 39 (AG) and 40 (SG). Further parcellation provided by Eidelberg and Galaburda¹ demonstrated that cortex of IPL could be divided into five cytoarchitectonic areas, out of which three belong to AG, and remaining two belong to SG. Parietal cortex can be recognized by the presence of layer IV. In some parts of parietal cortex layer IV is very prominent. These densely granulated regions are organized in few islands and surrounded by regions of thinner layer IV, which are called disgranular cortex². Specially formed layer IV is typical for parietal cortex and exists only in humans and primates³.

The increase of parietal lobe is typical for humans and its development partially depends on the influence from

external stimuli⁴. Human IPL, as other parts of the heteromodal association cortex, according to Frederikse and his associates⁵, was reported to have sexual differences in cortex volumes. They stressed that male left IPL was more voluminous than in females and that left-right asymmetry was more prominent among male subjects. Heteromodality of IPL association cortex is confirmed by a vast number of different investigations, mostly dealing with regional blood flow changes (rCBF) in various states, diseases and disorders. It is widely accepted that IPL integrates somatosensory and visual stimuli. For example, using functional magnetic resonance imaging (fMRI) it is shown that naming tools activate more the rostral part of the left IPL cortex than other brain areas⁶. Also, significant increasing of rCBF after cutaneous and intramuscular pain stimuli was observed in the region of

Brodmann's area 40⁷. In the memory examination study, provided by positron emission tomography (PET), a direct comparison of conceptual and perceptual tasks showed that conceptual tasks activated medial and lateral left hemisphere in frontal and temporal regions as well as the lateral aspect of bilateral inferior parietal lobule⁸. Patients with lesion parts of IPL had neglect of the opposite body part⁹.

Last few decades of the 20th century could be also named as »transmitters decades«, due to the rapid development in technologies indispensable for the investigation of many aspects of neurotransmitters in neurosciences. Our attention was turned to one of them.

Neuropeptide Y (NPY) is a 36-amino acids peptide, isolated as avian pancreatic polypeptide¹⁰. Co-localization of this peptide with somatostatin reactive neurons is noticeable, especially in temporal cortex¹¹. NPY immunoreactive neurons have close relations with the blood vessels¹². It has been confirmed that it has taken parts in the regulation of systemic blood pressure, feeding, anxiety, and memory¹³.

Transmitters of primary gastrointestinal origin (NPY, cholecystocinin – CCK, leucin-enkefalin – L-Enk, substance P – SP) were reported to be significantly reduced in schizophrenia. Neuropeptide deficit was more pronounced in temporal and frontal lobe of patients with schizophrenia¹⁴.

The aim of our study was to determine the morphological aspect of neurons containing NPY in the inferior parietal lobule, i.e. to observe their distribution through cortical layers, measure diameters of perikarya, maximal diameter of their axonal and dendritic branches.

Material and Methods

Five human brains of both sexes (3 male aged 38, 48, 54 and two female, aged 59 and 81) were examined. The independent Ethics Committee of the School of Medicine, Belgrade, approved the study. Regarding their medical documentation they were without neurological or psychiatric diseases or disorders. Postmortal interval was from 3 to 6 hours. The brains underwent perfusion with Zamboni fixative (0.4 M phosphate buffer, 4% paraformaldehyd and picric acid) 3–6 hours after death and put in the same solution for 7 days. After that blocks of AG and SG were isolated from hemispheres (human SG surrounds the ascendant part of the posterior ramus of lateral (*Sylvian*) fissure; AG surrounds the terminal part of superior temporal sulcus) and postfixed 3 days, and then immersed into 30% sucrose solution for 48 hours. Study was performed on consecutive free-floating 60 µm thick sections which were cut on a frigomobile. After washing in 0.1 M phosphate buffer pH 7.4 (PB) during 2 hours, sections were incubated in 0.5% Triton X-100 solution overnight and endogenous peroxidase activity was blocked by using 3% H₂O₂ (Reanal) during 10 minutes. After treating with 10% normal goat serum (Miles Laboratories, Napperville) for 1 hour, the sections were incubated in NPY antibody (made in rabbit 1:16000; from our

laboratory) for 48 hours at 4 °C. The characterization of the antisera used from our laboratory was described formerly^{15,16}.

After rinsing in PB sections were incubated in 1:500 biotinylated antirabbit IgG solution, than in biotinylated avidin-peroxidase complex (1:250) (Vector Laboratories, CA) for 1 hour at room temperature. The tissue bound peroxidase was visualized with nickel enhanced 3,3' diaminobenzidine (Ni-DAB) chromogen reaction resulting a dark blue reaction product.

Immunoreactive neurons and fibers were drawn by Camera lucida (Olympus) and photographed on the light microscope (Olympus). Palkovits and Fischer method¹⁷ was applied for determining lamination of IPL cortex.

Average number of drawn and analyzed cells was between 30 and 50, except in the case of Cajal-Retzius cells because of their rarity (7 NPY immunoreactive neurons). The statistical analysis was performed using one-way analysis of variance (ANOVA). Differences were considered statistically significant at $p < 0.05$.

Results

Our sample showed that NPY neurons can be detected in all cortical layers, from I to VI, and that there were a large number of them in the white matter below IPL cortex, as well. NPY immunoreactive neurons in IPL cortex, were classified as followed:

Small Cajal-Retzius NPY IR neurons of layer I have 2–4 short, varicose dendritic processes (average radius of the arborization was 129.01 ± 32.07 µm), which are parallel to pial surface. The cell bodies were incorporated into a dense plexus of the NPY immunoreactive fibers and getting the axonal collaterals from the other cells (Figure 1).

The cell bodies of the pyramidal NPY immunoreactive neurons were obtained in the layer II (Figure 2). They possessed triangular cell bodies which major cell body diameter was 25 ± 4.3 µm and minor cell body diameter 13 ± 3.7 µm. The apical dendrite was convoluted and oriented toward pial surface. Three to four basal dendrites




Fig. 1. Cajal-Retzius cell of the layer I of human IPL; NPY immunoreactive neuron.

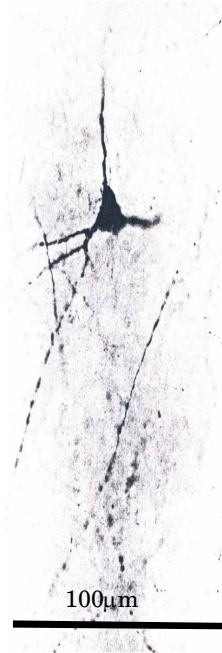

Fig. 2. Pyramidal NPY immunoreactive neuron of the layer II of human IPL.

come from the base and stretched out in $170 \pm 74.06 \mu\text{m}$ distance.

Improperly oriented or inverted pyramidal type of NPY immunoreactive neuron was a characteristic for lower cortical IPL layers (Figure 3). They measure $20 \pm 2.9 \mu\text{m}$ in length and $12 \pm 4.2 \mu\text{m}$ in width. Layer V of IPL cortex contains a representative sample these type of neurons: cell bodies were inverted for 180° , i.e. the apical dendrite was turned toward subcortical white matter and from the base arose four convolute dendrites which beard a small number of spines (sparsely spinous type). Dendritic radius layer V inverted pyramidal cells are considerable long ($300.3 \pm 88.55 \mu\text{m}$), while NPY immuno-

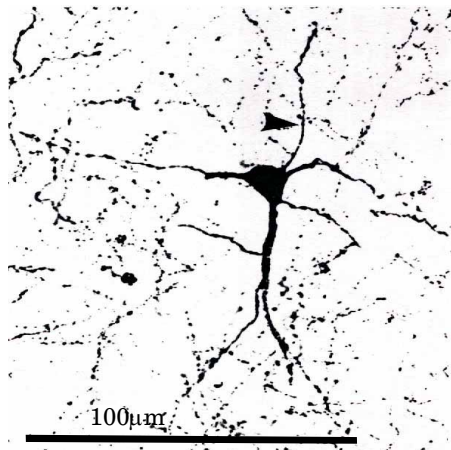


Fig. 3. Inverted pyramidal type of NPY immunoreactive neuron of human IPL; arrow indicate axon.




Fig. 4. »Double bouquet« (bitufted) NPY immunoreactive neuron of human IPL; arrow indicate axon.

reactive inverted pyramidal cells lying in the other layers have $147.53 \pm 8.57 \mu\text{m}$ length of the dendritic arborization.

»Double bouquet« (bitufted) NPY immunoreactive neurons were present in all IPL cortical layers, except layer I (Figure 4). Ovoid cell bodies belonged from small ($13.05 \pm 1.71 \mu\text{m}$) to large neuronal groups ($26.82 \pm 3.88 \mu\text{m}$). Dendritic field are vertically oriented and traversing into the other IPL cortical layers. Two to three main dendrites divide into a »bouquet« and bear a few spines, so they belong in the sparsely spinous cells group. Bitufted neurons in the layers II and VI possessed all features these type cells based on the Golgi impregnated cells morphology: bitufted dendritic tree, axon which emerged from the perikaryon or from the lower main dendritic shaft, and after short way branch into vertical ascending and descending smooth collaterals. Diameter of the dendritic arborization of the bitufted cells in layer III and VI were significantly longer ($217.42 \pm 68.35 \mu\text{m}$ to 389.25 ± 38.32 ; O-ANOVA $p=0.009$, respectively) in comparison to other NPY immunoreactive cell types.

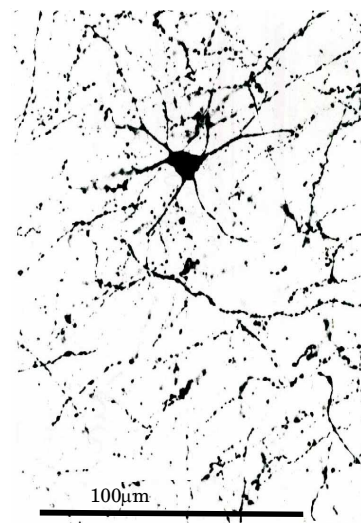


Fig. 5. Type 6 NPY immunoreactive neuron in the layer II of the IPL cortex.

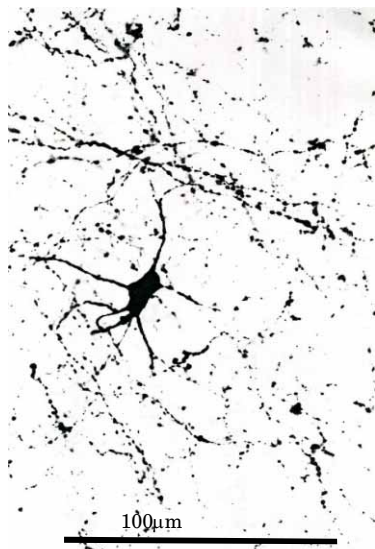

Fig. 6. Multipolar nonspinous NPY immunoreactive neuron.

Rare type 6 NPY immunoreactive cells in the layer II of the IPL cortex has a round perikarion (major axis $22 \pm 4.5 \mu\text{m}$ and minor $14 \pm 5.3 \mu\text{m}$) and six radially oriented dendrites which beared a small number of spines (Figure 5). Average radius of the arborization was $197 \pm 22.9 \mu\text{m}$.

Multiangular bodies and rich dendritic branching pattern characterized multipolar nonspinous NPY immuno-

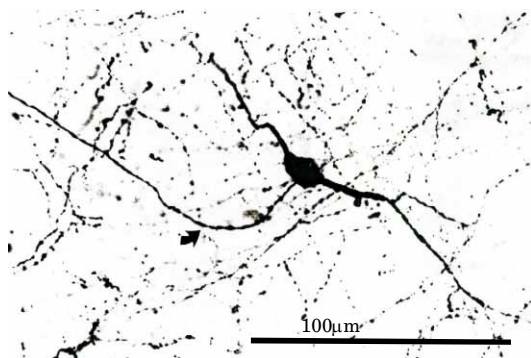


Fig. 7. Bipolar NPY immunoreactive neuron; arrow indicate axon.

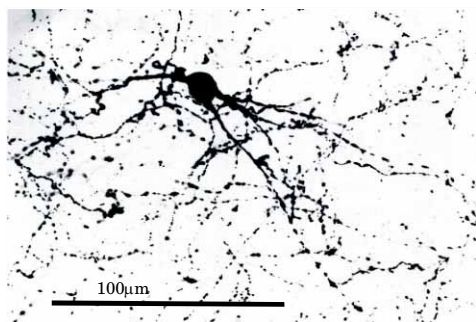


Fig. 8. »Basket« NPY immunoreactive neuron.

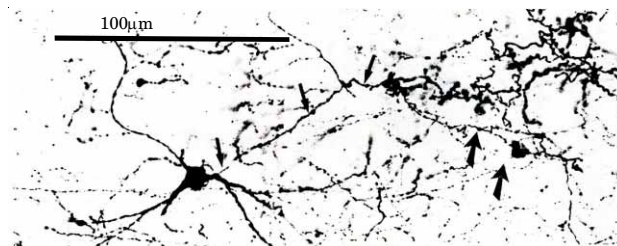


Fig. 9. Chandelier NPY immunoreactive neurons; arrows indicate axons.

reactive neurons. Their longer body diameter varied from rather small ($16 \pm 5.5 \mu\text{m}$) to large samples ($28 \pm 3.2 \mu\text{m}$), which had overall length of dendritic field from 110 ± 21.5 to $220 \pm 35.2 \mu\text{m}$ and were distributed in layers II, III, IV and V (Figure 6).

Bipolar NPY immunoreactive cells were concentrated in layers IV, V, VI, cell bodies predominantly were ovoid and they belonged to larger neurons: major cell body axis ranged from $27.35 \pm 7.32 \mu\text{m}$, while minor cell body diameter was $13.48 \pm 2.73 \mu\text{m}$ (Figure 7). Some of the NPY bipolar neurons are atypically (horizontally) oriented.

Voluminous, large NPY »basket« neurons with ovoid or multipolar cell body, tortuous dendrites with branches were irregularly scattered in the layer V. The average diameters were: longer $35.19 \pm 8.76 \mu\text{m}$; shorter $19.85 \pm 5.21 \mu\text{m}$. The most important feature of these cells is ascending axon from the upper part of the soma (Figure 8). Basket NPY immunoreactive cells, almost without exception, have a large dendritic trees ($259.85 \pm 18.05 \mu\text{m}$) with a few spines.

Chandelier cells could be only recognized by the form of their axons. Chandelier cell axon branched extensively and terminal tuft had a candle appearance. Chandelier NPY immunoreactive cells were rare and they were situated in layer VI (Figure 9). Perikarion was small, rounded with 3 main, radially oriented, dendrites. The somata of chandelier neurons were small ($14 \pm 6.3 \mu\text{m}$ major cell body diameter and $12 \pm 4.9 \mu\text{m}$ minor cell body diameter), but they had a long distance of their dendritic branching ($204 \pm 38.6 \mu\text{m}$ to $273 \pm 42.8 \mu\text{m}$). NPY immunoreactive fibers were abundant within all layers of IPL cortex, and were oriented in all directions.

Discussion

This investigation deals with the morphological variations among different types of NPY immunopositive neurons in the cortex of the inferior parietal lobule.

We used already accepted classification provided on Golgi impregnated specimens¹⁸ and if one is willing to compare bipolar Golgi impregnated neurons to some NPY immunoreactive neurons, he could see no differences between. Considering the perikarion position there was similar asymmetry as the one obtained among Golgi impregnated cells: the cells which bodies positioned in the middle of the IPL cortex had symmetrical

dendritic trees, while cells which somata lied in the deeper layers had longer upper dendritic trees and *vice versa*.

NPY, peptide studied in this investigation, like CCK, L-Enk and SP is also reported to be interfered in schizophrenia appearance by its reduced levels¹⁴, which was lately confirmed by the detection of morphological changes on NPY positive fibers in the hippocampus of schizophrenics¹⁹. The richness of the IPL cortex in NPY and CCK immunopositive neurons partially explains its involvement and consecutive changes of this region obtained in schizophrenic individuals^{5,20}, specially in the volumes of angular gyrus, which manifested a reversed asymmetry to one assessed among healthy controls. The polymorphism and heterogeneity in the shapes of NPY neuronal bodies, described as well in this paper, might be a base for further speculations linked to the functions of IPL, vaguely and only recognized by determined disturbances. If the memory loss and emotional deterioration could be explained by the degeneration hippocampal NPY-positive neurons¹⁹, than changes of mentioned neurotransmitter could be interfered in many losses of cognitive functions of the IPL. Briefly, NPY immunopositive neurons could be involved in learning process, together with the prefrontal cortex^{21–23}; region with representative wealth in NPY immunopositive neurons, very similar to IPL distribution²⁴.

Analysis of NPY immunoreactive neurons in Alzheimer's-type dementia showed that NPY neurons became distorted, with enlarged misshapen cell somata and reduced, thickened, and gnarled dendrites, and with sharp reduction in the extensiveness and delicacy of the axonal plexus. Besides the alteration in form and sizes, the NPY

population was not eliminated giving rise to the speculation that these peptide neurons may have unusual survival and reorganization potential even in terminal neurological disease²⁵.

Conclusion

Concluding discussion, we can say that the morphological variations in shape of the neuronal bodies which manifested immunoreactive labeling on NPY are indicating their involvement in various roles, in which cortex of the inferior parietal lobule takes part. This complexity of cortical functions is far from being entirely investigated; moreover the action of each neuronal group, divided either by the shape or immunopositivity, is yet to be discussed.

Morphological changes in NPY immunoreactive fibers in the hippocampus of patients with schizophrenia have been identified recently. Considering clinical investigations which point to the role of NPY in the pathogenesis of schizophrenia, together with data about morphological changes in NPY immunoreactive neurons in Alzheimer's-type dementia, as well as detection of a wealth of neurons immunoreactive to NPY and wealth in their morphology in the cortex of IPL suggest the role of these neurons in the pathogenesis of mentioned neurological diseases.

Acknowledgements

This work was supported by grant from Ministry of Science of Republic of Serbia N° 143004.

REFERENCES

- EIDELBERG D, GALABURDA AM, Arch Neurol, 41 (1984) 843. —
- PETERS A, JONES EG, Cerebral Cortex. Cellular Components of the Cerebral Cortex (Plenum Press 1, New York-London, 1984). —
- HAUG H, Am J Anat, 180 (1987) 126. —
- KAPPERS A, HUBER CU, CROSBY EC, The comparative anatomy of the nervous system of vertebrates including man (Hafner Publishing Company, New York, 1960). —
- FREDERIKSE ME, LU A, AYLWARD E, BARTA P, PEARLSON G, Cereb Cortex, 9 (1999) 896. —
- OKADA T, TANAKA S, NAKAI T, NISHIZAWA S, INUI T, SADATO N, YONEKURA Y, KONISHI J, Neurosci Lett, 296 (2000) 33. —
- SVENSSON P, MINOSHIMA S, BEYDOUN A, MORROW TJ, CASEY KL, J Neuropsychol, 78 (1997) 450. —
- BLAXTON TA, BOOKHEIMER SY, ZEFFIRO TA, FIGOLZZI CM, GAILLARD WD, THEODORE WH, Can J Exp Psychol, 50 (1996) 42. —
- HEIMER L, The second dissection. In: HEIMER L (Ed), Human brain and spinal cord, functional neuroanatomy and dissection guide (Springer-Verlag, New York-London-Berlin-Heidelberg-Tokyo, 1986). —
- SAID SI, MUTT V, Science, 169 (1970) 1217. —
- CHAN-PALAY V, J Comp Neurol, 260 (1987) 201. —
- GASPAR P, BERGER B, LESUR A, BORSOTTI JP, FEBRET A, Neurosci, 22 (1987) 49. —
- MUNGLANI R, HUDSPITH MJ, HUNT SP, Drug, 52 (1996) 371. —
- GABRIEL S, DAVIDSON M, HAROUTUNIAN V, POWCHIK P, BIERER L, PUROHIT D, PERL DP, DAVIS KL, Biol Psychiatry, 39 (1996) 82. —
- BAFFI J, GÖRCS T, SLOWIK F, HORVATH M, LEKKA N, PÁSZTOR E, PALKOVITS M, Brain Res, 570 (1992) 272. —
- CSIFFÁRY A, GÖRCS TJ, PALKOVITS M, Brain Res, 506 (1990) 215. —
- PALKOVITS M, FISCHER J, Karyometric investigations (Akademiai kiado, Budapest, 1968). —
- JONES EG, J Comp Neurol, 160 (1974) 205. —
- IRITANI S, KUROKI N, NIIZATO K, IKEDA K, Prog Neuropsychopharmacol Biol Psychiatr, 24 (2000) 241. —
- NIZNIKIEWICZ M, DONNINO R, McCARLEY RW, NESTOR PG, IOSIFESCU DV, O'DONNELL B, LEVITT J, SHENTON ME, Am J Psychiatry, 157 (2000) 428. —
- ELIASSEN JC, SOUZA T, SANES JN, Exp Brain Res, 141 (2001) 269. —
- KRIVOKUĆA D, The immunohistochemical and morphological characteristics of the amygdala PhD Thesis. In Serbian (School of Medicine, University of Novi Sad, Novi Sad, 2007). —
- PUŠKAŠ N, Cytohistological, morphometric and immunohistochemical characteristics of the rat amygdaloid complex. MSc Thesis. In Serbian (School of Medicine, University of Belgrade, Belgrade, 2003). —
- UYLINGS HB, DELALLE I, J Comp Neurol, 379 (1997) 523. —
- CHAN-PALAY V, LANG W, ALLEN YS, HAESLER U, POLAK JM, J Comp Neurol, 238 (1985) 390.

D. Krivokuća

Department of Anatomy, School of Medicine, University of Novi Sad, Hajduk Veljkova 3, 21000 Novi Sad, Serbia
e-mail: drdragan.k@neobee.net

MORFOMETRIJSKE KARAKTERISTIKE NEUROPEPTID Y IMUNOREAKTIVNIH NEURONA U KORI LOBULUS PARIETALIS INFERIOR ČOVJEKA

SAŽETAK

Cilj ovog rada bio je prikazati i precizno definirati morfologiju neuropeptid Y (NPY) imunoreaktivnih neurona u kori *lobulus parietalis inferior* (IPL) čovjeka. Na pet ljudskih mozgova, u serijskim rezovima supramarginalne i angularne vijuge, vršeno je imunohistokemijsko ispitivanje oblika i laminarne distribucije NPY imunoreaktivnih neurona. Imunoreaktivnost na NPY otkrivena je u svih šest slojeva kore IPL čovjeka. Međutim, veliki broj NPY imunoreaktivnih neurona nađen je u bijeloj tvari ispod kore IPL. Nađeni su sljedeći tipovi NPY imunoreaktivnih neurona: *Cajal-Retzius*, piramidni, obrnuti piramidni, »double bouquet«, rijedak tip 6, multipolarni nespinozni, bipolarni, voluminozni (»basket«) i lusteraste stanice. Ove informacije o morfološkim karakteristikama NPY imunoreaktivnih neurona slojeva kore, zajedno sa morfološkim podacima dobijenim izučavanjem mozgova pacijenata oboljelih od šizofrenije ili Alzheimerovog tipa demencije mogu pridonijeti boljem razumjevanju patogeneze ovih neuroloških bolesti. Nalaz *Cajal-Retzius* neurona imunoreaktivnih na NPY ukazuje na potrebu daljnjih istraživanja zbog velike važnosti tih stanica u neurogenezi navedenih bolesti iako su veoma rijetke.